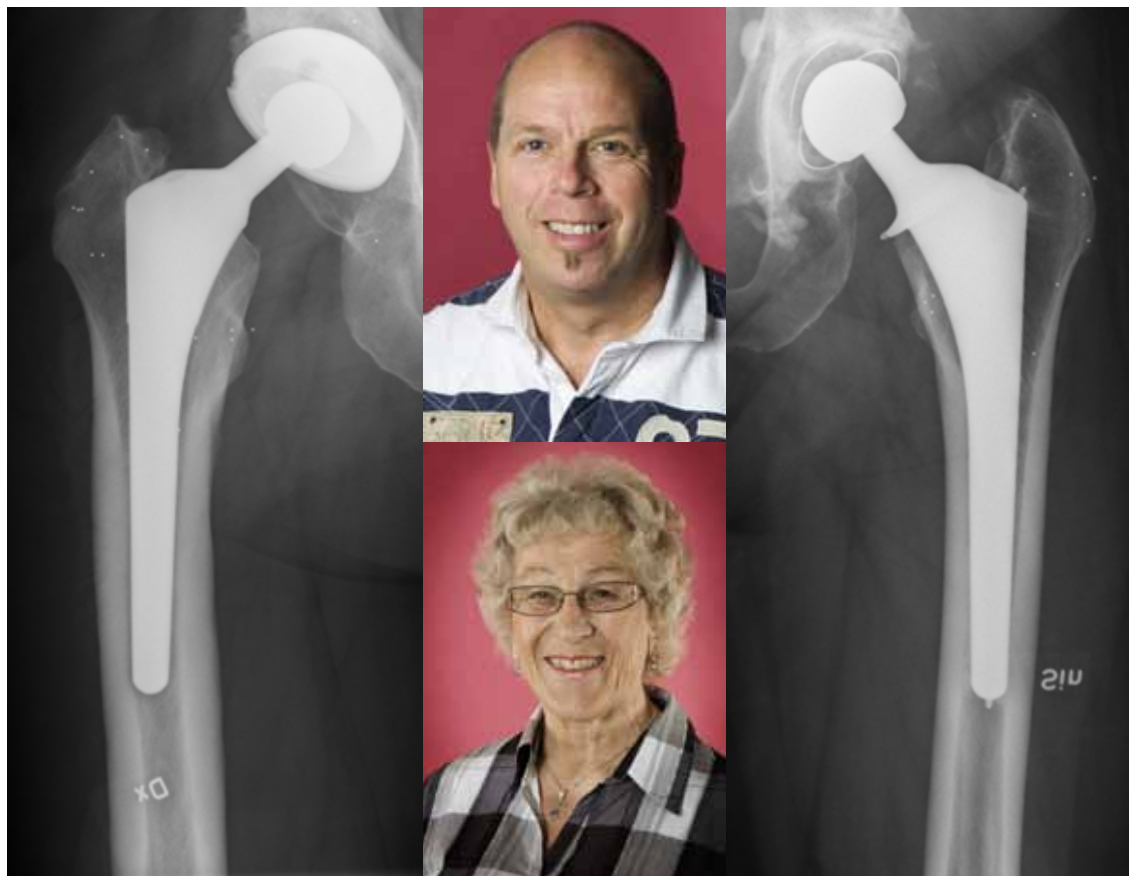

UNCEMENTED FEMORAL STEMS

Studies on periprosthetic bone remodelling and prevention of bone loss in total hip arthroplasty



Olof Sköldenberg



**Karolinska
Institutet**

200
1810 – 2010 *Years*

From
DEPARTMENT OF CLINICAL SCIENCES, DANDERYD HOSPITAL
Karolinska Institutet, Stockholm, Sweden

UNCEMENTED FEMORAL STEMS

STUDIES ON PERIPROSTHETIC BONE
REMODELLING AND PREVENTION OF
BONE LOSS IN TOTAL HIP ARTHROPLASTY

Olof Sköldenberg



**Karolinska
Institutet**

Stockholm 2010

All previously published papers were reproduced with permission of the publisher.

Published by Karolinska Institutet.

Art direction by Robert Szczypinski.

Photos on the cover by Zarah Jonsson.

The top photo and left radiograph is a patient from *Study III*.

The bottom photo and right radiograph is a patient from *Study IV*.

Printed by Elanders Sverige AB.

© Olof Sköldenberg, 2010

ISBN 978-91-7457-131-8

For Gabriella

ABSTRACT

Introduction

Tapered uncemented femoral stems are popular implants in total hip arthroplasty (THA). They are easy to use and excellent long-term results have been reported for patients with primary osteoarthritis of the hip (OA).

The disadvantages of these devices include post-operative periprosthetic bone loss, the clinical importance of which is still uncertain, and an increased risk of early periprosthetic fractures. These stems rely on initial primary stability to achieve biological fixation to bone. Poor bone quality, such as in patients with previous surgery of the hip or osteoporosis, is therefore generally considered to be a contraindication.

Hypotheses

We hypothesized that (1) femoral periprosthetic bone loss occurs after implantation of these devices and is related to the stem size used as well as the pre-operative bone mineral density (BMD) of the hip, (2) that femoral hip revision surgery using these implants is a reliable procedure with predictable mid-term results despite compromised proximal femoral bone stock prior to revision, (3) that a bisphosphonate will reduce the femoral periprosthetic bone loss and finally (4) that a tapered, uncemented, hydroxyapatite-(HA) coated femoral stem can provide durable fixation and good clinical outcome in elderly patients with osteoporotic fractures of the femoral neck.

Materials and methods

Two similar tapered uncemented HA-coated femoral stems were used in the studies. Bone mineral density (BMD) was measured using Dual-energy X-ray Absorptiometry (DXA), migration was assessed using radiostereometry (RSA) and Einzel-Bild-Röntgen-Analyse (EBRA). Clinical outcome was evaluated using the Harris hip score (HHS) and health related quality of life (EQ-5D)

Results

STUDY I

In a retrospective study, a single cohort of 138 patients with a unilateral THA was examined 3 years after surgery with DXA. It was found that periprosthetic proximal bone loss was related to stem size. Patients with the larger stem sizes lost more bone than patients with smaller stems.

STUDY II

In a retrospective analysis of 60 patients, who were examined 6 years after uncemented femoral stem revision surgery due to aseptic loosening, we found a 95% survival rate of the stem and no cases of aseptic loosening. We also noted that all stems were stable according to radiological parameters and that the clinical outcome was acceptable.

STUDY III

In a randomized, double-blind, placebo-controlled trial of 73 patients with hip OA, risedronate was given once weekly for 6 months following THA surgery. Risedronate reduced the proximal femoral bone loss by 7% up to 12 months post-operatively. In both groups, patients with a low pre-operative BMD lost significantly more bone than patients whose initial BMD was high.

STUDY IV

In a prospective single-cohort study of 50 cognitively intact elderly patients operated with a new HA-coated stem due to a displaced FNE, we found stable stems after 3 months. We also found a continuous decrease in BMD around the stems up to 2 years after surgery. Patients with osteoporosis lost more bone than patients with a normal BMD.

Conclusions

Periprosthetic bone loss after THA can be reduced with bisphosphonate treatment. Future studies on prevention of bone loss after THA should focus on patients who have a low pre-operative BMD of the hip.

An uncemented, tapered HA-coated stem can be used successfully for elderly patients with osteoporotic fractures of the femoral neck. Further studies are needed to ascertain whether uncemented femoral stems are superior, equivalent or inferior to cemented stems in the treatment of FNFs in the elderly. ◉

ARTICLE INFORMATION

Investigations performed between 2003 and 2010 at the Orthopaedic Department of Danderyd Hospital, Stockholm, Sweden.

CORRESPONDENCE

Dr. Olof Sköldenberg
olof.skoldenberg@ds.se

KEYWORDS

Total hip arthroplasty
Uncemented
Stem size
Bone remodelling
Stress-shielding
Hydroxyapatite
Osteoarthritis
Femoral neck fracture
Dual-energy X-ray Absorptiometry
Radiostereometry
Clinical outcome

ACKNOWLEDGMENTS

I would like to thank everyone at the Orthopaedic Department of Danderyd Hospital, Stockholm, Sweden for their contributions to this thesis.

I especially would like to extend my gratitude to my co-authors and the research nurses Helene Sjöo and Paula Kelly-Petterson for their invaluable help with inclusion of the patients and the clinical evaluations.

ISBN 978-91-7457-131-8

LIST OF PAPERS

This thesis is based on the following papers, which are indicated in the text by their Roman numerals (Studies I-IV).

I. Periprosthetic proximal bone loss after uncemented hip arthroplasty is related to stem size:

DXA measurements in 138 patients followed for 2-7 years.

Olof Sköldenberg, Henrik Bodén, Mats Salemyr, Torbjörn Ahl, Per Adolphson
Acta Orthopaedica 2006; 77 (3): 386-92

II. Good results with an uncemented proximally HA-coated stem in hip revision surgery:

62 hips followed for 2-13 years.

Mats Salemyr, Olof Sköldenberg, Henrik Bodén, Torbjörn Ahl, Per Adolphson
Acta Orthopaedica 2008; 79 (2): 184-93

III. Risedronate given once weekly prevents periprosthetic bone resorption after total hip arthroplasty.

A randomized, double-blind, placebo-controlled trial.

Olof Sköldenberg, Mats Salemyr, Henrik Bodén, Torbjörn Ahl, Per Adolphson
Submitted

IV. A new uncemented hydroxyapatite-coated femoral stem for treatment of femoral neck fractures.

A two-year radiostereometric and bone densitometric evaluation in 50 hips.

Olof Sköldenberg, Mats Salemyr, Henrik Bodén, Torbjörn Ahl, Arne Lundberg, Per Adolphson
Submitted

CONTENTS

1	Abbreviations	8
2	Definitions	9
3	Introduction	10
	3.1 History of hip arthroplasty	10
	3.2 Uncemented hip arthroplasty	15
	3.3 Introduction of new implants	21
	3.4 Bone remodelling	22
	3.5 Stem revision after failed hip arthroplasty	25
	3.6 Hip arthroplasty and femoral neck fractures	27
	3.7 Uncemented hip arthroplasty at Danderyd Hospital	28
4	Aims	31
5	Hypotheses	31
6	End points	32
7	Patients	33
8	Materials	36
9	Methods	38
	9.1 Surgery	39
	9.2 Radiological methods	41
	9.3 Clinical outcome measurements	49
	9.4 Statistical methods	50
10	Results	52
11	Discussion	61
	11.1 Discussion on Material	61
	11.2 Discussion on Methods	63
	11.3 Discussion on Results	65
	11.4 Strengths and limitations	71
	11.5 General discussion	73
12	Conclusions	77
13	Implications for future research	78
14	Acknowledgements	79
15	References	80
16	Studies	
	Study I	93
	Study II	103
	Study III	115
	Study IV	133

1 ABBREVIATIONS

ASA

American Society of Anesthesiologists

BMC

Bone mineral content

BMD

Bone mineral density

CDH

Congenital dysplasia of the hip

CoCrMb

Cobalt Chrome Molybdenum

DXA

Dual-energy X-Ray Absorptiometry

EQ-5D

European Quality of Life-5 Dimensions

FNF

Femoral neck fracture

HA

Hydroxyapatite

HHS

Harris hip score

OA

Osteoarthritis

PMMA

Polymethyl methacrylate

PNRS

Pain Numeric Rating Scale

RCT

Randomized controlled trial

RSA

Radiostereometric analysis

THA

Total hip arthroplasty

Ti-6Al-4V

Titanium-6Aluminium-4Vanadium

2 DEFINITIONS

BONE CEMENT

PMMA mixed with barium sulfate and (often) antibiotics, used as a filler to fix implants to bone.

BONE INGROWTH

New bone formation (osteogenesis) directly into the porous structure of an implant.

BONE LOSS

When bone remodelling leads to a decrease of bone mass.

BONE REMODELLING

In this thesis, bone remodelling refers to the adaptive change of bone architecture leading to a detectable change in either BMD or radiological appearance on x-ray.

DISUSE ATROPHY

Bone mineral decrease due to offloading of bone (stress-shielding).

EQ-5D

A 5-dimensional standardized instrument for use as a measure of health outcome.

HEMIARTHROPLASTY

A surgical procedure for repair of an injured or diseased hip joint (in this thesis) involving replacement of the head of the femur with a prosthesis and leaving the acetabulum intact.

HYDROXYAPATITE

A basic calcium phosphate mineral that is the principal inorganic constituent of bone and teeth.

LOOSENING

When implants are debonded from the substrate fixing them to bone, be it bone cement or osseous ingrowth.

OSSEOINTEGRATION

The direct structural and functional connection between living bone and the surface of a load-bearing artificial implant, typically made of titanium or titanium alloy.

OSTEOCONDUCTIVE

Refers to any structure that facilitates the formation of bone structure, often used to describe the properties of various types of bone grafts and bone graft substitutes.

OSTEOLYSIS

Localized areas of bone destruction and resorption caused by wear particles from the joint, can cause loosening of an implant.

PEDESTAL SIGN

Radiographically visible endosteal bone formation at the tip of the stem.

POLYMETHYL METHACRYLATE

A transparent plastic used in bone cement.

POROUS COATING

Coating on an implant applied to contain void regions with the intent of enhancing the fixation of the implant.

REVISION

In this thesis, revision surgery refers to a reoperation with replacement of one or several implant-parts.

SPOT WELD

Radiographically visible endosteal bone formation bridging from the cortical bone to the implant surface.

STRESS-SHIELDING

Off-loading of (in this thesis) bone.

Ti-6Al-4V

An alloy of titanium, 6% aluminum and 4% vanadium, used extensively as an alloy for uncemented implants.

TITANIUM

A shiny, white metallic element that is lightweight, strong, and highly resistant to corrosion.

UNCEMENTED

Implants designed for fixation by bone ingrowth.

3 INTRODUCTION

Total hip arthroplasty (THA) is an extraordinarily successful surgical procedure that has rightly been proclaimed “The Operation of the Century”.¹⁷¹ Since the introduction of the modern low-friction arthroplasty by Sir John Charnley,⁵⁴ millions of patients with degenerative and traumatic joint disease have been restored to good function and an improved quality of life after surgery.

3.1 HISTORY OF HIP ARTHROPLASTY

Degenerative joint disease and sequele after trauma have plagued man through history.¹¹⁵ Evidence of joint pathologies have been found in excavations of medieval *homo sapiens* as well as pre-historic *homo neanderthalensis*.²⁷⁸

During the 18th century, excision arthroplasty of a damaged joint was becoming increasingly popular. One of the early advocates of this procedure was Henry Parker (1744-1831). He worked at the Royal Infirmary in Liverpool and reacted to the appalling frequency with which amputation was used for injuries to the extremities. Liverpool was a port city with many sailors arriving from long voyages, sometimes with traumatic injuries that were months old. He practiced this procedure on the knee and elbow joints. In a letter to his mentor he describes his principles for treatment:²²⁹

“The resource I mean is the total extirpation of the articulation, or the entire removal of the extremities of all the bones which form the joints, with the whole, or as much as possible of the Capsular Ligament; thereby obtaining a cure by means of Callus.”

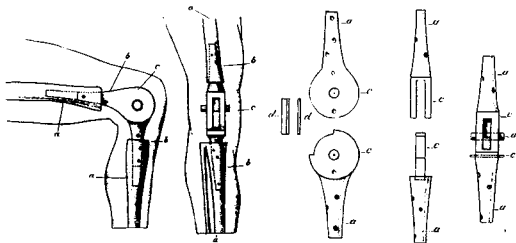


FIGURE 1. The Glück ivory total knee arthroplasty, with exploded view of knee prosthesis showing slots for horizontal fixation pegs. Reprinted from Eynon-Lewis et al.⁹⁶ with permission.

Anthony White (1782-1849) of the Westminster Hospital in London is credited with performing the first excision arthroplasty of the hip joint in 1821, although he never published a paper on the subject. The surgery was described in his obituary as follows:³⁰⁵

“He who first excised the head, neck and trochanters of the femur, the patient surviving the operation twelve years, and then dying consumptive . . . Mr. White had been unable, from his extensive practice, to contribute any literary work to the advancement of medical science . . .”*

Incidentally, he was also the first to describe *phlegmatic alba dolens* in an extremity, the condition which is now known as deep vein thrombosis. It is a common medical complication after THA.

However, this was before the dentist William Morthon’s discovery of sulphuric ether as an anaesthetic agent. The most important skill a surgeon possessed at this time, besides precision, was the ability to perform an amputation quickly. As amputation could be performed more quickly than excision arthroplasty, this prevented the surgery from gaining popularity. In addition, it was not until Joseph Lister’s (1827-1912) contribution of asepsis in the surgical field that the mortality rate for hip joint surgery dropped to below 50%. This was considered to be high, even by the surgical standards of the time.

The Berliner Professor Themistocles Glück (1853-1942) is attributed with performing the first total joint replacement operation.⁹⁶ On 20

*Relates to that the patient was affected with tuberculosis of the lungs. Septic tuberculosis of the joints was a common reason for surgery during this period.

May 1890 he performed a total knee replacement on a 17-year old woman whose knee had been destroyed by tuberculosis (Figure 1). One year later he implanted the first total hip arthroplasty consisting of an ivory ball and socket joint that he fixed to bone with nickel-plated screws.¹¹⁴ He subsequently experimented with a mixture of plaster of Paris and powdered pumice with resin to provide fixation.

Although his results, for his time, were spectacularly successful in the short term, they all ultimately failed due to chronic infection and prosthetic loosening. He was later forced to publish a declaration of repentance in which he took full responsibility for these failures. His idea of a total joint replacement was, nevertheless a very good idea, although the operations were performed on the wrong patients, at the wrong time.

Glück was far ahead of his time, discussing and experimenting on topics such as uncemented or cemented fixation of implants, stress-shielding and issues of biocompatibility.

Several more attempts at joint replacement were carried out with horrendous results during the later part of the 19th century. The first partially successful operation was not done until after the end of the First World War. Pierre Delbet, (1861-1925) a French surgeon, used a rubber femoral prosthesis in 1919 to replace one-half of the hip joint.

In 1923, the Norwegian-born American surgeon Marius Smith-Petersen (1886-1953) from Boston, Massachusetts performed a synthetic interpositional arthroplasty with a glass mold prosthesis. This arthroplasty was intended to facilitate bone-implant movement both on the femoral and the acetabular side of the implant.

He also described the anterior surgical approach to the hip which was used in this procedure. This approach is still commonly used in hip arthroplasty.²⁷³ It was not until 1937 however, when his dentist suggested that he try Vitallium® (an alloy of 60% cobalt, 20% chromium, 5% molybdenum and other substances) that predictable, and for the time, spectacular results, in pain relief for patients with degenerative joint disor-

ders were achieved.²⁷² Smith-Petersen implanted more than 500 of these devices (Figure 2).

The Judet brothers, Robert (1901-80) and Jean (1905-95) from Paris, France, received a lot of attention for their early prosthesis. They used an acrylic prosthesis in 1948 (Figure 3).¹⁴⁴ The Judet prosthesis showed itself to be exceptionally susceptible to wear, and failed even before the general acclaim had died down. However, there are still reports of Judet prostheses serving the patients well 50 years after implantation.



FIGURE 2. A Vitallium® Smith-Petersen interposition arthroplasty. Courtesy of Dr Ahl, photo by Carin Westström.



FIGURE 3. Newspaper advertisement for “the next big thing”, an artificial hip joint by the Judet brothers. This is a later version of the prosthesis in which the implant stem has been strengthened by stainless steel.

The radical solution of excision arthroplasty, was popularized by Gathorne Robert Girdlestone (1881-1950) in Oxford, United Kingdom¹¹¹ and is still occasionally used today as last resort in failed THA, a procedure that is simply called “conversion to a Girdlestone.”

The Judet brothers’ concept was refined by Frederick Röeck Thompson, (1907-83) who developed a Vitallium® prosthesis in 1950 which featured a distinctive flared collar below the head and a vertical intramedullary stem (Figure 4),²⁹¹ by Harold R. Böhlman (1893-1979) from Nebraska, and Austin Moore (1899-1963).

The stem was placed inside the femoral canal for stability and was connected in one piece (so called monoblock) with the artificial metal head (Figure 5). Dr. Moore inserted the first such metal prosthesis at John Hopkins Hospital in 1940 in a patient with a recurrent giant cell tumor.²¹¹ Böhlman and Moore refined their implant and in 1952 described a model that featured a fenestrated stem which allowed bone ingrowth. These were the first hip arthroplasty products that were to become widely used. Eventually they became legendary and are still used today for replace-

ment of the femoral head and neck, especially following femoral neck fractures (FNFs) in the elderly. In Sweden, 23 such hemiarthroplasties were implanted in 2008.¹⁰⁹

McKee and Watson-Farrar (1905-1991) of Norwich, England, developed prostheses in the late 1940s and experimented with dental acrylic cement [polymethyl methacrylate (PMMA)] for fixation. In the early 1950s, they started using the Thompson prosthesis on the femoral side that articulated with a three-claw type cup on a metal-on-metal articulation that was screwed into the acetabulum.²⁰⁴

Their high incidence of failure resulted from loosening of the components and there were unpredictable long-term results. However, there are several long term follow-ups showing a 84% survival of the implants at 20 years.⁴⁴

The concept of metal-on-metal articulation was “rediscovered” by McMinn²⁰⁵ and today another wave of metal-on-metal bearings is on the rise. The next contribution to the evolution of hip arthroplasty was made by Sir John Charnley and his so called low-friction arthroplasty of the hip, the modern THA.⁵⁴



FIGURE 4. Thompson monoblock hemiarthroplasty
Photo by Carin Westström



FIGURE 5. Austin Moore monoblock hemiarthroplasty
Photo by Carin Westström

Sir John Charnley and the low-friction arthroplasty

The remarkable achievements of Sir John Charnley (1911-1982) in the development of orthopaedic surgery in general and the modern THA in particular, cannot be overestimated. His work focused on joint friction and lubrication, recognizing the importance of achieving a low friction in THA.

He initially used McKee-Farrar's idea of using PMMA⁵⁵ to fixate an Austin-Moore stem in the femoral canal and used Teflon® – polytetrafluorethylene (PTFE) as the acetabular component. The initial results were good, but the PTFE wore out very rapidly, causing massive granulomatous tissue reactions, osteolysis and loosening of the components. Over the years, he altered the design of the stem to a slender stainless steel component with a fixed 22.2 mm head articulating on a high molecular weight polyethylene (HMWPE) acetabular component, both being cemented in place with PMMA, (Figure 6).

The first operation of this low-friction arthroplasty was performed in November 1962 and heralded a new era in THA surgery: that of predictable long-term results. Charnley also worked persistently on developing the surgical technique, improving all aspects of the procedure and also made enhancements to the surgical approach to the hip joint and the development of the instruments used as well as surgical sterility. He initially limited the use of his prosthesis

to surgeons whom he had personally trained and the prosthesis was not readily available to any surgeon who wished to use it until the early 1970s.

In Sweden, the first Charnley prosthesis was implanted into a patient at Södersjukhuset on 17th of February, 1968. The prosthesis is still the gold standard for a THA and the 20-25 year survivorship of the original prosthesis, with revision for any reason as end point, is approximately 80%¹⁸ for Charnley's own series and is similar for other independent surgical centers.³¹⁵

In the Swedish Hip Arthroplasty Register, where results are presented on a nation-wide basis, the 29-year survival of the original Charnley prosthesis is 72%, with revision for any reason as end point (Figure 7).¹⁰⁹ The cemented Charnley cup [although updated to ultra-high molecular weight polyethylene (UHMWPE)] is still one of the most widely used acetabular components in Sweden, but the stem is used more rarely. In 1977, Charnley was knighted by the Queen of England for his contributions to humanity.

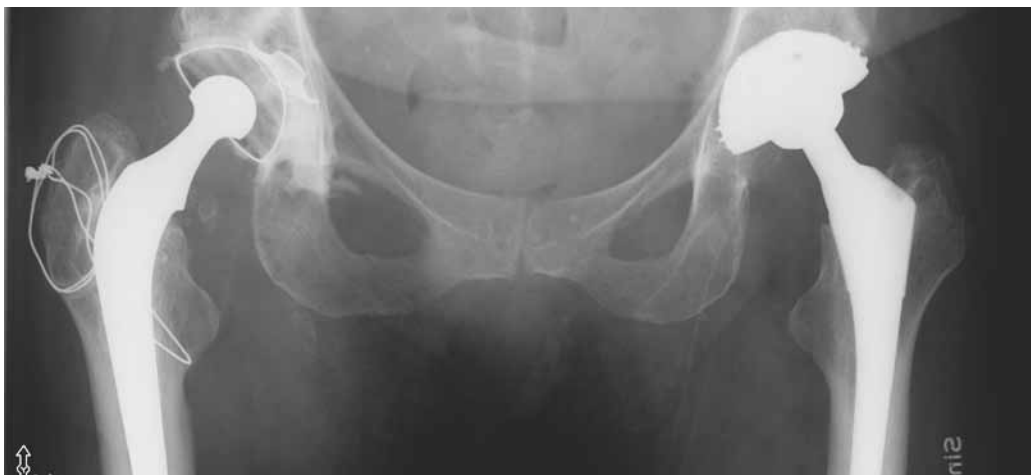

FIGURE 6. A 20 year old Charnley prosthesis on the patients' right side. On the left a 10 year old uncemented THA with the Bi-Metric stem.

The post-Charnley era and cemented implants

As in all aspects of medicine, the development of the THA has continued. Most implants have undergone several modifications over time. Simultaneously, advancements in sterility, surgical technique and instrumentation have also been made.

Mechanisms causing failure of early total hip replacement include fracture of the implant,⁵³ aseptic loosening as a result of mechanical failure of the fixation interface, infection,⁷⁸ polyethylene wear,³¹⁴ and dislocation.³¹¹ The importance of the surgical technique and that surgeons perform sufficient numbers of operations to achieve and retain proficiency are also paramount for good long term results in THA. In specialized centers, the 10-year revision rate for the Charnley prosthesis is typically around 3-7%,²⁵⁹ whereas the failure rate for the average surgeon can be significantly higher.⁹⁷

During the first decades of THA, infection was the most common reason for revision with infection rates of 5-10%. With improved surgical technique, laminar airflow in the operating room, improved clean air suits for surgeons and staff and the addition of antibiotics intravenously and to bone cement, the infection rate has dropped

significantly and is now around 1%.¹⁰⁹

The next problem, particularly in younger patients, was aseptic loosening of the stem and cup, caused by osteolysis – localized areas of bone destruction and resorption.⁷⁵ Since PMMA debris could be seen in histological samples of failed THAs with osteolysis,¹²⁸ this was originally attributed to a entity called “cement disease”.¹⁴³

This lead several investigators, particularly in the U.S.A, to direct their efforts towards the development of prostheses that could be implanted without use of cement. Later, osteolysis was found to be caused by wear from the polyethylene used^{79,125} and not by the cement itself.

Although the chemical composition of bone cement has essentially remained the same over the years, the cementation technique has changed radically. Bone cement is a grout not a glue and fixation is achieved by mechanical interlock rather than adhesion. Therefore, increased pressurization and cleaning of the endosteal bone with pulsed lavage significantly augmented cement intrusion into bone and enhanced the interface shear strength.¹⁸⁸

By using this so called third-generation cementing technique which also includes proximal and distal centralisers, reproducible creation of a complete, uniform, cement mantle is possible. The benefits of this technique have been shown in the Swedish Hip Arthroplasty Register, and very good mid-to-long-term results have been published.²¹⁶ In this register and by using the third-generation cementing technique, the 10-year survival rate of the Charnley THA is currently 93% (Figure 7).¹⁰⁹ Improvements in cemented femoral stems and acetabular components have also been made during the last decades and currently the 10-year survivorship of the 3 best performing THAs on a national level is, in Sweden, between 95% to 97%.¹⁰⁹

The details of this intricate and exhausting development of cemented THA lie, however, outside the scope of this thesis. ◉

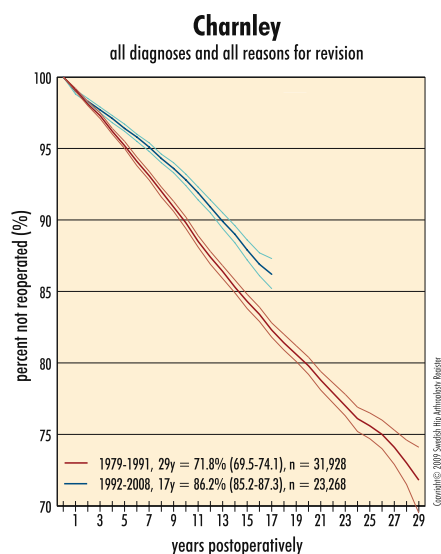


FIGURE 7. Implant survival of the original Charnley prosthesis. Reprinted with permission from the Swedish National Hip Arthroplasty Register.¹⁰⁹

3.2 UNCEMENTED HIP ARTHROPLASTY

The problems associated with loosening of cemented implants and the suspected “cement-disease” thus led to the development of uncemented implants, aimed at biological fixation. Furthermore, high failure rates were, and are still, reported for cemented and uncemented implants in younger patients (Figure 8 and Figure 9).^{51,75,109}

Today we know that particle-induced osteolysis caused by excessive wear from articulation is responsible for the majority of loosening. Nevertheless, implant manufacturers and researchers have been focusing on how to get reliable bony fixation of the implants. Implants had to be made with either a porous coating or a roughened surface that would allow intimate bony apposition to anchor the implant – bone ingrowth. Once the implant was biologically attached to bone, the component would allow normal transmission of biomechanical forces across the joint.

Acetabular cups

The early uncemented acetabular cups were threaded, had smooth surfaces and consistently showed poor results with continuous migration and alarmingly high revision rates.^{9,87,283}

This led to the development of modern uncemented press-fit hemispherical porous-coated acetabular components with revision rates as low as modern cemented acetabular components.¹⁰⁹

Despite this, the problem of late pelvic periprosthetic osteolysis is the main factor in reducing the longevity of these devices and is the focus of heated debate and extensive research.^{8,90,107,126,174} Pre-clinical and clinical research efforts in tribology has provided alternative articulations comprised e.g. of new polyethylene materials, with improved wear characteristics, so called highly cross-linked polyethylene (XLPE).⁷²

However, it is yet uncertain whether this new polyethylene will reduce the osteolytic potential. The current research on acetabular components also falls outside the scope of this thesis.

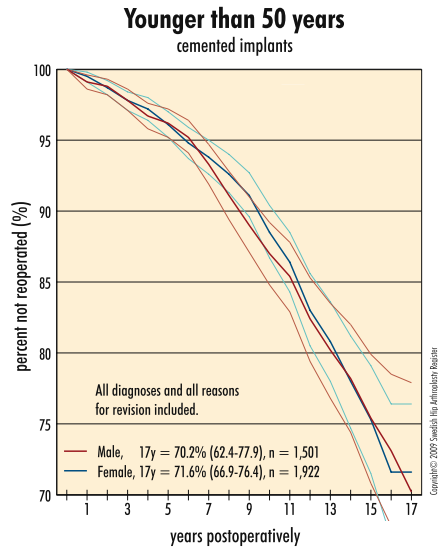


FIGURE 8. Implant survival of cemented implants in patients younger than 50 years on a national level. Reprinted with permission from the Swedish National Hip Arthroplasty Register.

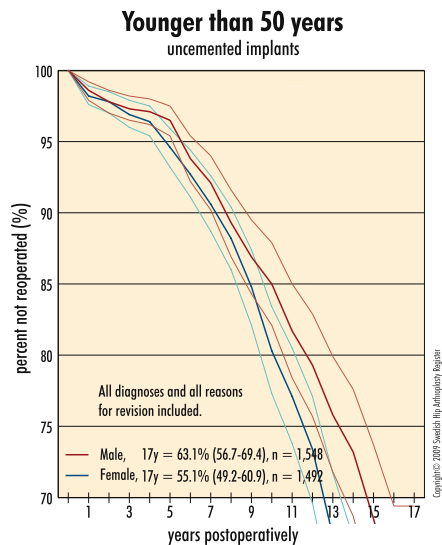


FIGURE 9. Implant survival of uncemented implants in patients younger than 50 years on a national level. Reprinted with permission from the Swedish National Hip Arthroplasty Register.

Design of stems

The first designs of uncemented femoral implants were cylindrical, with extensive porous-coating on the whole length of the implant.⁸⁵⁻⁸⁶ One example is the anatomic medullary locking (AML) stem (Depuy, Warsaw, Indiana) which initially, even though achieving fixation of the stem, caused a high rate of cortical atrophy, proximal stress-shielding and bone loss.

This remodelling of bone results from the mismatch between the stiffness of the flexible femur and the implant and is discussed in detail in *Study I* of this thesis.

The clinical manifestations of this mismatch are thigh pain,^{36,168} late presenting avulsion fractures of the greater trochanter¹³⁷ and presumably an increased susceptibility for periprosthetic femoral fractures and aseptic loosening. The AML stem, like many others, was therefore modified. First the proximal two-thirds, and later only the proximal one-third had porous coating. The philosophy thus was, and still is, to achieve metaphyseal fixation, thereby mimicking the natural loading of the femur. The AML stem is a *straight cylindrical stem* design and the coveted metaphyseal fixation is also used as a rationale for the *anatomic, tapered* and *press-fit* stem designs. An extreme variant of the press-fit design, still clinically unproven in the long-term perspective, is the so called *ultra-short* stem where the diaphyseal portion of the stem has been removed, thereby fully relying on metaphyseal fixation (Figure 10).^{4,260} The straight-stem design is still used widely among orthopaedic surgeons in its country of origin, U.S.A.

The anatomic stem design, as the name implies, incorporates an anteroposterior curve to match the natural bow of the patient's femur and is thus manufactured with a left and right-sided version. It was hoped that this curved stem would seat favorably in the metaphysis but instead they initially had problems with thigh pain and migration.^{48,147} The more modern design variations of the anatomic stem [e.g. ABG (Stryker, Newbury, UK)] (Figure 11) have largely overcome the problems of their predecessors and are widely used.¹⁵⁴

The tapered femoral stem use proximal cancellous bony ingrowth and three-point stem

fixation to obtain immediate stability. They can be provided with or without a collar to prevent excessive subsidence during ingrowth. The stems are often straight and wedged in a tight mechanical fit in the lower metaphyseal region. Clinical results of tapered stems with at least a 10-year follow-up have been good, with stem survivorship reported between 92% and 100%.^{37,233} Both stems used in this thesis are tapered femoral stems and are described in detail in chapter 6.

The press-fit femoral stem rely on the initial mechanical joining of the implant and the bone by high contact pressure.²⁹⁹ Modern press-fit femoral stems, just like the tapered stems, consistently have good results in arthroplasty registers with stems survivorship in arthroplasty registers of approximately 97% after 15 years with revision for all reasons as end point.^{109,120}

The geometrical classification of uncemented implants is problematic however, since there are numerous implants that cannot easily be classified into one of these categories and which uses a combination of implant philosophies to obtain rigid fixation in the femur.

It is also important to note that uncemented femoral stems, since they all rely on firm mechanical initial fixation of the implant to the bone, were originally intended for use in patients with a good bone stock e.g. younger patients with osteoarthritis (OA). When using these implants in patients with osteoporosis and a FNF the results are probably not as good as when using a cemented femoral stem*. There are however potential benefits of uncemented fixation in these patients and this is discussed in detail in *Study IV* where the use of a new uncemented, tapered, femoral stem in patients with a FNF is evaluated.

* In the Swedish and Australian hip arthroplasty registers, the revision risk for press-fit stems and other uncemented stems is higher in patients with a FNF than in contemporary cemented femoral stems.

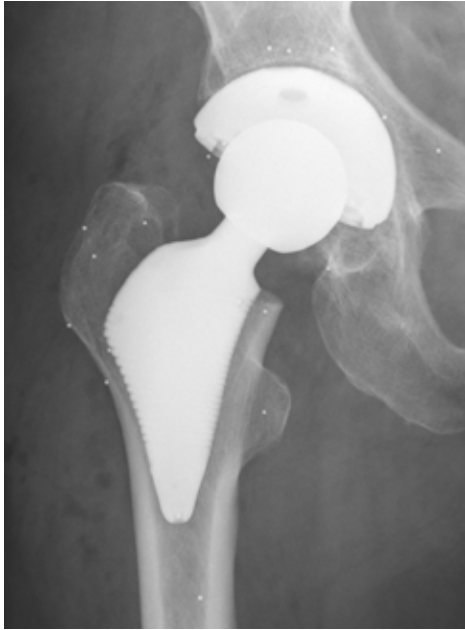


FIGURE 10. A ultra-short stem (Proxima®)
A new type of stem design to achieve metaphyseal fixation.



FIGURE 11. The anatomic ABG II stem
Courtesy of Dr Brangstrup, photo Carin Wesström

COBALT-CHROME MOLYBDENUM ALLOY

In the early 1970s, porous²⁴¹ or sintered fiber metal¹⁰⁶ cobalt-chrome molybdenum alloy (CoCrMb) implants, which allowed ingrowth of living bone into the surface, were introduced. Because of the concept of straight cylindrical femoral stems, the (initially) extensive porous coating and the relatively high stiffness of CoCrMb in relation to human femur, the stem was prone to cause disuse atrophy. Titanium alloys therefore became more popular with uncemented implants. CoCrMb is still a widely used alloy for femoral heads, for cemented femoral stems and together with hydroxyapatite coating for acetabular cups in resurfacing arthroplasties.

TITANIUM ALLOY

Pure titanium has a lower modulus of elasticity—closer to that of bone—and is more biocompatible than CoCrMb and was therefore the substrate of choice for uncemented implants.¹³² Titanium was proven by Brånemark to osseointegrate with living bone,⁴⁰ creating a direct structural and

functional connection between the bone and the surface of the implant.⁶

The strength of the bond between bone and titanium implants is of the same magnitude as bone itself.^{29,121} Pure titanium has a strength that is somewhat less than CoCrMb. If titanium is alloyed with 6% aluminum and 4% vanadium (Ti-6Al-4V) it was found to have superior mechanical properties while still having a favorable modulus of elasticity compared to CoCrMb.

At present, Ti-6Al-4V is the alloy of choice for most uncemented femoral stems. Using it as a bearing surface however has proven disastrous as metallic wear debris from the heads caused rapid, massive, osteolysis and loosening.¹⁸² Modular heads made of CoCrMb or ceramic materials are therefore used in combination with these stems.

For cemented femoral stems, there are reports of favorable long-term results with Ti-6Al-4V³⁸ but most researchers currently agree that the alloy is inferior to stainless steel or CoCrMb due to high revision rates.^{158,200,308}

COMPOSITE STEMS

To further mimic the natural flexibility of the human femur, and thereby in theory prevent bone resorption due to stress-shielding, the concept of isoelasticity — stems with the same modulus of elasticity as the femur — led to several different designs during the late 1970s.^{46,221} In theory, and on numerous in vitro experiments in cadaver femora, this seemed to be a good idea since forces in the hip were transformed in a more physiological manner using a flexible rather than a rigid stem.¹⁷⁶ The short term results were acceptable but all these concepts eventually failed with high revision rates due to aseptic loosening (Figure 12).^{141,294}

Computer simulated models later showed that flexible stems create high proximal stem/bone interface stresses, causing interface debonding and relative motions, possibly affecting implant loosening.¹³⁸ Therefore, the concept of isoelasticity should achieve a compromise between the optimal stem flexibility, which reduces interface stresses and, at the same time, only moderate stress shielding.²⁹⁴

A later attempt was made using the Epoch stem (Zimmer, Warsaw, Indiana, U.S.A.),¹¹³ a composite stem made of a thin, forged, CoCrMb core surrounded by polyaryletherketone, a thermoplastic polymeric adhesive that is molded between the core and an outer casting of titanium fiber metal (Figure 13).

The result is a stem that enables immediate stability and bone ingrowth along its entire

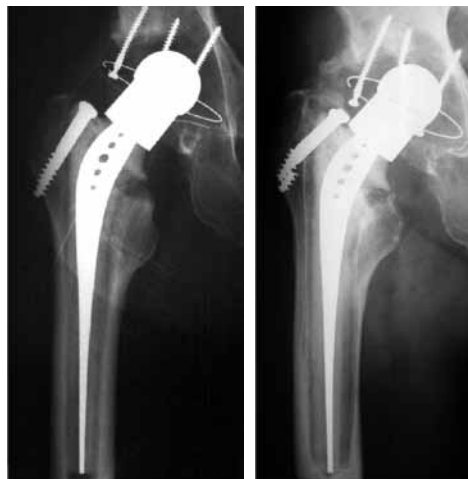

FIGURE 12. Radiograph of an isoelastic stem showing initial close contact between the implant and bone (left) and massive osteolysis and loosening after 9.7 years (right). Reprinted from Trebbe et al.²⁹⁴ with permission.

length and yet is less rigid than the corresponding CoCrMb or Ti-6Al-4V stems of similar size. In mechanical testing, the design has been shown to have a proximal stiffness equivalent to, and distally even less stiffness than, the human femur. In the short and medium term, this stem is clinically successful with low revision rates and favorable migration pattern measured with radiostereometry (RSA).^{164,286}

Bone remodelling in relation to the size and stiffness of a femoral implant is one of the main aspects of this thesis and is discussed in *Study I*.



FIGURE 13. The isoelastic Epoch® stem
Courtesy of Zimmer, Sweden.

POROUS COATINGS

To enable stable fixation of the implants after the initial period of mechanical interlock acquired at surgery, bone ingrowth into porous surfaces of the implants was advocated.²⁷⁹ This porous surface can be manufactured with beaded microspheres¹⁰⁶, by plasma spraying the implant²⁰⁶ or by using novel methods that mimic the micro-architecture of trabecular bone.²⁷

As has been previously discussed, osseointegration will occur with Ti-6Al-4V implants and this process can also be enhanced by grit-blasting the surface.⁶⁶ In fact, many manufacturers use a combination of proximal porous coating and distal grit-blasting on their stems, one such example of this is the Bi-Metric stem used in *Study I-III* of this thesis.

Regardless of whether the bone ingrowth occurs on an uncemented implant into a porous surface or directly against the prosthesis surface (osseointegration), load (stress) must be transferred with minimal micromotion at the implant/bone interface.

The bone ingrowth after surgery occurs through a series of events that are similar to fracture healing; inflammation, repair and bone remodelling.¹⁰⁶ During the first days after surgery, coagulated blood fills voids between the implant and bone. Thereafter, up to a few weeks after surgery, the hematoma is invaded by mesenchymal cells which promote osteoblast formation.

These initial osteoblasts form woven fiber bone and after approximately 4 weeks remodelling begins with the formation of parallel, lamellar, fiber bone with intramembranous ossification.²¹³

Micromotion between the implant and host bone, pore size and the size of the gap between the bone and the implant all influence bone ingrowth. Excessive motion of approximately 150

µm or more between the implant and host bone leads to fibrous tissue forming rather than bone ingrowth.^{5,242} The optimum pore size is in the range of 100-400 µm, corresponding to the pore size of trabecular bone (300 µm).²⁶⁻²⁷

Early designs of proximal coatings on femoral stems were applied in patches around the stem. This led to later failures as polyethylene particles gained access to the distal femur through channels between the areas of porous coating.²⁶³ This problem was rectified by applying the porous coating circumferential in the proximal part of the stem and thus reliable mid- and long-term results could be achieved (Figure 14).^{32,94,153}



FIGURE 14. Magnification of the circumferential proximal porous coating of a Bi-Metric stem that was revised for other reason than loosening. Note the large patches of bone ingrowth and the scratch marks from the revision surgery illustrating the inherent difficulty in removing a well fixated uncemented stem. Courtesy of Dr Eisler, photo Carin Wesström.

HYDROXYAPATITE COATING

Up to two-thirds of the dry weight of bone is inorganic mineral hydroxyapatite (HA), $(Ca_{10}(PO_4)_6(OH)_2)$, also known as bone mineral.⁹³ Using plasma spraying or chemical deposition, it is possible to coat implants with HA (Figure 15).

In experimental and in vivo settings this has been shown to have an osteoconductive effect. Thus, HA-coating can significantly increase the attachment strength of implants and facilitate a more rapid development of osseointegration.²⁹⁰

It also makes the surgical technique more forgiving by bridging gaps of up to 2 mm and mitigating the adverse effect of initial micromotion.^{274,277}

The HA resorbs in vivo, micromotion accelerates resorption and resorbed HA is partly replaced by newly formed bone, thus further enhancing the implant fixation.²⁷⁵




FIGURE 15. Hydroxyapatite

Scanning electron microscope of raw hydroxyapatite particles ranging from 100-300 nm in size.

HA and other ceramic coatings like tricalcium phosphate (TCP) have been added to uncemented stems and acetabular components to enhance the reliability of biological fixation.^{274,277} Like all well-fixed femoral components, osseointegration will result in adaptive femoral remodelling over time. Intuitively this should result in a somewhat larger bone mineral content (BMC) but this has only been studied twice in vivo in sufficiently sized trials.^{47,281,284}

These trials confirm earlier results from non-randomized studies,^{76,255} that it is possible to influence the bone remodelling and thereby the migration of a stem with HA-coating. However, proximally porous coated femoral stems, with and without HA, have similar long-term results in arthroplasty registers,²³⁴ so the relevance of this small difference in migration can be of negligible clinical relevance.

HA-coating has also been questioned because of the concern regarding particle release from wear and abrasion possibly affecting the long term results.²³ Lazarinis et al., in a recent report from the Swedish Hip Arthroplasty Register,¹⁷⁰ questioned the routine use of HA-coated cups in primary total hip arthroplasty. They found that HA-coating was a risk factor for cup revision due to aseptic loosening (adjusted RR 1.7; 95% CI: 1.3-2).

Most commonly used porous coated femoral stems are available with and without HA and the surgeon's preference dictate which implant is used. In this thesis all operations was performed with HA-coated implants.

Thus, modern uncemented THA appears to have come to terms with the problem of fixation whereas stress-shielding (one of the subjects of this thesis), wear and osteolysis still remain areas of attention. ☉

3.3 INTRODUCTION OF NEW IMPLANTS

The history of THA is, like many aspects of medical development, paved with both triumphant successes and spectacular failures. Traditionally, new implants are evaluated by their inventors in single-surgeon series before they are made available to the general orthopaedic surgeons and ultimately patients.

In most, but not all cases, this is preceded by pre-clinical laboratory and animal models trials. However, pre-clinical testing has a poor predictive ability to foresee clinical situations and the complex biology of man.

This has lead to unforeseen consequences where new, theoretically ingenious concepts, or small “improvements” to already existing successful designs, have lead to catastrophic failures. The previously mentioned early generations of short and isoelastic femoral stems^{141,294} and introduction of the matte surface Exeter stem²⁰⁷ are two, of many, examples.

When introducing new drugs there is an extensive safety and regulatory program that companies have to adhere to. For new orthopaedic implants however, this is only rudimentary in Sweden and in most other countries. One exception is the USA Food and Drug Administration (FDA) who approves (new designs) or clears (altered designs) implants after thorough documentation from the manufacturers.

However, this is still not a guarantee for clinical success. In august 2010, the FDA-approved ASR hip resurfacing prosthesis was recalled by the manufacturer due to a 5-year revision rate of 13% in upcoming reports from the National Joint Registry of England and Wales (Figure 16).⁶⁹

A stepwise clinical introduction of new implants and methods has therefore been advocated.¹⁸⁹⁻¹⁹⁰ This involves pre-clinical testing, small prospective trials using high precision methods like RSA²⁶⁴ to assess implant fixation and wear, larger multicenter trials and finally population-based register studies.

In *Study IV*, two methods, validated for fixation of implants and bone remodelling, RSA and DXA are used to evaluate a new femoral implant. ◉



FIGURE 16. A advertisement in 2007 for “the next big thing”, an ASR hip resurfacing THA. The implant was recalled by the manufacturer in August 2010.

3.4 BONE REMODELLING

Remodelling of bone is the process by which the adult skeleton is continually being resorbed (osteoclasts) and formed (osteoblasts) in small cavities on the surfaces of cancellous bone and tunnels (Haversian systems) in cortical bone.

In a state of equilibrium, as in healthy young adults with stable bone mass, the bone remodelling rate is low and the amount of bone formed is about the same as is being resorbed. The entire skeleton is remodeled every ten years and any given site in trabecular bone is remodeled every 1-2 years.¹⁹⁴

The structure of bone requires close cooperation between osteoblasts and osteoclasts. It relies on a complex system of signaling pathways to achieve normal rates of growth and differentiation.

Osteoblasts (basically modified fibroblasts) are mononuclear cells responsible for bone formation and are derived from osteoprogenitor cells located in the periosteum and the cancellous bone.⁶⁴

Growth factors, in particular bone morphogenetic proteins (BMPs), platelet derived growth factor and transforming growth factor beta induce these precursors to mature into osteoblasts.³ Osteoblasts then begin to express a wide range of genetic markers and surface proteins which eventually lead to the generation of new bone.

Osteoclasts are multinuclear cells responsible for bone resorption and are derived from monocytic cells in the synovium and cancellous bone. The principal regulator of osteoclast proliferation is the RANKL¹ /RANK/osteoprotegerin (OPG) pathway.¹⁷⁵

RANKL is a necessary and commonly occurring surface molecule that is highly expressed by stromal cells and osteoblasts, thus requiring direct contact between these cells and osteoclast precursors. Osteoclast formation also requires macrophage colony stimulating factor (M-CSF) acting on precursors.

RANKLs receptor, RANK, is widely expressed in cortical and cancellous bone located on the cell membrane of osteoclasts and pre-osteoclasts. RANKL–RANK binding stimulates the formation, activity, and survival of osteoclasts, resulting in osteoclast activation and increased bone resorption.⁶¹

The system is balanced by OPG, a naturally occurring soluble non-signaling “decoy receptor” for RANKL. By binding to RANKL and preventing its interaction with RANK, OPG inhibits osteoclast formation, activity, and survival, thereby reducing bone resorption.²⁶⁷ An increase of RANKL in proportion to OPG is associated with the development of postmenopausal osteoporosis and other skeletal disorders,¹⁹⁴ but has never been investigated in adjunction to disuse atrophy of the proximal femur after THA.

¹ Receptor Activator for Nuclear Factor κ B Ligand (RANKL) belongs to the super family of Tumor Necrosis Factors (TNFs).

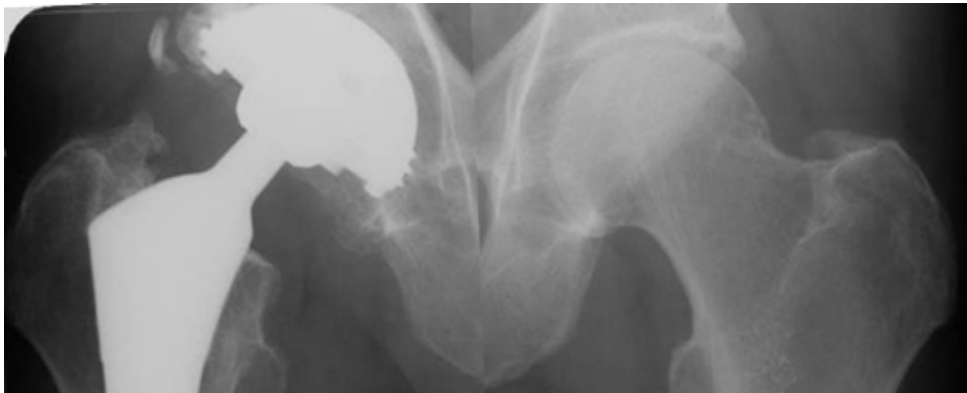

FIGURE 17. Proximal femoral disuse atrophy due to stress-shielding in a 63 year old male 3 years after THA with an uncemented Bi-Metric stem. Note the proximal decrease of cancellous bone in the greater trochanter compared to the unoperated side.

Adaptive bone remodelling

It has long been recognized that placement of a rigid metallic device into bone alters the stress pattern and thereby deprives the bone of the physiological stress levels and cause bone resorption, named disuse atrophy.^{28,86,265}

This “stress-shielding” has been noted after plate fixation of fractures and has led to the development of more flexible plates.²⁴⁰ The primary factor for bone atrophy is the mismatch between the stiffness of the bone and the implant. When two materials are joined, the stiffer of the materials bears the majority of the load, this is especially true when the loading is axial; the stiffer material prevents the more flexible material from deforming and with less deformation there is less load (stress).

In THA, this stress-shielding, with subsequent bone resorption, is a different entity than the wear-induced bone resorption known as osteolysis.^{124,126} The loss of bone induced by stress-shielding is typically seen on radiographs as cortical thinning or a more diffuse decrease in periprosthetic bone density (Figure 17). Osteolysis on the other hand, appears as localized lesions with well-defined borders (Figure 18).

The mismatch in stiffness between a femoral stem and the surrounding femur can be calculated by taking the elastic modulus of the implant

(E) and a geometric factor known as the second moment of inertia (I) that is based on cross-sectional shape and size. The stiffness of the implant is thus $E \cdot I$.²⁵ The moment of inertia varies with the fourth power of the cross-sectional dimension, thus, a small change in implant size causes a large change in the stiffness of the implant.

Thus, increasing stem size and thereby stiffness of femoral implants should lead to higher stress-shielding and thereby larger bone resorption. This has been shown in animal studies,²⁵ in cadaver studies,⁸⁶ in computer models^{103,138} and in clinical series using plain radiographs.⁸⁵

However, there are few studies that specifically study the relationship between stem size and bone loss in vivo and who also utilizes the most precise way of measuring bone mineral content, DXA.^{220,237} Therefore, in *Study I*, the extent of periprosthetic bone loss and its relationship to femoral stem size 3 years after surgery with the uncemented Bi-Metric stem is investigated in a large cohort of patients.

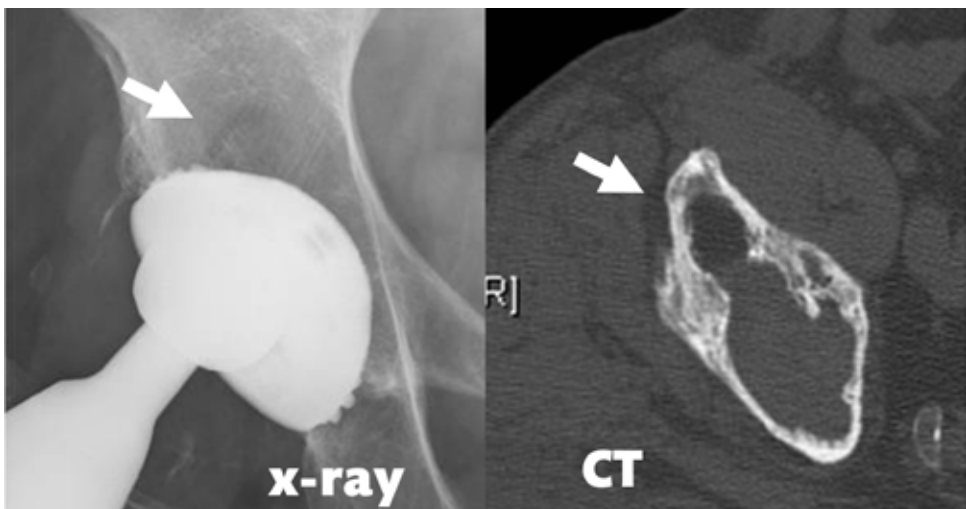


FIGURE 18. Wear induced pelvic osteolysis (arrows). The same patient examined with both x-ray and computed tomography (CT). Note the asymmetry of the femoral head in relation to the cup, indicating severe polyethylene wear.

Bisphosphonates

Bisphosphonates are powerful inhibitors of bone resorption that exert their effect on already matured osteoclasts.²² Treatment with bisphosphonates decreases biochemical markers of bone turnover¹⁶ and increases bone mineral density (BMD).

In osteoporotic patients, these changes are associated with significant reductions in vertebral and nonvertebral fracture risk.^{22,123,203,208} Bisphosphonates are also used in Paget's disease of bone²⁰⁸ and in malignancies.²⁵⁶

Bisphosphonates have been available for more than two decades and currently 7 bisphosphonates — alendronate, clodronate, etidronate, ibandronate, pamidronate, risedronate (Figure 19) and zoledronic acid — are approved in Sweden.¹⁸⁴ The biological characteristics of bisphosphonates were first described more than 40 years ago.¹⁰¹⁻¹⁰²

They were originally used in industry, where inorganic pyrophosphate had been used for many years to inhibit the accumulation of calcium carbonate in water pipes and in the oil industry. Pyrophosphate was found to inhibit calcification in vivo but failed to act when given orally due to rapid hydrolysis. It is still used in scintigraphy and as an anti tartar agent in toothpaste.¹⁰⁰

By modifying pyrophosphate, a number of bisphosphonates, each with its own characteristic profile, have been synthesized and investigated. They vary in their potency to inhibit bone resorp-

tion in vitro and in vivo. Bisphosphonates have a strong affinity to bone mineral – HA – and when osteoclasts try to engulf the bisphosphonate-containing bone they undergo apoptosis (Figure 20).

Once osteoclasts become apoptotic, they are quickly ingested by bone marrow phagocytes.²⁵² Interestingly, the actual effect of bisphosphonates on their target cells remains enigmatic, since in patients benefiting from therapy, little change, has been observed in the actual number of osteoclasts.³⁰³

BISPHOSPHONATES AND ORTHOPAEDIC IMPLANTS

The possibility to reduce periprosthetic bone resorption with bisphosphonates after THA has been addressed by several researchers and effects on periprosthetic BMD and migration have been noted in the short and mid-term perspective.^{11-12,133,219,304,306-307,317-318,320}

In animal models, bisphosphonates can cause augmentation of osseointegration and bone ingrowth of orthopaedic implants,^{236,285} increase pull-out strength of screws²⁶⁸ and even reduce wear-induced osteolysis.^{266,310}

Bisphosphonates have also been shown to reduce the migration of uncemented acetabular components in THA and cemented tibial components in total knee arthroplasty (TKA).^{104,134} These are important findings since the continuous migration of implants is associated with an increased risk for future revision.^{160,165}

Hilding et al. used RSA to show that intravenous administration of clodronate in humans reduced the migration of the cemented tibial component in TKA.¹³⁴ The same research group later demonstrated a similar effect of a local elution of ibandronate applied to the freshly cut bone surfaces, but failed to show any effect on migration in uncemented components with the use of oral alendronate.¹²²

In *Study III* of this thesis, the effect of risedronate on periprosthetic BMD, stem migration and clinical outcome after THA is studied. ◉

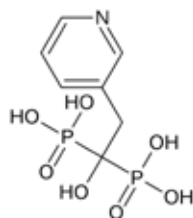


FIGURE 19. Chemical structure of the bisphosphonate risedronate used in *Study III*: [1-Hydroxy-2-(3-pyridinyl)-ethylidene] bis-phosphonate.

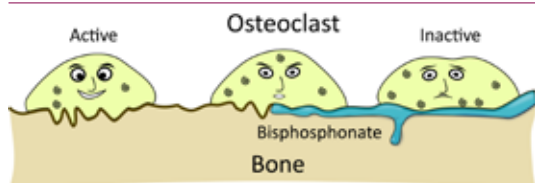


FIGURE 20. Present hypothesis for mechanism of action of bisphosphonates. The osteoclast is inhibited directly after having taken up bisphosphonate from bone. Illustration by Max Gordon.

3.5 STEM REVISION AFTER FAILED HIP ARTHROPLASTY

The most frequent reasons for revision surgery after THA are, in order of frequency, aseptic loosening of the components, dislocation, deep infections, and fractures.^{109,129} In addition, the results with regard to revision rate and clinical outcome are less favorable after secondary surgery than after primary surgery.^{79,312}

Cemented stem revision

Early reports of cemented revision for prosthetic loosening after cemented THA have shown an unacceptably high failure rate with a 15–20% re-revision rate at 10 years of follow-up.^{73,80,131}

One cause of the high incidence of mechanical failure after cemented revision may be the lack of endosteal cancellous bone in the femur. However, when applying meticulous techniques with cement extraction, femoral canal preparation and third-generation cementing techniques, it is possible to achieve good outcome after cemented revisions using tapered polished stems.¹³⁶

Hip revision with cement and impacted morselized allograft bone has shown acceptable long-term results in specialized centres.^{225,248,297} This technique has obvious advantages in bone stock restitution (Figure 21). However, impaction bone grafting surgery is technically demanding and time consuming. There are well known complications associated with this technique, such as major subsidence and per- and post-operative fractures.²²⁴

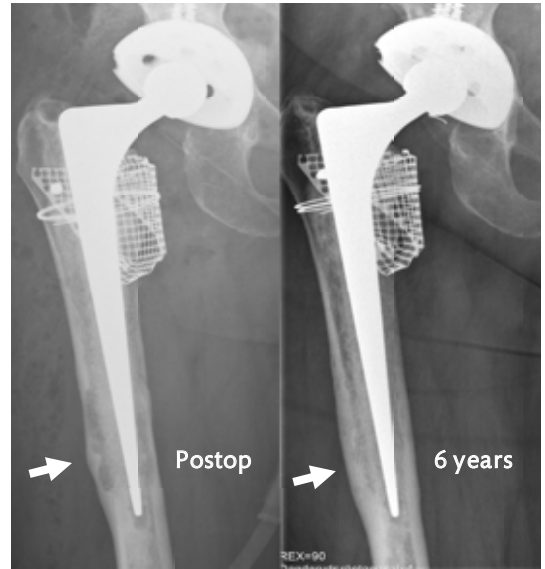


FIGURE 21. Femoral stem revision with impaction bone grafting using morselized allograft and a cemented collarless, polished, tapered stem. Note restitution of bone defect at 6 years compared to immediate postop radiograph (white arrows).

Uncemented stem revision

Uncemented stem revision after aseptic loosening has shown itself to be promising in the short to medium term^{34,212,296} and also in the long term.^{228,247,249,298}

The aim of using these components is to achieve biological fixation, i.e. ingrowth of endosteal bone by new bone formation within the porous surface structure of the implant.⁸⁶ In a revision situation, proximal bone stock in the femur is often compromised and to achieve early post-operative stability, most uncemented stems are designed to bypass the proximally damaged zone and to achieve initial stability from press-fit distally.

Most stems used in these studies are long-stemmed, extensively porous or HA-coated, or distally anchored (Figure 22). A disadvantage with these stems is the transfer of excessive load distally, leading to diminished proximal bone stock and in some cases to a high incidence of thigh pain. Despite this, there are good long-term results reported with the use of distally anchored stems.³⁴

Extensively coated uncemented stems in femoral revision surgery get fixated both proximally and distally and are used with good results.^{62,169,228} However, these devices are prone to stress-shielding and therefore stems with only proximal coating, such as the Bi-Metric stem, have also been used (Figure 23).

The aim of using any of these implants is to enhance the proximal fixation in order to prevent further bone loss proximally and to minimize the load transfer distally. Earlier studies with stems aimed at proximal fixation have not shown entirely promising results,¹⁹ later reports show better outcome with survival rate in the mid- and long term of 95-100%.^{83,149}

In *Study II*, clinical and radiographic results after stem revision surgery with a tapered, proximally porous and HA-coated stem are presented. ◉

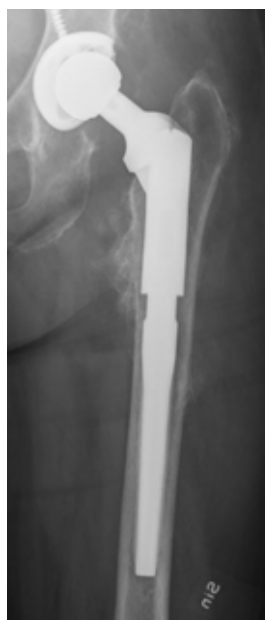

FIGURE 22. Femoral stem revision using a uncemented distally anchored stem.

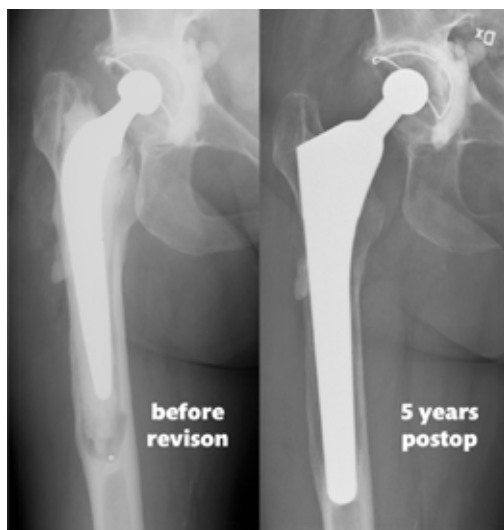


FIGURE 23. Stem revision using the Bi-metric stem.

3.6 HIP ARTHROPLASTY AND FEMORAL NECK FRACTURES

In an international perspective, osteoporotic fractures represent a significant public health burden, which is likely to increase in the future. The lifetime risk is high; up to 50% in women and 22% in men. Since life expectancy, and thereby osteoporosis, is increasing, these demographic changes alone can be expected to increase the number of hip fractures occurring worldwide from 1.7 million in 1990 to 6.3 million in 2050.⁶⁸

Hip fractures are classified as femoral neck fractures (FNFs) (51%), trochanteric fractures (41%) and subtrochanteric fractures (8%).⁸¹ FNFs are usually (65-75%) displaced (Garden III and IV¹⁰⁸), (Figure 24), and these differ from the other hip fractures with regards to its high incidence of healing complications.²⁹²

The majority of displaced FNFs in elderly patients were, until recently, treated with internal fixation (IF) in Sweden. However, there is now solid evidence to support recommending a primary hip arthroplasty instead of IF for a displaced FNF in elderly patients who are independent walkers and have no severe cognitive impairment.^{14,112,218,253,293} This leads to a higher quality of life, hip function and a significant reduction of reoperations compared to IF without increasing mortality.

In most Swedish hospitals, the standard of care has thus changed to primary arthroplasty instead of IF for this patient group (Figure 25).²⁵⁴

Cemented or uncemented stems

Earlier studies have supported the use of cemented stems in hip fracture patients, mainly due to decreased post-operative pain during rehabilitation.^{151,181,230} However, the concept of inserting an uncemented stem, even in elderly patients, is attractive to many surgeons¹⁴⁸ as bone cement has several major, albeit uncommon, negative side-effects. These are mainly cardiac arrhythmias and cardio-respiratory collapse which can occur during the cementing process.²³²

The mechanisms involved are not fully understood but the side-effects are most likely caused by pulmonary embolization of bone marrow and PMMA particles.^{57,243} The mortality rate in this frail patient group may therefore be higher after cemented rather than uncemented arthroplasty.^{173,231} The potential advantages of an un-

cemented femoral stem are also related to the shorter duration of surgery (thereby possibly minimizing intra-operative bleeding and decreasing the risk of infection).²³⁰ The disadvantages include an increased risk for periprosthetic fractures with subsequent increased revision rates,¹⁰⁹ thigh pain and stress-shielding of the proximal femur.

A new uncemented femoral stem, based on the Bi-Metric stem,^{32,206} with full HA-coating to enable fast ingrowth in osteoporotic bone,²⁸¹ and a collar to avoid excessive subsidence, has been developed specifically for FNFs and is evaluated in *Study IV* of this thesis. ◉

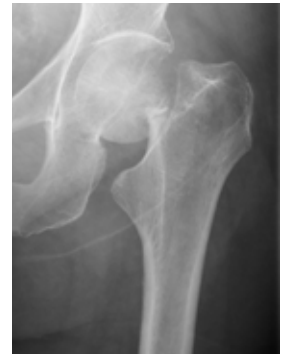

FIGURE 24. Displaced femoral neck fracture in a 82-year old woman from Study IV.

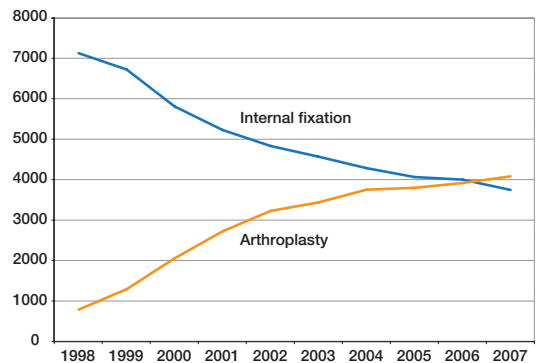


FIGURE 25. Yearly number of procedures used for femoral neck fractures over time in Sweden. Reprinted from Rogmark et al.²⁵⁴ with permission.

3.7 UNCEMENTED HIP ARTHROPLASTY AT DANDERYD HOSPITAL

Primary THA with uncemented femoral stems has been performed at the Orthopaedic Department, Danderyd Hospital, Stockholm since 1985. From 1989, the same stem, Bi-Metric (Biomet, Warsaw, Indiana, U.S.A.) has been routinely used in THA surgery.

Up until July 2009, 1.718 stems in 1.420 patients have been implanted as primary THA, and data on these has been collected in a clinical audit database. In the first 8 cases, the stem was proximally porous coated and Ti-6Al-4V heads were used. After these initial cases, stems with plasma-sprayed HA-coating on the porous coating and a CoCrMb head were used.

On the acetabular side, an uncemented cup with inferior results was initially used in most cases.²⁷⁰ Nowadays, we use an uncemented press-fit shell with a XLPE liner or a cemented XLPE cup.

Patients

The selection criteria for uncemented fixation in the femur were initially patients below 60 years of age, a good general health and good bone quality equivalent to a type A or B femur.⁷⁴ Over the years, the indication has broadened and since

2007 the uncemented stem is our standard implant for elective THA (Figure 26).

No formal age limit now exists, but most surgeons use a cemented stem for patients over 75 years of age, for patients with a C-type femur (regardless of age), and in patients with FNFs.

TABLE 1. Anthropometrical data on patients operated with the uncemented Bi-Metric and the cemented CPT stem at Danderyd Hospital

	Bi-Metric	CPT
Sex^a		
Male	695 (41)	582 (31)
Female	1023 (59)	1309 (69)
Age^b	61 (20-92)	76 (35-98)
Diagnosis^a		
OA	1405 (82)	1575 (83)
FNF	120 (7)	223 (12)
RA	77 (4)	19 (1)
Other	116 (7)	74 (4)

^a n (%), ^b mean (range)

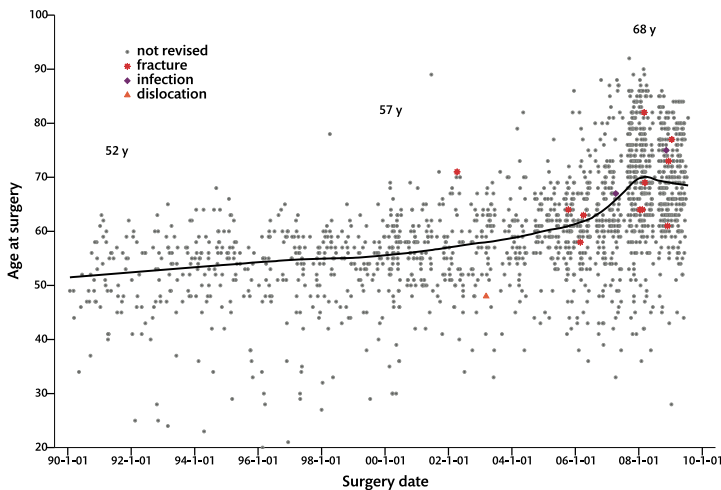


FIGURE 26. Scatter plot of all 1.718 primary THA using the Bi-Metric stem 1989-2009 at Danderyd Hospital as a function of age at surgery. Hips revised and reasons for revision are marked as well as the yearly mean age at surgery (solid line).

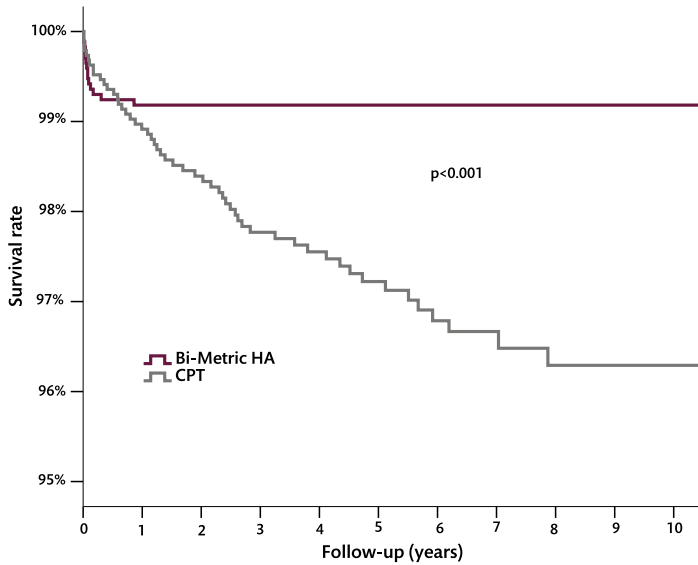


FIGURE 27. Survival curves with all reasons for stem revision as end point

Stem survival

Until September 2010, with a follow-up time of mean 7 (1-21) years, 14 stem revisions have been performed [due to fracture (n=11), infection (n=1) and dislocation (n=2)] indicating a survival rate of 99.2% (95%CI 98.7%-99.6%) with all reasons for revision as end point.^{32,270} We have no cases of aseptic loosening. Median time to revision was 28 (7-476) days and the majority of fractures were calcar-split fractures with little or no preceding trauma.

When comparing these revisions with a cohort of all primary THAs performed at Danderyd Hospital with a tapered, polished, cemented stem during 1999-2009 [CPT (Zimmer, Warsaw, Indiana, U.S.A.)], there is a significant difference in revision rate. The revision rate, with all reasons for revision as end point, and with a follow-up time of mean 6 (1-12) years for the cemented stem is 96.3% (95%CI 95.2%-97.4%), (Figure 27). The 53 revisions were performed due to fracture (n=25), dislocation (n=14), infection (n=9) and aseptic loosening (n=5). The majority of the fractures in the CPT-group were periprosthetic fractures after low energy trauma (time to fracture median (range) 22 (1-90) months)

The demographics of the patients differ, with more males, younger patients and a lower rate

of THAs performed as a result of a FNF in the uncemented group (Table 1). When adjusting for these inequalities with a Cox regression (Table 2), a diagnosis of FNF [odds ratio (OR) 1.9 (1.0-3.7)] and a cemented stem [OR 2.8 (1.2-1.9)] were found to be independent risk factors for revision, whereas age or sex were not. For revisions due to fracture, a diagnosis of FNF [OR 2.9 (1.3-6.5)] was found to be an independent risk factor, whereas sex, age or stem type were not.

TABLE 2. Multivariate Cox regression to evaluate factors associated with risk of stem revision

Explanatory	n	revisions (n)	revision rate (%)	OR (95% CI)	p-value
Sex					
Male	1277	18	1.4	1	
Female	2332	49	2.1	1.3 (0.8-2.3)	0.2
Age					
≤65	1384	13	0.9	1	
>65	2225	54	2.4	1.6 (0.8-3.3)	0.2
Indication					
OA	2980	52	1.7	1	
FNF	343	11	3.2	1.9 (1.0-3.7)	0.05
RA	96	0	0.0	0 (0.0-0.0)	1.0
Other	190	4	2.1	1.7 (0.6-4.7)	0.3
Stem type					
Uncemented	1718	14	0.8	1	
Cemented	1891	53	2.8	2.4 (1.2-4.9)	0.02

Conclusion

These excellent mid- to long term results of an uncemented Ti-6Al-4V, tapered, proximally porous and HA-coated femoral stem demonstrate two things. Firstly, when using these implants there is an increased risk for early fractures, most of them occurring during surgery, though they are not always detected. Secondly, once a modern stem osseointegrates it is seldom revised.

However, we have, particularly in patients with a pre-operatively poor bone stock, seen radiographic signs of severe stress-shielding (Figure 28) and in some cases this has lead to periprosthetic fractures after minimal trauma (Figure 29).

We have not seen an impact on revision rates, but our main concerns are that this bone remodeling, in the long term, may lead to an increased rate of periprosthetic fractures. Many of our patients are young and can be expected to have a life expectancy of over 30 years.

Our research group at the Joint Replacement Unit at Danderyd Hospital has, prior to this thesis, published several papers and one thesis on outcome and bone remodelling after uncemented THA. ^{2,29-30,32-33,269-270}

The general aims of this thesis are to further describe this phenomenon in primary and secondary surgery and to attempt to treat this periprosthetic bone atrophy using a drug. Based on our results in degenerative joint disease, we were also looking to extend the indication for uncemented femoral stems to patients with FNFs. ◉

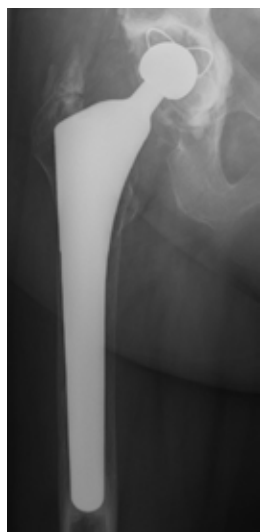


FIGURE 28. Severe stress-shielding 10 years after revision surgery. Note thin cortex proximally. Distally pedestal sign and cortical hypertrophy as a sign of distal fixation.

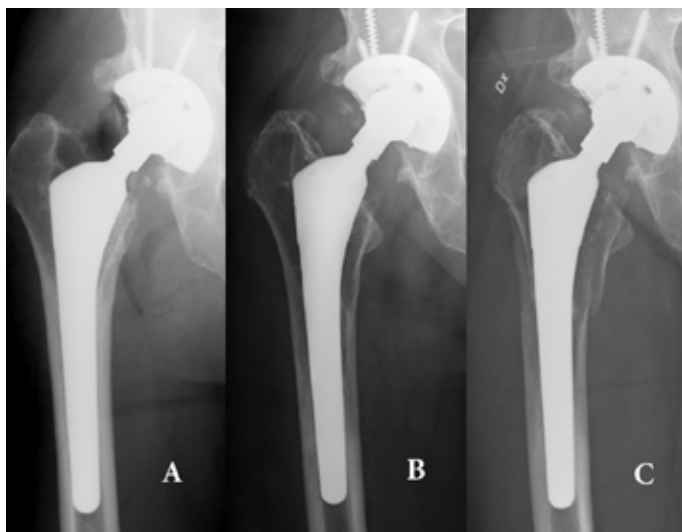


FIGURE 29. Disuse atrophy due to stress-shielding. Postoperatively (A). At 4 years (B) there are clear signs of stress-shielding (atrophy in Gruen zone 1, 2, 6 and 7). After 5 years the patient sustained a periprosthetic fracture after minimal trauma (C). The patient was successfully treated with open reduction and internal fixation. The stem was not revised.

4 AIMS

The general aims of the studies were to investigate the bone remodelling around and migration of uncemented femoral stems after primary and secondary THA. The specific aims of these investigations were:

- I** To study the relationship between periprosthetic bone loss and femoral stem size after THA for degenerative joint disease when using a tapered uncemented proximally porous- and HA- coated femoral stem.
- II** To study the clinical outcome and radiological results of hip revision surgery for aseptic stem loosening when using a tapered uncemented proximally porous- and HA- coated femoral stem.
- III** To study the effect of oral risedronate on femoral periprosthetic bone resorption after total hip arthroplasty in patients with OA of the hip when using a tapered uncemented proximally porous- and HA- coated femoral stem.
- IV** To evaluate the fixation of, bone remodelling around, and clinical outcome after surgery of a new, uncemented, fully HA-coated, collared and tapered femoral stem, designed specifically for elderly patients with a FNF. ◉

5 HYPOTHESES

- I** Periprosthetic bone loss is related to stem size; larger stems will increase the bone loss after THA.
- II** Femoral hip revision surgery using an uncemented technique with a proximally coated stem is a reliable procedure with predictable mid-term results if bone defects prior to surgery are moderate.
- III** Risedronate, 35 mg given post-operatively once weekly for 6 months, will, up to 2 years, reduce the periprosthetic bone resorption around an uncemented stem.
- IV** An uncemented, fully hydroxyapatite-coated femoral stem can be used to treat FNFs. ◉

6 END POINTS

- I** The primary end point was periprosthetic bone loss in the Gruen¹¹⁸ zones 1 - 7 and its relationship to femoral stem size. Secondary end points included hip function assessed using the Harris hip score¹²⁷ (HHS) and the number of complications after surgery.
- II** The end points were clinical outcome and radiographic signs of bone remodelling. This was measured by gathering data on complications and revision surgery, hip function (HHS) and by assessing pre- and post-operative radiographs with regards to the Stability/Fixation score.
- III** The primary end point was change in BMD in the Gruen¹¹⁸ zones 1 and 7 around the femoral stem in subjects receiving risedronate compared to those receiving placebo during a 2-year period with measurements at 2 days, 3, 6, 12 and 24 months. Secondary end points included change in BMD in the other Gruen zones, vertical migration of the stem, radiological results, clinical outcome and the occurrence of adverse events.
- IV** The primary end point was migration of the stem measured with RSA during a 2-year period with measurements at 2 days, 6 weeks, 3, 6, 12 and 24 months. Secondary end points included change in BMD in the Gruen zones¹¹⁸ around the stem and clinical outcome. ◉

7 PATIENTS

All 1.757 uncemented THA operations done between 1989-2008 as either a primary (n=1.608) or secondary (n=149) intervention at the Orthopaedic Department at Danderyd Hospital constituted the study base for Studies I-III. For Study IV, the study base was recruited from 750 patients with hip fractures admitted to Danderyd Hospital between 2005-2008 (Figure 30).

From these, between 2003-2008, a study population of 617 hips (615 patients) was eligible for inclusion in one of the studies. After inclusion, Studies I-IV contained a sample of 314 hips in 312 patients (Table 3).

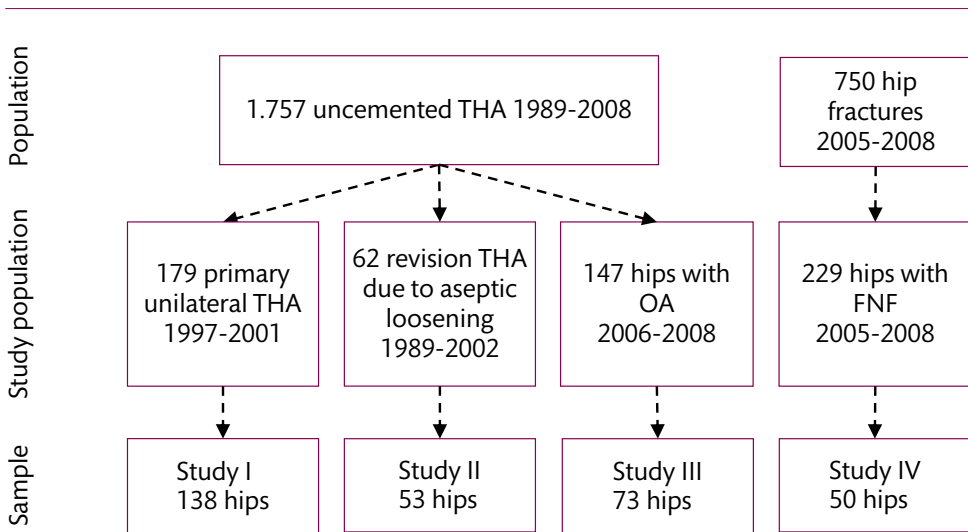


FIGURE 30. Sample selection for study I-IV

Study	Study I	Study II ^a	Study III		Study IV
			risedronate (n=36)	placebo (n=37)	
Male/female ^c	66/72	37/23	14/22	16/21	36/14
Age ^b	58 (37-91)	65 (35-84)	61 (41-69)	60 (41-69)	81 (70-92)
Height ^b	171 (146-198)	174 (159-191)	171 (160-187)	174 (156-192)	168 (9)
Weight ^b	81 (47-120)	81 (51-28)	79 (59-104)	86 (55-130)	66(14)
Diagnosis ^c	OA 123 CDH 5 Other 10	OA 44 CDH 4 Other 14	OA 36	OA 37	FNF 50

^a for the original 60 patients (62 hips), ^b mean (range), ^c n, at primary surgery

Study I

We identified a consecutive series of 179 primary unilateral THAs performed with the uncemented Bi-Metric femoral implant at Danderyd Hospital from 1997 to 2001. A total of 31 patients were excluded from the study [rheumatoid arthritis (15), per-operative or post-operative fractures of the femur (7), corticosteroid treatment as a result of systemic illness (6), congenital hip dysplasia with abnormal anatomy of the proximal femur (2), and per-operative damage to the sciatic nerve (1)]. Ten other patients were lost to follow-up (4 died, 2 refused to participate and 4 could not be contacted). A total of 138 patients were thus included in the study and followed up at a mean of 3 (2-7) years after surgery.

Study II

In study II, all patients who had undergone revision of THA at Danderyd Hospital with the Bi-Metric stem between 1989 — 2002 due to aseptic loosening were eligible for inclusion in the study. 62 hips in 60 patients were identified. At follow-up, 9 of the 60 patients had died. 1 of these had been re-revised 3 months after the uncemented stem revision due to a fracture adjacent to a per-operative fenestration. The other 8 patients still had their stem in place. Thus, 51 patients (53 hips) were followed up at a mean of 6 (2-13) years.

Study III

All 147 patients planned for primary THA during 2006-2008 were screened for participation in the study. Patients aged 40-70 years, with primary OA of the hip, and a type A or B femur according to Dorr et al.⁷⁴ were eligible for inclusion in the study.

Patients were excluded if they had a condition that could affect BMD. Patients with a hypersensitivity to risedronate, who had hypocalcaemia, or who, for any reason, were unsuitable to take part of a randomized controlled trial, or patients who sustained a periprosthetic fracture during surgery, were also excluded.

We enrolled 73 patients, 36 in the risedronate group and 37 in the placebo group (Figure 31). All patients received at least 1 dose of study medication and completed the 24 month follow-up.

Study IV

All 229 patients who were admitted to our emergency department with an acute (<24h before admission) FNF during the inclusion period between October 2005 and April 2008 were screened for participation in the study. The inclusion criteria were a displaced fracture (Garden III or IV)¹⁰⁸, an age of at least 70 years, intact cognitive function [at least 8 correct answers on a 10-item (SPMSQ) mental test],²³⁸ the ability to walk independently with or without the help of walking aids and a willingness to participate in the study.

Patients with a previous fracture in the same hip, a pathological fracture, those deemed not suitable for THA by the anaesthesiologist or those who for any other reason were considered unsuitable to participate in the study, were excluded. A research nurse gave the patients oral and written information about the study, and 50 patients who agreed to take part in the study gave their written informed consent.

Ethics

All studies were conducted in conformity with the principles of the Helsinki declaration and were approved by The Ethics Committee of the Karolinska Institute and the Committee for Protection Against Radiation at Danderyd hospital. Approval for *Study III* was also granted from The Swedish Medical Products Agency.

The studies were initiated, designed and performed as academic investigations. In *Study III*, the pharmaceutical company Sanofi-Aventis/Warner Chilcott Pharmaceuticals Inc. funded in part the risedronate and placebo used. In *Study IV*, Biomet (Biomet Orthopaedics AB, Sjöbo, Sweden) marked the implants. Beyond this, neither company had any further input or participation in the studies. ◉

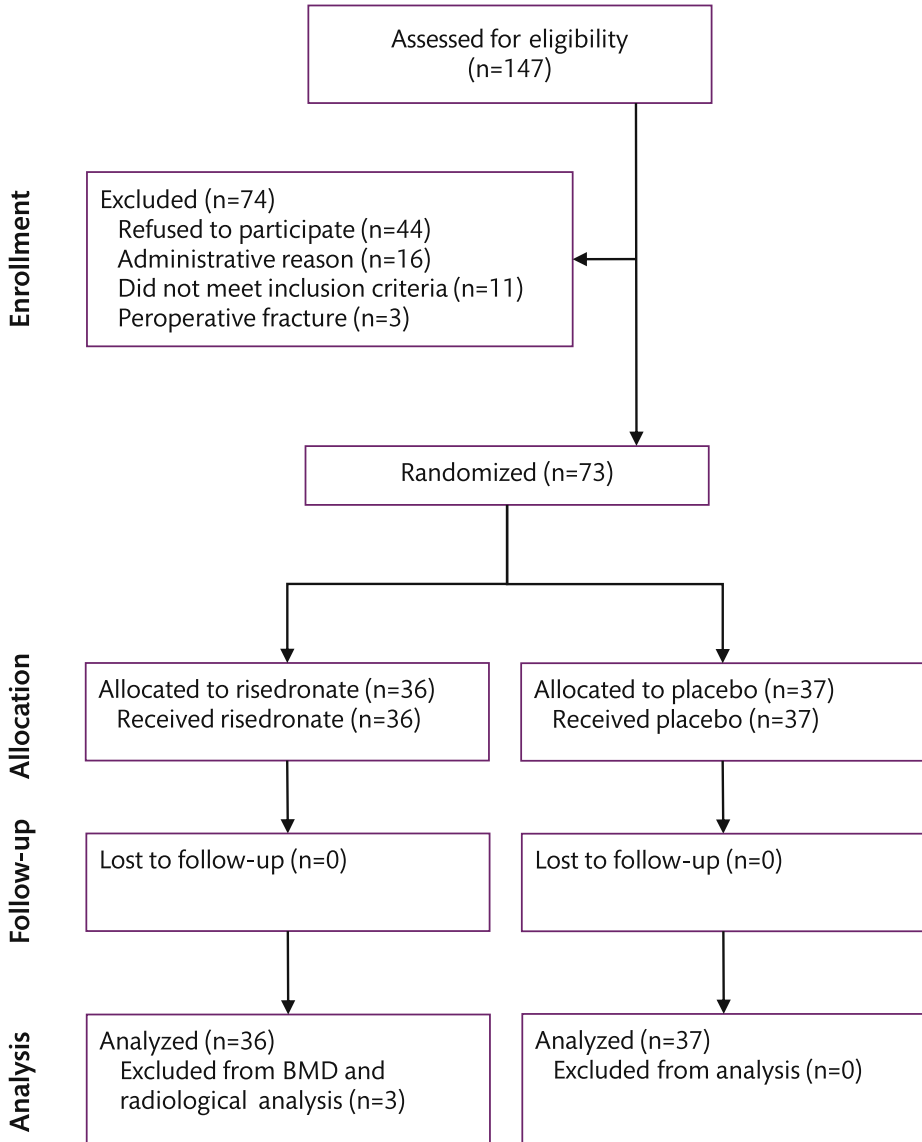


FIGURE 31. CONSORT diagram Study III

Flow of patients in accordance with CONSORT (Consolidated Standards of Reporting Trials). Three subjects in the risedronate group were excluded from the BMD and radiological analysis of end points [stem revision 6 days postoperatively due to dislocation (n=1), unwillingness to complete protocol due to nausea (n=2)]. All patients completed the end points for clinical outcome.

8 MATERIALS

The Bi-Metric stem

In *Study I-III*, all patients received the uncemented, tapered, collarless Bi-Metric stem (Biomet Inc., Warsaw, Indiana, U.S.A.) (Figure 32). It is made of Ti-6Al-4V, where the proximal one-quarter has a circumferential, plasma-sprayed, Ti-6Al-4V porous coating with a mean pore size of 300 μm .

The distal part has a grit-blasted surface with a roughness of 6.9 μm . The porous part has a plasma-sprayed HA layer of 40–70 μm thickness, crystallinity of 50–70%, and a purity of >95%. The stem has a straight 3° proximal-to-distal taper in 2 planes and a taper from the lateral shoulder to the medial calcar area.

The stem is available in 13 proportional sizes from 7 to 19 mm, with corresponding lengths of 115 to 175 mm and has both standard and lateralized offset options.

In *Study I-II*, there was initially (1989-1999) only a standard offset stem available. For articulation, a 28-mm modular CoCrMb head of varying lengths of neck extension was used in all cases in *Study I* and *III*. In *Study II* the diameter of the head varied between 22 and 32 mm.



FIGURE 32. Bi-Metric stem.
photo by Carin Wesström.

The BFX stem

In *Study IV*, all patients received the Biomet Fracture Stem, BFX® (Figure 33), (Biomet UK Ltd, Bridgend, U.K.). It is a tapered, collared, stem intended for uncemented fixation in the femur. It is made of Ti-6Al-4V with a grit-blasted surface roughness of 7.5-10 µm.

The geometry of the stem, except for the collar, is identical to the Bi-Metric® stem, but it has no proximal porous coating. The stem has plasma-sprayed HA on the entire surface (thickness 65-95 µm, crystallinity 50-70%, purity >95%) to enable fast ingrowth in osteoporotic bone.⁵⁹

The stem is available in 6 sizes (7-17 mm, uneven sizes only), and has a standard offset with a neck/shaft angle of 140°. For articulation, a 32-mm modular CoCrMb head of varying lengths of neck extension was used in all cases.

Acetabular Components

In *Study I-III*, both uncemented and cemented cups were used according to the surgeons' preference and in *Study IV* only cemented cups were used (Table 4).

In *Study I-II*, standard polyethylene, and in *Study III-IV*, XLPE (Longevity®) was used.

In *Study I* and *II*, two types of uncemented acetabular components were used. The first (Romanus®, Biomet UK Ltd, Bridgend, U.K.), used 1989-1999, is a partially threaded acetabular Ti-6Al-4V shell with plasma-sprayed Ti-6Al-4V porous coating covered with HA, combined with a polyethylene liner. The second (Trilogy®, Zimmer, Warsaw, Indiana, U.S.A), is a Ti-6Al-4V hemispherical press-fit shell with sintered Ti-6Al-4V porous coating covered with HA, combined with a polyethylene liner. Both acetabular components have a ring locking mechanism to secure the liner to the shell. Ⓞ



FIGURE 33. Biomet Fracture Stem (BFX®).

The implant has been modified for RSA with tantalum marker beads at the shoulder, collar and tip of the prosthesis. Photo by Carin Wesström.

TABLE 4. Acetabular components used in Study I-IV

Type	Study I	Study II	Study III		Study III
			risedronate	placebo	
Uncemented	74	18	9	11	0
Cemented	64	35	27	26	50

9 METHODS

Orthopaedic researchers use a number of objective and subjective instruments to measure the outcome after THA. Radiological outcome includes evaluation of the fixation and stability of the implant from plain radiographs,⁹¹ RSA of implant migration²⁶⁴ and DXA to assess the amount of bone remodelling. Clinical outcome involves patient satisfaction, measured by hip specific¹²⁷ and generic outcome scores,²⁴⁵ as well as complication rates after surgery.

On a national level, hip arthroplasty registers provide not only valuable epidemiological information but also patient, hospital and implant related risk factors for revision.^{109,117,129}

Study protocol and follow-up

Study I and II were both retrospective, cross-sectional studies with patients attending a single follow-up visit. In both these studies, prospectively collected data from hospital charts and

radiographs were available for analysis in all patients. Study III and IV were both prospective studies with data collected at regular follow-up visits up to 2 years after inclusion. The study protocol and follow-up visits are shown in Figure 34. ◉

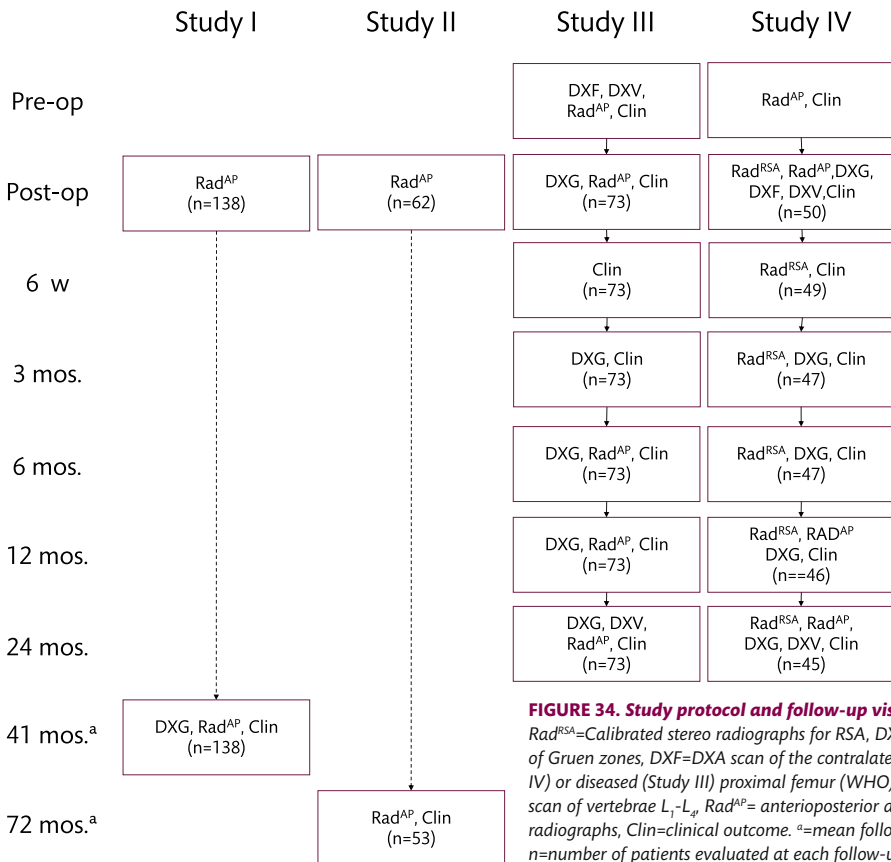


FIGURE 34. Study protocol and follow-up visits
 Rad^{RSA}=Calibrated stereo radiographs for RSA, DXG=DXA scan of Gruen zones, DXF=DXA scan of the contralateral (Study IV) or diseased (Study III) proximal femur (WHO), DXV=DXA scan of vertebrae L₁-L₄, Rad^{AP}= anteroposterior and lateral radiographs, Clin=clinical outcome. ^a=mean follow-up time. n=number of patients evaluated at each follow-up visit.

9.1 SURGERY

Surgical technique

Pre-operative planning was performed with templates on plain radiographs in *Study I-II* and with a digital templating software (mDesk®, RSA Biomedical, Umeå, Sweden) in *Study III-IV*.

In *Study IV*, all operations were done within the first 48 hours after admission and in *Study I-III* all were performed as planned procedures. The surgical technique and instrumentation used were identical for both stems.

A standard posterolateral approach,²¹⁰ with repair of the posterior capsule and external rotator muscles,¹⁶³ was used. In *Study II*, the repair was not routinely done in the first years of the study.

Once the femoral head has been dislocated from the acetabulum, the resection of the femoral neck was done using a template (Figure 35). The femoral canal was then reamed with increasing sizes until cortical bone contact was obtained (Figure 36).

Thereafter, the proximal femur was prepared with broaches of increasing size until rotational stability was achieved (Figure 37). With the final broach in place, the calcar femoris was planed flush using a planing tool and the final implant was inserted (Figure 38).

In *Study IV*, the prosthetic collar thus rests on the calcar femoris when the prosthesis is fully seated and rotationally stable (collar-calcar contact). For some hips, the fracture line was more distal than the ideal collar resection line; in these hips, the collar of the stem did not rest on bone when the stem was rotationally stable (no prosthetic collar-calcar contact).

Before the final implant was inserted, 5 to 9 tantalum marker beads (1.0 mm in diameter) were inserted in the cancellous bone of the proximal femur.

In *Study II* bone grafting around the neck of the stem was carried out in 33 of the 62 original cases.

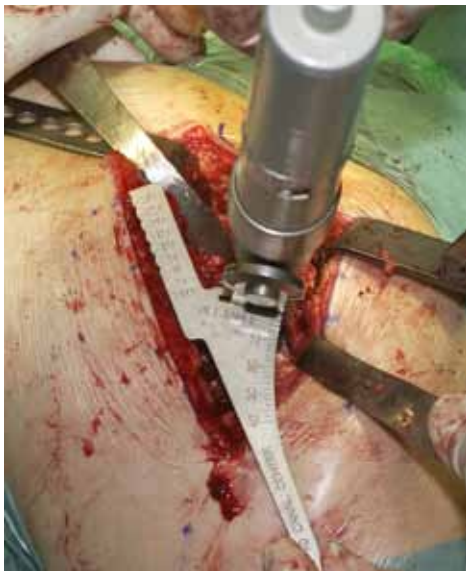

FIGURE 35. Head resection

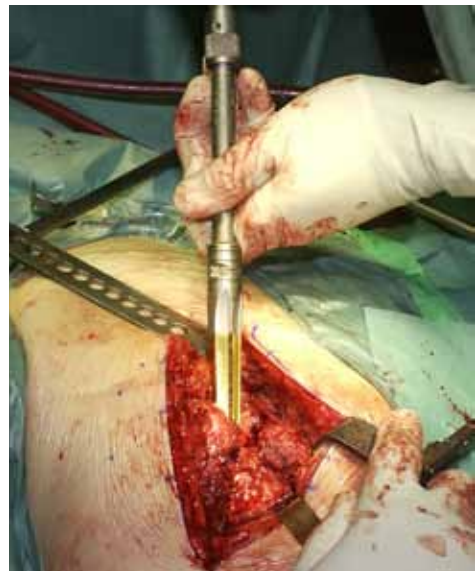

FIGURE 36. Reaming

Per- and post-operative care

After 2001, in *Study I* and *II* and for all patients in *Study III* and *IV*, intravenous tranexamic acid (Cyclokapron®, Pfizer, Sweden) was administered before the start of surgery to reduce bleeding. Prophylactic antibiotics (Cloxacillin®, Meda, Sweden) were given to all patients 30 minutes prior to the start of surgery and in the first 24 hours post-operatively.

To reduce the risk for thromboses, intravenous dextran (Macrodex® Meda, Solna, Sweden) was given during the first 3 days in *Study I-II*. In *Study III-IV*, daltaparin (Fragmin®, AstraZeneca, Sweden) was given 10 days post-operatively to prevent thromboses.

The patients were mobilized using a standard physiotherapy program. In *Study I-II*, no protocol regarding weight bearing or use of crutches was used. In *Study III-IV*, patients were encouraged to weight bear fully using crutches for support.

Risedronate

In *Study III*, the patients were randomized on the second post-operative day to take either a tablet of 35 mg risedronate or placebo once weekly for 6 months.

Patients were instructed to take the tablet on an empty stomach 30 minutes before breakfast and to remain in an upright position for 1 hour after ingestion of the tablet.

All patients received oral supplements of calcium carbonate (1000 mg) and vitamin-D (400 IU) daily for 6 months. The computerized randomization and blinding procedure was carried out by the central pharmacy (Apoteket AB, Stockholm, Sweden), which produced the study drug and the placebo tablets in physically indistinguishable and coded containers.

Patients were block-randomized in groups of 10 using sealed envelopes and the randomization was stratified to ensure that the gender distribution would be the same in both groups. All patients, staff and investigators were blinded as to the treatment assignment during the study.

Two patients in the risedronate group were unblinded due to adverse events.

Compliance ($\geq 80\%$ of study drug taken) was controlled at the 6 week, 3 and 6 monthly follow-up visits. The compliance was 93% in the risedronate and 97% in the placebo group. ◉

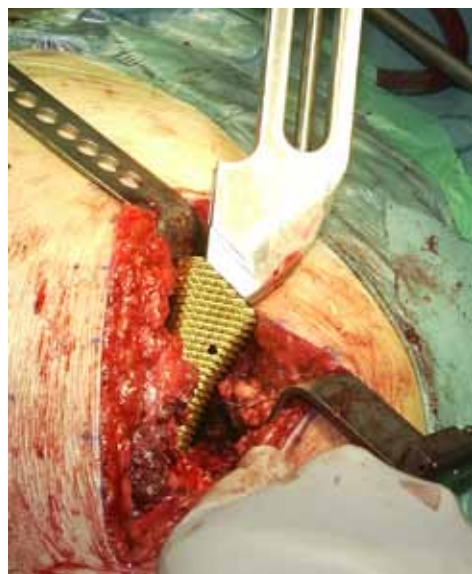

FIGURE 37. Broaching

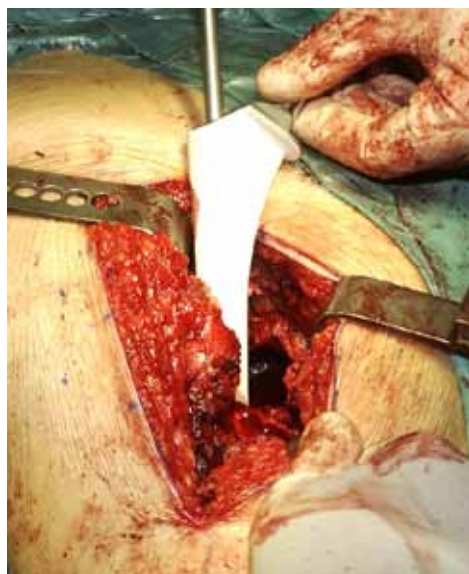


FIGURE 38. Final implant

9.2 RADIOLOGICAL METHODS

Fixation/Stability score

In 1990, Engh and co-workers presented a semi-quantitative radiological assessment of the biological fixation of porous-coated femoral components.⁹¹ They developed a scoring system that is divided into signs of fixation (in the original article synonymous with osseointegration) and stability. The score is used in *Study I-III*.

Signs of fixation are absence/appearance of endosteal bone bridges (spot welds) (Figure 39) and absence/appearance of reactive lines in the coated region of the stem.

Signs of stability include absence/appearance of reactive lines in the uncoated region, pedestal formation (Figure 40), calcar modeling (Figure 39), interface deterioration (widening radiolucent lines), migration of the implant and visible shedding of particles from the porous coating.

Migration was considered definite if the change was more than 4 mm.¹⁹¹

Distal cortical hypertrophy is not part of the original score but is a sign of firm distal fixation (Figure 40). In *Study IV*, in addition to assessing the Stability/Fixation score, the presence of osteolysis and distal cortical hypertrophy were noted.

By assigning points for each sign when present, absent or if undetermined, a scoring system was developed (Table 5) and validated against clinical parameters such as hip pain and walking ability.⁹¹ A score of ≥ 0 indicates a fixated and stable stem, a score < 0 clinically uncertain and < -5 a definitely unstable (loose) stem.

This scoring system is still widely used to describe the radiological outcome after THA with uncemented stems despite the fact that DXA and RSA have emerged as more precise methods of measuring fixation and bone remodelling.

TABLE 5. Fixation/Stability score⁹¹

Sign present	No	Undetermined	Yes
FIXATION SCALE			
spot welds?	-2.5	0	+5.0
reactive lines in $\geq 50\%$ of porous coating	+5.0	0	-2.5
STABILITY SCALE			
reactive lines in $\geq 50\%$ of distal stem	+5.0	0	-3.5
pedestal formation and reactive lines	+2.5	0	-3.5
calcar atrophy	-3.5	0	+4.0
interface deterioration	+2.5	0	-2.5
migration	+3.0	0	-5.0
particle shedding	+1.0	0	-5.0

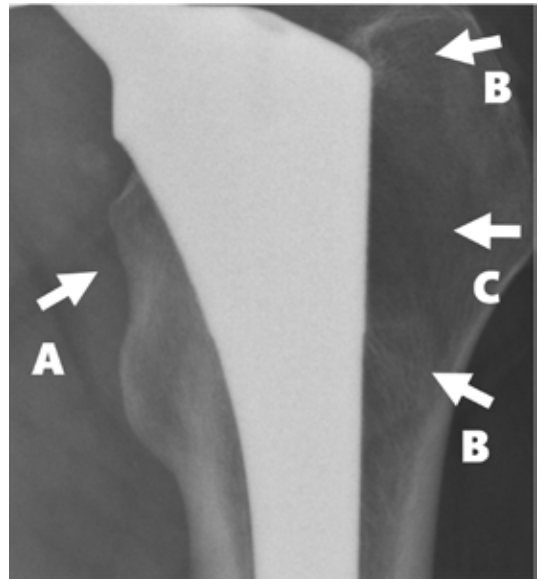


FIGURE 39. The 2-year radiograph of a 41-year old man in the placebo group in Study III. Note calcar atrophy (A), spot welds (B) and proximal cancellous bone atrophy (C).

Other radiological parameters

In all studies, anteroposterior and lateral radiographs were reviewed at follow-up visits. In Study I-II, plain, and in Study III-IV, digital radiographs were used.

RADIOLUCENT LINES

In Study I-III, radiolucent lines between bone and cement (for cemented cups) or bone and porous coating (for uncemented cups) in DeLee and Charnley⁶⁷ zones around the cups were recorded.

HETEROTOPIC OSSIFICATION

In Study II-IV, the presence of heterotopic ossification was evaluated according to Brooker et al.⁴²

POSITION OF IMPLANT

In Study IV, varus/valgus angle and fill¹⁵³ of the stem in the femoral canal were measured on radiographs with the digital templating software.

The proximal fill was measured at the upper border of the lesser trochanter and the distal fill 3 cm proximally of the tip of the prosthesis. Fill was defined as good when there was an 80% fill on the anteroposterior radiograph and 70% fill on the lateral radiograph.¹⁵³

DORR CLASSIFICATION

A simple classification for pre-operative bone quality before primary THA, aimed at estimating the suitability of a uncemented stem, and based on the radiographic appearance of the femur, is the Dorr classification.⁷⁴

Dorr suggested that there are three types of proximal femur, A is the normal taper and thick cortex, C is a clear loss of taper and thin cortex (also called stove pipe femur), and B is in between. In Study III, A and B femur were used as an inclusion criterion in the trial.

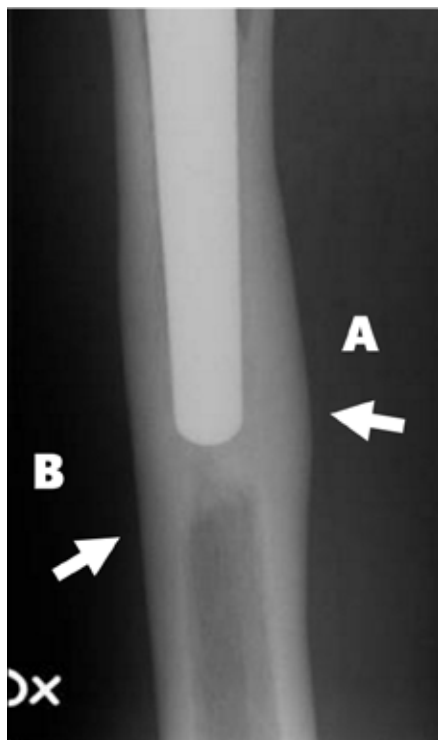


FIGURE 40. Example of distal cortical hypertrophy (A) and pedestal formation (B).

Classification of bone defects

All failed THA's have bone defects and often this bone loss is more advanced than the radiographs indicate.⁷⁹ Nevertheless, for the surgeon it is necessary to assess this pre-operatively so as to be able to best plan for the revision surgery.¹⁹⁶

In *Study II*, we used the Bi-Metric stem in cases where the pre-operative bone defects were moderate (type I-III) according to the following two classification systems (Figure 41):

GUSTILO-PASTERNAK CLASSIFICATION¹¹⁹

According to this classification a type I defect is denoted by minimal endosteal or inner cortical bone loss. A type II defect involves proximal canal enlargement with cortical thinning of 50% or more and sometimes a lateral wall defect with an intact circumferential wall is presented.

A posteromedial wall defect involving the lesser trochanter is classed as type III. A type IV defect exhibits total proximal circumferential bone loss of varying distances below the lesser trochanter.

ENDO-KLINK CLASSIFICATION⁸⁴

A type I defect means there are radiolucent lines limited to the proximal half of the cement mantle in combination with clinical signs of loosening.

A complete radiolucent line surrounding the cement mantle with endosteal erosion around the proximal section of the cement mantle resulting in widening of the medullary canal indicates a type II defect.

In a type III there is a widening of the medullary cavity around the loose implant due to endosteal erosion and expansion of the femur.

A type IV defect displays large destruction of the proximal third of the femur with involvement of the middle third femur.

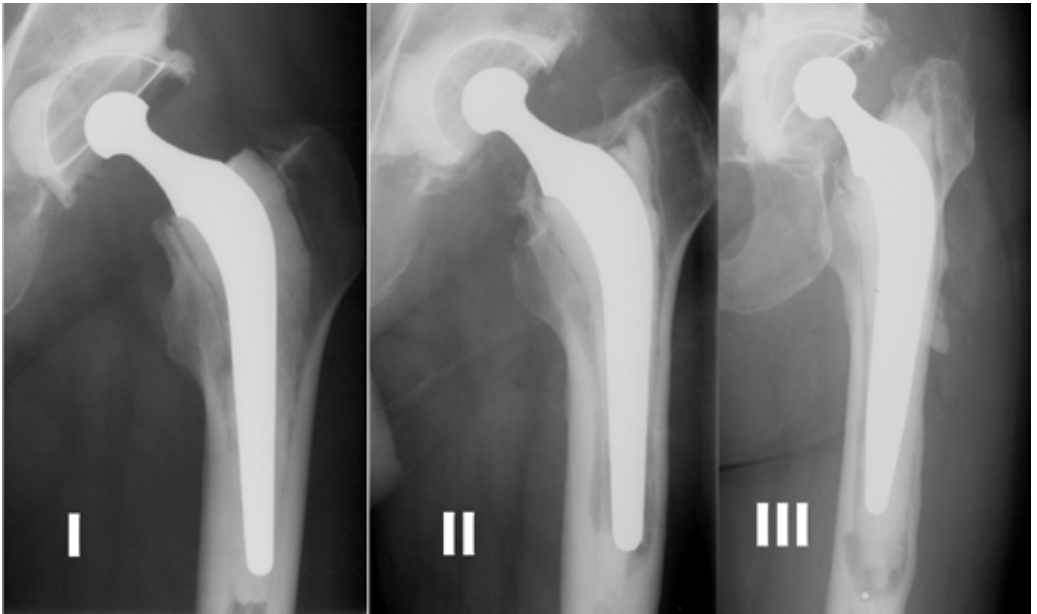


FIGURE 41. Aseptic loosening with bone defects type I, II and III according to both classification systems.

Radiostereometry

Radiostereometry (synonyms; radiostereometric analysis and roentgen stereophotogrammetric analysis) is a high-precision method to measure three-dimensional (3-D) micro-motions from calibrated stereo radiographs.²⁶⁴ Since its introduction in the 1970s, it has been widely used to measure 3-D motion between skeletal structures,¹⁹⁹ between implants and host bone¹⁶⁵ and for wear analysis.⁷¹

The method requires the insertion of tantalum markers (0.8 – 1.0 mm) into the skeleton (Figure 42) as well as corresponding marking of the implant (or other skeletal structure) to create two rigid bodies called segments. Post-operatively, and at regular follow-up intervals, simultaneous calibrated stereo radiographs are taken.

The migration of the center of gravity of the implant segment in relation to the skeleton segment for translation and rotation around the x-, y- and z-axes (the six degrees of freedom) is then calculated using readily available computer software (Figure 43).^{146,282,301}

By doing measurements over time, implant migration can be quantified and loosening predicted with high sensitivity.^{165,257} The precision of RSA is, in laboratory conditions, close to perfect³⁰² and in clinical trials typically around 0.2 mm in translations and 0.5° in rotations.^{13,35,39,49}

In RSA studies, the amount of migration that increases the risk for revision varies between implants and the method of fixation. For the cemented Lubinus SP I stem, a subsidence exceeding 1.2 mm during the first post-operative year indicates a 50% risk for revision within 5-7 years.¹⁶⁵ In uncemented stems, there is evidence that subsidence should be lower than 1-1.5 mm and retroversion less than 3° during the first year to avoid revision surgery.¹⁶⁶

RSA IN STUDY IV

The RSA method in *Study IV* follows the published guidelines for RSA.³⁰¹ We took digital calibrated radiographs (Bucky Diagnostic®, Philips, Eindhoven, Netherlands) using a fixed and a mobile x-ray source (120 kV, 4-6 mAs), and an uniplanar calibration cage (Uniplanar digital 43, RSA Biomedical AB, Umeå, Sweden), (Figure 44). All data were analysed using the UmRSA®

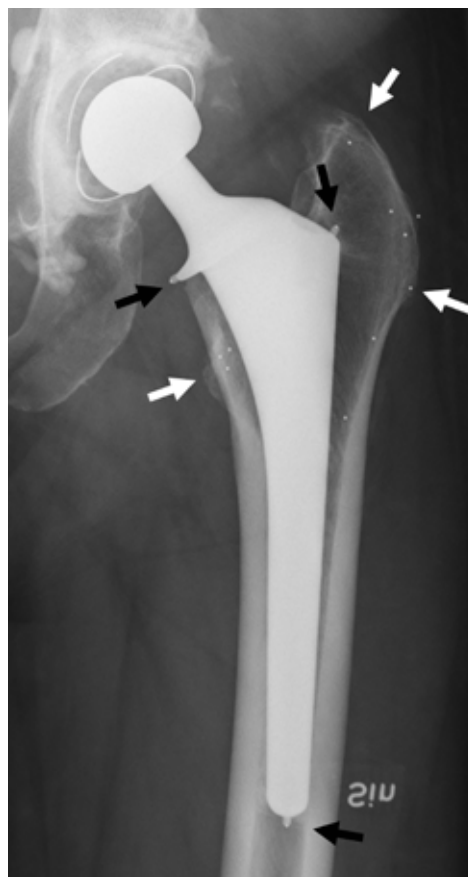


FIGURE 42. Tantalum markers in proximal femur (white arrows) and implant (black arrows).

computer software (RSA Biomedical AB, Umeå, Sweden).

The markers in the proximal femoral bone form one segment. The centre of the prosthetic head, in combination with the tantalum marker beads in the femoral stem, forms another segment. The 3-D translations and rotations of the

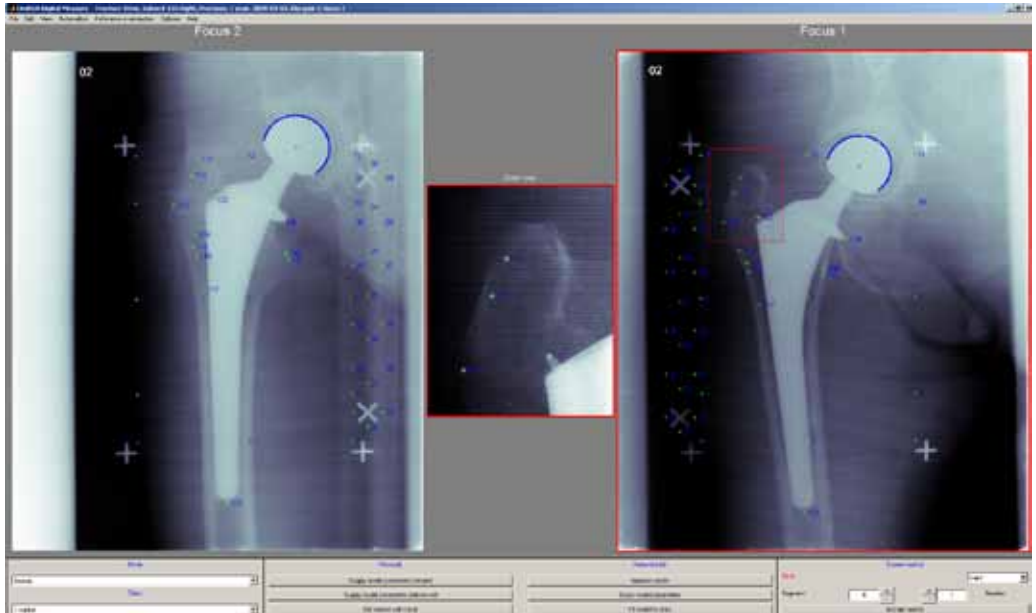


FIGURE 43. RSA evaluation of calibrated stereo radiographs in semi-automated software.

calculated centre of gravity of the femoral stem segment in relation to the femoral bone segment were calculated at each follow-up visit with the immediate post-operative examination as baseline.

We also measured the maximum total point motion (MTPM). This is the 3-D translation vector of the femoral stem marker that has the largest movement and is seen as an indicator of the overall magnitude of migration.

At 12 months, we performed double examinations 15 minutes apart on 25 patients with complete repositioning of the x-ray tubes and the calibration cage. We calculated the precision as the 99% confidence limits (SD 2.7) of the difference between these examinations. For translation along the x (transverse), y (vertical) and z (anterioposterior) axes, it was 0.27, 0.19 and 0.52 mm, respectively. For rotation about the x-axis (flexion/extension), y-axis (ante-/retroversion) and z-axis (varus/valgus) the values were 0.52, 0.76 and 0.27°, respectively and for MTPM it was 0.74 mm. The precision for our RSA-setting is similar to that of previously reported trials.^{122,281}

The mean error of rigid body fitting²⁸² is used

to evaluate the stability of marker position over time. We excluded examinations where this value was >0.3 mm, indicating migration of markers.

Condition number²⁸² is used to evaluate marker distribution and a high value precludes accurate measurements of z-translation as well as segment rotation and MTPM. Therefore, in examinations where the condition number exceeds 100, only transverse (x) and vertical (y) translations were calculated.

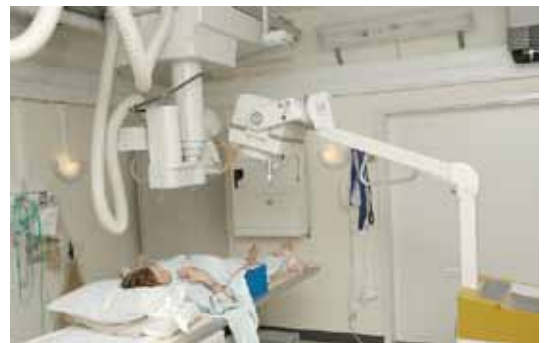

FIGURE 44. RSA setting in Study IV showing the fixed and the mobile x-ray tubes.

Einzel-Bild-Röntgen-Analyse

*Einzel-Bild-Röntgen-Analyse*¹⁵⁹ (EBRA) can also be used to measure migration of implants. Compared to RSA, it has both advantages and limitations.

The greatest advantages are that it can be used retrospectively on plain radiographs, that the precision is significantly better than manual methods and that no implant or host-bone marking is necessary.²³⁹

Initially, it could only be used to assess migration of acetabular components¹⁵⁹ but the method was later expanded to include assessment of migration in femoral components (EBRA-FCA) as well.²¹

The biggest disadvantages are its lower precision compared to RSA, that it can only be used to evaluate THA and that more patients are required for a trial.

EBRA has been used in several studies to analyze clinically relevant migration of a femoral stem after THA^{157,160} and has, as in *Study III*, been used to study the effect of bisphosphonates on cup and stem migration after THA.^{104,306}

EBRA-FCA IN STUDY III

As in RSA, a semi-automated software is used for the analysis, and points are placed in predefined areas around the contours of the implant (Figure 45).²⁰¹ At least 4 plain radiographs are required for each patient at different follow-ups.

The software excludes radiographs that are not comparable. Thereafter, it calculates the vertical migration of the stem shoulder in relation to the greater trochanter, as well as, the angle between the bone and stem. The diameter of the femoral head is used to correct for magnification.

The software uses algorithms to calculate corrected migration based on comparable radiographs (Figure 46).

Using these landmarks, the method has an accuracy of 1.5 mm and it can detect a migration larger than 1.0 mm with a specificity of 100% and a sensitivity of 78%.²¹

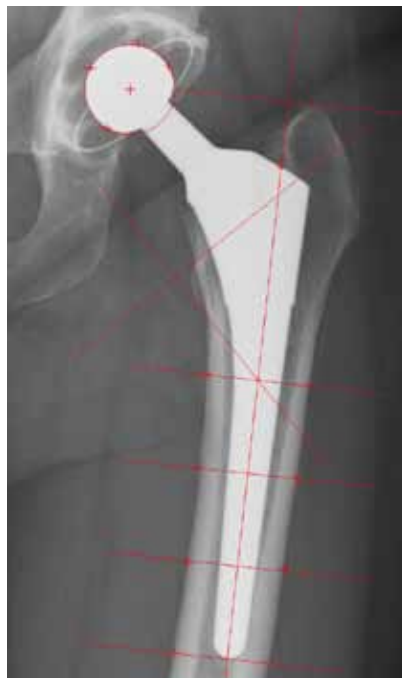

FIGURE 45. EBRA-FCA measurement.

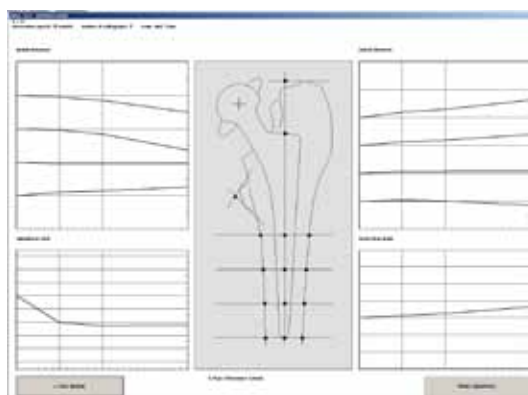

FIGURE 46. EBRA-FCA graph of migration based on comparable radiographs.

Dual-energy X-ray Absorptiometry

Radiographs are insensitive when used for quantifying bone density change, requiring losses of up to 30% before being reliably detectable.⁸⁸ DXA is a more sensitive tool for measuring bone remodelling around femoral stems and was first used to measure BMD of the spine¹⁵⁰ and the femoral neck.²²⁷

For scanning, the patient is placed in the supine position on the patient table. A narrow x-ray beam (small angle fan-beam), filtered through a metal filter (cerium) producing two x-ray energies, is scanned across the patient. The x-rays transmitted through the body are collected by a digital detector which produces a signal.

The detector can separate the signal into two different energy regions corresponding to the energies produced from the x-ray source. The greater the BMD, the greater the difference in the detected signal between the two energy regions will be. The difference in attenuation coefficient for muscle as opposed to bone is used in an equation to calculate the BMD.

Quantitative computed tomography is the only technique that can directly measure bone density and volume and can distinguish trabecular from cortical bone. However, DXA scanning is less expensive, exposes the patient to less radiation¹⁴⁵ and is more sensitive and accurate at measuring subtle changes in bone density over time^{30,33} or changes that occur in response to drug therapy^{12,63,304} as in *Study III* of this thesis.

DXA measures bone mineral content (BMC) in grams in the frontal plane only and by dividing it with the scanned surface area the BMD in g/cm² can be calculated.

In the early 1990s, new software developments made it possible to measure BMD adjacent to metal implants¹⁵² which spawned a plethora of published reports in the field of bone remodelling after THA.^{17,60,161,258}

The standard method is to measure BMD around the stem in the 7 frontal Gruen zones¹¹⁸ (Figure 47), but it can also be used around acetabular cups,^{70,98} in modified zones for ultra-short stems⁴ or for resurfacing implants.^{130,177}

DXA IN STUDY I, III AND IV

In *Study I, III* and *IV*, a DXA scanner was used (DPX-L™, Lunar Co., Madison, Wisconsin, U.S.A.) to measure BMD of the periprosthetic femur in the 7 Gruen¹¹⁸ zones in the frontal plane. During scanning, the patient was placed in the supine position with knee and foot supports and the femur was positioned in neutral rotation. The software then detects the interface between the bony part and the prosthesis stem on the basis of density changes and simulated the stem in the form of a prosthesis mask corresponding to the Gruen zones.

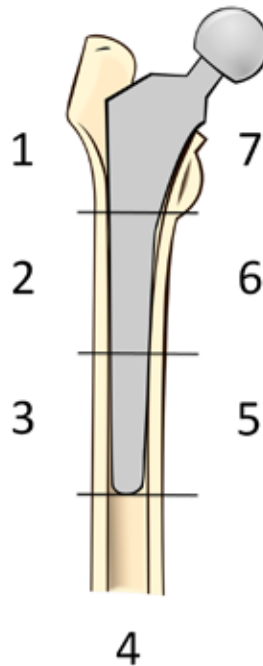


FIGURE 47. The 7 Gruen zones in the frontal plane. Illustration by Max Gordon.

ACCURACY OF DXA

Accuracy is defined as the closeness of a true value and the most probable value, which has been derived from a series of measurements. Accuracy includes both random and systematic errors.

The accuracy of DXA in determining the true BMD of bone is controlled in several ways. Firstly, a HA phantom with known BMC of the lumbar spine and hip is used to calibrate the scanner after manufacture. Secondly, the physicist performed weekly scans with an aluminium vertebrae phantom (Figure 48). In addition, daily scans of another phantom were performed to calibrate hardware and software parameters and radiation dose.

The accuracy error using this control method is typically 0.5-1%.

PRECISION OF DXA

Precision, also called reproducibility, is the degree to which repeated measurements under unchanged conditions show the same results and refers to random errors. The precision of BMD measurements around an implant is, in a HA phantom 0.6% and in cadavers 2-3%.⁶⁰

To estimate the precision error of the DXA method, we had previously made double measurements in 10 patients with complete repositioning of the patients and the scanner and calculated the

error of the difference between these two measurements.

The precision error was found to be 2.3% in Gruen zone 1, 1.0% in zone 2, 2.0% in zone 3, 3.5% in zone 4, 4.2% in zone 5, 1.3% in zone 6, and 3.7% in zone 7.³⁰ This precision compares well with that reported in other studies.^{152,220}

CALCULATING BMD CHANGE

In *Study I*, the healthy hip was scanned at the corresponding level and the prosthesis mask was superimposed on the healthy side and used as control to calculate percentage BMD change.

In *Study III-IV*, the change in periprosthetic BMD ratio in all individual zones, as well as the entire periprosthetic region (zone 1-7), was calculated by dividing the BMD value at each follow-up visit by the post-operative BMD and converting it to a percentage change.

In *Study III-IV*, as well as periprosthetic BMD, we also assessed the patients general BMD. In *Study III*, this was done pre-operatively (at inclusion) by scanning the proximal femur of the diseased hip (WHO total hip) and vertebrae L₁-L₄ (WHO lumbar spine). In *Study IV* this was done immediately post-operatively by scanning the proximal femur in 36 patients with a healthy contralateral hip at inclusion. This was then used as a proxy for the pre-operative BMD of the injured side.

In *Study III-IV* we also scanned the lumbar spine of all patients. In both studies the BMD of the L₁-L₄ vertebrae were also measured at 24 months post-operatively. ◉



FIGURE 48. Aluminum phantom used for weekly accuracy calibration.
Photo by Hans-Jerker Lundberg

9.3 CLINICAL OUTCOME MEASUREMENTS

Charnley classification

In his original article on low-friction arthroplasty,⁵⁴ Charnley suggested a simple classification system for assessing the walking ability of patients who are candidates for hip arthroplasty surgery. (A) denotes a patient with unilateral hip disease or unilateral THA. (B) is a patient with bilateral hip disease (or with a THA in one hip and disease in the other). (C) is a patient with a co-morbidity contributing to loss of walking ability, such as rheumatoid arthritis, knee OA, cardiovascular or respiratory disability.

This commonly used classification system allows a comparison between groups and is used as a co-morbidity factor in the Swedish Hip Arthroplasty Register.¹⁰⁹

Charnley's classification has also been criticized because of its simplicity as those graded as class B consists of two very different patient groups: those with a THA in one hip and a diseased joint in the other, and those who have bilateral THAs.

An extension of the traditional Charnley classification has therefore been proposed, taking into account the two different patient groups in Charnley class B. The new fourth Charnley class consists of patients with bilateral THA and is labeled BB in order to express the presence of two artificial hip joints.²⁵¹

In this thesis however, the original A, B and C classification has been used.

Harris hip score

The most widely used hip-specific outcome score after THA is the Harris hip score (HHS).¹²⁷ Originally developed for outcome measurements of mold arthroplasty after traumatic arthritis, it has been found to be a valid and reliable score for hip function after THA.²⁷⁶ HHS was originally surgeon-assessed but since then has been vali-

dated for self-reporting,¹⁸⁶ and also for outcome after FNFs.¹⁰⁵

The HHS gives a maximum of 100 points (full function of the hip) and a minimum of 0 (no function in the hip). It has 4 domains: pain, function, deformity, and range of motion. Pain and function are the two domains with the heaviest weighting (44 and 47 points, respectively). Function is further subdivided into activities of daily living (14 points) and gait (33 points). Range of motion, deformity and limb length discrepancy receives 9 points. The somewhat elaborate calculations for the last three categories can be simplified with on-line tools.⁵⁶

In this thesis, the assessment of the HHS was done as it was originally intended; by the surgeon at the follow-up visit.¹²⁷

EQ-5D

EQ-5D95 is a standardized, self-reported, non-disease-specific instrument for measurement of health-related quality of life that was developed by the EuroQoL group.^{43,245} It is now widely used in many countries around the world and has been translated into most major languages.^{43,45}

EQ-5D describes health status in 5 dimensions: mobility, self-care, usual activity, pain/discomfort and anxiety/depression. Each dimension is divided into 3 levels: 1 - no problems, 2 - some problems and 3 - extreme problems. This generates 243 different "health states" and the EQ-5D index score assigns each "health state" a value, ranging from -0.59, indicating the worst possible health state, to a value of 1, indicating full health.

EQ-5D has been used in clinical trials in many different fields of medicine and is frequently used to access quality of life after both hip fracture surgery^{24,293} and THA.^{187,209}

Pain Numeric Rating Scale

The Pain Numeric Rating Scale (PNRS)⁷⁷ is an 11-point (0-10) numerical rating scale that is easy to administer, and has been validated as a measure of pain intensity in populations with known pain.¹⁴² A score of 0 denotes no pain and 10 indicates the worst possible pain. In *Study III* and *IV*, patients were asked to evaluate the level of pain they experienced in the operated hip during the previous week (Figure 49).

Complications

In all studies information regarding the occurrence of complications and reoperations was collected on all patients. This was done retrospectively by checking hospital records in *Study I- II* and prospectively at regular follow-up visits in *Study III-IV*.

HHS was used to evaluate hip function in all studies and the Charnley classification was used in *Study II-IV*. EQ-5D and PNRS was used at follow-up visits in *Study III-IV*. In *Study I-II* the presence of thigh pain was graded by the patient as either mild, moderate or severe. ◉

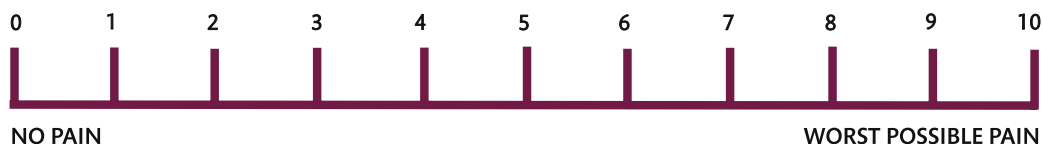

FIGURE 49. Pain Numeric Rating Scale.

9.4 STATISTICAL METHODS

In *Study I-II*, the statistical package JMP 6.0 was used for all analyses. In *Study III-IV*, the statistical software PASW Statistics 18.0 for Windows was used. Sample size calculations were performed using the software SamplePower 2.0.

Sample size calculation

STUDY I

A power analysis was performed in advance (one-sided, $p=0.05$) and indicated a 90% power to detect a 15% difference in BMD (SD 10%) between the non-operated and operated side in Gruen zones 1 and 7 using 21 patients.

STUDY II

No power analysis was performed in advance.

STUDY III

A power analysis (two-sided, $p=0.05$) based upon Study I was performed in advance on the primary end point. A total of 30 patients in each group indicated a power of 90% to detect

a clinically relevant difference of 10% (SD 11%) in BMD in the periprosthetic zones 1 and 7 between the 2 treatment groups. We estimated that we would have a loss of data of up to 20% and therefore planned to recruit 37 patients in each group.

STUDY IV

A power analysis performed in advance indicated that the study, with 20 patients, would have a power (two-sided, $p=0.01$) of more than 99% and 93% to detect a continuous migration in MTPM and y -translation, respectively.

These estimates were based upon a previous RSA study with the HA-coated version of the Bi-Metric stem²⁸¹ where MTPM was mean (SD) 1.9 (1.3) mm and y -translation was 0.2 (0.2) mm. We recruited 50 patients to accommodate for an expected loss to follow-up and to allow for subgroup analyses in subjects with high and low BMD.

Statistical analysis

Due to varying journal policies, the methods regarding parametric or nonparametric tests differ somewhat in the studies. We used the chi-square test to test for differences between distributions. P-values ≤ 0.05 were considered significant.

STUDY I

Student's t-test was used to analyze the difference in BMD between the operated and non-operated hip and also the difference between stem sizes in the different Gruen zones. To investigate factors that may influence bone remodelling, we used the Pearson's product moment correlation coefficient to analyze the relationship between BMD and sex, age, weight, height, body mass index, implant time, initial BMD—expressed as BMD on the healthy femur—and Harris hip score.

STUDY II

The Mann-Whitney U-test was used to test the association between HHS and Charnley's classification system.

STUDY III

Analyses of efficacy were based on the intention-to-treat principle and all patients, who received at least 1 dose of either risedronate or placebo, were included in the final analyses. Subjects with missing BMD data at any of the follow-ups (5 follow-ups in the risedronate group and 4 in the placebo group) were analyzed with the last observation carried forward. The analyses were repeated with the use of only the available data, and the same results were produced (data not shown).

We used a one-way repeated measures analysis of variance (ANOVA) to detect an overall effect of treatment throughout the study period.

Factors known to influence periprosthetic bone loss, for example sex,⁷ age, BMI, stem size²⁷¹ and pre-operative BMD of the hip²⁴⁶, were included as covariates in the analyses. Stem size was categorized into sizes 8-10/11-13/14-15 (size 8-10 as reference).

Median pre-operative hip BMD (1.014 g/cm^2) was used to dichotomize the subjects into 2 groups; patients with either high or low BMD (mean $1.173 \pm 0.130 \text{ g/cm}^2$ and $0.896 \pm 0.096 \text{ g/}$

cm^2 , respectively). The reference category was patients with a high BMD. The effect of general bone mass (WHO total hip and WHO lumbar spine) on periprosthetic bone loss was also analyzed using the Pearson's correlation coefficient at 24 months.

The unpaired Student's t-test was used for group comparisons and the paired Student's t-test for comparing longitudinal changes. Between-group comparisons of clinical outcome scores at follow-up visits were analyzed with the Mann-Whitney U-test and within-group comparisons between baseline and follow-up were analyzed with the Wilcoxon signed-rank test.

STUDY IV

We used analysis of covariance (ANCOVA) to study covariates affecting implant migration and bone loss. Firstly; to evaluate the effect of periprosthetic BMD on implant migration and bone loss, we used MTPM and a BMD change in zone 1-7 as dependent variables and sex, age, BMI, stem size and immediate post-operative BMD in zone 1-7 as covariates.

Median BMD was used to dichotomize the subjects into 2 groups, patients with either high or low BMD (high vs. low: mean BMD $1.77 \pm 0.33 \text{ g/cm}^2$ and $1.35 \pm 0.11 \text{ g/cm}^2$, respectively).

In the second analysis, we evaluated the effect of pre-operative BMD on bone loss in a subgroup of 36 patients. These patients had a healthy contralateral femur at inclusion and post-operative DXA scans of the unaffected hip and vertebrae L₁-L₄ (WHO total hip and lumbar spine) were used as a proxy for pre-operative BMD and categorized as normal (T-score $> -1 \text{ SD}$), osteopenia ($-1 \text{ SD} \geq \text{T-score} > -2.5 \text{ SD}$) and osteoporosis (T-score $\leq -2.5 \text{ SD}$). In the analyses, BMD change in zone 1-7 then was used as the dependent variable and sex, age, BMI, stem size and T-score category of the hip or lumbar spine as covariates.

Between-group comparisons of continuous variables at follow-up were analyzed with the Mann-Whitney U test and within-group comparisons between baseline and follow-up values were analyzed with the Wilcoxon signed-rank test. ◉

10 RESULTS

Study I

CLINICAL OUTCOME

Within 6 weeks of surgery, 16 non-fatal complications (7 superficial wound infections that required antibiotics, 4 deep venous thromboses, 3 pulmonary emboli, and 2 myocardial infarctions) were diagnosed.

All stems were stable according to the Fixation/Stability score and no stem revision was required. The mean HHS was 97 (63–100) points with 6 patients having mild thigh pain.

STEM SIZE AND BONE LOSS

The distribution of stem sizes in females and males differed somewhat (Figure 50), the most common size for females being 11 and for males 13.

The periprosthetic bone loss was most pronounced in zones 1 and 7 with a -19% difference compared to the unoperated side (Table 6 and Figure 51). In the proximal zones 1, 2, 6 and 7 we found a decreasing BMD correlated to the stem size used ($r^2=0.16, 0.09, 0.16$ and 0.14 , respectively), (Figure 52 and Figure 53). The multiple regression analysis with stem size as control variable showed no correlation between bone loss in any zone of the operated femur and sex, age, weight, height, body mass index, implant time, initial BMD—expressed as BMD on the healthy femur—or HHS.

In addition, no difference was found in BMD loss in any zone between the patients who received an uncemented HA-coated cup and those who received a cemented polyethylene cup.

TABLE 6. BMD in the 7 Gruen zones for all stem sizes. Mean (SD) values.

Gruen zone	Operated side (g/cm ²)	Unoperated side (g/cm ²)	Change (%)
1	0.85 (0.16)	1.05 (0.17)	-19 (11)
2	1.81 (0.28)	1.85 (0.26)	-2 (10)
3	2.00 (0.25)	1.92 (0.25)	+5 (8)
4	1.91 (0.29)	1.95 (0.26)	-2 (9)
5	2.09 (0.23)	1.99 (0.23)	+5 (7)
6	1.78 (0.28)	1.87 (0.23)	-5 (10)
7	1.09 (0.29)	1.35 (0.24)	-19 (15)

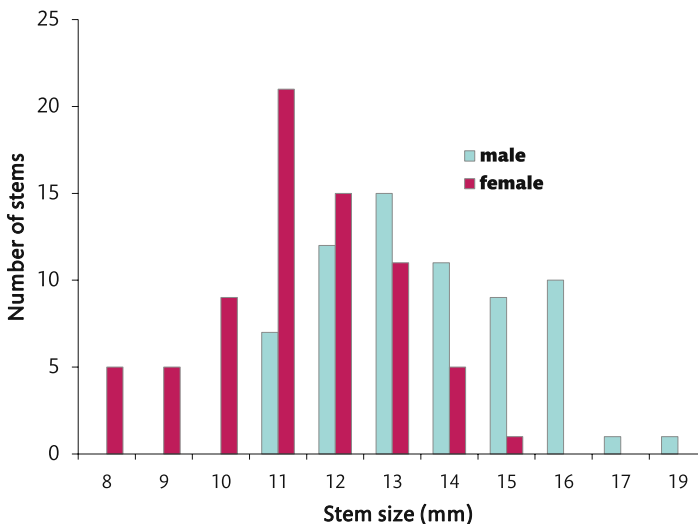


FIGURE 50. The distribution of femoral stem diameters.

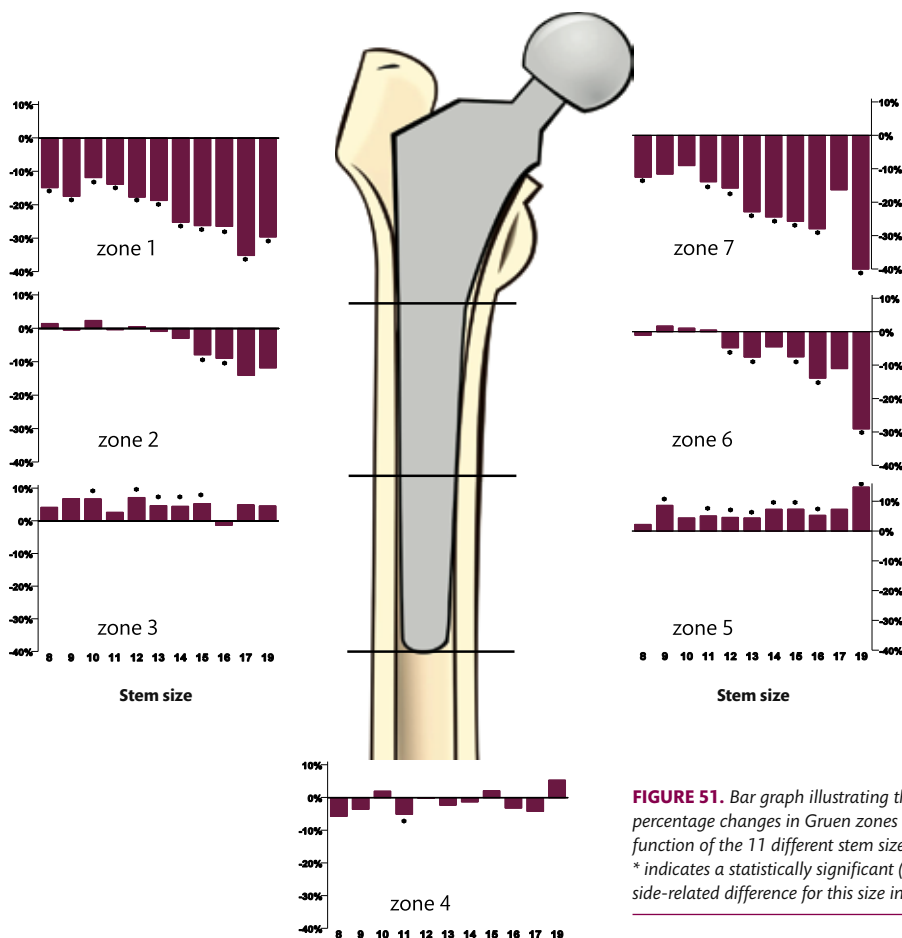


FIGURE 51. Bar graph illustrating the mean percentage changes in Gruen zones 1-7 as a function of the 11 different stem sizes. * indicates a statistically significant ($p \leq 0.05$) side-related difference for this size in that zone.

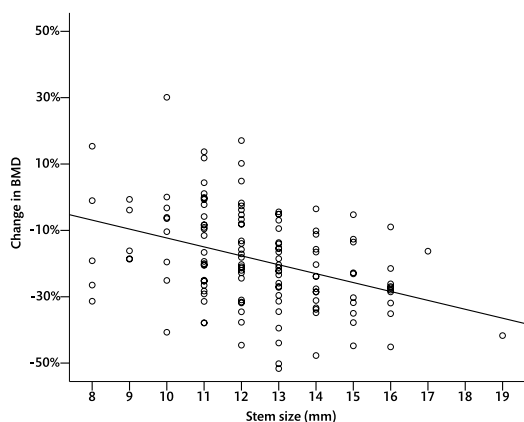


FIGURE 52. Scatter plot of correlation between stem size and BMD ratio (percentage of the contralateral value) in Gruen zone 1.

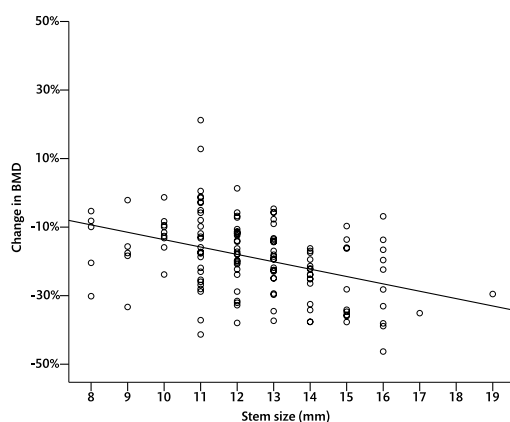


FIGURE 53. Scatter plot of correlation between stem size and BMD ratio (percentage of the contralateral value) in Gruen zone 7.

Study II

CLINICAL OUTCOME

Between the femoral revision operation and the follow-up, 6 of the original 60 patients (62 hips), had undergone a cup revision/liner exchange and 3 stems required re-revision (Table 7). The 6-year prosthetic survival rate was 95% (95% CI: 0.83–0.98). The dislocation rate was 15% (9/62).

At follow-up, the mean HHS score was 75 (30–100) points. We noted a lower HHS for patients classified as Charnley class C compared to patients classified as class A ($p < 0.001$) and B ($p < 0.005$), (Figure 54).

RADIOGRAPHIC RESULTS

Bone defects were predominately type II in both classifications, and no type IV defect was observed (Table 8).

At follow-up, all stems showed several signs of rigid fixation (Table 9).

The most commonly used stem sizes in *Study II* were 15 and 17. There were no differences in HHS or bone remodelling parameters between large and small diameter stems (data not shown). However, only 4 patients received a stem smaller than 15 mm and the smallest stem used in the study was 11 mm.

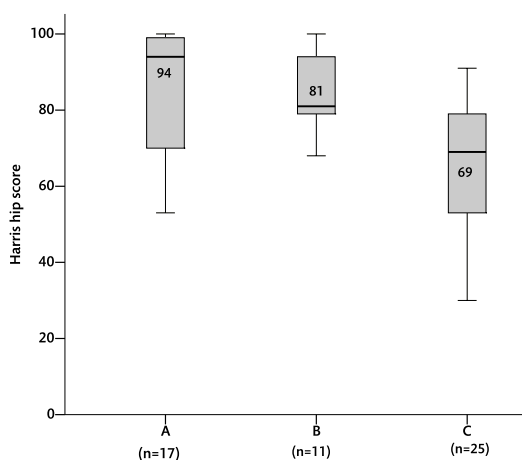


FIGURE 54. Box plot of Harris hip score (53 hips) in the different Charnley classes.

TABLE 7. Complications and revision surgery of the original 62 hips

Complications	n	Stem re-revision	Cup revision/liner exchange
Dislocation ^a	9		1
Cup loosening	5		5
Periprosthetic fracture			
Peroperative ^b	4	1	
Postoperative	4	2 ^c	
Deep infection	1		
Superficial infection	2		
DVT	1		
Sensory sciatic nerve injury	1		

^a Two had recurrent dislocations, 1 underwent liner exchange converting it to a larger articulation.

^b Two of these were treated with cerclage wiring peroperatively. The revised patient, who sustained a fissure in the lesser trochanter peroperatively, suffered from pain and subluxations. The stem had subsided and he was re-revised using impacted morselized bone allograft and a cemented stem.

^c One immediate re-revision and another 2 years postoperatively.

TABLE 8. Femoral bone defects at revision (53 hips)

Type	Gustilo and Pasternak	Endo-Klinik
I	17	4
II	35	38
III	1	11
IV	0	0

TABLE 9. Bone remodelling at follow-up (53 hips)

	No.
STEM STABILITY PARAMETERS	
Fixated stems	53
Subsidence (maximum 8 mm)	19
Change in varus-valgus alignment	0
Spot welds	30
STRESS-SHIELDING PARAMETERS	
Calcar resorption	16
Calcar "round-off"	7
Distal cortical hypertrophy (1-4 mm)	14
BONE REMODELLING PARAMETERS	
Osteolysis at revision	48
Regression of osteolysis	
total	7
partial	37
Newly formed osteolysis	2
UNSPECIFIED PARAMETERS	
Pedestal formation	36
Reactive lines	16
Heterotopic ossification	
grade 1	13
grade 2	6
grade 3	5
grade 4	0

Study III

CLINICAL OUTCOME

The frequency of adverse events was comparable in both groups (risedronate vs. placebo; 20 of 36 versus 24 of 37, $p=0.416$). In the risedronate group, a significantly larger number of patients discontinued the study drug because of adverse events [2 due to urticaria and 2 due to nausea ($p=0.037$ versus placebo)].

Two patients in the placebo group suffered a non-traumatic dislocation of the hip; one patient had to undergo a stem revision 6 days post-operatively and another required a closed reduction 8 weeks post-operatively. Both hips have remained stable since then.

One patient suffered a pulmonary embolism and another a deep vein thrombosis, both in the placebo group. The patients' HHS, EQ-5D and PNRs had all improved compared to the pre-operative value and no differences were found between the groups at any time. The HHS was median 100 (81-100) and 98 (46-100) in the risedronate and placebo groups at 24 months, respectively.

EFFICACY FOR PRIMARY END POINT

In the placebo group, a continuous bone loss was seen with a BMD decrease of 18% in zones 1 and 7 after 24 months. In the risedronate group, bone resorption was effectively reduced during the first 6 months with an efficacy (difference between the 2 groups) of 9.2% and 8.0% at 6

months in zone 1 and 7 respectively ($p<0.001$ and $p=0.003$). In zone 1, the difference between the groups was still statistically significant at 12 months (risedronate vs. placebo; -7.4% versus -14.5%, $p=0.006$) with a trend towards a difference at 24 months (risedronate vs. placebo; -13.6% versus -17.7%, $p=0.066$). In zone 7, there was no statistically significant difference between the risedronate and placebo groups at either 12 or 24 months (Table 10).

The protective effect of risedronate on bone resorption during the entire study period was statistically significant when controlling for sex, age, BMI, stem size and pre-operative BMD of the operated hip (zone 1, $p=0.005$ and zone 7, $p=0.006$, ANOVA), (Figure 55).

In addition, the larger stem sizes (size 11-13 and 14-15) were associated with increased bone loss in zone 1 ($p=0.045$).

Low pre-operative BMD of the hip correlated with an increased bone resorption after surgery in zones 1 and 7 ($p=0.05$ and $p<0.001$, respectively), (Figure 56). Sex, age or BMI did not affect the primary end point at any time (data not shown).

TABLE 10. The effect of risedronate on BMD

Outcome	risedronate	placebo	difference (95% CI)	p value
CHANGE IN BMD ZONE 1 (%)^a				
3 months	1.2±7.6	-5.9±9.0	7.2 (3.2 - 11.1)	<0.001
6 months	-0.5±10.8	-9.7±9.9	9.2 (4.2 - 14.1)	<0.001
12 months	-7.4±14.7	-14.5±11.2	7.2 (1.0 - 13.3)	0.006
24 months	-13.6±12.3	-17.7±13.1	4.1 (-2.0 - 10.2)	0.066
CHANGE IN BMD ZONE 7 (%)^a				
3 months	-3.6±10.2	-10.3±10.9	6.7 (1.6 - 11.7)	0.007
6 months	-5.1±10.6	-13.1±11.7	8.0 (2.7 - 13.4)	0.003
12 months	-11.9±12.3	-16.1±12.0	4.3 (-1.5 - 10.1)	0.318
24 months	-17.2±13.2	-18.1±14.9	0.9 (-5.9 - 7.7)	0.699

^a mean ±SD, p-value Student's t-test.

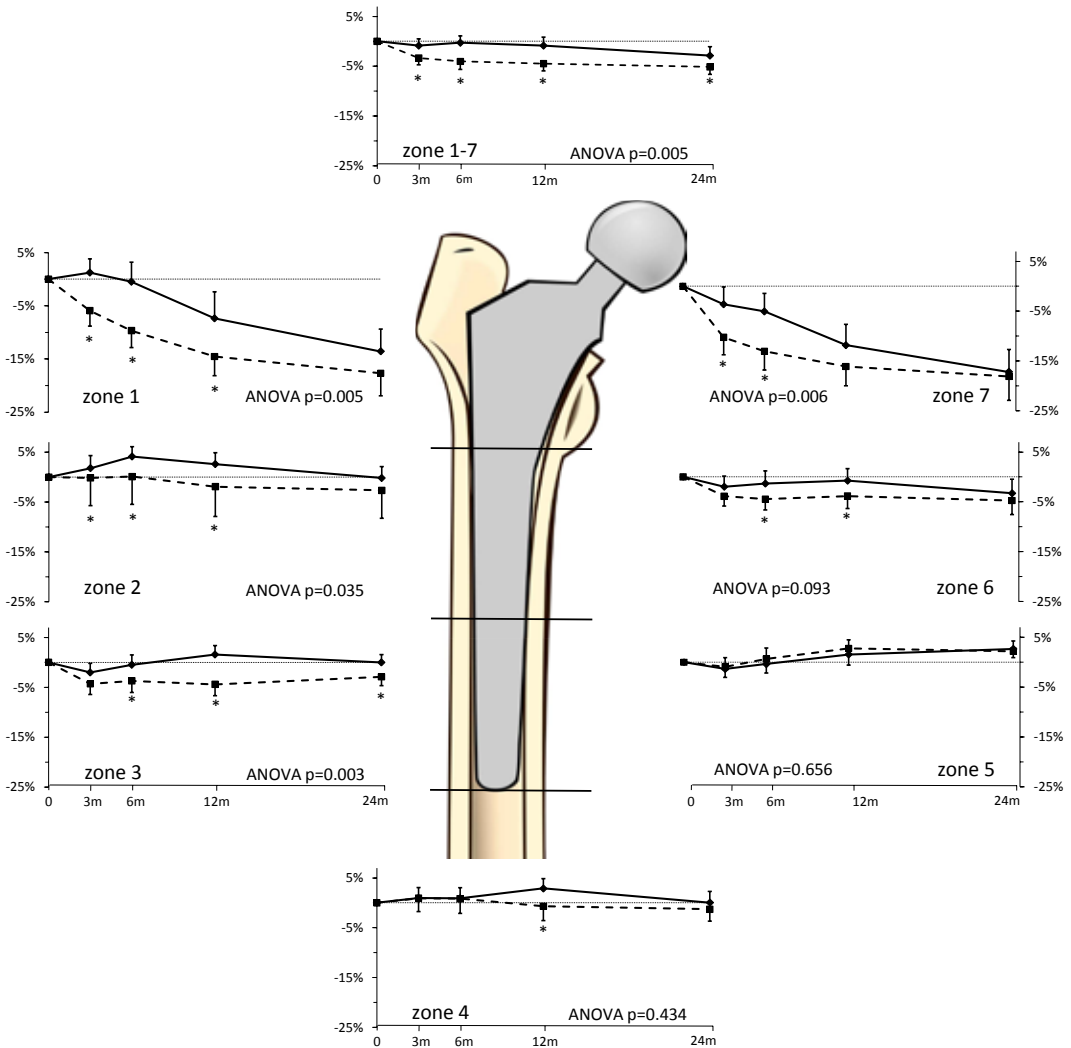


FIGURE 55. The mean (95% CI) percentage change in BMD around the stem in patients receiving risedronate (solid line) or placebo (dashed line). * $p < 0.05$.

EFFICACY FOR SECONDARY END POINTS

In the combined periprosthetic regions (zones 1-7), the patients in the risedronate group had a significantly lower bone resorption at all follow-up visits compared to patients in the placebo group (Figure 55). Bone resorption was also reduced in the risedronate group in zones 2, 3 and 6 with the same tendency as for zones 1 and 7; reduced resorption during the first 6 and 12 months and then increased resorption up till 24 months.

The vertical migration of the stem did not differ between the groups and was mean -1.7 mm in both groups at 24 months. At 24 months, we found no difference in vertebral BMD or the rate

of heterotopic ossification between the groups.

All stems were stable according to the fixation/stability score,⁹¹ but the score was higher in the placebo group (risedronate vs. placebo; 15.5 versus 18.0, $p=0.004$, Mann-Whitney U-test). This was due to a higher number of spot welds in the placebo group (risedronate vs. placebo; 9 of 33 versus 21 of 37, $p=0.013$). There was no difference between the groups with regard to other fixation/stability parameters (data not shown).

On the acetabular side, we found radiolucent lines between bone and cement in DeLee and Charnley⁶⁷ zone 1 in 2 hips in the risedronate group and 1 in the placebo group. There was no radiolucent line around the uncemented cups.

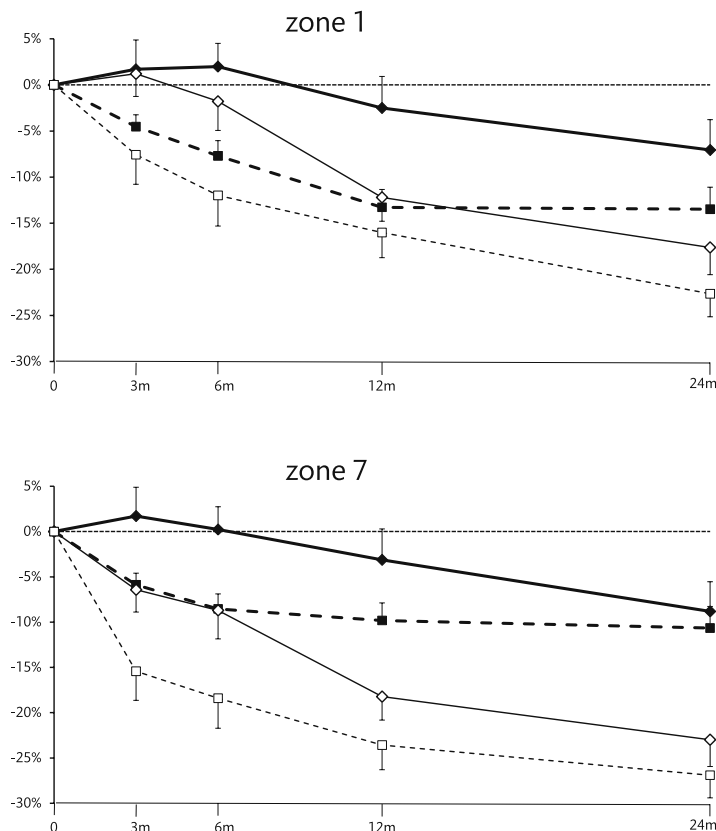


FIGURE 56. The mean (95% CI) percentage change in BMD in patients with high (bold line) or low (thin line) preoperative BMD of the hip in the risedronate (solid line) and placebo (dashed line) groups.

Study IV

CLINICAL OUTCOME

One stem was revised 3 weeks after the primary operation due to a deep wound infection; the infection later healed uneventfully. We noted 1 intra-operative fracture of the greater trochanter and, in the same patient, an undisplaced femoral fracture at the distal tip of the prosthesis.

At 18 months post-operatively, this patient presented with a deep infection in the operated hip and was treated with an open synovectomy and antibiotics. A total of 7 hips (14%) dislocated, 3 of these suffered recurrent dislocations and in 1 of these the cup was converted to a double-mobility cup. Two patients were treated with antibiotics for a superficial wound infection.

There was a slight deterioration in function

and increased pain in the operated hip during the study period (HHS and PNRS prefracture vs. 24 months; mean 88 ± 11 and 0.4 ± 1.3 versus 82 ± 13 and 1.0 ± 1.9 , $p=0.006$ and 0.033 , respectively).

The outcome was less favourable for patients in Charnley class C where degenerative disease in other joints and/or associated medical comorbidities affected the outcome. The median HHS was 88 (100-52), 90 (91-80) and 76 (88-51) in class A, B and C, respectively. Health-related quality of life also declined during the study but did not reach statistical significance (EQ-5D prefracture vs. 24 months; mean 0.71 ± 0.23 versus 0.63 ± 0.37 , $p=0.112$).

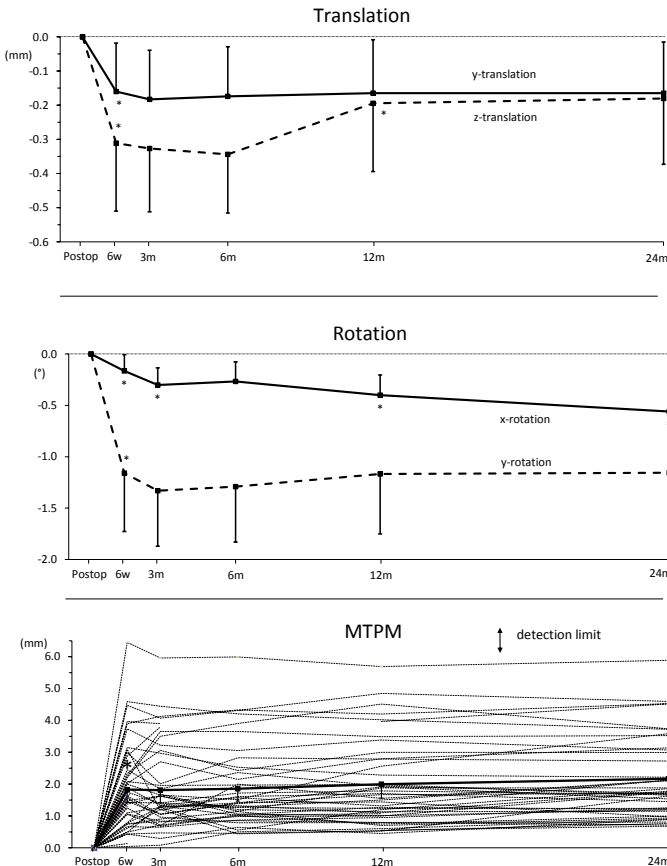


FIGURE 57. The mean (95%CI) migration of the stem in translation and rotation. X-translation and z-rotation are not shown due to insignificant migration. Total migration (MTPM) is shown with mean (95% CI) (solid strong line) and individual (dashed line) values. The length of the arrow corresponds to the detection limit of true (at 99% level) migration. *indicates a significant ($p \leq 0.05$) mean migration compared to the previous examination.

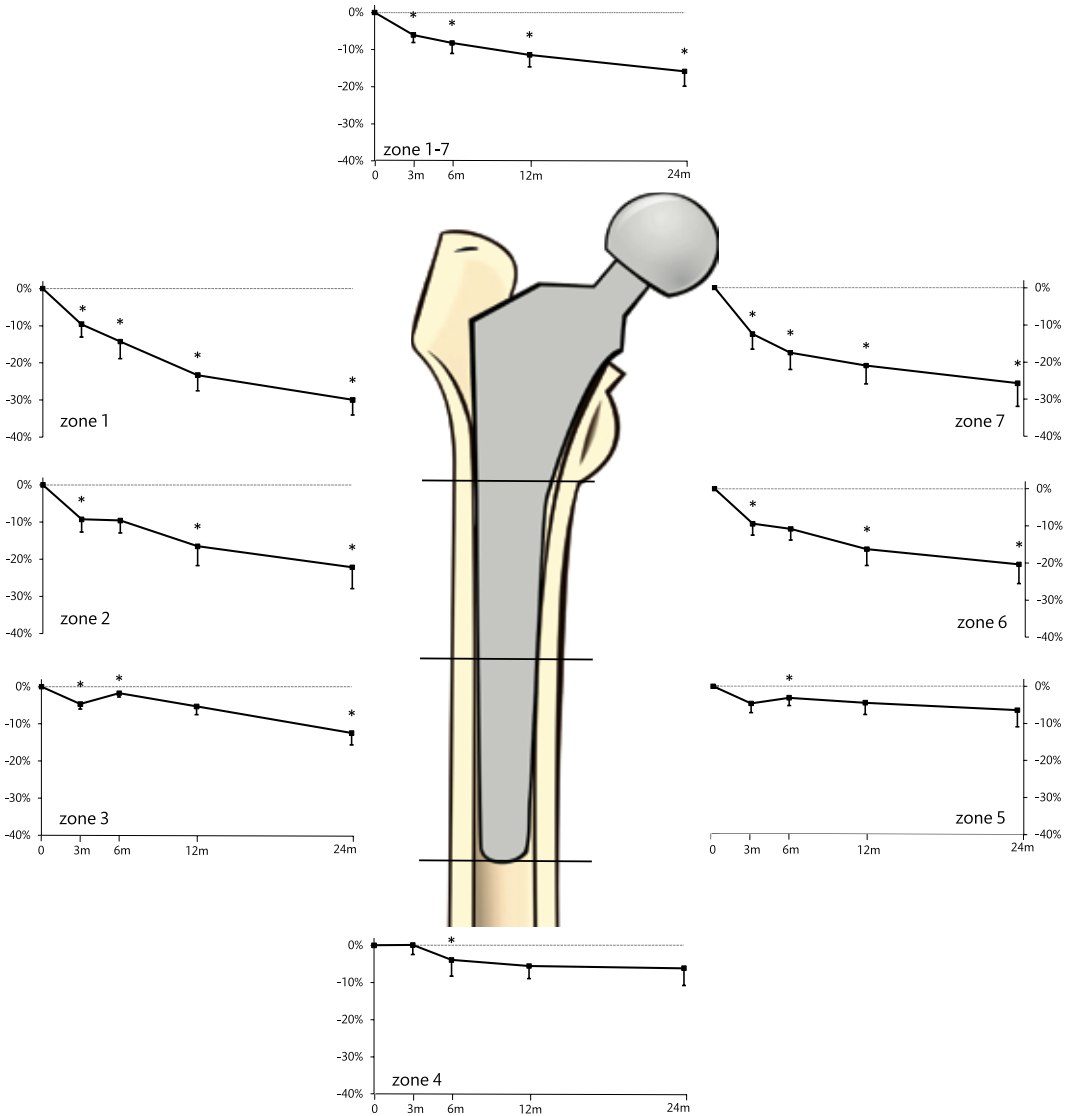


FIGURE 58. Periprosthetic bone remodelling. The mean (95% CI) percentage change in BMD around the stem. * indicates a significant ($p < 0.05$) change in BMD compared to the preceding value.

MIGRATION

Thirty-four stems migrated above the detection limit up to 6 weeks post-operatively and 4 stems continued to migrate up until the 3 month follow-up. After 3 months, all stems had stabilized.

The mean (SD) initial translation in the x, y and z-axes was -0.03 ± 0.27 , -0.16 ± 0.48 and -0.26 ± 0.56 mm with the corresponding rotation -0.16 ± 0.53 , -1.16 ± 1.88 and 0.01 ± 0.62 degrees at 6 weeks. MTPM was 1.83 ± 1.30 mm at 6 weeks.

After this, the mean migration stopped except for rotation in flexion/extension (x), which indicated a small, but statistically significant, continuous migration between 12 and 24 months (Figure 57). Migration of the stem was more pronounced in patients with a low periprosthetic BMD.

BONE REMODELLING

We found a continuous decrease of periprosthetic BMD, with the highest rate of bone loss occurring during the first 12 months, in all zones but zone 4, and a reduction in the total periprosthetic BMD of mean 16% at 24 months (Figure 58).

The bone loss was greatest in zones 1 and 7, with a decrease of 30% and 26%, respectively, at 24 months. Bone loss was significantly related to the patient's general bone mass (Figure 59). The 24-month BMD of vertebrae L₁-L₄ did not differ from the immediate post-operative value.

OTHER RADIOLOGICAL PARAMETERS

The fill of the implant in the femoral canal was classified as good in 17 hips (34%) and we succeeded in achieving a collar-calcus contact in 33 hips (66%). The fill or collar-calcus contact did not affect either migration or bone loss (data not shown).

At 24 months, 25 hips had no heterotopic ossification, 13 had class I-II and 7 class III-IV ossification.⁴² ©

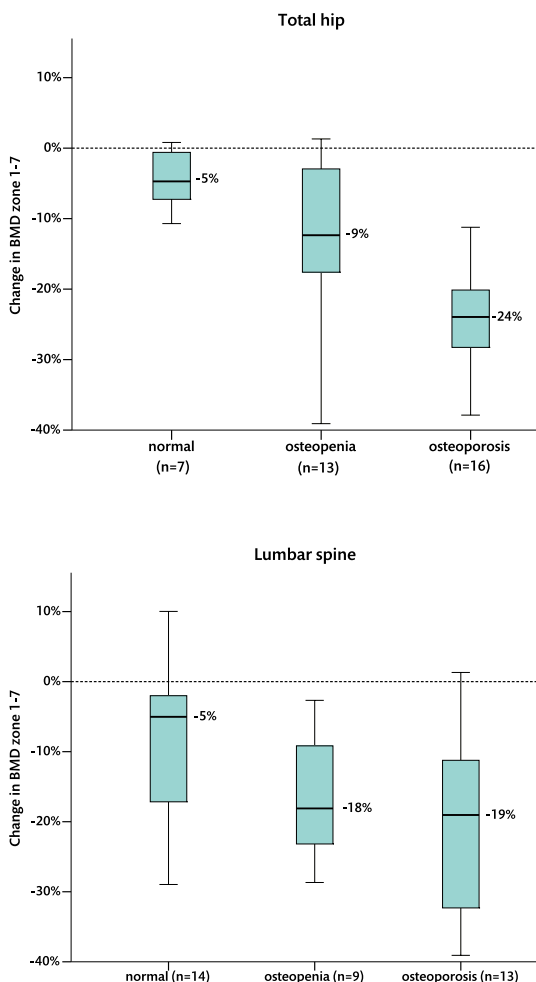


FIGURE 59. The relation between preoperative BMD and bone loss. Change in BMD in zones 1-7 in for 36 patients, with complete follow-up data at 24 months, who were included in a substudy of what effect the BMD of total hip (the non-operated contralateral hip) and lumbar spine had on bone loss after 24 months. Osteopenia and osteoporosis in the hip and lumbar spine were significantly related to periprosthetic bone loss after controlling for sex, age, BMI and stem size (total hip $p=0.015$, $p<0.001$ and vertebrae L₁-L₄ $p=0.021$, $p=0.027$, ANCOVA).

11 DISCUSSION

11.1 DISCUSSION ON MATERIAL

The Bi-Metric stem

The clinical outcome in Study I-III is similar to other studies with the Bi-Metric stem and other uncemented porous-coated THAs from a midterm point of view (Table 11).^{32,65,206,244,250}

The Bi-Metric stem was developed as a straight taper alternative to the Taperloc stem and is commonly used in Scandinavia. In published papers, the revision rate for aseptic loosening is 0-1% after 10 years. There are however, as is described in chapter 3.7, more revisions performed due to fractures and dislocations.

In several studies, particularly these from the Finnish Arthroplasty Register,²²⁶ the results for the stem is less favorable as a result of frequent cup revisions due to osteolysis caused by poorly performing uncemented acetabular components.^{94,217,244} Register studies have the drawback of being dependent on the quality of the data registered. The Bi-Metric stem has, over the years, been marketed in a number of varying configurations in different countries; cemented, uncemented, with/without HA-coating, as a long revision stem and even as a grit-blasted fracture stem similar to the BFX stem in *Study IV*.

The HA-coating increases the amount of

ingrowth and attachment to bone⁵⁹ thereby reducing the migration of the stem.²⁸¹ The only study specifically examining the influence of HA-coating on the Bi-Metric stem on a nationwide basis is a study from the Danish Hip Arthroplasty Register.²³⁴

With a follow-up of median 2.7 years in a cohort of patients under 70 years of age who received a Bi-Metric stem with (n=3158) and without (n=4749) HA-coating, the survival rate concerning stem revision due to aseptic loosening was 100% (CI: 99–100%) for stems both with and without coating. The survival rate concerning stem revision for any reason was 96% (CI: 94–97) and 96% (CI: 95–96%) for stems with or without HA-coating, respectively.

It appears that the stems with and without HA-coating are, at least in the short time perspective, equivalent with regard to revision rate. Whether the HA-coating on the Bi-Metric stem affects the bone remodelling has not yet been studied.

TABLE 11. Studies on the uncemented Bi-Metric stem with and without HA-coating. Only studies with a minimal follow-up of 5 years of 50 hips are shown. In the bottom is, for comparison, the unpublished data from Danderyds Hospital (chapter 3.7).

Authors	year	n	age	fu (yr)	HA	aseptic loosening	all revisions
Puolakka et al. ²⁴⁴	1999	384	n.r.	7.5	no	0.8%	2.7%
Jacobsen et al. ¹⁴⁰	2003	97	50	8.0	no	0%	1%
Yamamoto et al. ³¹⁹	2003	70	55	6.8	no	0%	0%
Lybäck et al. ¹⁸³	2004	77	28	9.6	no	0%	2.1%
Meding et al. ²⁰⁶	2004	105	56	11	no	0%	0%
Bodén et al. ³²	2006	115	52	12.2	yes	0%	0%
Eskelinen et al. ⁹⁴	2006	1982	<55	6.6	no	1.9%	3.7%
Isaac et al. ¹³⁹	2007	58	57	7.6	no	0%	0%
Sköldenberg et al. ²⁷⁰	2009	332	52	12.9	yes	0%	0%
Davies et al. ⁶⁵	2010	64	54	15.2	no	0%	0%
Mäkelä et al. ²¹⁷	2010	5379	>55	6.8	no	1.0%	2.5%
Danderyd Hospital	2010	1718	61	7.3	yes	0%	0.8%

n: number of hips

age: mean age at surgery

fu: mean follow-up time in years

The BFX stem

The BFX stem was designed to be easy to use by traumatologists or general orthopaedic surgeons and is marketed with a unipolar or bipolar hemi-articulation.

In clinical practice, operation with a hemiarthroplasty is still the most common procedure for a displaced FNF in elderly patients despite recent evidence that a THA provides better hip function than a hemiarthroplasty.²⁴ In *Study IV*, we wanted to exclude the possibility of acetabular erosion and the pain associated with this erosion, and therefore all patients who participated received a THA.

The BFX stem has been modified compared to the original Bi-Metric design. It is available in uneven sizes only, has a single offset option and has a collar. The first 2 factors are unnecessary limitations of the stem; particularly in males, two

offset options is lacking and the high dislocation rate seen in this study can, in part, be attributed to this fact.

We cannot prove that the collar affects migration. Still, we believe that it makes insertion of the implant safer with regard to the risk of accidentally causing calcar split fractures at final impaction of the stem.

The full HA-coating is probably also advantageous in this patient group since the coating has strong osteoconductive properties. Despite the fact that we only attained a tight fill in the femoral canal in about one third of the hips, all stems were fixated after 3 months. ◉

11.2 DISCUSSION ON METHODS

Risedronate

When *Study III* was planned, the first publications on prevention of bone loss after THA had just been published with alendronate³⁰⁴ and pamidronate.³⁰⁷ Risedronate was, at that time, the only bisphosphonate available with once-weekly administration and had not previously been studied in conjunction with orthopaedic implants in humans.

In addition, in other bisphosphonates, the amino group is open and is thought to be responsible for the increased risk for upper GI effects seen with these drugs. This shielding of the amino group in risedronate may account for the decreased incidence of GI effects in published trials.^{123,203} This, together with its strong antiresorptive potential,¹⁰⁰ led us to using it for *Study III*.

Previously, when trying to decrease the effect of stress-shielding using bisphosphonates, a 6 month treatment regime had been advocated as the greatest bone loss occurs during the initial post-operative period.^{14,336} Arabmotlagh et al.¹² studied the duration of antiresorptive treatment and suggested that the minimum time needed for treatment is 6 months, at least when using alendronate.

Thus, when the trial was designed, our hypothesis was an efficacy up to 2 years with 6 months of treatment and the study was designed accordingly. During the course of *Study III*, results from several new trials involving bisphosphonates and outcome after THA have been published.

TABLE 12. Calcaneal remodelling and its relation to mean (SD) BMD change in zone 7 at 24 months in *Study III*. Despite the wide SDs, the difference between the groups is statistically significant (ANOVA).

Calcar remodeling	% BMD zone 7
No	-6.8 ± 9.4
Calcar round-off	-11.1 ± 14.7
Calcar atrophy	-22.9 ± 12.2

Stability/Fixation score

The Stability/Fixation score used in *Study I-III* is the most commonly used radiological instrument for evaluation of uncemented stems.⁹¹ As in *Study II*, the method is often modified to assess other parameters such as osteolysis and distal cortical hypertrophy.

Developed in the 1980s, before DXA evolved as a quantitative way to measure bone remodeling and RSA became the standard for evaluating migration. The system has a definite “ceiling effect” when it comes to assessing the fixation and stability of a modern Ti-6Al-4V stem with proximal porous coating. Since all stems described in this thesis, according to this score, were fixated/stable (a score of ≥ 0), the BMD measurements should not have been influenced by instability. This is essential for accurate BMD measurements since unstable/loose stems leads to a BMD decrease as has been shown by Bodén et al.³¹

It has proved difficult to draw any definite conclusions from some of these Stability/Fixation-scores. In *Study III*, we found a higher number of endosteal bone bridges (spot welds) in the placebo group resulting in a lower score for the risedronate group. Despite this, all stems were firmly fixed and the amount of migration (measured with EBRA-FCA) did not differ between the two groups.

One possible explanation for this finding could be the higher regional bone resorption identified in the placebo group in which the lower attenuation makes these bone bridges easier to observe on plain x-ray film. Typically, spot welds are found in the proximal regions where the stress-shielding effect is most pronounced and the bone bridges contrast distinctly from the surrounding bone. In the risedronate group, where the stems were also well fixated according to other parameters, the spot welds are blurred by the high attenuation.

Another explanation for this finding is possibly that normally, foci of traumatized and devitalized cancellous bone trabeculae are remodeled post-operatively by osteoclasts followed by an

osteoblast phase. Since risedronate effectively stops the osteoclast response at the interface, we hypothesize that bone repair is slower and probably more homogenous which would explain the absence of spot welds in the risedronate group.

In *Study III*, the presence of pedestal formation or distal cortical hypertrophy did not correlate to BMD gain in the distal zones (3-5), while visible calcar remodelling did correlate to BMD loss in zone 7 (Table 12).

Radiostereometry

RSA, used in *Study IV*, is technically demanding and requires that all aspects of the method are followed meticulously. Few studies have been conducted in which a cohort of elderly patients with hip fractures has been examined using RSA.^{167,198-199} This frail patient group is often difficult to study. In our study 11% of the RSA data was lost due to patients being unable to come to follow-up visits. Some of the data loss can also be explained by technical errors e.g. inability to locate the tantalum markers on both RSA x-rays. This is an acceptable rate when compared to other RSA studies.^{164,300,321}

Dual-energy X-ray Absorptiometry

DXA is the most widely used tool to assess general bone mass and bone resorption due to stress-shielding. The method is highly accurate and, if patients are correctly positioned in the scanner, it is also precise enough to allow for continuous measurements of BMD around implants.

POSITIONING OF THE PATIENTS

The positioning of the patients in the scanner is crucial to achieve a good precision. Leg rotation must be strictly controlled since there is a large variation with different rotations, particularly in Gruen zone 7.⁶⁰ In *Study I, III* and *IV*, a leg holder was used to insure that the femur was in neutral alignment and rotation.

TIMING OF MEASUREMENTS

Retrospective studies using contralateral comparisons such as *Study I* have shown a 40% decrease in proximal femoral BMD after 7-14 years.²⁰²

The retrospective approach is convenient for the researcher but requires that measurements are performed when the bone remodelling has reached a steady state.

In *Study I* we found no correlation between duration of implantation and BMD changes in any zone and we concluded that a longer implant time would not have affected the results. However, in a later study, we have found that, at least in zone 7, the bone loss occurs more rapidly than the normal ageing of the contralateral side in the long-term perspective.³³

Other important aspects of retrospective BMD studies are that the contralateral hip is healthy and that the software is capable of superimposing the exact Gruen zones scanned in the operated hip on the healthy hip. The effect of per-operative bone loss, due to reaming and broaching, can also affect the BMD in retrospective studies.^{162,195}

In *Study III-IV*, we performed longitudinal measurements, as recommended,²⁹⁵ and thereby circumvented the problems described above. ◉

11.3 DISCUSSION ON RESULTS

Study I

In a single cohort of 138 patients examined with DXA 3 years after THA we found femoral periprosthetic proximal bone loss which was related to the stem size used. Despite this, most patients had an excellent clinical outcome, with only 6 patients (4%) complaining of slight thigh pain, and no loosening of any stem occurred.

STEM SIZE AND BONE LOSS

In the original work examining the relationship between stem stiffness and bone loss, Eng and Bobyn assessed bone resorption at 2 years' minimum follow-up using the plain radiographs of 411 patients who received the AML stem.⁸⁵ With regard to stem size, they found a five-fold increase in bone resorption in subjects with the larger stem sizes (stem size ≥ 13.5 mm). They also noted that the extent of the porous coating affects the amount of bone loss. Extensively coated stems transfer more load distally and result in loss of bone over a greater area of the bone-implant interface. Therefore, many stem designs with porous coating are now confined to the metaphyseal region of the stem.

The Bi-Metric stem is one example of a stem which is intended to load proximally (Figure 60). Despite this the bone loss after 3 years in zones 1 and 7 was approximately 20%.³⁰ This is probably due to the fact that the greatest mismatch between femur stiffness and implant stiffness is in these zones. Here, almost all uncemented implants flare to facilitate an immediate rigid fixation during insertion of the implant. This

leads to an exponential increase in stiffness (according to the fourth power size relationship).²⁹ Even for smaller stems, this stiffness exceeds the natural stiffness of the femur by a factor of 10-20, depending on the stem size and the stiffness of the alloy used.

In addition to several studies using semi-quantitative methods on plain radiographs or cadaver femora²⁸⁰ only three studies utilizing DXA to assess the relationship between stem size and bone loss have been published.^{220,237,316} The study by Nishii et al. involved an extensively porous coated CoCrMb stem used in 32 patients who were followed-up for 12 months. They found a clear correlation between stem size and proximal periprosthetic bone loss.²²⁰ In contrast, both Petersen et al.,²³⁷ using a Taperloc Ti-6Al-4V stem in 22 patients, and Yamaguchi et al.,³¹⁶ using two different CoCrMb stems in 44 patients, failed in finding such a correlation. Due to the low number of patients in these studies, it is doubtful whether any of them really had sufficient power to verify or dispute whether size is associated with bone loss.

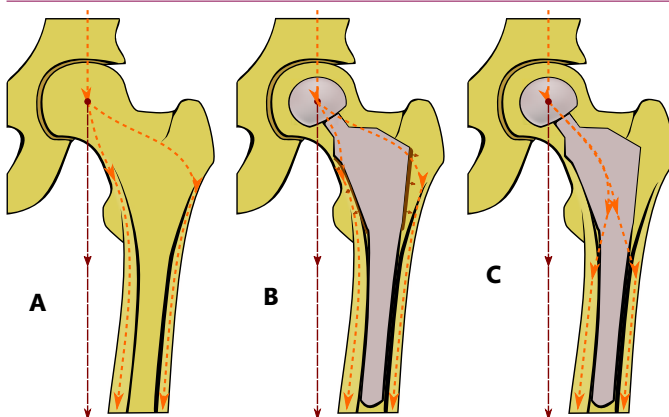


FIGURE 60. The coveted proximal fixation

In A the load on the normal femur. B after insertion of a stem with proximal fixation and C the usual result; distal fixation and off-loading of the proximal femur.

FACTORS AFFECTING PERIPROSTHETIC BONE LOSS

It is evident that there are many other factors influencing the extent of bone loss after THA. Our correlation coefficient squared (r^2) ranged between 0.14 and 0.16, indicating that only 14-16% of the bone loss can be explained by stem size. Factors, besides stem size, that influence periprosthetic bone remodelling after THA include sex,^{7,41} age,⁴¹ weight,¹⁵⁵ BMD,^{7,193,220,246} activity level, diagnosis, disease state, medications, duration of implantation,³³ stem design,²⁴⁶ extent of porous coating,^{85,316} surgical approach²³⁵ and ceramic (HA/TCP) coating.^{47,284}

Researchers have found conflicting results regarding the effect of these co-variables on bone remodelling (Table 13). Brodner et al.,⁴¹ found a correlation between sex and BMD in most Gruen zones, and between age and BMD in Gruen zones 1 and 7. Kärrholm et al.¹⁶⁴ evaluated possible confounding factors (sex, age, weight, diagnosis, BMD and stem size) immediately af-

ter the operation, and found that periprosthetic BMD was influenced only by stem design (the low stiffness composite Epoch stem). However, a follow-up study after 7 years using the same cohort of patients has shown that the difference in BMD tended to disappear over time and was only significant in zone 7.²⁸⁶

The most important predictor for bone loss, verified in *Study III* and *IV*, is the pre-operative BMD of the hip.^{7,193,220,246} In a recently published study, female patients with low systemic BMD had greater bone loss in Gruen zone 7 after uncemented THA than patients with normal BMD,⁷ confirming the interaction between anthropometrical factors and the host bone reaction to the stem.

We found no correlation between anthropometrical factors and BMD loss in *Study I*. This is possibly due to the retrospective design of the study.

TABLE 13. Factors influencing bone loss after uncemented THA. Only in vivo studies with DXA are shown.

Authors	year	n	fu (y)	factor	finding
Kiratli et al. ¹⁵⁷	1996	32	2	weight	low weight was a predictor for bone loss
Nishii et al. ²²⁰	1997	32	2	stem size, BMD	low BMD and larger stem size loose more bone
Yamaguchi et al. ³¹⁶	2000	44	2.5	porous coating	porous coated stems loose more bone in zones 3, 6
Tanzer et al. ²⁸⁴	2001	39	2	ceramic coating (TCP)	smaller bone loss in zone 1, 2 and 7 in TCP group
Kärrholm et al. ¹⁶⁴	2002	68	2	stem stiffness	lower bone loss in zone 1, 2, 6 and 7 in low stiffness group
Brodner et al. ⁴¹	2004	100	5	sex, age	older females lost more bone in zone 1 and 2
Rahmy et al. ²⁶⁴	2004	60	3	stem design, BMD	anatomic stem (zone 4 and 7) and low BMD loose more bone (zone 1-7)
Perka et al. ²³⁵	2005	82	6	surgical approach	transgluteal, compared to abductor split approach, induces more bone loss in zone 1, 2, 6 and 7
Bodén et al. ³³	2006	28	10-14	time	bone loss rate in zone 7 is faster than the normal ageing
Sköldenberg et al. ²⁷¹	2006	138	3	stem size	larger stems loose more bone in zone 1, 2, 6 and 7
Alm et al. ⁸	2009	39	2	sex, BMD	females with low BMD lost more bone in zone 7

Study II

In this retrospective analysis of femoral revision surgery in patients with aseptic loosening, who had moderate pre-revision bone defects, we found a 95% survival rate of the Bi-Metric stem after 6 years and no aseptic loosening of the stem. We also noted that all stems were stable according to the Stability/Fixation score and that the clinical outcome was acceptable.

CLINICAL OUTCOME

Dislocation was the most common complication in our series (9 of 62 hips). We believe that this was caused by our use of 22- to 29-mm head sizes (except in 3 cases in which the head diameter was 32 mm), and the fact that only one femoral offset option was available at the time. We had 4 per-operative fractures during stem insertion and 4 patients suffered post-operative fractures. This serious complication was responsible for all the re-revisions although the rate is lower than in previous reports.^{192,215}

The great proportion of patients were classified as Charnley's functional class C, which contributed to a lower HHS than would have been the case if it were only the operated hip that interfered with their functional capacity (Figure 54). The HHS of 75 points compares favorably with other studies of uncemented femoral revision using stems intended for proximal fixation.^{149,215}

PERIPROSTHETIC BONE REMODELLING

Our radiographic data revealed that the Bi-Metric stem osseointegrates both proximally and distally. We saw several signs of stress-shielding and distal fixation — such as calcar resorption, proximal cortical thinning, proximal osteopenia, and distal cortical hypertrophy — of varying degrees (Figure 61).

Patients who require femoral revision have a lower quality femoral bone stock than patients in need of a primary hip arthroplasty. Because of this, the surgeon also has to use larger diameter stems than in primary surgery to achieve initial stability.

Both these factors will contribute to a more pronounced stress shielding after femoral revision than after a primary arthroplasty and we have extreme examples of this in our study (Figure 28). However, perhaps because of the distal fixation, the longevity of the artificial joint is as-

sured, as is the case with stems designed for distal fixation.^{34,298}

It is also important to mention that both the sensitivity and the specificity of evaluating bone loss on plain radiographs are low. Bone loss is not detectable on plain radiographs until one third of the bone is lost and the loss is not reproducibly recognized by several observers until two-thirds of the bone is resorbed.⁸⁸ Thus, it is sometimes difficult to determine whether bone remodelling seen in the femur is due to osteopenia or to osteolysis.

We have recently published a DXA study of 22 hips from the cohort in *Study II* where we found a marked reduction in BMD in the operated femur in all Gruen zones compared to the healthy, unoperated, side. The largest bone reduction was in zones 1-2 and 6-7 where it was lowered by 36-45%.²

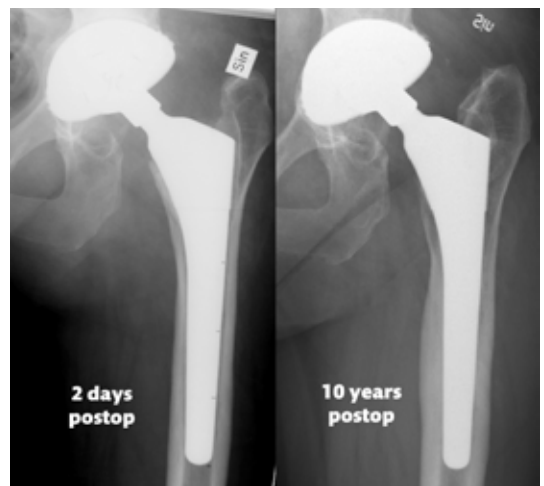


FIGURE 61. Signs of stress shielding and distal fixation: calcar atrophy, distal cortical hypertrophy.

Study III

In patients with OA, 35 mg of oral risedronate taken once weekly for 6 months is effective in reducing femoral periprosthetic bone resorption up to 12 months after THA with a trend towards an effect up to 24 months.

CLINICAL OUTCOME

The clinical outcome in this study was excellent with both groups improving significantly in HHS and EQ-5D. The overall incidence of adverse events during the study period did not differ between the groups. However, 4 subjects in the treatment group experienced either nausea or urticaria which lead to them having to discontinue the risedronate treatment.

This reflects the clinical setting and if patients not taking their medication are excluded from the study, this will boost the effect of the studied drug, something for which most previous studies on prevention of bone loss after THA can be criticized for (Table 14).

PREVENTION OF BONE LOSS

The primary outcome variable, prevention of bone resorption after THA, is, as with migration of implants, a proxy variable for clinical success.

Thillemann et al. recently published a nationwide population-based study examining post-operative use of bisphosphonates and the risk for revision after primary THA in osteoporotic patients.²⁸⁹

A total of 632 patients, who were revised after primary THA were compared to 1262 non-revised controls. No overall difference in risk for

revision due to aseptic loosening was detected between these taking bisphosphonates and these who were not. However, a subgroup analysis of patients with bisphosphonate treatment for more than 240 days, showed a decreased risk for revision.

In *Study III*, we found that patients with a lower pre-operative BMD lost significantly more bone after THA (Figure 56). We found that patients in the placebo group with low pre-operative bone mass had lost 23% and 27% in zones 1 and 7 of the operated hip after 2 years whereas patients with high systemic BMD lost only 14% and 11%, respectively. This is consistent with results from earlier studies showing a correlation between low pre-operative bone mass and increased bone loss around uncemented stems (Table 13).^{10,246}

Our results, together with these of Thillemann et al.²⁸⁹ indicate that prolonged treatment with bisphosphonates after THA in osteoporotic patients is warranted. Since bone loss around THA is suspected to be continuous and occurs more rapidly than normal ageing, at least in zone 7,³³ the length of treatment must be long enough duration so as to be able to reach normal steady-state in bone metabolism. This may even require life-long treatment.

TABLE 14. Studies on bisphosphonates and THA in humans, Study III in the bottom for comparison.

Authors	year	bisphosphonate	n	diagnosis	stem	method	fu (m)	blinding	intention
Venesmaa et al. ³⁰⁴	2001	alendronate	13	OA	UPP	DXA	6	no	n.r.
Wilkinson et al. ³⁰⁷	2001	pamidronate	47	M	CT	DXA/EBRA	6	yes	no
Hennigs et al. ¹³³	2002	alendronate	66	M	UPP/GB	DXA	12	no	n.r.
Nehme et al. ²¹⁹	2003	alendronate	38	N/A	CT	DXA	24	yes	n.r.
Yamaguchi et al. ³³⁸	2003	ethidronate	53	CDH	UFP/UPP	DXA	12	no	no
Yamaguchi et al. ³¹⁷	2004	ethidronate	45	CDH	UFP/UPP	DXA	30	no	no
Wilkinson et al. ³⁰⁶	2005	pamidronate	47	M	CT	DXA/EBRA	24	yes	no
Arabmotlagh et al. ¹²	2006	alendronate	51	OA	UPP/GB	DXA	12	yes	n.r.
Yamasaki et al. ³²⁰	2007	risedronate	40	CDH	UFP/UPP	DXA	6	no	no
Arabmotlagh et al. ¹¹	2009	alendronate	49	M	UPP/GB	DXA	72	no	n.r.
Friedl et al. ¹⁰⁴	2009	zoledronic acid	49	ON	GB	EBRA	36	yes	n.r.
Study III	2010	risedronate	73	OA	UPPH	DXA/EBRA	24	yes	yes

n = sample size diagnosis: = OA=osteoarthritis, M=mixed diagnoses, CDH=congenital dysplasia of the hip, ON=osteonecrosis of the femoral head stem = GB=uncemented grit-blasted, CT=cemented tapered, UFP=uncemented fully porous-coated, UPP=uncemented proximally porous-coated, UPPH=uncemented proximally porous-coated with hydroxyapatite intention = study conducted according to intention-to-treat n.r. = not reported

Study IV

In a cognitively intact cohort of elderly patients with a displaced FNF and who received a new HA-coated stem, we found a favourable migration pattern and stable stems after 3 months post surgery. We also found a continuous decrease in BMD around the stems up to 2 years after surgery.

CLINICAL OUTCOME

During the study one intra-operative femoral fracture occurred (treated conservatively) as well as two implant revisions (1 stem due to infection and 1 cup due to dislocation) were required. The HHS was lower than in *Study I* and *III* and the EQ-5D lower than in *Study III*, but this is to be expected in this patient group and is consistent with other studies done on THA after a FNF.^{24,293}

Despite using the posterior repair technique¹⁶³ and 32 mm heads in all surgeries the dislocation rate was 14%. A high dislocation rate for the posterolateral approach after THA in patients with a FNF has previously been reported.⁹² After the completion of the current trial our Orthopaedic Department has subsequently reduced the dislocation rate by changing to the anterolateral approach for hip arthroplasty in patients with a FNF.²⁶⁹

MIGRATION AND BONE REMODELLING

Despite having individual stems with a large initial migration, all stems had stabilized within 3 months. The migration (Figure 57) was less than,⁴⁹ or equivalent to,²⁸¹ results reported from previous RSA studies of clinically successful uncemented stems. There was however a tendency for a continuous migration (z-rotation and MTPM) at 24 months. This could be attributed to the bone loss that had occurred around the stem.

The best predictor for migration was the BMD around the stem; stems with low surrounding BMD had a significantly higher mean migration than stems with high BMD. The patients who were osteopenic or osteoporotic before the fracture, as confirmed by the BMD of the contralateral femur, had also lost more bone around the stem at 2 years.

This is potentially problematic as this bone loss could lead to loosening of the stem or predispose to a periprosthetic fracture. As this has not been

studied before, we cannot know whether there would be any difference in bone remodelling if we had used a cemented stem.

The migration of, and bone remodelling around, this stem can serve as a reference for other implants in this patient group.

COMPARISON TO OTHER STUDIES

The majority of data available on modern uncemented stems (i.e. excluding Thompson or Austin-Moore types) in patients with a FNF is from single cohort studies.^{15,20,52,156-157,322} They are equivalent to *Study IV* with regards to the age group studied and functional outcome. The rate of calcar split/periprosthetic fractures range between 0-17% and is typically around 4% (Table 15).

There are only 2 trials where HA-coated stems are compared to other stem types^{99,180} and Figved et al. has performed the only randomized study comparing a modern cemented implant (Spectron) and a HA-coated press-fit implant (Corail).⁹⁹ Their study showed equivalence between the groups in HHS after 1 year (their main outcome variable).

The patient selection was similar to that in our study, with a mean age of 83 years, and predominantly female patients. HHS and EQ-5D was similar to our results. They had more intra- and post-operative periprosthetic fractures in the uncemented group, compared to the cemented group; 6% versus 2% after 1 year. They also excluded 4 patients during surgery because they could not achieve primary stability with uncemented fixation of the stem. Despite this, they concluded that both femoral implants could be used with good results in displaced FNFs.

WHY USE UNCEMENTED FEMORAL STEMS IN TREATMENT OF FEMORAL NECK FRACTURES?

The rationale for using these devices for displaced FNFs in osteoporotic elderly patients, often with a stove-pipe femur, is mainly theoretical. During pressurization, cement and fat embolism are known to occur^{57,243} and can have an impact on mortality.^{173,231} Nevertheless, we acknowledge that there are several potential problems which may occur when using an uncemented stem in this patient group. The most obvious is the increased risk for periprosthetic fractures, occurring either intra-operative as in our series of Bi-Metric stems (chapter 3.7), or, perhaps due to the above described periprosthetic bone loss, late presenting after minor trauma.

In our trial, we had only one fracture; a femoral crack distal to the tip of the prosthesis. We had no femoral split fractures or calcar fractures. However, all the surgeons who performed the operations in this trial were experienced hip surgeons, and therefore it is uncertain as to whether these results can be reproducible in a standard clinical setting.

The risk for femoral split fractures is perhaps also implant-specific; the most commonly used uncemented stem for FNFs in Sweden is a press-fit type (Corail®), where the technique is to use increasing sizes of broaches and to impact as much cancellous bone as possible. ◉

In a coming report from the Swedish Hip Arthroplasty Register, modern HA-coated uncemented stems used for hemiarthroplasty in this elderly population are, compared to modern cemented stems, associated with an increased risk for revision due to femoral fractures (odds ratio 3.8, 95%CI 2.0-7.1).¹¹⁰ Similar results can be seen from the Australian National Arthroplasty Register where uncemented stems in fracture patients have a significantly higher risk for revision compared to cemented stems.¹¹⁷

TABLE 15. Studies on modern uncemented stems in FNFs with the current study for comparison.

Authors	stem	year	coating	type	trial	fu (y)	n	age	fx (%)	rev	HHS	appr	disl (%)
Livesley ¹⁸⁰	JRI/Austin-Moore	1993	HA	BHA	RCT	1	48	81	17/0	2/1	n.r.	n.r.	4
Bezawada ²⁰	Taperloc	2004	PP	BHA	PSC	3.5	168	77	0	2	82	n.r.	n.r.
Klestil ¹⁵⁷	Zweimüller	2006	GB	UHA	PSC	2	46	76	0	0	n.r.	AL	0
Klein ¹⁵⁶	Taperloc, Accolade	2006	PP	THA	RSC	3.8	85	78	4	0	82	AL	4
Chandran ⁵²	Furlong	2006	HA	BHA	RSC	4	112	78	2	5	n.r.	AL	n.r.
Öztürkmen ²²²	F40, Helios	2008	FP	BHA	RSC	4.2	48	88	n.r.	1	84	PL	2
Barnett ¹⁵	Corail	2009	HA	THA	PSC	1	46	72	7	0	n.r.	AL	0
Figved ⁹⁹	Corail/Spectron	2009	HA	BHA	RCT	1	200	83	6/3	2/1	79/80	PL	5
Study IV	BFX	2010	HA	THA	PSC	2	50	81	2	1	82	PL	14

coating: HA=hydroxyapatite-coated, FP=fully porous-coated, PP=proximally porous-coated, GB=grit-blasted
 type: THA=total hip arthroplasty, UHA=unipolar hemiarthroplasty, BHA=bipolar hemiarthroplasty
 trial: PSC=prospective single cohort, RSC=retrospective single cohort, RCT=randomized controlled trial
 fu: follow-up
 fx: intra- and post-operative periprosthetic fractures (%)
 rev: stem revisions (n)
 HHS: Harris hip score (mean)
 appr: surgical approach, AL=anterolateral, PL=posterolateral
 disl: dislocation rate (%)
 n.r.: not reported

11.4 STRENGTHS AND LIMITATIONS

Study I

Though the majority of patients who participated in the study underwent surgery for OA (89%), several other diagnoses were also included in the study, for example, congenital dysplasia of the hip (CDH) and post-traumatic arthritis. This is a potential source of error as patients with CDH may have a different pre-operative BMD of the hip compared to patients with OA.²²³ We have, also, analyzed the data using only subjects with OA and the results were the same as those for the overall study (data not shown).

Study I is a cross-sectional study in which peri-prosthetic BMD is compared to the value of the unaffected side. This could be a possible source for error as there may exist a side-related difference in bone mass pre-operatively. Some studies have shown findings that indicate a lower BMD in the Gruen zones 1-7 on the affected side before operation.^{155,195} In addition, the initially BMD can be high due to the impaction of cancellous bone.

Thus, the BMD difference found in cross-sectional studies may be either under- or overestimated. In the longitudinal *Study III*, we found very similar BMD changes in the placebo group when compared to the findings in *Study I*. This may indicate that these possible sources of error may not be as important.

We did not assess the patients general bone mass by scanning the lumbar spine or total hip, as was done in *Study III-IV*, and could therefore not verify, or disprove, the impact of this on the periprosthetic BMD.

We used both uncemented and cemented acetabular cups in *Study I-III* but we could not find any correlation between mode of fixation and BMD change or bone remodelling parameters. From a previous study however, it is known that different bearing materials, in the short-term perspective, do not affect BMD of the proximal femur.²²²

As in *Study II*, it was not possible to assess the HHS prior to surgery due to the retrospective

design. However, the majority of patients had an excellent HHS at follow-up and no relation to BMD change was found.

The main strength of our study is the large sample size that, despite its limitations has enabled us to verify the relationship between stem size and bone loss in vivo which has previously been hypothesized.⁸⁵

Study II

The same limitations regarding the retrospective designs mentioned above also apply for *Study II*. In addition to these, differences in cup fixation, the lack of pre-operative HHS data and the method of assessing radiographic bone remodelling parameters can also be regarded as limitations.

As previously mentioned (chapter 11.2) the Stability/Fixation score used in *Study I-III* has limitations regarding its ability to accurately identify subtle changes in bone loss or stem migration over time. The method cannot, as with RSA, be used as a predictor of revision. However, because of its easy availability, and the possibility of using it in retrospective studies, it is still widely used in orthopaedic research.

The semi-quantitative method of describing radiographically visible bone remodelling changes also has the advantage of the intuitive understanding of the biological response of the proximal femur to the stem.

The strengths of the study lie in the fact that we were able to examine all patients and the relatively large sample size for a revision arthroplasty study.

Study III

Unfortunately, the intention-to-treat analysis was not perfect; we had to exclude 3 patients who suffered an undisplaced calcar split fracture during surgery. All were treated with protected weight bearing for 6 weeks and their later clinical outcome was excellent. They were excluded because the fracture healing would interfere with the BMD analysis.

Another limitation of the study is the 2 different concepts used in the fixation of the acetabular component. The method used to assess the migration of our implants, EBRA, has a lower resolution than RSA, and, even though one study, using EBRA, has shown less migration of uncemented acetabular components after bisphosphonate treatment,¹⁰⁴ another study, has failed to do so.³⁰⁶ For TKA, the mean effect of bisphosphonate treatment is in the magnitude of 0.1 mm^{122,134} which is too small to be detected by EBRA.

The strengths of our study include a high follow-up rate and a large sample size. To our knowledge, this is the largest randomized clinical trial studying the effect of bisphosphonates after an arthroplasty. In addition, the study was double-blinded and analysis of efficacy was done according to the intention-to-treat principle, an approach that has not been used, or reported, in most previously published studies.^{304,307,317-318,320}

As a result of the prospective design, we were also able to obtain consistent and reliable BMD data with which to calculate the effect of treatment.

Study IV

To assess the influence of the injury on clinical outcome scores (HHS, EQ-5D and PNRs), the patients were asked to report their prefracture status when they were included in the study. The patients' ability to correctly evaluate this while waiting for acute surgery may be questioned. It is however impossible to collect this data in a prospective manner and the method is generally used in studies on trauma patients e.g. hip fracture patients.^{14,253,293}

As this was a pilot study of a new medical device, only patients with intact cognitive function were included. This had consequences for the sample as we had to screen 229 patients in order to include the 50 patients studied. It also meant that our cohort is relatively healthy, and our mortality rate of 4% and the loss of follow up rate of 10% is low compared to other hip fracture studies.^{82,135,185,197} However, we were able to include patients with a mean age and general bone mass that is representative for patients with a displaced FNF since the majority of patients were either osteopenic or osteoporotic.

The strengths of the study are, for an RSA study, the large sample size and the quality of data acquired in using both RSA and DXA to evaluate migration and bone remodelling. ⊙

11.5 GENERAL DISCUSSION

Clinical relevance of bone remodelling

It is apparent that there is a BMD decrease in the proximal femur after uncemented THA. What is more uncertain is the interpretation of this phenomenon. Is it a benign, natural response to off-loading in accordance with Wolff's law³⁰⁹ that is necessary for the longevity of these devices? Or is it a potential catastrophe that, several decades from now, will result in increased numbers of periprosthetic fractures and high revision rates?

In earlier studies of extensively porous-coated stems, not only was the revision rate high, presumably due to massive bone resorption, but the acetabular components were also plagued with high wear rates and inferior fixation.

This made it almost impossible to identify which implants required revision due to disuse atrophy and which were revised as a result of wear and/or osteolysis.

As yet, no studies have shown a correlation between periprosthetic BMD decrease and revision rate or clinical outcome. Such a study would require a large number of patients and a follow-up of at least 10 years. If performing longitudinal DXA scans, it would also be difficult to distinguish BMD decrease from osteolytic lesions.

There is however, an intuitive sense that bone loss over time cannot have a positive effect on the longevity of the implant. There is also the debate as to whether this makes patients susceptible to wear induced osteolysis or that it increases the risk for periprosthetic fracture, the incidence of which may be increasing.¹⁷⁸⁻¹⁷⁹

It is evident from the literature that as of yet there is no definitive explanation for the large individual variation of periprosthetic BMD change after surgery. In this thesis, the BMD in the proximal zones varies between +11% and -37% 2 years after surgery for individual patients (Figure 62).

Even though anthropometrical,^{41,155} surgical,²³⁵ and implant related factors^{246,271} affect bone loss, it is still impossible to predict the individual patient's outcome with regards to this bone remodelling. A patient's susceptibility to osteolysis has recently been shown to be associated with individual differences in response to immune stimuli.¹¹⁶ Perhaps this susceptibility

could also apply for adaptive bone remodelling due to stress shielding. Orthopaedic researchers clearly need to focus more on the actual biological response of the host bone after THA.

The most important predictor for bone loss, an initial low BMD, clearly shown in *Study III* and *IV*, incorporates several factors. The lower strength of the bone creates a mismatch in stiffness between the implant and bone, thereby increasing the stress-shielding. Secondly, osteoporosis in itself disrupts the bone micro-architecture and makes patients even more susceptible to bone loss.

In addition, osteoporosis is a disease caused by the effects of a sex steroid deficiency, aging osteoblasts, impairment of the growth hormone/insulin-like growth factor axis and a long list of secondary causes.^{58,262} Whether these biological factors also influence periprosthetic bone loss after THA has not yet been studied.

Study I shows that Ti-6Al-4V stems induce bone loss that is related to the size (and thereby stiffness) of the implant. In terms of patient outcome, it has been suggested that larger diameter stems cause an increased frequency of thigh pain.³¹³ Though, in a recent report from a study done on a large number of patients, no correlation was found between stem size and revision, loosening, pain, or patient satisfaction for the extensively porous-coated AML stem.⁸⁹

The authors concluded that patients with large-diameter, extensively porous-coated femoral components were no more likely to require revision or have thigh or activity-limiting pain than patients with smaller stems. This compares favorably with our results from *Study I-IV*, where the patients with larger stems have the

same clinical outcome and HHS as these with smaller stems.

The choice of stem size per-operatively is ultimately not decided by the surgeon, it is the anatomical characteristics of the femur which dictates the size to be used to achieve initial stability and subsequently bony ingrowth. In *Study II* this is evident, where large diameter stems were frequently used due to the presence of large bone defects at revision caused by the loosening process. Since the initial stability is crucial, downsizing implants is not an option.

Design variations such as ultra-short stems,⁴ only proximally porous coated stems,³³ custom made stems,²¹⁴ isoelastic stems¹⁶⁴ etc. have all shown a moderate effect on bone loss. The only clinically successful stem with an elasticity close to that of the femur (Epoch) has a bone loss after 7 years which is equivalent to that of the Bi-Metric stem.²⁸⁶ A more aggressive post-operative weight bearing regime also seems to be of limited benefit.^{30,287}

Our concern regarding this bone loss is that it, alone, or in combination with wear particles from the polyethylene liner, may facilitate the development of osteolysis, with a periprosthetic fracture as the ultimate consequence. We have, as has been previously mentioned, several such cases at our department (Figure 29).

In the literature however, it is, with few exceptions,¹³⁷ difficult to find reports on this phenomenon. In addition, periprosthetic fracture is a

well-known complication for all elderly patients with a long-lasting THA, whether it be cemented or uncemented.

Our results after risedronate treatment should indicate that there may be an indication for bisphosphonate treatment in patients with a low pre-operative BMD or these with manifest osteoporosis. The recently published study by Thillemann et al.²⁸⁸ points in this direction.

However, no results from a sufficiently sized randomized controlled trail (RCT) with bisphosphonate treatment after THA yet been published. To our knowledge no such study is presently being conducted. Such a trial would require clinically relevant end points, such as, reduction of fracture or revision risk.

In the original work on risedronate for prevention of hip fractures²⁰³ a 4.8% and 3.4% increase in BMD in the greater trochanter and femoral neck, roughly equivalent to Gruen zones 1 and 7, corresponded to a 70% reduction in hip fracture risk during a 3 year period (absolute risk reduction 1.1%). Assuming the effect was the same as in the original study with risedronate,²⁰³ a study done on a high-risk patient group for periprosthetic fracture¹⁷⁸ would still require a sample size of at least 2.000 patients. Though in selected patients group, such as hip revision surgery, where the risk of periprosthetic fracture is significantly elevated, fewer patients would be needed.

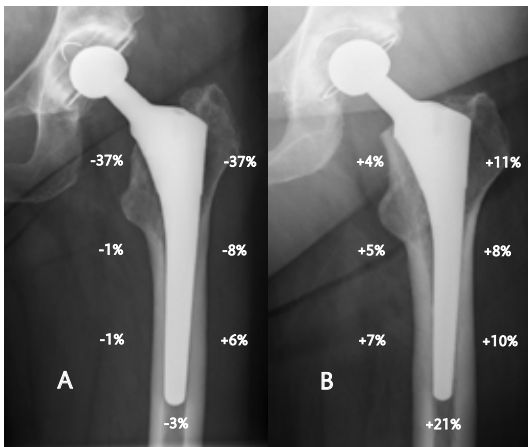


FIGURE 62. The mystery of individual variation in periprosthetic bone remodelling

Two female patients, 65 and 67 years of age, both with a normal preoperative BMD and who got the same stem size implanted. Both are from the placebo group of Study III. After 2 years, the BMD decrease is significant in patient A, while patient B has an increased BMD. Also note that there are very few radiological signs of this change in BMD: calcar atrophy in A and a minimal distal cortical hypertrophy in B.

Uncemented stems for patients with a femoral neck fracture

*Are there any benefits in using a modern uncemented stem to treat FNFs in the elderly?
Is the increased risk of fracture offset by a lower mortality for uncemented stems?*

In *Study IV*, we have implemented the recommended stepwise introduction of new implants (chapter 3.3).¹⁸⁹⁻¹⁹⁰ We used two methods validated for fixation of implants and bone remodelling, that is, RSA and DXA. To our knowledge, no other study using such a combination of high-precision methods to evaluate a new hip prosthesis in osteoporotic patients with a FNF is being carried out.

It must be noted, however, that the results of this study should be interpreted with caution as there is no control group. The study was designed as a pilot study and therefore cannot give any answer to questions regarding differences in fracture or mortality risk for uncemented versus cemented femoral stems in this patient group.

Parvizi et al. reviewed the records of 23 patients (out of 38,488 procedures performed) who had died intra-operatively during hip ar-

throplasty at the Mayo Clinic 1969-1997.²³² All deaths occurred in patients receiving cemented implants and the majority (n=14) of patients were being treated for a FNF. The autopsies of 13 of these patients revealed bone marrow microemboli (n=11) and PMMA particles (n=3) in the lungs. By using methods to avoid femoral pressurization, such as thorough lavage and a low pressure cementing technique, the intra-operative mortality rate was reduced significantly.

Vacuum mixing of bone cement, as opposed to using hand-mixing in a bowl, can also help to reduce mortality.¹⁷²

In another analysis of the same large cohort of patients, Parvizi and co-workers later found increased thirty-day mortality following cemented rather than uncemented arthroplasty in patients with a FNF. The risk was 8 times greater in the cemented group after adjustments for other comorbidity factors.²³¹

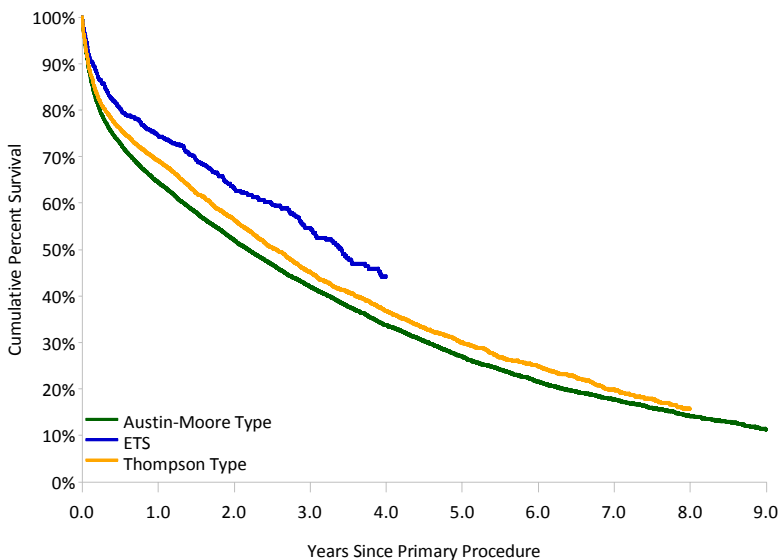


FIGURE 63. Cumulative percent patient survival after hemiarthroplasty for FNFs in Australia

ETS (Exeter trauma Stem) and Thompson stems are fixated with bone cement, whereas Austin-Moore is uncemented. Reprinted with permission from the Australian Orthopaedic Association National Joint Replacement Registry. Annual Report 2010.

However, no recent studies with sufficiently large sample size have been done on this patient group looking specifically at mortality, and taking into account the recent advancements in anesthesia and cementing technique.

Studies on this topic have, up until now, had an impact on the choice of uncemented versus cemented technique in patients with FNFs. This is the probable explanation for the paradox in the Australian Hip Arthroplasty Register (Figure 63).

Here, patients operated with the uncemented Austin-Moore stem have a small, but statistically significant, elevated mortality rate after surgery, first apparent after one year. The most likely explanation for this is selection bias by the surgeons who tend to select the patients with most co-morbidities for uncemented fixation.

In the same register, the revision rate for uncemented hemiarthroplasties, compared to cemented, is significantly elevated with a 3-5 fold

increased revision risk during the first years after surgery (Figure 64).¹¹⁷

The fear of increased mortality with cemented implants can thus lead to an increased revision burden due to poor fixation and periprosthetic fractures in elderly patients with uncemented implants.

Despite the fact that a HA-coated femoral stem, as in *Study IV*, can work quite well in osteoporotic patients with a FNE, there is still little evidence to recommend it. The high rate of calcar split/periprosthetic fractures reported in this patient group is a risk that is perhaps unacceptable when we consider the low risk of adverse events occurring during cementation of the stem.

Additional research should, in the context of multicentre randomized trials or population-based register studies, focus on whether uncemented HA-coated femoral stems are inferior, equivalent or superior to cemented stems in the treatment of FNFs in the elderly. ◉

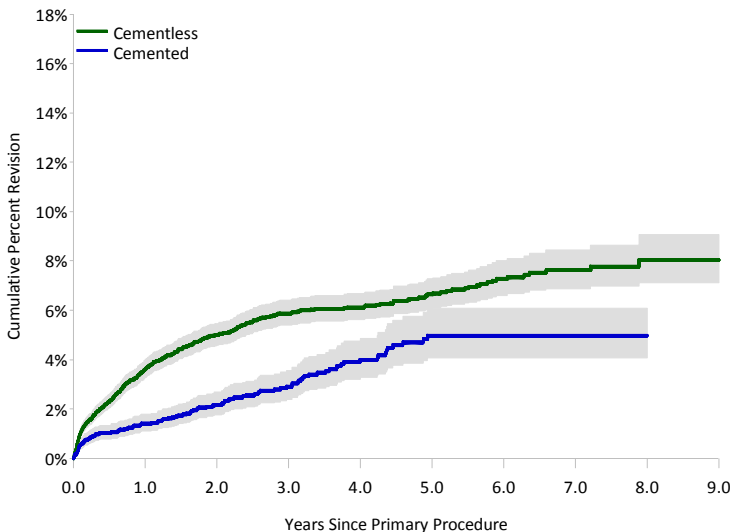


FIGURE 64. Cumulative percent revision of uncemented and cemented hemiarthroplasty for FNFs in Australia.

Reprinted with permission from the Australian Orthopaedic Association National Joint Replacement Registry. Annual Report 2010.

12 CONCLUSIONS

- I Periprosthetic proximal bone loss after THA using an uncemented tapered proximally porous- and hydroxyapatite coated femoral stem is related to the stem size used.
- II In patients with moderate pre-revision bone defects, femoral revision surgery with an uncemented tapered proximally porous- and HA- coated femoral stem is a reliable procedure in the mid-term perspective.
- III Risedronate given once weekly for 6 months after THA is effective in preventing periprosthetic proximal bone loss after THA around an uncemented femoral stem up to 12 months, with a trend towards an effect up to 24 months post-operatively.
- IV The short time results from this study indicate that the new femoral stem can be used for elderly patients with osteoporotic fractures of the femoral neck. ◉

13 IMPLICATIONS FOR FUTURE RESEARCH

- * Large population based studies and RCTs studying bisphosphonate treatment in conjunction with THA and TKA.
- * High-sensitivity C-reactive protein is a significant and independent risk predictor of non-traumatic fracture, strengthening the hypothesis of a tight interplay between low-grade inflammation and bone turnover.^{50,261} It has never been studied in conjunction with periprosthetic bone loss.
- * Further adequately-powered RCTs comparing modern uncemented stems with cemented for elderly patients with a FNF. The studies should be large enough to ascertain whether there are differences in clinical outcome, hip function and quality of life between the two methods of fixation.
- * Further DXA studies on bone remodelling after THA for OA and FNFs, studying differences between modes of fixation and stem geometry.
- * Future studies of bisphosphonate treatment after THA should focus on patients who have both osteoarthritis and a low BMD of the hip.
- * Denosumab is a fully human monoclonal antibody to RANKL that blocks its binding to RANK, inhibiting the development and activity of osteoclasts. It is administered subcutaneously every 6 months and reduces the risk of vertebral, non-vertebral, and hip fractures in women with osteoporosis.⁶³ Its mechanism of action makes it highly interesting for treatment of both periprosthetic bone loss and wear-induced osteolysis. ◉

14 ACKNOWLEDGEMENTS

I gratefully acknowledge the help of all my colleagues and the staff at Danderyds Hospital. I especially want to thank:

PER ADOLPHSON

My supervisor throughout this thesis. For his support and enthusiasm over the years. For always being there when I need him. Thank you!

TORBJÖRN AHL

My co-supervisor throughout this thesis. For his unending passion and knowledge in the field of orthopaedic surgery, his constant curiosity in attaining new knowledge and for being a true friend in clinical matters.

GUSTAF NEANDER AND ULF LILLKRONA

The present and former head of the Orthopedic Department at Danderyd hospital, for your constant support in resources and time for me to do thesis.

MATS SALEMYR

My co-author and head of the Joint Replacement Unit, for his dynamic work in constantly improving our work and research.

HENRIK BODÉN

My dear colleague, co-author and research friend for his thoughtful ideas on life in general and research in particular.

HELENE SJÖÖ AND PAULA KELLY-PETTERSSON

The research nurses at the Orthopaedic Department of Danderyd Hospital. You are, without a doubt, the most competent and pleasant professional individuals I have ever met. It is safe to say, that without you, this thesis would not exist. You are both the reason why I love going to work every day. Thank you!

HANS-JERKER LUNDBERG

The physicist responsible for all the DXA measurements in this thesis. For your immense support, passion in all matters of DXA-related issues and your problem solving capacity.

ARNE LUNDBERG

My co-author in *Study IV* for teaching me the basics of the RSA-method.

EVA HOFMAN AND LISE-LOTTE WIDMARK

For all the help with the RSA examinations over the years.

MAX GORDON

For your enthusiasm over orthopedic research and for your help with the illustrations in this thesis.

OLLE MUREN

My clinical mentor, for your support and for teaching me orthopedics.

ANDRÉ STARK

The new professor at the Orthopaedic Department at Danderyd Hospital. For your vigorous enthusiasm over research making it hard even for me to keep up!

THOMAS EISLER

For valuable input on the mystery of spot welds and the abstract.

AGNETA SÖDERBERGH

From Sanofi/Aventis for help with the risedronate and placebo tablets in Study III

ANDERS HAHN

From Biomet for help with the RSA-markings of the stem in Study IV

PER GRUNDSTRÖM

From RSA Biomedical for support with the RSA method.

ALL MY FRIENDS

Whom I have sadly neglected during the writing of this thesis, I will be back!

BENGT SKÖLDENBERG

My late father whom I love and miss so much.

BIRGIT SKÖLDENBERG

My mother, for your continuous support and inspiration. I finally understand what the fuss about research is all about!

ERIK SKÖLDENBERG

My brother and his lovely family Anette, Elsa, Siri and Love, for giving me and my family a happy life.

EBBA SKÖLDENBERG

My dear sister, for always being there.

GABRIELLA AND ELLIOT

My beloved family, you are the true meaning of my life.

15 REFERENCES

- Acklin YP, Berli BJ, Frick W, Elke R, Morscher EW. Nine-year results of Muller cemented titanium Straight Stems in total hip replacement. *Arch Orthop Trauma Surg.* 2001;121(7):391-8.
- Adolphson PY, Salemyr MO, Sköldenberg OG, Boden HS. Large femoral bone loss after hip revision using the uncemented proximally porous-coated Bi-Metric prosthesis: 22 hips followed for a mean of 6 years. *Acta Orthop.* 2009;80(1):14-9.
- Agata H, Asahina I, Yamazaki Y, Uchida M, Shinohara Y, Honda MJ, et al. Effective bone engineering with periosteum-derived cells. *J Dent Res.* 2007;86(1):79-83.
- Albanese CV, Santori FS, Pavan L, Learmonth ID, Passariello R. Periprosthetic DXA after total hip arthroplasty with short vs. ultrashort custom-made femoral stems: 37 patients followed for 3 years. *Acta Orthop.* 2009;80(3):291-7.
- Albrektsson T, Albrektsson B. Osseointegration of bone implants. A review of an alternative mode of fixation. *Acta Orthop Scand.* 1987;58(5):567-77.
- Albrektsson T, Branemark PI, Hansson HA, Lindstrom J. Osseointegrated titanium implants. Requirements for ensuring a long-lasting, direct bone-to-implant anchorage in man. *Acta Orthop Scand.* 1981;52(2):155-70.
- Alm JJ, Makinen TJ, Lankinen P, Moritz N, Vahlberg T, Aro HT. Female patients with low systemic BMD are prone to bone loss in Gruen zone 7 after cementless total hip arthroplasty. *Acta Orthop.* 2009;80(5):531-7.
- Amstutz HC, Campbell P, Kossovsky N, Clarke IC. Mechanism and clinical significance of wear debris-induced osteolysis. *Clin Orthop Relat Res.* 1992(276):7-18.
- Apel DM, Smith DG, Schwartz CM, Paprosky WG. Threaded cup acetabuloplasty. Early clinical experience. *Clin Orthop Relat Res.* 1989(241):183-9.
- Arabmotlagh M, Hennigs T, Warzecha J, Rittmeister M. Bone strength influences periprosthetic bone loss after hip arthroplasty. *Clin Orthop Relat Res.* 2005;440:178-83.
- Arabmotlagh M, Pilz M, Warzecha J, Rauschmann M. Changes of femoral periprosthetic bone mineral density 6 years after treatment with alendronate following total hip arthroplasty. *J Orthop Res.* 2009;27(2):183-8.
- Arabmotlagh M, Rittmeister M, Hennigs T. Alendronate prevents femoral periprosthetic bone loss following total hip arthroplasty: prospective randomized double-blind study. *J Orthop Res.* 2006;24(7):1336-41.
- Baad-Hansen T, Kold S, Kaptein BL, Soballe K. High-precision measurements of cementless acetabular components using model-based RSA: an experimental study. *Acta Orthop.* 2007;78(4):463-9.
- Baker RP, Squires B, Gargan MF, Bannister GC. Total hip arthroplasty and hemiarthroplasty in mobile, independent patients with a displaced intracapsular fracture of the femoral neck. A randomized, controlled trial. *J Bone Joint Surg Am.* 2006;88(12):2583-9.
- Barnett AJ, Burston BJ, Atwal N, Gillespie G, Omari AM, Squires B. Large diameter femoral head uncemented total hip replacement to treat fractured neck of femur. *Injury.* 2009;40(7):752-5.
- Bauer DC, Black DM, Garnero P, Hochberg M, Ott S, Orloff J, et al. Change in bone turnover and hip, non-spine, and vertebral fracture in alendronate-treated women: the fracture intervention trial. *J Bone Miner Res.* 2004;19(8):1250-8.
- Beck TJ, Mourrada FA, Ruff CB, Scott WW, Jr., Kao G. Experimental testing of a DEXA-derived curved beam model of the proximal femur. *J Orthop Res.* 1998;16(3):394-8.
- Berry DJ, Harmsen WS, Cabanela ME, Morrey BE. Twenty-five-year survivorship of two thousand consecutive primary Charnley total hip replacements: factors affecting survivorship of acetabular and femoral components. *J Bone Joint Surg Am.* 2002;84-A(2):171-7.
- Berry DJ, Harmsen WS, Ilstrup D, Lewallen DG, Cabanela ME. Survivorship of uncemented proximally porous-coated femoral components. *Clin Orthop Relat Res.* 1995(319):168-77.
- Bezwaada HP, Shah AR, Harding SH, Baker J, Johanson NA, Mont MA. Cementless bipolar hemiarthroplasty for displaced femoral neck fractures in the elderly. *J Arthroplasty.* 2004;19(7 Suppl 2):73-7.
- Biedermann R, Krismer M, Stockl B, Mayrhofer P, Ornstein E, Franzen H. Accuracy of EBRA-FCA in the measurement of migration of femoral components of total hip replacement. Einzel-Bild-Röntgen-Analyse-femoral component analysis. *J Bone Joint Surg Br.* 1999;81(2):266-72.
- Bilezikian JP. Efficacy of bisphosphonates in reducing fracture risk in postmenopausal osteoporosis. *Am J Med.* 2009;122(2 Suppl):S14-21.
- Bloebaum RD, Beeks D, Dorr LD, Savory CG, DuPont JA, Hofmann AA. Complications with hydroxyapatite particulate separation in total hip arthroplasty. *Clin Orthop Relat Res.* 1994(298):19-26.
- Blomfeldt R, Törnkvist H, Eriksson K, Söderqvist A, Ponzer S, Tidermark J. A randomised controlled trial comparing bipolar hemiarthroplasty with total hip replacement for displaced intracapsular fractures of the femoral neck in elderly patients. *J Bone Joint Surg Br.* 2007;89(2):160-5.
- Bobynd JD, Glassman AH, Goto H, Krygier JJ, Miller JE, Brooks CE. The effect of stem stiffness on femoral bone resorption after canine porous-coated total hip arthroplasty. *Clin Orthop Relat Res.* 1990(261):196-213.
- Bobynd JD, Pilliar RM, Cameron HU, Weatherly GC. The optimum pore size for the fixation of porous-surfaced metal implants by the ingrowth of bone. *Clin Orthop Relat Res.* 1980(150):263-70.
- Bobynd JD, Stackpool GJ, Hacking SA, Tanzer M, Krygier J. Characteristics of bone ingrowth and interface mechanics of a new porous tantalum biomaterial. *J Bone Joint Surg Br.* 1999;81-B(5):907-14.
- Bobynd JD, Tanzer M, Glassman AH. Stress-related Bone Resorption. In: Shanbhag A, et al., editors. *Joint Replacement and Bone Resorption.* New York: Taylor & Francis Group; 2006. p. 13-52.
- Bodén H. A Clinical Study of Uncemented Hip Arthroplasty. Radiological findings of host-bone reaction to the stem.: Karolinska Institute; 2006.
- Bodén H, Adolphson P. No adverse effects of early weight bearing after uncemented total hip arthroplasty: a randomized study of 20 patients. *Acta Orthop Scand.* 2004;75(1):21-9.

31. **Bodén H, Adolphson P, Öberg M.** Unstable versus stable uncemented femoral stems: a radiological study of periprosthetic bone changes in two types of uncemented stems with different concepts of fixation. *Arch Orthop Trauma Surg.* 2004;124(6):382-92.
32. **Bodén H, Salemyr M, Sköldenberg O, Ahl T, Adolphson P.** Total hip arthroplasty with an uncemented hydroxyapatite-coated tapered titanium stem: results at a minimum of 10 years' follow-up in 104 hips. *J Orthop Sci.* 2006;11(2):175-9.
33. **Bodén H, Sköldenberg O, Salemyr M, Lundberg H, Adolphson P.** Continuous bone loss around a tapered uncemented femoral stem: a long-term evaluation with DEXA. *Acta Orthop.* 2006;77(6):877-85.
34. **Bohm P, Bisschel O.** Femoral revision with the Wagner SL revision stem : evaluation of one hundred and twenty-nine revisions followed for a mean of 4.8 years. *J Bone Joint Surg Am.* 2001;83-A(7):1023-31.
35. **Borlin N, Rohrl SM, Bragdon CR.** RSA wear measurements with or without markers in total hip arthroplasty. *J Biomech.* 2006;39(9):1641-50.
36. **Bourne RB, Rorabeck CH, Ghazal ME, Lee MH.** Pain in the thigh following total hip replacement with a porous-coated anatomic prosthesis for osteoarthritis. A five-year follow-up study. *J Bone Joint Surg Am.* 1994;76(10):1464-70.
37. **Bourne RB, Rorabeck CH, Patterson JJ, Guerin J.** Tapered titanium cementless total hip replacements: a 10- to 13-year followup study. *Clin Orthop Relat Res.* 2001(393):112-20.
38. **Boyer P, Lazennec JY, Poupon J, Rousseau MA, Ravaud P, Catonne Y.** Clinical and biological assessment of cemented titanium femoral stems: an 11-year experience. *Int Orthop.* 2009;33(5):1209-15.
39. **Bragdon CR, Thanner J, Greene ME, Malchau H, Digas G, Harris WH, et al.** Standing versus supine radiographs in RSA evaluation of femoral head penetration. *Clin Orthop Relat Res.* 2006;448:46-51.
40. **Branemark PI, Hansson BO, Adell R, Breine U, Lindstrom J, Hallen O, et al.** Osseointegrated implants in the treatment of the edentulous jaw. Experience from a 10-year period. *Scand J Plast Reconstr Surg Suppl.* 1977;16:1-132.
41. **Brodner W, Bitzan P, Lomoschitz F, Krepler P, Jankovsky R, Lehr S, et al.** Changes in bone mineral density in the proximal femur after cementless total hip arthroplasty. A five-year longitudinal study. *J Bone Joint Surg Br.* 2004;86(1):20-6.
42. **Brooker AF, Bowerman JW, Robinson RA, Riley LH, Jr.** Ectopic ossification following total hip replacement. Incidence and a method of classification. *J Bone Joint Surg Am.* 1973;55(8):1629-32.
43. **Brooks R.** EuroQol: the current state of play. *Health Policy.* 1996;37(1):53-72.
44. **Brown SR, Davies WA, DeHeer DH, Swanson AB.** Long-term survival of McKee-Farrar total hip prostheses. *Clin Orthop Relat Res.* 2002(402):157-63.
45. **Burström K, Johannesson M, Diderichsen F.** Swedish population health-related quality of life results using the EQ-5D. *Qual Life Res.* 2001;10(7):621-35.
46. **Butel J, Robb JE.** The isoelastic hip prosthesis followed for 5 years. *Acta Orthop Scand.* 1988;59(3):258-62.
47. **Boe B, Heier T, Snorrason L, Nordsetten L.** A clinical study comparing electrochemically deposited hydroxyapatite and plasma sprayed hydroxyapatite on titanium stems. 2 years follow-up with RSA and DXA in 55 hips. A prospective randomized study. *Acta Orthop.* 2010.
48. **Callaghan JJ, Dysart SH, Savory CG.** The uncemented porous-coated anatomic total hip prosthesis. Two-year results of a prospective consecutive series. *J Bone Joint Surg Am.* 1988;70(3):337-46.
49. **Campbell D, Mercer G, Nilsson KG, Wells V, Field JR, Callary SA.** Early migration characteristics of a hydroxyapatite-coated femoral stem: an RSA study. *Int Orthop.* 2009.
50. **Cauley JA, Danielson ME, Boudreau RM, Forrest KY, Zmuda JM, Pahor M, Tylavsky FA, Cummings SR, Harris TB, Newman AB.** Inflammatory markers and incident fracture risk in older men and women: the Health Aging and Body Composition Study. *J Bone Miner Res.* 2007;22(7):1088-95.
51. **Chandler HP, Reineck FT, Wixson RL, McCarthy JC.** Total hip replacement in patients younger than thirty years old. A five-year follow-up study. *J Bone Joint Surg Am.* 1981;63(9):1426-34.
52. **Chandran P, Azzabi M, Burton DJ, Andrews M, Bradley JG.** Mid term results of Furlong LOL uncemented hip hemiarthroplasty for fractures of the femoral neck. *Acta Orthop Belg.* 2006;72(4):428-33.
53. **Charnley J.** Fracture of femoral prostheses in total hip replacement. A clinical study. *Clin Orthop Relat Res.* 1975(111):105-20.
54. **Charnley J.** The long-term results of low-friction arthroplasty of the hip performed as a primary intervention. *J Bone Joint Surg Br.* 1972;54(1):61-76.
55. **Charnley J.** The reaction of bone to self-curing acrylic cement. A long-term histological study in man. *J Bone Joint Surg Br.* 1970;52(2):340-53.
56. **Chelnokov A, Golovin A.** Hip joint evaluation system - Harris Hip Score. 2000; Available from: http://exper.ural.ru/trauma/harris_e.phtml.
57. **Christie J, Burnett R, Potts HR, Pell AC.** Echocardiography of transiatrial embolism during cemented and uncemented hemiarthroplasty of the hip. *J Bone Joint Surg Br.* 1994;76(3):409-12.
58. **Clarke BL, Khosla S.** Physiology of bone loss. *Radiol Clin North Am.* 2010;48(3):483-95.
59. **Coathup MJ, Blunn GW, Flynn N, Williams C, Thomas NP.** A comparison of bone remodelling around hydroxyapatite-coated, porous-coated and grit-blasted hip replacements retrieved at post-mortem. *J Bone Joint Surg Br.* 2001;83(1):118-23.
60. **Cohen B, Rushton N.** Accuracy of DEXA measurement of bone mineral density after total hip arthroplasty. *J Bone Joint Surg Br.* 1995;77(3):479-83.
61. **Collin-Osdoby P.** Regulation of vascular calcification by osteoclast regulatory factors RANKL and osteoprotegerin. *Circ Res.* 2004;95(11):1046-57.
62. **Crawford CH, 3rd, Malkani AL, Incavo SJ, Morris HB, Krupp RJ, Baker D.** Femoral component revision using an extensively hydroxyapatite-coated stem. *J Arthroplasty.* 2004;19(1):8-13.
63. **Cummings SR, San Martin J, McClung MR, Siris ES, Eastell R, Reid IR, et al.** Denosumab for prevention of fractures in postmenopausal women with osteoporosis. *N Engl J Med.* 2009;361(8):756-65.
64. **D'ippolito G, Schiller PC, Ricordi C, Roos BA, Howard GA.** Age-related osteogenic potential of mesenchymal stromal stem cells from human vertebral bone marrow. *J Bone Miner Res.* 1999;14(7):1115-22.
65. **Davies H, Ollivere B, Motha J, Porteous M, August A.** Successful performance of the bi-metric uncemented femoral stem at a minimum follow-up of 13 years in

- young patients. *J Arthroplasty*. 2010;25(2):186-90.
66. Delaunay C, Bonomet F, North J, Jobard D, Cazeau C, Kempf JF. Grit-blasted titanium femoral stem in cementless primary total hip arthroplasty: a 5- to 10-year multicenter study. *J Arthroplasty*. 2001;16(1):47-54.
 67. DeLee JG, Charnley J. Radiological demarcation of cemented sockets in total hip replacement. *Clin Orthop Relat Res*. 1976(121):20-32.
 68. Dennison E, Mohamed MA, Cooper C. Epidemiology of osteoporosis. *Rheum Dis Clin North Am*. 2006;32(4):617-29.
 69. Diaz R, Chkolnik M. ASR™ XL Acetabular System and DePuy ASR™ Hip Resurfacing System Recall. 2010 [updated 2010-08-27]; Available from: <http://www.depuy.com/corporate-information/depuy-divisions/depuy-orthopaedics-inc/landasr>.
 70. Digas G, Kärrholm J, Thanner J. Different loss of BMD using uncemented press-fit and whole polyethylene cups fixed with cement: repeated DXA studies in 96 hips randomized to 3 types of fixation. *Acta Orthop*. 2006;77(2):218-26.
 71. Digas G, Kärrholm J, Thanner J, Malchau H, Herberts P. Highly cross-linked polyethylene in cemented THA: randomized study of 61 hips. *Clin Orthop Relat Res*. 2003(417):126-38.
 72. Digas G, Kärrholm J, Thanner J, Malchau H, Herberts P. The Otto Aufranc Award. Highly cross-linked polyethylene in total hip arthroplasty: randomized evaluation of penetration rate in cemented and uncemented sockets using radio-stereometric analysis. *Clin Orthop Relat Res*. 2004(429):6-16.
 73. Dohmae Y, Bechtold JB, Sherman RE, Puno RM, Gustilo RB. Reduction in cement-bone interface shear strength between primary and revision arthroplasty. *Clin Orthop Relat Res*. 1988(236):214-20.
 74. Dorr LD, Faugere MC, Mackel AM, Gruen TA, Bognar B, Mal-luche HH. Structural and cellular assessment of bone quality of proximal femur. *Bone*. 1993;14(3):231-42.
 75. Dorr LD, Luckett M, Conaty JP. Total hip arthroplasties in patients younger than 45 years. A nine- to ten-year follow-up study. *Clin Orthop Relat Res*. 1990(260):215-9.
 76. Dorr LD, Wan Z, Song M, Ranawat A. Bilateral total hip arthroplasty comparing hydroxyapatite coating to porous-coated fixation. *J Arthroplasty*. 1998;13(7):729-36.
 77. Downie WW, Leatham PA, Rhind VM, Wright V, Branco JA, Anderson JA. Studies with pain rating scales. *Ann Rheum Dis*. 1978;37(4):378-81.
 78. Eftekhar NS. Long-term results of cemented total hip arthroplasty. *Clin Orthop Relat Res*. 1987(225):207-17.
 79. Eisler T. On loosening and revision in total hip arthroplasty. Stockholm: Karolinska Institutet; 2003.
 80. Eisler T, Svensson O, Iyer V, Wej-kner B, Schmalholz A, Larsson H, et al. Revision total hip arthroplasty using third-generation cementing technique. *J Arthroplasty*. 2000;15(8):974-81.
 81. Ekström W. Proximal Femoral Fractures. Functional outcome, quality of life and mortality. Stockholm: Karolinska Institutet; 2008.
 82. Ekström W, Karlsson-Thur C, Larsson S, Ragnarsson B, Alberts KA. Functional outcome in treatment of unstable trochanteric and subtrochanteric fractures with the proximal femoral nail and the Medoff sliding plate. *J Orthop Trauma*. 2007;21(1):18-25.
 83. Emerson RH, Jr, Head WC, Higgins LL. Clinical and radiographic analysis of the Mallory-Head femoral component in revision total hip arthroplasty. A minimum 8.8-year and average eleven-year follow-up study. *J Bone Joint Surg Am*. 2003;85-A(10):1921-6.
 84. Engelbrecht E, Siegel A. Endo-Klinik Klassifikation. *Radiologe*. 1989;29(10):505-18.
 85. Engh CA, Bobyn JD. The influence of stem size and extent of porous coating on femoral bone resorption after primary cementless hip arthroplasty. *Clin Orthop Relat Res*. 1988(231):7-28.
 86. Engh CA, Bobyn JD, Glassman AH. Porous-coated hip replacement. The factors governing bone ingrowth, stress shielding, and clinical results. *J Bone Joint Surg Br*. 1987;69(1):45-55.
 87. Engh CA, Griffin WL, Marx CL. Cementless acetabular components. *J Bone Joint Surg Br*. 1990;72(1):53-9.
 88. Engh CA, Jr, McAuley JP, Sychterz CJ, Sacco ME, Engh CA, Sr. The accuracy and reproducibility of radiographic assessment of stress-shielding. A postmortem analysis. *J Bone Joint Surg Am*. 2000;82-A(10):1414-20.
 89. Engh CA, Jr, Mohan V, Nagowski JP, Sychterz Terefenko CJ, Engh CA, Sr. Influence of stem size on clinical outcome of primary total hip arthroplasty with cementless extensively porous-coated femoral components. *J Arthroplasty*. 2009;24(4):554-9.
 90. Engh CA, Jr, Sychterz CJ, Young AM, Pollock DC, Toomey SD, Engh CA, Sr. Interobserver and intraobserver variability in radiographic assessment of osteolysis. *J Arthroplasty*. 2002;17(6):752-9.
 91. Engh CA, Massin P, Suthers KE. Roentgenographic assessment of the biologic fixation of porous-surfaced femoral components. *Clin Orthop Relat Res*. 1990(257):107-28.
 92. Enocson A, Hedbeck CJ, Tidermark J, Pettersson H, Ponzer S, Lapidus LJ. Dislocation of total hip arthroplasty in patients with fractures of the femoral neck. *Acta Orthop*. 2009;80(2):184-9.
 93. Eriksen EF, Vesterby A, Kassem M, Melsen F, Mosekilde L. Bone remodelling and bone structure. In: Mundy GR, et al., editors. *Physiology and Pharmacology of Bone Handbook of Experimental Pharmacology*. New York: Springer-Verlag; 1993. p. 67-109.
 94. Eskelinen A, Remes V, Hele-nius I, Pulkkinen P, Nevalainen J, Paavolainen P. Uncemented total hip arthroplasty for primary osteoarthritis in young patients: a mid-to long-term follow-up study from the Finnish Arthroplasty Register. *Acta Orthop*. 2006;77(1):57-70.
 95. EuroQol-group. EQ-5D A standardised instrument for use as a measure of health outcome. 2010; Available from: <http://www.euro-qol.org/>.
 96. Eynon-Lewis NJ, Ferry D, Pearse ME. Themistocles Gluck: an unrecognised genius. *BMJ*. 1992;305(6868):1534-6.
 97. Fender D, van der Meulen JH, Gregg PJ. Relationship between outcome and annual surgical experience for the Charnley total hip replacement. Results from a regional hip register. *J Bone Joint Surg Br*. 2003;85(2):187-90.
 98. Field RE, Cronin MD, Singh PJ, Burtenshaw C, Rushton N. Bone remodelling around the Cambridge cup: a DEXA study of 50 hips over 2 years. *Acta Orthop*. 2006;77(5):726-32.
 99. Figved W, Opland V, Frihagen E, Jervidal T, Madsen JE, Nord-sletten L. Cemented versus uncemented hemiarthroplasty for displaced femoral neck frac-

- tures. *Clin Orthop Relat Res*. 2009;467(9):2426-35.
100. Fleisch H. Bisphosphonates In Bone Disease. From the laboratory to the patient. 2nd ed. New York: The Parthenon Publishing Group Ltd.; 1995.
 101. Fleisch H, Russell RG, Bisaz S, Casey PA, Muhlbauer RC. The influence of pyrophosphate analogues (diphosphonates) on the precipitation and dissolution. *Calcif Tissue Res*. 1968;Suppl:10-a.
 102. Fleisch H, Russell RG, Straumann F. Effect of pyrophosphate on hydroxyapatite and its implications in calcium homeostasis. *Nature*. 1966;212(5065):901-3.
 103. Folgado J, Fernandes PR, Jacobs CR, Pellegrini VD, Jr. Influence of femoral stem geometry, material and extent of porous coating on bone ingrowth and atrophy in cementless total hip arthroplasty: an iterative finite element model. Computer methods in biomechanics and biomedical engineering. 2009;12(2):135-45.
 104. Friedl G, Radl R, Stihens C, Rehak P, Aigner R, Windhager R. The effect of a single infusion of zoledronic acid on early implant migration in total hip arthroplasty. A randomized, double-blind, controlled trial. *J Bone Joint Surg Am*. 2009;91(2):274-81.
 105. Frihagen F, Grotle M, Madsen JE, Wyller TB, Mowinckel P, Nordsletten L. Outcome after femoral neck fractures: a comparison of Harris Hip Score, Eq-5d and Barthel Index. *Injury*. 2008;39(10):1147-56.
 106. Galante J, Rostoker W, Lueck R, Ray RD. Sintered fiber metal composites as a basis for attachment of implants to bone. *J Bone Joint Surg Am*. 1971;53(1):101-14.
 107. Gallo J, Raska M, Mrazek F, Petrek M. Bone remodeling, particle disease and individual susceptibility to periprosthetic osteolysis. *Physiol Res*. 2008;57(3):339-49.
 108. Garden R. Low-angle fixation in fractures of the femoral neck. *J Bone Joint Surg Br*. 1961;43-B:647-63.
 109. Garellick G, Kärrholm J, Rogmark C, Herberts P. Swedish Hip Arthroplasty Register Annual Report 2008. 2009 2009-10-20. Report No.
 110. Garellick G, Kärrholm J, Rogmark C, Herberts P. Swedish Hip Arthroplasty Register Annual Report 2009. 2010; Available from: <http://www.jru.orthop.gu.se/>.
 111. Girdlestone GR. Acute pyogenic arthritis of the hip: an operation giving free access and effective drainage. 1943. *Lancet*. 1943(1):419.
 112. Gjertsen JE, Vinje T, Engesaeter LB, Lie SA, Havelin LI, Furnes O, et al. Internal screw fixation compared with bipolar hemiarthroplasty for treatment of displaced femoral neck fractures in elderly patients. *J Bone Joint Surg Am*. 2010;92(3):619-28.
 113. Glassman AH, Crowninshield RD, Schenck R, Herberts P. A low stiffness composite biologically fixed prosthesis. *Clin Orthop Relat Res*. 2001(393):128-36.
 114. Glück T. Referat über die durch das moderne chirurgische Experiment gewonnenen positiven Resultate, betreffend die Naht und den Ersatz von Defecten höherer Gewebe. *Langenbecks Arch klin Chir*. 1891(41):187-239.
 115. Gomez PF, Morcuende JA. Early attempts at hip arthroplasty-1700s to 1950s. *Iowa Orthop J*. 2005;25:25-9.
 116. Gordon A, Greenfield EM, Eastell R, Kiss-Toth E, Wilkinson JM. Individual susceptibility to periprosthetic osteolysis is associated with altered patterns of innate immune gene expression in response to pro-inflammatory stimuli. *J Orthop Res*. 2010.
 117. Graves S, Davidson D, de Steiger R. Australian National Joint replacement Registry Annual Report 2009. 2010; Available from: www.dmac.adelaide.edu.au/aoanjrr/.
 118. Gruen TA, McNeice GM, Amstutz HC. "Modes of failure" of cemented stem-type femoral components: a radiographic analysis of loosening. *Clin Orthop Relat Res*. 1979(141):17-27.
 119. Gustilo RB, Pasternak HS. Revision total hip arthroplasty with titanium ingrowth prosthesis and bone grafting for failed cemented femoral component loosening. *Clin Orthop Relat Res*. 1988(235):111-9.
 120. Hallan G, Lie SA, Furnes O, Engesaeter LB, Vollset SE, Havelin LI. Medium- and long-term performance of 11,516 uncemented primary femoral stems from the Norwegian arthroplasty register. *J Bone Joint Surg Br*. 2007;89(12):1574-80.
 121. Hansson HA, Albrektsson T, Brånemark PI. Structural aspects of the interface between tissue and titanium implants. *J Prosthet Dent*. 1983;50(1):108-13.
 122. Hansson U, Toksvig-Larsen S, Ryd L, Aspenberg P. Once-weekly oral medication with alendronate does not prevent migration of knee prostheses: A double-blind randomized RSA study. *Acta Orthop*. 2009;80(1):41-5.
 123. Harris ST, Watts NB, Genant HK, McKeever CD, Hangartner T, Keller M, et al. Effects of risedronate treatment on vertebral and nonvertebral fractures in women with postmenopausal osteoporosis: a randomized controlled trial. Vertebral Efficacy With Risedronate Therapy (VERT) Study Group. *JAMA*. 1999;282(14):1344-52.
 124. Harris WH. Conquest of a worldwide human disease: particle-induced periprosthetic osteolysis. *Clin Orthop Relat Res*. 2004(429):39-42.
 125. Harris WH. Osteolysis and particle disease in hip replacement. A review. *Acta Orthop Scand*. 1994;65(1):113-23.
 126. Harris WH. The problem is osteolysis. *Clin Orthop Relat Res*. 1995(311):46-53.
 127. Harris WH. Traumatic arthritis of the hip after dislocation and acetabular fractures: treatment by mold arthroplasty. An end-result study using a new method of result evaluation. *J Bone Joint Surg Am*. 1969;51(4):737-55.
 128. Harris WH, Schiller AL, Scholler JM, Freiberg RA, Scott R. Extensive localized bone resorption in the femur following total hip replacement. *J Bone Joint Surg Am*. 1976;58(5):612-8.
 129. Havelin LI, Engesaeter LB, Espehaug B, Furnes O, Lie SA, Vollset SE. The Norwegian Arthroplasty Register: 11 years and 73,000 arthroplasties. *Acta Orthop Scand*. 2000;71(4):337-53.
 130. Hayashi Y, Miki H, Nishii T, Hananouchi T, Yoshikawa H, Sugano N. Proximal femoral bone mineral density after resurfacing total hip arthroplasty and after standard stem-type cementless total hip arthroplasty, both having similar neck preservation and the same articulation type. *J Arthroplasty*. 2007;22(8):1208-13.
 131. Haydon CM, Mehin R, Burnett S, Roraback CH, Bourne RB, McCalden RW, et al. Revision total hip arthroplasty with use of a cemented femoral component. Results at a mean of ten years. *J Bone Joint Surg Am*. 2004;86-A(6):1179-85.
 132. Head WC, Bauk DJ, Emerson RH, Jr. Titanium as the material of choice for cementless femoral components in total hip

- arthroplasty. *Clin Orthop Relat Res.* 1995;311:85-90.
133. Hennigs T, Arabmollah M, Schwarz A, Zichner L. Dose-dependent prevention of early periprosthetic bone loss by alendronate. *Z Orthop Ihre Grenzgeb.* 2002;140(1):42-7.
 134. Hilding M, Ryd L, Toksvig-Larsen S, Aspenberg P. Clodronate prevents prosthetic migration: a randomized radiostereometric study of 50 total knee patients. *Acta Orthop Scand.* 2000;71(6):553-7.
 135. Holt G, Smith R, Duncan K, Finlayson DF, Gregori A. Early mortality after surgical fixation of hip fractures in the elderly: an analysis of data from the scottish hip fracture audit. *J Bone Joint Surg Br.* 2008;90(10):1357-63.
 136. Howie DW, Wimhurst JA, McGee MA, Carbone TA, Badaruddin BS. Revision total hip replacement using cemented collarless double-taper femoral components. *J Bone Joint Surg Br.* 2007;89(7):879-86.
 137. Hsieh PH, Chang YH, Lee PC, Shih CH. Periprosthetic fractures of the greater trochanter through osteolytic cysts with uncemented MicroStructured Omnifit prosthesis: retrospective analyses of 23 fractures in 887 hips after 5-14 years. *Acta Orthop.* 2005;76(4):538-43.
 138. Huiskes R, Weinans H, van Rietbergen B. The relationship between stress shielding and bone resorption around total hip stems and the effects of flexible materials. *Clin Orthop Relat Res.* 1992(274):124-34.
 139. Isaac DL, Forder J, Skyrme AD, James SE. The Biomet Bi-Metric total hip arthroplasty and universal acetabular cup: high polyethylene failure rate in the medium term. *J Arthroplasty.* 2007;22(5):697-700.
 140. Jacobsen S, Jensen FK, Poulsen K, Sturup J, Retpen JB. Good performance of a titanium femoral component in cementless hip arthroplasty in younger patients: 97 arthroplasties followed for 5-11 years. *Acta Orthop Scand.* 2003;74(4):375-9.
 141. Jacobsson SA, Djerf K, Gillquist J, Hammerby S, Ivarsson I. A prospective comparison of Butel and PCA hip arthroplasty. *J Bone Joint Surg Br.* 1993;75(4):624-9.
 142. Jensen MP, Turner JA, Romano JM, Fisher LD. Comparative reliability and validity of chronic pain intensity measures. *Pain.* 1999;83(2):157-62.
 143. Jones LC, Hungerford DS. Cement disease. *Clin Orthop Relat Res.* 1987(225):192-206.
 144. Judet J, Judet R. The use of an artificial femoral head for arthroplasty of the hip joint. *J Bone Joint Surg Br.* 1950;32-B(2):166-73.
 145. Kalender WA. Effective dose values in bone mineral measurements by photon absorptiometry and computed tomography. *Osteoporos Int.* 1992;2(2):82-7.
 146. Kaptein BL, Valstar ER, Stoel BC, Rozing PM, Reiber JH. A new model-based RSA method validated using CAD models and models from reversed engineering. *J Biomech.* 2003;36(6):873-82.
 147. Kattapuram SV, Lodwick GS, Chandler H, Khurana JS, Ehara S, Rosenthal DI. Porous-coated anatomic total hip prostheses: radiographic analysis and clinical correlation. *Radiology.* 1990;174(3 Pt 1):861-4.
 148. Keisu KS, Orozco F, Sharkey PF, Hozack WJ, Rothman RH, McGuigan FX. Primary cementless total hip arthroplasty in octogenarians. Two to eleven-year follow-up. *J Bone Joint Surg Am.* 2001;83-A(3):359-63.
 149. Kelly SJ, Incavo SJ, Beynonn B. The use of a hydroxyapatite-coated primary stem in revision total hip arthroplasty. *J Arthroplasty.* 2006;21(1):64-71.
 150. Kelly TL, Slovik DM, Schoenfeld DA, Neer RM. Quantitative digital radiography versus dual photon absorptiometry of the lumbar spine. *J Clin Endocrinol Metab.* 1988;67(4):839-44.
 151. Khan RJ, MacDowell A, Crossman P, Datta A, Jallali N, Arch BN, et al. Cemented or uncemented hemiarthroplasty for displaced intracapsular femoral neck fractures. *Int Orthop.* 2002;26(4):229-32.
 152. Kilgus DJ, Shimaoka EE, Tipton JS, Eberle RW. Dual-energy X-ray absorptiometry measurement of bone mineral density around porous-coated cementless femoral implants. Methods and preliminary results. *J Bone Joint Surg Br.* 1993;75(2):279-87.
 153. Kim YH, Kim VE. Uncemented porous-coated anatomic total hip replacement. Results at six years in a consecutive series. *J Bone Joint Surg Br.* 1993;75(1):6-13.
 154. Kim YH, Oh SH, Kim JS. Primary total hip arthroplasty with a second-generation cementless total hip prosthesis in patients younger than fifty years of age. *J Bone Joint Surg Am.* 2003;85-A(1):109-14.
 155. Kiratli BJ, Checovich MM, McBeath AA, Wilson MA, Heiner JP. Measurement of bone mineral density by dual-energy x-ray absorptiometry in patients with the Wisconsin hip, an uncemented femoral stem. *J Arthroplasty.* 1996;11(2):184-93.
 156. Klein GR, Parvizi J, Vegari DN, Rothman RH, Purtill JJ. Total hip arthroplasty for acute femoral neck fractures using a cementless tapered femoral stem. *J Arthroplasty.* 2006;21(8):1134-40.
 157. Klestil T, Biedermann R, Kruger A, Goller P, Schmoelz W, Rangger C, Krismer M, Blaut M. Cementless hemiarthroplasty in femoral neck fractures: evaluation of clinical results and measurement of migration by EBRA-FCA. *Arch Orthop Trauma Surg.* 2006;126(6):380-6.
 158. Kovac S, Trebse R, Milosev I, Pavlovic V, Pisot V. Long-term survival of a cemented titanium-aluminum-vanadium alloy straight-stem femoral component. *J Bone Joint Surg Br.* 2006;88(12):1567-73.
 159. Krismer M, Bauer R, Tschupik J, Mayrhofer P. EBRA: a method to measure migration of acetabular components. *J Biomech.* 1995;28(10):1225-36.
 160. Krismer M, Biedermann R, Stockl B, Fischer M, Bauer R, Haid C. The prediction of failure of the stem in THR by measurement of early migration using EBRA-FCA. Einzel-Bild-Roentgen-Analyse-femoral component analysis. *J Bone Joint Surg Br.* 1999;81(2):273-80.
 161. Kruger A, Berli B, Lampert C, Kranzlin C, Morscher E. [Comparative periprosthetic bone density measurements of the proximal femur shaft using dual energy x-ray absorptiometry (DEXA) with experimental "Press Fit-gliding Stem Prosthesis"]. *Z Orthop Ihre Grenzgeb.* 1998;136(2):115-25.
 162. Kröger H, Miettinen H, Arnala I, Koski E, Rushton N, Suomalainen O. Evaluation of periprosthetic bone using dual-energy x-ray absorptiometry: precision of the method and effect of operation on bone mineral density. *J Bone Miner Res.* 1996;11(10):1526-30.
 163. Kwon MS, Kuskowski M, Mulhall KJ, Macaulay W, Brown TE, Saleh KJ. Does surgical approach affect total hip arthroplasty dislocation rates? *Clin Orthop Relat Res.* 2006;447:34-8.
 164. Kärholm J, Anderberg C, Snor-

- rason F, Thanner J, Langeland N, Malchau H, Herberts P. Evaluation of a femoral stem with reduced stiffness. A randomized study with use of radiostereometry and bone densitometry. *J Bone Joint Surg Am.* 2002;84-A(9):1651-8.
165. Kärrholm J, Borsen B, Lowenhillem G, Snorrason F. Does early micromotion of femoral stem prostheses matter? 4-7-year stereoradiographic follow-up of 84 cemented prostheses. *J Bone Joint Surg Br.* 1994;76(6):912-7.
166. Kärrholm J, Herberts P, Hultmark P, Malchau H, Nivbrant B, Thanner J. Radiostereometry of hip prostheses. Review of methodology and clinical results. *Clin Orthop Relat Res.* 1997(344):94-110.
167. Larsson S, Elloy M, Hansson LI. Stability of osteosynthesis in trochanteric fractures. Comparison of three fixation devices in cadavers. *Acta Orthop Scand.* 1988;59(4):386-90.
168. Lavernia C, D'Apuzzo M, Hernandez V, Lee D. Thigh pain in primary total hip arthroplasty: the effects of elastic moduli. *J Arthroplasty.* 2004;19(7 Suppl 2):10-6.
169. Lawrence JM, Engh CA, Macalino GE, Lauro GR. Outcome of revision hip arthroplasty done without cement. *J Bone Joint Surg Am.* 1994;76(7):965-73.
170. Lazarinis S, Karrholm J, Hailer NP. Increased risk of revision of acetabular cups coated with hydroxyapatite. *Acta Orthop.* 2010;81(1):53-9.
171. Learmonth ID, Young C, Rorabeck C. The operation of the century: total hip replacement. *Lancet.* 2007;370(9597):1508-19.
172. Leidinger W, Hoffmann G, Meierhofer JN, Wolfel R. [Reduction of severe cardiac complications during implantation of cemented total hip endoprostheses in femoral neck fractures]. *Unfallchirurg.* 2002;105(8):675-9.
173. Lennox IA, McLauchlan J. Comparing the mortality and morbidity of cemented and uncemented hemiarthroplasties. *Injury.* 1993;24(3):185-6.
174. Leung S, Naudie D, Kitamura N, Walde T, Engh CA. Computed tomography in the assessment of periacetabular osteolysis. *J Bone Joint Surg Am.* 2005;87(3):592-7.
175. Lewiecki EM. Denosumab: a promising drug for the prevention and treatment of osteoporosis. *Womens Health (Lond Engl).* 2006;2(4):517-25.
176. Lewis JL, Askew MJ, Wixson RL, Kramer GM, Tarr RR. The influence of prosthetic stem stiffness and of a calcar collar on stresses in the proximal end of the femur with a cemented femoral component. *J Bone Joint Surg Am.* 1984;66(2):280-6.
177. Lian YY, Pei FX, Yoo MC, Cheng JQ, Fatou CY. Changes of the bone mineral density in proximal femur following total hip resurfacing arthroplasty in osteonecrosis of femoral head. *J Orthop Res.* 2008;26(4):453-9.
178. Lindahl H. Epidemiology of periprosthetic femur fracture around a total hip arthroplasty. *Injury.* 2007;38(6):651-4.
179. Lindahl H, Garellick G, Regner H, Herberts P, Malchau H. Three hundred and twenty-one periprosthetic femoral fractures. *J Bone Joint Surg Am.* 2006;88(6):1215-22.
180. Livesley PJ, Srivastava VM, Needoff M, Prince HG, Moulton AM. Use of a hydroxyapatite-coated hemiarthroplasty in the management of subcapital fractures of the femur. *Injury.* 1993;24(4):236-40.
181. Lo WH, Chen WM, Huang CK, Chen TH, Chiu FY, Chen CM. Bateman bipolar hemiarthroplasty for displaced intracapsular femoral neck fractures. Uncemented versus cemented. *Clin Orthop Relat Res.* 1994(302):75-82.
182. Lombardi AV, Jr., Mallory TH, Vaughn BK, Drouillard P. Aseptic loosening in total hip arthroplasty secondary to osteolysis induced by wear debris from titanium-alloy modular femoral heads. *J Bone Joint Surg Am.* 1989;71(9):1337-42.
183. Lybäck CC, Lybäck CO, Kyro A, Kautiainen HJ, Belt EA. Survival of Bi-Metric femoral stems in 77 total hip arthroplasties for juvenile chronic arthritis. *Int Orthop.* 2004;28(6):357-61.
184. Läkemedelsindustriföreningen. FASS. 2010; Available from: www.fass.se.
185. Macaulay W, Nellans KW, Garvin KL, Iorio R, Healy WL, Rosenwasser MP. Prospective randomized clinical trial comparing hemiarthroplasty to total hip arthroplasty in the treatment of displaced femoral neck fractures: winner of the Dorr Award. *J Arthroplasty.* 2008;23(6 Suppl 1):2-8.
186. Mahomed NN, Arndt DC, McGroarty BJ, Harris WH. The Harris hip score: comparison of patient self-report with surgeon assessment. *J Arthroplasty.* 2001;16(5):575-80.
187. Mahon JL, Bourne RB, Rorabeck CH, Feeny DH, Stitt L, Webster-Bogaert S. Health-related quality of life and mobility of patients awaiting elective total hip arthroplasty: a prospective study. *CMAJ.* 2002;167(10):1115-21.
188. Majkowski RS, Miles AW, Bannister GC, Perkins J, Taylor GJ. Bone surface preparation in cemented joint replacement. *J Bone Joint Surg Br.* 1993;75(3):459-63.
189. Malchau H. Introducing new technology: a stepwise algorithm. *Spine.* 2000;25(3):285.
190. Malchau H. On the importance of stepwise introduction of new hip implant technology: Assessment of total hip replacement using clinical evaluation, radiostereometry, digitized radiography and a national hip registry. Göteborg, Sweden: Göteborg University; 1995.
191. Malchau H, Kärrholm J, Wang YX, Herberts P. Accuracy of migration analysis in hip arthroplasty. Digitized and conventional radiography, compared to radiostereometry in 51 patients. *Acta Orthop Scand.* 1995;66(5):418-24.
192. Malkani AL, Lewallen DG, Cabanela ME, Wallrichs SL. Femoral component revision using an uncemented, proximally coated, long-stem prosthesis. *J Arthroplasty.* 1996;11(4):411-8.
193. Maloney WJ, Sychterz C, Bragdon C, McGovern T, Jasty M, Engh CA, et al. The Otto Aufranc Award. Skeletal response to well fixed femoral components inserted with and without cement. *Clin Orthop Relat Res.* 1996(333):15-26.
194. Manolagas SC. Birth and death of bone cells: basic regulatory mechanisms and implications for the pathogenesis and treatment of osteoporosis. *Endocr Rev.* 2000;21(2):115-37.
195. Martini F, Kremling E, Schmidt B, Sell S, Mayer F. Bone mineral density of the proximal femur after unilateral cementless total hip replacement. *Int Orthop.* 1999;23(2):104-6.
196. Masri BA, Masterson EL, Duncan CP. The classification and radiographic evaluation of bone loss in revision hip arthroplasty. *Orthop Clin North Am.* 1998;29(2):219-27.
197. Masson M, Parker MJ, Fleischer S. Internal fixation versus arthroplasty for intracapsular proximal femoral fractures in adults. *Cochrane Database Syst Rev.* 2003(2):CD001708.

198. Mattsson P, Larsson S. Stability of internally fixed femoral neck fractures augmented with resorbable cement. A prospective randomized study using radiostereometry. *Scand J Surg*. 2003;92(3):215-9.
199. Mattsson P, Larsson S. Unstable trochanteric fractures augmented with calcium phosphate cement. A prospective randomized study using radiostereometry to measure fracture stability. *Scand J Surg*. 2004;93(3):223-8.
200. Maurer TB, Ochsner PE, Schwarzer G, Schumacher M. Increased loosening of cemented straight stem prostheses made from titanium alloys. An analysis and comparison with prostheses made of cobalt-chromium-nickel alloy. *Int Orthop*. 2001;25(2):77-80.
201. Mayrhofer P. EBRA (Ein-Bild-Roentgen-Analyse). 2010; Available from: <http://geometrie.uibk.ac.at/Forschung/ebra/EBRA.htm>.
202. McCarthy CK, Steinberg GG, Agren M, Leahey D, Wyman E, Baran DT. Quantifying bone loss from the proximal femur after total hip arthroplasty. *J Bone Joint Surg Br*. 1991;73(5):774-8.
203. McClung MR, Geusens P, Miller PD, Zippel H, Bensen WG, Roux C, Adams S, Fogelman I, diamond T, Eastell R, Meunier PJ, Reginster JY. Effect of risedronate on the risk of hip fracture in elderly women. Hip Intervention Program Study Group. *N Engl J Med*. 2001;344(5):333-40.
204. McKee GK, Watson-Farrar J. Replacement of arthritic hips by the McKee-Farrar prosthesis. *J Bone Joint Surg Br*. 1966;48(2):245-59.
205. McMinn D, Treacy R, Lin K, Pynsent P. Metal on metal surface replacement of the hip. Experience of the McMinn prosthesis. *Clin Orthop Relat Res*. 1996(329 Suppl):S89-98.
206. Meding JB, Keating EM, Ritter MA, Faris PM, Berend ME. Minimum ten-year follow-up of a straight-stemmed, plasma-sprayed, titanium-alloy, uncemented femoral component in primary total hip arthroplasty. *J Bone Joint Surg Am*. 2004;86-A(1):92-7.
207. Middleton RG, Howie DW, Costi K, Sharpe P. Effects of design changes on cemented tapered femoral stem fixation. *Clin Orthop Relat Res*. 1998(355):47-56.
208. Miller PD, Brown JB, Siris ES, Hoseyni MS, Axelrod DW, Bekker PJ. A randomized, double-blind comparison of risedronate and etidronate in the treatment of Paget's disease of bone. Paget's Risedronate/Etidronate Study Group. *Am J Med*. 1999;106(5):513-20.
209. Montin L, Suominen T, Katajisto J, Lepisto J, Leino-Kilpi H. Economic outcomes from patients' perspective and health-related quality of life after total hip arthroplasty. *Scand J Caring Sci*. 2009;23(1):11-20.
210. Moore AT. The self-locking metal hip prosthesis. *J Bone Joint Surg Am*. 1957;39-A(4):811-27.
211. Moore AT, Bohlman HR. Metal hip joint. A case report. *J Bone Joint Surg Am*. 1943(25):688-792.
212. Moreland JR, Moreno MA. Cementless femoral revision arthroplasty of the hip: minimum 5 years followup. *Clin Orthop Relat Res*. 2001(393):194-201.
213. Moucha CS, Urban RM, Turner TM, Jacobs JJ, Sumner DR. Fixation of Implants. In: Shanbhag A, et al., editors. Joint Replacement and Bone Resorption. New York: Taylor & Francis Group; 2006. p. 13-52.
214. Muller S, Irgens F, Aamodt A. A quantitative and qualitative analysis of bone remodelling around custom uncemented femoral stems: a five-year DEXA follow-up. *Clin Biomech (Bristol, Avon)*. 2005;20(3):277-82.
215. Mulliken BD, Rorabeck CH, Bourne RB. Uncemented revision total hip arthroplasty: a 4-to-6-year review. *Clin Orthop Relat Res*. 1996(325):156-62.
216. Mulroy RD, Jr., Harris WH. The effect of improved cementing techniques on component loosening in total hip replacement. An 11-year radiographic review. *J Bone Joint Surg Br*. 1990;72(5):757-60.
217. Mäkelä KT, Eskelinen A, Paavolainen P, Pulkkinen P, Remes V. Cementless total hip arthroplasty for primary osteoarthritis in patients aged 55 years and older. *Acta Orthop*. 2010;81(1):42-52.
218. Neander G. Displaced femoral neck fractures: studies on osteosynthesis and total hip arthroplasty. Stockholm: Karolinska Institutet; 2000.
219. Nehme A, Maalouf G, Tricoire JL, Giordano G, Chiron P, Puget J. [Effect of alendronate on periprosthetic bone loss after cemented primary total hip arthroplasty: a prospective randomized study]. *Rev Chir Orthop Reparatrice Appar Mot*. 2003;89(7):593-8.
220. Nishii T, Sugano N, Masuhara K, Shibuya T, Ochi T, Tamura S. Longitudinal evaluation of time related bone remodeling after cementless total hip arthroplasty. *Clin Orthop Relat Res*. 1997(339):121-31.
221. Nistor L, Blaha JD, Kjellstrom U, Selvik G. In vivo measurements of relative motion between an uncemented femoral total hip component and the femur by roentgen stereophotogrammetric analysis. *Clin Orthop Relat Res*. 1991(269):220-7.
222. Nygaard M, Zerahn B, Bruce C, Soballe K, Borgwardt A. Early periprosthetic femoral bone remodelling using different bearing material combinations in total hip arthroplasties: a prospective randomized study. *European cells & materials*. 2004;8:65-73.
223. Okano K, Ito M, Aoyagi K, Motokawa S, Shindo H. Bone mineral densities in patients with developmental dysplasia of the hip. *Osteoporos Int*. 2010.
224. Ornstein E. Hip revisions with impacted morselized allograft bone and cement. Patient outcome, prosthetic fixation and risks. *Acta Orthop Scand Suppl*. 2002;73(306):1-66.
225. Ornstein E, Atroshi I, Franzen H, Johnsson R, Sandquist P, Sundberg M. Early complications after one hundred and forty-four consecutive hip revisions with impacted morselized allograft bone and cement. *J Bone Joint Surg Am*. 2002;84-A(8):1323-8.
226. Paavolainen P, Hamalainen M, Mustonen H, Slati P. Registration of arthroplasties in Finland. A nationwide prospective project. *Acta Orthop Scand Suppl*. 1991;241:27-30.
227. Pacifici R, Rupich R, Griffin M, Chines A, Susman N, Avioli LV. Dual energy radiography versus quantitative computer tomography for the diagnosis of osteoporosis. *J Clin Endocrinol Metab*. 1990;70(3):705-10.
228. Paprosky WG, Greidanus NV, Antoniou J. Minimum 10-year-results of extensively porous-coated stems in revision hip arthroplasty. *Clin Orthop Relat Res*. 1999(369):230-42.
229. Park H. An account of a new method of treating diseases of the joints of the knee and elbow. Letter to P Pott. London 1782.
230. Parker MJ, Gurusamy K. Arthroplasties (with and without bone cement) for proximal femoral fractures in adults. *Cochrane Database Syst Rev*. 2006;3:CD001706.
231. Parvizi J, Ereth MH, Lewallen DG. Thirty-day mortality following hip arthroplasty for acute fracture. *J Bone Joint Surg Am*. 2004;86-

- A(9):1983-8.
232. **Parvizi J, Holiday AD, Ereth MH, Lewallen DG.** The Frank Stinchfield Award. Sudden death during primary hip arthroplasty. *Clin Orthop Relat Res.* 1999(369):39-48.
 233. **Parvizi J, Keisu KS, Hozack WJ, Sharkey PF, Rothman RH.** Primary total hip arthroplasty with an uncemented femoral component: a long-term study of the Taperloc stem. *J Arthroplasty.* 2004;19(2):151-6.
 234. **Paulsen A, Pedersen AB, Johnsen SP, Riis A, Lucht U, Overgaard S.** Effect of hydroxyapatite coating on risk of revision after primary total hip arthroplasty in younger patients: findings from the Danish Hip Arthroplasty Registry. *Acta Orthop.* 2007;78(5):622-8.
 235. **Perka C, Heller M, Wilke K, Taylor WR, Haas NP, Zippel H, et al.** Surgical approach influences periprosthetic femoral bone density. *Clin Orthop Relat Res.* 2005(432):153-9.
 236. **Peter B, Gauthier O, Laib S, Bu-joli B, Guicheux J, Janvier P, et al.** Local delivery of bisphosphonate from coated orthopedic implants increases implants mechanical stability in osteoporotic rats. *J Biomed Mater Res A.* 2006;76(1):133-43.
 237. **Petersen MB, Kalthoff N, Eiken P.** Bone mineral density around femoral stems. DXA measurements in 22 porous-coated implants after 5 years. *Acta Orthop Scand.* 1995;66(5):432-4.
 238. **Pfeiffer E.** A short portable mental status questionnaire for the assessment of organic brain deficit in elderly patients. *J Am Geriatr Soc.* 1975;23(10):433-41.
 239. **Phillips NJ, Stockley I, Wilkinson JM.** Direct plain radiographic methods versus EBRA-Digital for measuring implant migration after total hip arthroplasty. *J Arthroplasty.* 2002;17(7):917-25.
 240. **Pilliar RM, Cameron HU, Binnington AG, Szivek J, Macnab I.** Bone ingrowth and stress shielding with a porous surface coated fracture fixation plate. *J Biomed Mater Res.* 1979;13(5):799-810.
 241. **Pilliar RM, Cameron HU, Macnab I.** Porous surface layered prosthetic devices. *Biomed Eng.* 1975;10(4):126-31.
 242. **Pilliar RM, Lee JM, Maniopoulos C.** Observations on the effect of movement on bone ingrowth into porous-surfaced implants. *Clin Orthop Relat Res.* 1986(208):108-13.
 243. **Pitto RP, Koessler M, Kuehle JW.** Comparison of fixation of the femoral component without cement and fixation with use of a bone-vacuum cementing technique for the prevention of fat embolism during total hip arthroplasty. A prospective, randomized clinical trial. *J Bone Joint Surg Am.* 1999;81(6):831-43.
 244. **Puolakka TJ, Pajamaki KJ, Pulkkinen PO, Nevalainen JK.** Poor survival of cementless Biomet total hip: a report on 1,047 hips from the Finnish Arthroplasty Register. *Acta Orthop Scand.* 1999;70(5):425-9.
 245. **Rabin R, de Charro F.** EQ-5D: a measure of health status from the EuroQol Group. *Ann Med.* 2001;33(5):337-43.
 246. **Rahmy AI, Gosens T, Blake GM, Tonino A, Fogelman I.** Periprosthetic bone remodelling of two types of uncemented femoral implant with proximal hydroxyapatite coating: a 3-year follow-up study addressing the influence of prosthesis design and preoperative bone density on periprosthetic bone loss. *Osteoporos Int.* 2004;15(4):281-9.
 247. **Raman R, Kamath RP, Parikh A, Angus PD.** Revision of cemented hip arthroplasty using a hydroxyapatite-ceramic-coated femoral component. *J Bone Joint Surg Br.* 2005;87(8):1061-7.
 248. **Randhawa K, Hossain FS, Smith B, Mauffrey C, Lawrence T.** A prospective study of hip revision surgery using the Exeter long-stem prosthesis: function, subsidence, and complications for 57 patients. *J Orthop Traumatol.* 2009;10(4):159-65.
 249. **Reikeras O, Gunderson RB.** Excellent results with femoral revision surgery using an extensively hydroxyapatite-coated stem: 59 patients followed for 10-16 years. *Acta Orthop.* 2006;77(1):98-103.
 250. **Robertsen K, Gaarden M, Teichert G, Langhoff O.** Results of the total bi-metric cementless hip arthroplasty. *Orthopedics.* 1996;19(8):673-4.
 251. **Roder C, Staub LP, Eichler P, Widmer M, Dietrich D, Eggli S, Müller U.** Avoiding misclassification bias with the traditional Charnley classification: rationale for a fourth Charnley class BB. *J Orthop Res.* 2006;24(9):1803-8.
 252. **Rogers MJ, Gordon S, Benford HL, Coxon FB, Luckman SP, Monkonen J, Frith JC.** Cellular and molecular mechanisms of action of bisphosphonates. *Cancer.* 2000;88(12 Suppl):2961-78.
 253. **Rogmark C, Johnell O.** Primary arthroplasty is better than internal fixation of displaced femoral neck fractures: a meta-analysis of 14 randomized studies with 2,289 patients. *Acta Orthop.* 2006;77(3):359-67.
 254. **Rogmark C, Spetz CL, Garellick G.** More intramedullary nails and arthroplasties for treatment of hip fractures in Sweden. *Acta Orthop.* 2010;81(5):588-92.
 255. **Rothman RH, Hozack WJ, Ranawat A, Moriarty L.** Hydroxyapatite-coated femoral stems. A matched-pair analysis of coated and uncoated implants. *J Bone Joint Surg Am.* 1996;78(3):319-24.
 256. **Roux C, Ravaud P, Cohen-Solal M, de Vernejoul MC, Guillemand S, Cherruau B, et al.** Biologic, histologic and densitometric effects of oral risedronate on bone in patients with multiple myeloma. *Bone.* 1994;15(1):41-9.
 257. **Ryd L, Albrektsson BE, Carlsson L, Dansgard F, Herberts P, Lindstrand A, et al.** Roentgen stereophotogrammetric analysis as a predictor of mechanical loosening of knee prostheses. *J Bone Joint Surg Br.* 1995;77(3):377-83.
 258. **Sabo D, Reiter A, Simank HG, Thomsen M, Lukoschek M, Ewerbeck V.** Periprosthetic mineralization around cementless total hip endoprosthesis: longitudinal study and cross-sectional study on titanium threaded acetabular cup and cementless Spotorno stem with DEXA. *Calcif Tissue Int.* 1998;62(2):177-82.
 259. **Salvati EA, Wilson PD, Jr., Jolley MN, Vakil F, Aglietti P, Brown GC.** A ten-year follow-up study of our first one hundred consecutive Charnley total hip replacements. *J Bone Joint Surg Am.* 1981;63(5):753-67.
 260. **Santori FS, Manili M, Fredella N, Tonci Ottieri M, Santori N.** Ultra-short stems with proximal load transfer: Clinical and radiographic results at five-year follow-up. 2006. p. S31-S9.
 261. **Schett G, Kiechl S, Weger S, Pederiva A, Mayr A, Petrangeli M, et al.** High-sensitivity C-reactive protein and risk of nontraumatic fractures in the Bruneck study. *Arch Intern Med.* 2006;166(22):2495-501.
 262. **Schett G, Saag KG, Bijlsma JW.** From bone biology to clinical outcome: state of the art and future perspectives. *Ann Rheum Dis.* 2010;69(8):1415-9.
 263. **Schmalzried TP, Jasty M, Harris WH.** Periprosthetic bone loss in

- total hip arthroplasty. Polyethylene wear debris and the concept of the effective joint space. *J Bone Joint Surg Am.* 1992;74(6):849-63.
264. Selvik G. Roentgen stereophotogrammetry. A method for the study of the kinematics of the skeletal system. *Acta Orthop Scand Suppl.* 1989;232:1-51.
265. Shanbhag A, Rubash HE, Jacobs JJ. *Joint Replacement and Bone Resorption.* New York: Taylor & Francis Group; 2006.
266. Shanbhag AS, Hasselman CT, Rubash HE. The John Charnley Award. Inhibition of wear debris mediated osteolysis in a canine total hip arthroplasty model. *Clin Orthop Relat Res.* 1997(344):33-43.
267. Simonet WS, Lacey DL, Dunstan CR, Kelley M, Chang MS, Luthy R, Nguyen HQ, Wooden S, Bennett L, Boone T, Shimamoto G, DeRose M, Elliott R, Colombero A, Tan HL, Trail G, Sullivan J, Davy E, Bucay N, Renshaw-Gegg L, Hughes TM, Hill D, Pattison W, Campbell P, Sander S, Van G, Tarpley J, Derby P, Lee R, Boyle WJ. Osteoprotegerin: a novel secreted protein involved in the regulation of bone density. *Cell.* 1997;89(2):309-19.
268. Skoglund B, Holmertz J, Aspenberg P. Systemic and local ibandronate enhance screw fixation. *J Orthop Res.* 2004;22(5):1108-13.
269. Sköldenberg O, Ekman A, Salemyr M, Boden H. Reduced dislocation rate after hip arthroplasty for femoral neck fractures when changing from posterolateral to anterolateral approach. *Acta Orthop.* 2010.
270. Sköldenberg O, Salemyr M, Muren O, Johansson Å, Ahl T, Boden H. The Ringloc liner compared with the Hexloc liner in total hip arthroplasty 2009.
271. Sköldenberg OG, Bodén HS, Salemyr MO, Ahl TE, Adolphson PY. Periprosthetic proximal bone loss after uncemented hip arthroplasty is related to stem size: DXA measurements in 138 patients followed for 2-7 years. *Acta Orthop.* 2006;77(3):386-92.
272. Smith-Petersen MN. Evolution of mould arthroplasty of the hip joint. *J Bone Joint Surg Br.* 1948;30B(1):59-75.
273. Smith-Petersen MN. A new supra-articular subperiosteal approach to the hip joint. *Amer J Orthop Surg.* 1917;15:592.
274. Soballe K, Hansen ES, H BR, Jorgensen PH, Bunger C. Tissue ingrowth into titanium and hydroxyapatite-coated implants during stable and unstable mechanical conditions. *J Orthop Res.* 1992;10(2):285-99.
275. Soballe K, Overgaard S, Hansen ES, Brokstedt-Rasmussen H, Lind M, Bunger C. A review of ceramic coatings for implant fixation. *J Long Term Eff Med Implants.* 1999;9(1-2):131-51.
276. Söderman P, Malchau H. Is the Harris hip score system useful to study the outcome of total hip replacement? *Clin Orthop Relat Res.* 2001(384):189-97.
277. Stephenson PK, Freeman MA, Revell PA, Germain J, Tuke M, Pirie CJ. The effect of hydroxyapatite coating on ingrowth of bone into cavities in an implant. *J Arthroplasty.* 1991;6(1):51-8.
278. Straus WL, Jr, Cave JE. Pathology and the posture of Neanderthal man. *Q Rev Biol.* 1957;32(4):348-63.
279. Sumner DR, Galante JO. Bone ingrowth. In: Envarls CM, editor. *Surgery of the Musculoskeletal system* New York: Churchill Livingstone; 1990.
280. Sychterz CJ, Topoleski LD, Sacco M, Engh CA, Sr. Effect of femoral stiffness on bone remodeling after uncemented arthroplasty. *Clin Orthop Relat Res.* 2001(389):218-27.
281. Soballe K, Toksvig-Larsen S, Gelineck J, Fruensgaard S, Hansen ES, Ryd L, et al. Migration of hydroxyapatite coated femoral prostheses. A Roentgen Stereophotogrammetric study. *J Bone Joint Surg Br.* 1993;75(5):681-7.
282. Söderkvist I, Wedin PA. On condition numbers and algorithms for determining a rigid-body movement. *Bit.* 1994(34):424-36.
283. Tallroth K, Slati P, Ylinen P, Paavolainen P, Paavilainen T. Loosening of threaded acetabular components. Radiographic manifestations. *J Arthroplasty.* 1993;8(6):581-4.
284. Tanzer M, Kantor S, Rosenthal L, Bobyn JD. Femoral remodeling after porous-coated total hip arthroplasty with and without hydroxyapatite-tricalcium phosphate coating: a prospective randomized trial. *J Arthroplasty.* 2001;16(5):552-8.
285. Tanzer M, Karabasz D, Krygier JJ, Cohen R, Bobyn JD. The Otto Aufranc Award: bone augmentation around and within porous implants by local bisphosphonate elution. *Clin Orthop Relat Res.* 2005;441:30-9.
286. Thien T. Influence of postoperative treatment, surface treatment and stem design on the outcome of primary total hip arthroplasty. Göteborg: University of Gothenburg; 2009.
287. Thien TM, Ahnfelt L, Eriksson M, Stromberg C, Kärrholm J. Immediate weight bearing after uncemented total hip arthroplasty with an anteverted stem: a prospective randomized comparison using radiostereometry. *Acta Orthop.* 2007;78(6):730-8.
288. Thillemann TM, Pedersen AB, Mehnert F, Johnsen SP, Soballe K. Postoperative use of bisphosphonates and risk of revision after primary total hip arthroplasty: A nationwide population-based study. *Bone.* 2010.
289. Thillemann TM, Pedersen AB, Mehnert F, Johnsen SP, Soballe K. Postoperative use of bisphosphonates and risk of revision after primary total hip arthroplasty: a nationwide population-based study. *Bone.* 2010;46(4):946-51.
290. Thomas KA, Kay JF, Cook SD, Jarcho M. The effect of surface macrotexture and hydroxylapatite coating on the mechanical strengths and histologic profiles of titanium implant materials. *J Biomed Mater Res.* 1987;21(12):1395-414.
291. Thompson FR. Vitallium intramedullary hip prosthesis, preliminary report. *N Y State J Med.* 1952;52(24):3011-20.
292. Tidermark J. Quality of life and femoral neck fractures. *Acta Orthop Scand Suppl.* 2003;74(309):1-42.
293. Tidermark J, Ponzer S, Svensson O, Söderqvist A, Törnkvist H. Internal fixation compared with total hip replacement for displaced femoral neck fractures in the elderly. A randomised, controlled trial. *J Bone Joint Surg Br.* 2003;85(3):380-8.
294. Trebbe R, Milosevic I, Kovac S, Mikek M, Pisot V. Poor results from the isoelastic total hip replacement: 14-17-year follow-up of 149 cementless prostheses. *Acta Orthop.* 2005;76(2):169-76.
295. Trevisan C, Bigoni M, Randelli G, Marinoni EC, Peretti G, Ortolani S. Periprosthetic bone density around fully hydroxyapatite coated femoral stem. *Clin Orthop Relat Res.* 1997(340):109-17.
296. Trikha SP, Singh S, Raynham OW, Lewis JC, Mitchell PA, Edge AJ. Hydroxyapatite-ceramic-coated femoral stems in revision hip surgery. *J Bone Joint Surg Br.* 2005;87(8):1055-60.

297. Ullmark G, Hallin G, Nilsson O. Impacted corticocancellous allografts and cement for revision of the femur component in total hip arthroplasty. *J Arthroplasty*. 2002;17(2):140-9.
298. Wagner H. [Revision prosthesis for the hip joint in severe bone loss]. *Orthopade*. 1987;16(4):295-300.
299. Walker PS, Schneeweis D, Murphy S, Nelson P. Strains and micromotions of press-fit femoral stem prostheses. *J Biomech*. 1987;20(7):693-702.
300. Valstar ER, Gill R, Ryd L, Flivik G, Borlin N, Kärrholm J. Guidelines for standardization of radiostereometry (RSA) of implants. *Acta Orthop*. 2005;76(4):563-72.
301. Valstar ER, Gill R, Ryd L, Flivik G, Borlin N, Kärrholm J. Guidelines for standardization of radiostereometry (RSA) of implants. *Acta Orthop*. 2005;76(4):563-72.
302. Valstar ER, Vrooman HA, Toksvig-Larsen S, Ryd L, Nelissen RG. Digital automated RSA compared to manually operated RSA. *J Biomech*. 2000;33(12):1593-9.
303. Weinstein RS, Roberson PK, Manolagas SC. Giant osteoclast formation and long-term oral bisphosphonate therapy. *N Engl J Med*. 2009;360(1):53-62.
304. Venesmaa PK, Kroger HP, Miettinen HJ, Jurvelin JS, Suomalainen OT, Alhava EM. Alendronate reduces periprosthetic bone loss after uncemented primary total hip arthroplasty: a prospective randomized study. *J Bone Miner Res*. 2001;16(11):2126-31.
305. White A. (Obituary). *Lancet*. 1849(1):324.
306. Wilkinson JM, Eagleton AC, Stockley I, Peel NE, Hamer AJ, Eastell R. Effect of pamidronate on bone turnover and implant migration after total hip arthroplasty: a randomized trial. *J Orthop Res*. 2005;23(1):1-8.
307. Wilkinson JM, Stockley I, Peel NE, Hamer AJ, Elson RA, Barrington NA, et al. Effect of pamidronate in preventing local bone loss after total hip arthroplasty: a randomized, double-blind, controlled trial. *J Bone Miner Res*. 2001;16(3):556-64.
308. Willert HG, Broback LG, Buchhorn GH, Jensen PH, Koster G, Lang I, et al. Crevice corrosion of cemented titanium alloy stems in total hip replacements. *Clin Orthop Relat Res*. 1996(333):51-75.
309. Wolff J. *Das Gesetz der Transformation der Knochen*. Berlin: Hirschwald. 1892.
310. von Knoch F, Jaquiere C, Kowalsky M, Schaeren S, Alabre C, Martin I, Rubash HE, Shanbhag AS. Effects of bisphosphonates on proliferation and osteoblast differentiation of human bone marrow stromal cells. *Biomaterials*. 2005;26(34):6941-9.
311. Woo RY, Morrey BF. Dislocations after total hip arthroplasty. *J Bone Joint Surg Am*. 1982;64(9):1295-306.
312. Wraighte PJ, Howard PW. Femoral impaction bone allografting with an Exeter cemented collarless, polished, tapered stem in revision hip replacement: a mean follow-up of 10.5 years. *J Bone Joint Surg Br*. 2008;90(8):1000-4.
313. Vresilovic EJ, Hozack WJ, Rothman RH. Incidence of thigh pain after uncemented total hip arthroplasty as a function of femoral stem size. *J Arthroplasty*. 1996;11(3):304-11.
314. Wroblewski BM. Direction and rate of socket wear in Charnley low-friction arthroplasty. *J Bone Joint Surg Br*. 1985;67(5):757-61.
315. Wroblewski BM, Fleming PA, Siney PD. Charnley low-friction torque arthroplasty of the hip. 20- to 30-year results. *J Bone Joint Surg Br*. 1999;81(3):427-30.
316. Yamaguchi K, Masuhara K, Ohzono K, Sugano N, Nishii T, Ochi T. Evaluation of periprosthetic bone-remodeling after cementless total hip arthroplasty. The influence of the extent of porous coating. *J Bone Joint Surg Am*. 2000;82-A(10):1426-31.
317. Yamaguchi K, Masuhara K, Yamasaki S, Fuji T, Seino Y. Effects of discontinuation as well as intervention of cyclic therapy with etidronate on bone remodeling after cementless total hip arthroplasty. *Bone*. 2004;35(1):217-23.
318. Yamaguchi K, Masuhara K, Yamasaki S, Nakai T, Fuji T. Cyclic therapy with etidronate has a therapeutic effect against local osteoporosis after cementless total hip arthroplasty. *Bone*. 2003;33(1):144-9.
319. Yamamoto K, Imakiire A, Shishido T, Masaoka T, Koizumi R, Ito K, et al. Cementless total hip arthroplasty using porous-coated Biomet acetabular cups (Hexloc and Ringloc types). *J Orthop Sci*. 2003;8(5):657-63.
320. Yamasaki S, Masuhara K, Yamaguchi K, Nakai T, Fuji T, Seino Y. Risedronate reduces postoperative bone resorption after cementless total hip arthroplasty. *Osteoporos Int*. 2007;18(7):1009-15.
321. Zhou ZK, Li MG, Borlin N, Wood DJ, Nivbrant B. No increased migration in cups with ceramic-on-ceramic bearing: an RSA study. *Clin Orthop Relat Res*. 2006;448:39-45.
322. Öztürkmen Y, Karamehmetoğlu M, Caniklioğlu M, Ince Y, Azboy I. Cementless hemiarthroplasty for femoral neck fractures in elderly patients. *Indian J Orthop*. 2008;42(1):56-60.

I

Periprosthetic proximal bone loss after uncemented hip arthroplasty is related to stem size

DXA measurements in 138 patients followed for 2–7 years

Olof G Sköldenberg, Henrik S G Bodén, Mats O F Salemyr, Torbjörn E Ahl and Per Y Adolphson

Division of Orthopaedics, Karolinska Institutet at Danderyd Hospital, Stockholm, Sweden

Correspondence OGS: olof.skoldenberg@ds.se

Submitted 05-03-15. Accepted 05-08-30

Background Periprosthetic bone loss occurs around uncemented femoral stems and may be influenced by the stem size.

Patients and methods We studied 138 consecutive patients, 3 (2–7) years on average after a total hip arthroplasty operation (THA) for unilateral osteoarthritis with the Bi-Metric uncemented femoral stem. We analyzed Harris hip score and bone mineral density.

Results The mean Harris hip score was 97 at follow-up. Bone mineral density decreased proximally by 19% in both Gruen zones 1 and 7. Bone loss in zones 1, 2, 6, and 7 was significantly associated with stem size. Distally, a small gain in bone mass was found in zones 3 and 5 for medium femoral sizes.

Interpretation We found a marked proximal BMD loss, especially for the larger stems, which may be specific for this particular implant. Long-term studies should reveal whether this proximal bone loss will affect the longevity of the THA.

In recent years, the most common designs with porous-coated femoral components or those with ceramic coating such as hydroxyapatite have shown promising mid-term results (McLaughlin and Lee 1997, McNally et al. 2000). However, a remodeling of the periprosthetic bone of the proximal femur has been noted and gives cause for concern (Dorr et al. 1997, Khalily and Whiteside

1998). A well-fixed stem distally seems to cause stress-shielding, with proximal bone resorption (Engh et al. 1992, Kilgus et al. 1993). Prosthetic designs with only proximal coating (Khalily and Whiteside 1998), iso-elastic materials (Jacobsson et al. 1993, Ang et al. 1997) and short femoral components (Morrey et al. 2000) have all been designed to reduce this remodeling.

One long-standing concern is that asymptomatic bone loss may lead to implant subsidence, aseptic loosening or periprosthetic fractures around the stem. One factor known to influence the periprosthetic BMD is stem size of the femoral implant (Huiskes et al. 1992, Nishii et al. 1997), especially after insertion of a stem with a large diameter (Maloney et al. 1996). To achieve “fit and fill”, uncemented stems are typically larger than cemented stems. From a mechanical standpoint, increased stem size results in increased stiffness and subsequently to greater stress-shielding. We have previously found remodeling and proximal bone loss after uncemented THA with the Bi-Metric femoral stem (Bodén and Adolphson 2004). Changes in periprosthetic BMD after THA can be assessed with high precision by DXA (Cohen and Rushton 1995, Venesmaa et al. 2001). This study was undertaken to investigate the extent of periprosthetic bone loss and its relationship to femoral stem size after implantation of the uncemented Bi-Metric femoral stem.

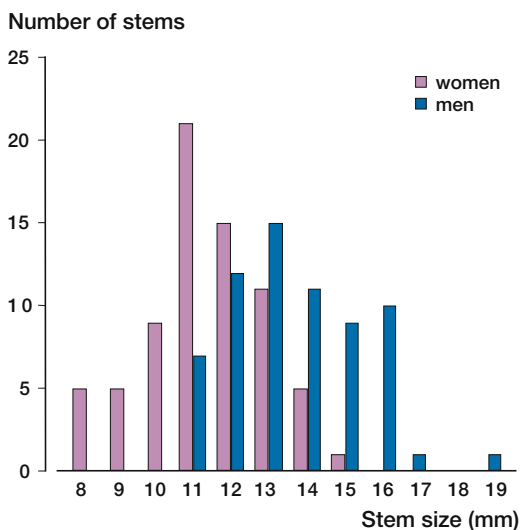


Figure 1. The distribution of femoral stem diameters.

Patients and methods

179 primary unilateral THAs were performed with the uncemented Bi-Metric femoral implant at Danderyd Hospital from 1997 through 2001. 31 patients were excluded from this study (because of rheumatoid arthritis in 15 patients, peroperative or postoperative fractures of the femur in 7, corticosteroid treatment as a result of systemic illness in 6, congenital hip dysplasia with abnormal anatomy of the proximal femur in 2, and peroperative damage to the sciatic nerve in 1). 10 other patients were lost to follow-up (4 died, 2 refused to participate and 4 could not be reached). Thus, 138 patients (66 men) with the following characteristics were included in the study: mean age 58 (37–91) years, mean weight 81 (47–120) kg, and mean height 171 (146–198) cm. The patients were operated on because of primary arthrosis (89%), congenital hip dysplasia (4%), posttraumatic arthritis (2%), and other diseases (5%). The distribution of stem sizes in the patients is shown in Figure 1.

All patients were operated on through a standard posterior approach. A 28-mm cobalt-chrome head was used for all patients. On the acetabular side, the patients received either an uncemented hydroxyapatite-coated cup with a cylindrical polyethylene liner (74 patients) or a cemented polyethylene cup (64 patients). After surgery, the patients were mobilized on the day after the operation. Postoperative

weight bearing was individualized according to the surgeon's wishes. No protocol regarding weight bearing or use of crutches was used.

Within 6 weeks of surgery, 16 non-fatal complications (7 superficial wound infections that required antibiotics, 4 deep venous thromboses, 3 pulmonary emboli, and 2 myocardial infarctions) were diagnosed. All patients were studied after a mean of 41 (24–80) months after surgery, which included clinical examination, radiographical assessment and DXA measurement.

We recorded Harris hip score. Standard antero-posterior and lateral radiographs were taken immediately after surgery and at the time of survey. All radiographs were examined for prosthetic migration and remodeling changes (Engh et al. 1990).

The BMD of the periprosthetic femur was measured in the coronal plane by DXA (DPX-L, Lunar Co., Madison, WI). Avoiding interference from the femoral implant, the software detected the interface between the bony part and the prosthesis stem on the basis of density changes and simulated the stem in the form of a prosthesis mask, which was superimposed on the healthy side. The healthy hip was scanned at the corresponding level and BMD in 7 regions of interest, based on Gruen zones, was analyzed. The values were expressed as areal BMD in g/cm^2 . The differences in BMD were compared with stem size and correlated to sex, age, weight, height, body mass index, implant time, initial BMD—expressed as BMD on the healthy femur—and Harris hip score.

To estimate the precision error of the DXA method, we had previously made double measurements in 10 patients with complete repositioning of the patients and the scanner. The precision error was found to be 2.3% in Gruen zone 1, 1.0% in zone 2, 2.0% in zone 3, 3.5% in zone 4, 4.2% in zone 5, 1.3% in zone 6, and 3.7% in zone 7 (Bodén and Adolphson 2004). This precision is of the same order as reported by Kilgus et al. (1993) and Nishii et al. (1997).

The investigation was approved by the ethics committee of Karolinska Hospital (D.nr approval no. 04-011/3). The patients also gave their informed consent before inclusion into the study.

Statistics

The mean values (SD) were calculated for absolute

BMD in the 7 Gruen zones for all stem sizes. Mean values (SD)

Gruen zone	Operated side (g/cm ²)	Unoperated side (g/cm ²)	Change (%)
1	0.85 (0.16)	1.05 (0.17)	-19 (11)
2	1.81 (0.28)	1.85 (0.26)	-2 (10)
3	2.00 (0.25)	1.92 (0.25)	+5 (8)
4	1.91 (0.29)	1.95 (0.26)	-2 (9)
5	2.09 (0.23)	1.99 (0.23)	+5 (7)
6	1.78 (0.28)	1.87 (0.23)	-5 (10)
7	1.09 (0.29)	1.35 (0.24)	-19 (15)

change and percentage change in BMD. Student's t-test was used to analyze the difference between the legs (paired observations) and also the differences between stem sizes in the different Gruen zones (unpaired observations). To investigate factors that may influence bone remodeling, we used the Pearson's product moment correlation coefficient to analyze the relationship between BMD and sex, age, weight, height, body mass index, implant time, initial BMD—expressed as BMD on the healthy femur—and Harris hip score. The statistical analyses were performed with the statistical package JMP (SAS Institute Inc., Cary, NC). Dif-

ferences were considered significant at p-values of less than 0.05.

Results

At follow-up, the mean Harris hip score was 97 (63–100) points with only 6 patients having slight thigh pain. There were no signs of stem loosening.

The mean BMD values and the percentage change for all implants in the different Gruen zones are summarized in the table. BMD loss most pronounced in zones 1 and 7 (Figure 2). All stem sizes caused significant bone loss in zone 1 (Figure 3). There was a decrease of 2% in zone 2. The 15-mm and 16-mm stems lost 8% and 9%, respectively, and these were the only stems that gave statistically significant losses ($r^2 = 0.091$, $p < 0.001$). The BMD in zone 3 showed a gain of 5%. Stem sizes of 10 mm (7%), 12 mm (7%), 13 mm (5%), 14 mm (5%) and 15 mm (5%) were significantly increased. No correlation between stem size and BMD gain was found. In zone 4, a BMD loss of 2% was found. Stem size 11 mm decreased by 5% and was the only size that showed significant change. We found

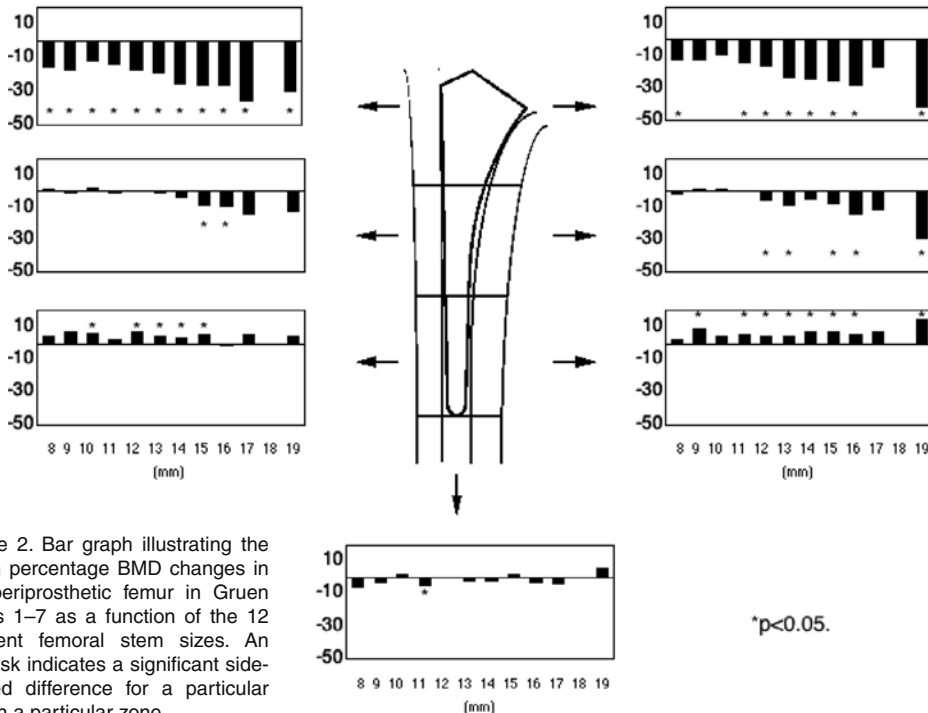


Figure 2. Bar graph illustrating the mean percentage BMD changes in the periprosthetic femur in Gruen zones 1–7 as a function of the 12 different femoral stem sizes. An asterisk indicates a significant side-related difference for a particular size in a particular zone.

*p<0.05.

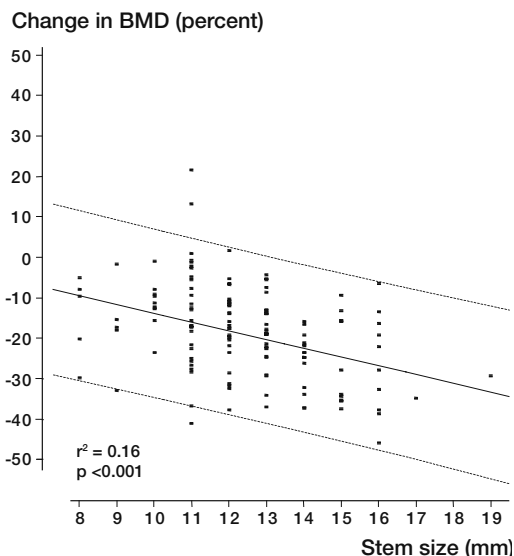


Figure 3. Correlation between stem size and BMD ratio (percentage of the contralateral value) in Gruen zone 1. Regression line and 95% confidence intervals are given.

no correlation between stem size and bone loss in this zone. A gain of 5% was found in zone 5. Sizes 9 mm, 11–16 mm, and 19 mm were all significantly increased with a gain of 4–15%. However, we found no correlation between stem size and change in BMD. In zone 6, there was a BMD loss of 5%. Stem sizes 12 mm (–5%), 13 mm (–7%), 15 mm (–7%), 16 mm (–14%), and 19 mm (–29%) were significantly reduced. The correlation analysis indicated a strong relationship between stem size and bone loss ($r^2 = 0.16$, $p < 0.001$). Finally, in zone 7, the mean BMD loss was 19%. The correlation analysis yielded $r^2 = 0.14$, $p < 0.001$ (Figure 4).

Multiple regression analysis with stem size as the control variable showed no correlation between bone loss of the operated femur in any zone and sex, age, weight, height, body mass index, implant time, initial BMD—expressed as BMD on the healthy femur—or Harris hip score. In addition, we did not find any difference in BMD loss in any zone between the patients who received an uncemented hydroxyapatite-coated cup and those who received a cemented polyethylene cup.

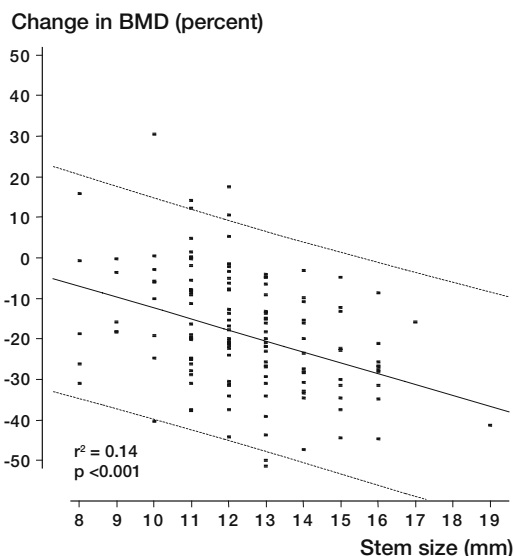


Figure 4. Correlation between stem size and BMD ratio (percentage of the contralateral value) in Gruen zone 7. Regression line and 95% confidence intervals are given.

Discussion

The clinical outcomes in our study are similar to those of other studies with the Bi-Metric stem and other uncemented porous-coated THAs from a mid-term standpoint (Robertsen et al. 1996, Meding et al. 2004). Most patients had an excellent clinical outcome, with only 6 patients (4%) complaining of slight thigh pain, and there was no loosening of any stem. We did, however, find pronounced bone resorption of the proximal femur. There is concern that bone loss may lead to osteolysis, with loosening of the stem or a periprosthetic fracture. Although there is no evidence that bone resorption causes clinical symptoms or complications, a large amount of—or continuous—femoral bone resorption may reduce the stability of the stem.

Retrospective studies using contralateral comparisons have shown a 40% decrease in proximal femoral BMD after 7–14 years (McCarthy et al. 1991). Kilgus et al. (1993) noted largest BMD loss (35%) in the most proximal 1 cm of the medial femoral cortex. Longitudinal studies have also been performed (Trevisan et al. 1997, Venesmaa et al. 2001), confirming the results of cross-sectional studies.

There was a significant correlation between stem size and periprosthetic change in BMD in zones

1, 2, 6 and 7. Stress-shielding and disuse atrophy are considered to be the main factors contributing to BMD loss after THA (Engh and Bobyn 1988, Bryan et al. 1996). Engh et al. (1987) noted that stems equal to or greater than 13.5 mm showed 5 times the amount of resorption of those 12 mm or less. The concept of stems that mimic the elasticity of the normal femur, i.e. isoelastic stems, was introduced to reduce stress-shielding and subsequent bone loss (Morscher and Mathys 1974, Butel and Robb 1988). Earlier isoelastic stems have suffered from early loosening and a high revision rate (Nistor et al. 1991, Jacobsson et al. 1993, Niinimäki et al. 1994). However, Glassman et al. (2001) and Kärrholm et al. (2002) presented good results with the Epoch isoelastic stem.

DXA is an accurate and reproducible method for measurement of bone remodeling (Kalender 1992). It is possible to measure the quantity of bone near a metallic implant accurately (Kiratli et al. 1996, Kröger et al. 1996, 1997). The accuracy error of DXA in the femur is less than 3% (Barden and Mazess 1989). The precision error of the method is also low: 1.1–5.3% (Cohen and Rushton 1995, Kröger et al. 1996). We have previously found a precision error of the same order (Bodén and Adolphson 2004).

A large degree of bone loss of the proximal femur has been identified in longitudinal studies as early as 3–6 months after implantation of an uncemented stem; thereafter, the BMD stabilizes during the first postoperative year (Marchetti et al. 1996, Nishii et al. 1997, Wixson et al. 1997, Kröger et al. 1998). None of our patients were measured until 2 years after surgery. We could not find any correlation between implant time and bone loss in any zone, and we therefore conclude that one can use varying follow-up time beyond 2 years.

Factors that could influence periprosthetic bone remodeling after THA include sex, age, weight, density of bone, activity level, diagnosis, disease state, medications, duration of implantation, and stem stiffness. Different researchers have found conflicting results regarding the effect of anthropometrical factors on bone remodeling. Thus, Brodner et al. (2004) found a correlation between gender and BMD in most Gruen zones, and between age and BMD in Gruen zones 1 and 7. However, Korovessis et al. (1997) did not find any

correlation between age and BMD changes; only body mass index correlated with BMD in zone 3 in their study. Kärrholm et al. (2002) evaluated possible confounding factors (sex, age, weight, diagnosis, BMD and stem size) immediately after the operation, and found that periprosthetic BMD was influenced only by stem design. Kiratli et al. (1996) reported that weight was the only variable that affected bone remodeling. Maloney et al. (1996) found that patients with low weight lost more bone distally. We could not find any correlation between anthropometrical factors and BMD loss.

There is controversy as to whether preoperative BMD predicts the rate of bone loss after THA. Some authors have found that the lower the BMD is before the THA, the larger the BMD loss becomes after the THA (Nishii et al. 1997). However, Aldinger et al. (2003) did not find any correlation between initial BMD and degree of periprosthetic bone loss. Using multiple regression analysis with stem size as control variable, we could not find any correlation between BMD loss on the operated side and initial BMD (expressed as BMD on the unoperated side) in any zone.

Bone atrophy depends on stem elasticity (Ang et al. 1997): the stiffer the stem, the greater the atrophy (Bobyn et al. 1992). Also, femoral stem size and amount of hydroxyapatite coating may influence BMD (Bobyn et al. 1992). Some authors have found a correlation between femoral stem size and proximal bone loss (Engh and Bobyn 1988, Nishii et al. 1997), while other investigators have found no such correlation (Petersen et al. 1995, Yamaguchi et al. 2000, Sychterz et al. 2001). Petersen et al. (1995) concluded that the Taperloc prosthesis design transferred the load in a way that made the stem size of minor importance. However, these authors used a prosthesis with sizes ranging from 7.5 to 15 mm and studied only 22 patients, so the number of hips of any specific size was probably too low. Thus, it is doubtful whether their study had sufficient power to indicate whether size is associated with bone loss with this prosthesis.

Our investigation has some limitations. It is a cross-sectional study in which periprosthetic BMD is compared to the value of the healthy side. This could be a cause of error because of a possible side-related difference in bone mass preoperatively. Some authors have found a lower BMD on the

arthrosis side before operation (Kiratli et al. 1996, Martini et al. 1999). Thus, the BMD difference found in cross-sectional studies could be overestimated, and only a longitudinal study would give more accurate information about the remodeling process. In a cross-sectional study, it is important to perform the investigation after the changes have stabilized. We found no correlation between duration of implantation and BMD changes in any zone; thus, we conclude that a longer implant time would not have affected the results. Also, Hughes et al. (1995) considered that approximately 3 years—after which time most remodeling was complete—is an optimum time to assess atrophy of the proximal femur.

In conclusion, we found that this uncemented femoral prosthesis induced a large degree of bone loss in proximal periprosthetic zones. Intervention with antiresorptive drugs should be considered to inhibit this bone loss. Long-term studies will reveal whether this proximal bone loss is a negative factor for the longevity of this uncemented THA.

The study was supported by research grants from the Emil and Maria Palm Foundation and the Ulla and Gustaf af Uggle Foundation, Sweden. We are also indebted to the Department of Nuclear Medicine, Danderyd Hospital—especially to radiology assistant Hans-Jerker Lundberg—for technical assistance with the DXA analyses, and to Pål Bergström and Siri Backhans for help with statistical analysis.

Contributions of authors

OS examined all patients, collected the data and prepared the manuscript. HB and MS performed the clinical investigations and wrote manuscript. The senior authors, TA and PA, designed the study and supervised the statistical analyses.

- Aldinger P R, Sabo D, Pritsch M, Thomsen M, Mau H, Ewerbeck V, Breusch S J. Pattern of periprosthetic bone remodeling around stable uncemented tapered hip stems: a prospective 84-month follow-up study and a median 156-month cross-sectional study with DXA. *Calcif Tissue Int* 2003; 73 (2): 115-21.
- Ang K C, Das De S, Goh J C H, Low S L, Bose K. Periprosthetic bone remodelling after cementless total hip replacement. A prospective comparison of two different implant designs. *J Bone Joint Surg (Br)* 1997; 79 (4): 675-9.
- Barden H S, Mazess R B. Bone densitometry of the appendicular and axial skeleton. *Top Geriatr Rehabil* 1989; 4 (2): 1-12.
- Bobyn J D, Mortimer E S, Glassman A H, Engh C A, Miller J E, Brooks C E. Producing and avoiding stress shielding. Laboratory and clinical observations of noncemented total hip arthroplasty. *Clin Orthop* 1992; (274): 79-96.
- Bodén H, Adolphson P. No adverse effects of early weight bearing after uncemented total hip arthroplasty. A randomized study of 20 patients. *Acta Orthop Scand* 2004; 75 (1): 21-9.
- Brodner W, Bitzan P, Lomoschitz F, Krepler P, Jankovsky R, Lehr S, Kainberger F, Gottsauner-Wolf F. Changes in bone mineral density in the proximal femur after cementless total hip arthroplasty. A five-year longitudinal study. *J Bone Joint Surg (Br)* 2004; 86 (1): 20-6.
- Bryan J M, Sumner D R, Hurwitz D E, Tompkins G S, Andriacchi T P, Galante J O. Altered load history affects periprosthetic bone loss following cementless total hip arthroplasty. *J Orthop Res* 1996; 14 (5): 762-8.
- Butel J, Robb J E. The isoelectric hip prosthesis followed for 5 years. *Acta Orthop Scand* 1988; 59 (3): 258-62.
- Cohen B, Rushton N. Accuracy of DEXA measurement of bone mineral density after total hip arthroplasty. *J Bone Joint Surg (Br)* 1995; 77 (3): 479-83.
- Dorr L D, Lewonowski K, Lucero M, Harris M, Wan Z. Failure mechanisms of anatomic porous replacement I cementless total hip replacement. *Clin Orthop* 1997; (334): 157-67.
- Engh C A, Bobyn J D. The influence of stem size and extent of porous coating on femoral bone resorption after primary cementless hip arthroplasty. *Clin Orthop* 1988; (231): 7-28.
- Engh C A, Bobyn J D, Glassman A H. Porous-coated hip replacement. The factors governing bone ingrowth, stress shielding, and clinical results. *J Bone Joint Surg (Br)* 1987; 69 (1): 45-55.
- Engh C A, Massin P, Suthers K E. Roentgenographic assessment of the biologic fixation of porous-surfaced femoral components. *Clin Orthop* 1990; 257: 107-28.
- Engh C A, McGovern T F, Bobyn J D, Harris W H. A quantitative evaluation of periprosthetic bone-remodeling after cementless total hip arthroplasty. *J Bone Joint Surg (Am)* 1992; 74 (7): 1009-20.
- Glassman A H, Crowninshield R D, Schenck R, Herberts P. A low stiffness composite biologically fixed prosthesis. *Clin Orthop* 2001; (393): 128-36.
- Hughes S S, Furia J P, Smith P, Pellegrini V D Jr. Atrophy of the proximal part of the femur after total hip arthroplasty without cement. A quantitative comparison of cobalt-chromium and titanium femoral stems with use of dual x-ray absorptiometry. *J Bone Joint Surg (Am)* 1995; 77 (2): 231-9.
- Huiskes R, Weinans H, van Rietbergen B. The relationship between stress shielding and bone resorption around total hip stems and the effects of flexible materials. *Clin Orthop* 1992; (274): 124-34.
- Jacobsson S A, Djerf K, Gillquist J, Hammerby S, Ivarsson I. A prospective comparison of Butel and PCA hip arthroplasty. *J Bone Joint Surg (Br)* 1993; 75 (4): 624-9.
- Kalender W A. Effective dose values in bone mineral measurements by photon absorptiometry and computed tomography. *Osteoporos Int* 1992; 2 (2): 82-7.

- Kärholm J, Anderberg C, Snorrason F, Thanner J, Langeland, N, Malchau H, Herberts P. Evaluation of a femoral stem with reduced stiffness. *J Bone Joint Surg (Am)* 2002; 84 (9): 1651-8.
- Khalily C, Whiteside L A. Predictive value of early radiographic findings in cementless total hip arthroplasty femoral components: an 8- to 12-year follow-up. *J Arthroplasty* 1998; 13 (7): 768-73.
- Kilgus D J, Shimaoka E E, Tipton J S, Eberle R W. Dual-energy X-ray absorptiometry measurement of bone mineral density around porous-coated cementless femoral implants. Methods and preliminary results. *J Bone Joint Surg (Br)* 1993; 75 (2): 279-87.
- Kiratli B J, Checovich M M, McBeath A A, Wilson M A, Heiner J P. Measurement of bone mineral density by dual-energy x-ray absorptiometry in patients with the Wisconsin hip, an uncemented femoral stem. *J Arthroplasty* 1996; 11 (2): 184-93.
- Korovessis P, Droutsas P, Piperos G, Michael A, Baikousis A, Stamatakis M. Course of bone mineral content changes around cementless Zweymüller total hip arthroplasty. A 4-year follow-up study. *Arch Orthop Trauma Surg* 1997; 116 (1-2): 60-5.
- Kröger H, Miettinen H, Arnala I, Koski E, Rushton N, Suomalainen O. Evaluation of periprosthetic bone using dual-energy x-ray absorptiometry: precision of the method and effect of operation on bone mineral density. *J Bone Miner Res* 1996; 11 (10): 1526-30.
- Kröger H, Vanninen E, Overmyer M, Miettinen H, Rushton N, Suomalainen O. Periprosthetic bone loss and regional bone turnover in uncemented total hip arthroplasty: a prospective study using high resolution single photon emission tomography and dual-energy X-ray absorptiometry. *J Bone Miner Res* 1997; 12 (3): 487-92.
- Kröger H, Venesmaa P, Jurvelin J, Miettinen H, Suomalainen O, Alhava E. Bone density at the proximal femur after total hip arthroplasty. *Clin Orthop* 1998; (352): 66-74.
- Maloney W J, Sychterz C, Bragdon C, McGovern T, Jasty M, Engh C A, Harris W H. The Otto Aufranc Award. Skeletal response to well fixed femoral components inserted with and without cement. *Clin Orthop* 1996; (333): 15-26.
- Marchetti M E, Steinberg G G, Greene J M, Jenis L G, Baran D T. A prospective study of proximal femur bone mass following cemented and uncemented hip arthroplasty. *J Bone Miner Res* 1996; 11 (7): 1033-9.
- Martini F, Kremling E, Schmidt B, Sell S, Mayer F. Bone mineral density of the proximal femur after unilateral cementless total hip replacement. *Int Orthop (SICOT)* 1999; 23 (2): 104-6.
- McCarthy C K, Steinberg G G, Ågren M, Leahey D, Wyman E, Baran D T. Quantifying bone loss from the proximal femur after total hip arthroplasty. *J Bone Joint Surg (Br)* 1991; 73 (5): 774-8.
- McLaughlin J R, Lee K R. Total hip arthroplasty with an uncemented femoral component. Excellent results at ten-year follow-up. *J Bone Joint Surg (Br)* 1997; 79 (6): 900-7.
- McNally S A, Shepperd J A, Mann C V, Walczak J P. The results at nine to twelve years of the use of a hydroxyapatite-coated femoral stem. *J Bone Joint Surg (Br)* 2000; 82 (3): 378-82.
- Meding J B, Keating E M, Ritter M A, Faris P M, Berend M E. Minimum ten-year follow-up of a straight-stemmed, plasma-sprayed, titanium-alloy, uncemented femoral component in primary total hip arthroplasty. *J Bone Joint Surg (Am)* 2004; 86 (1): 92-7.
- Morrey B F, Adams R A, Kessler M. A conservative femoral replacement for total hip arthroplasty. A prospective study. *J Bone Joint Surg (Br)* 2000; 82 (7): 952-8.
- Morscher E, Mathys R. Total isoelastic hip prosthesis implanted without cement. Initial results. *Acta Orthop Belg* 1974; 40 (5-6): 639-47.
- Niinimäki T, Puranen J, Jalovaara P. Total hip arthroplasty using isoelastic femoral stems. A seven to nine-year follow-up in 108 patients. *J Bone Joint Surg (Am)* 1994; 76 (3): 413-8.
- Nishii T, Sugano N, Masuhara K, Shibuya T, Ochi T, Tamura S. Longitudinal evaluation of time related bone remodeling after cementless total hip arthroplasty. *Clin Orthop* 1997; (339): 121-31.
- Nistor L, Blaha J D, Kjellström U, Selvik G. In vivo measurements of relative motion between an uncemented femoral total hip component and the femur by roentgen stereophotogrammetric analysis. *Clin Orthop* 1991; (269): 220-7.
- Petersen M B, Kolthoff N, Eiken P. Bone mineral density around femoral stems. DXA measurements in 22 porous-coated implants after 5 years. *Acta Orthop Scand* 1995; 66 (5): 432-4.
- Robertsen K, Gaarden M, Teichert G, Langhoff O. Results of the total Bi-Metric cementless hip arthroplasty. *Orthopedics* 1996; 19 (8): 673-4.
- Sychterz C J, Topoleski L D, Sacco M, Engh C A. Effect of femoral stiffness on bone remodeling after uncemented arthroplasty. *Clin Orthop* 2001; (389): 218-27.
- Trevisan C, Bigoni M, Randelli G, Marinoni E C, Peretti G, Ortolani S. Periprosthetic bone density around fully hydroxyapatite coated femoral stem. *Clin Orthop* 1997; (340): 109-17.
- Venesmaa P K, Kröger H P, Miettinen H J, Jurvelin J S, Suomalainen O T, Alhava E M. Monitoring of periprosthetic BMD after uncemented total hip arthroplasty with dual-energy X-ray absorptiometry - a 3-year follow-up study. *J Bone Miner Res* 2001; 16 (6): 1056-61.
- Wixson R L, Stulberg S D, Van Flandern G J, Puri L. Maintenance of proximal bone mass with an uncemented femoral stem analysis with dual-energy x-ray absorptiometry. *J Arthroplasty* 1997; 12 (4): 365-72.
- Yamaguchi K, Masuhara K, Ohzono K, Sugano N, Nishii T, Ochi T. Evaluation of periprosthetic bone remodeling after cementless total hip arthroplasty. The influence of the extent of porous coating. *J Bone Joint Surg (Am)* 2000; 82 (10): 1426-31.

II

Good results with an uncemented proximally HA-coated stem in hip revision surgery

62 hips followed for 2–13 years

Mats O F Salemyr, Olof G Sköldenberg, Henrik S G Bodén, Torbjörn E Ahl, and Per Y Adolphson

Department of Clinical Sciences at Danderyd Hospital, Karolinska Institutet, Stockholm, Sweden

Correspondence PYA: per.adolphson@ds.se

Submitted 07-03-18. Accepted 07-09-02

Background and purpose Proximal bone loss due to stress-shielding is a matter of concern after uncemented femoral hip revision. We have used short, proximally hydroxyapatite-coated prostheses in revision since 1989, and we now report the results.

Methods 60 patients (62 hips) were revised because of aseptic loosening. Bone defects prior to revision were mostly of type II according to the Gustilo-Pasternak and Endo-Klinik classifications. Follow-up time was 73 (24–161) months. 9 patients had died before follow-up; 8 of these still had the stem in place. Clinical assessment was performed with the Harris hip score. Radiographs were evaluated for bone defects at revision, postoperative stem fixation, and periprosthetic bone remodeling.

Results Mean Harris hip score was 75 (30–100) points. There was no stem loosening or progressive subsidence. 8 patients had mild to moderate thigh pain. Osteolysis, present at revision, had diminished, partially or completely, in four-fifths of the hips at follow-up. 4 hips had required re-revision due to fracture or dislocation. The 6-year prosthesis survival rate was 95% (95% CI: 0.83–0.98).

Interpretation Uncemented revision with a short, proximally hydroxyapatite-coated prosthesis is a reliable procedure with encouraging results in the medium term if bone defects at revision are moderate.

an unacceptably high failure rate (Dohmae et al. 1988, Eisler et al. 2000, Haydon et al. 2004). This method might be chosen in the elderly patient with low demands regarding activity. In active patients with a poor bone stock, hip revision with cement and impacted morselized allograft bone has shown good long-term results (Gie et al. 1993, Ornstein et al. 2002, Ullmark et al. 2002, Halliday et al. 2003). Uncemented hip revision after aseptic loosening has been promising in the short to medium term (Bohm and Bischel 2001, Moreland and Moreno 2001, Trikha et al. 2005) and also in the long term (Wagner 1987, Paprosky et al. 1999, Raman et al. 2005, Reikerås and Gunderson 2006). Most stems used in these studies are long-stemmed, extensively coated, or distally anchored. A disadvantage with these stems is the transfer of excessive load distally, leading to diminished proximal bone stock. Stress-shielding could lead to an increased risk of periprosthetic fractures and even stem loosening (Engh et al. 1987, Huiskes 1990). Several studies of proximally coated uncemented stems in hip revision have shown a high incidence of failure due to aseptic loosening or fracture (Berry et al. 1995, Malkani et al. 1996, Mulliken et al. 1996). The reason for this is insufficient fixation of the implant in the proximal metaphysis due to poor bone stock. However, Kelly et al. (2006) reported good results with a proximally coated stem in hip revision. We have used a similar stem and now report our results.

Cemented revision for prosthetic loosening after cemented total hip arthroplasty (THA) has shown

Patients and methods

Patients

All patients who had been reoperated at the Orthopedic Department of Danderyd Hospital with the proximally porous- and HA-coated tapered Bi-Metric stem between 1989 and 2002 due to aseptic loosening were included in the study. We used this prosthesis for revision in younger patients and in elderly patients who had a good bone stock. 62 hips in 60 patients were reoperated (Table 1). The index diagnoses were primary osteoarthritis (44 hips), fractures and related complications (9 hips), inflammatory arthritis (5 hips), and developmental dysplasia (4 hips). The mean time between the first hip arthroplasty and the revision was 7 (1–19) years. 41 of the hips had been operated only once in the same hip before revision. Mean follow-up time was 6 (2–13) years. At follow-up, 9 of the 60 patients had died. 1 of these had been re-revised 3 months after the uncemented stem revision due to a fracture adjacent to a peroperative fenestration. The other 8 patients still had their stem in place. No stem-related problems were found in these patients. 1 patient had only attended the radiographic part of the study.

Implant

The patients were reoperated with the Bi-Metric femoral stem (Biomet Inc., Warsaw, IN, USA). This is a collarless, tapered stem (3°) made of titanium alloy, where the proximal 30% of the stem has a porous-coated (100–200 µm) surface with plasma-sprayed HA (thickness 40–70 µm, crystallinity 50–70%, purity > 95%). The distal 70% has a textured surface. The femoral component is available in 13 proportional sizes and has a modular head of cobalt chrome. Only 1 offset option was available.

Surgery

All operations were performed using a posterior approach. 53 of the 62 revised stems were cemented and 9 were uncemented; 1 of these was a hemiarthroplasty. Bone grafting around the neck of the stem was carried out simultaneously in 33 of the cases. In 24 of the operations, only the stem was revised. At follow-up, 39 of the patients had a cemented polyethylene cup and 21 patients an

Table 1. Demographic data for the patients

Age at follow-up, years ^a	65 (35–84)
Male / female	37 / 23
Weight, kg ^a	81 (51–128)
Height, cm ^a	174 (159–191)
BMI ^a	27 (18–39)
Harris hip score at follow-up ^a	75 (30–100)
Charnley clinical classification (A / B / C)	17 / 11 / 26
^a mean (range)	

uncemented cup. The patients were mobilized on the day after the revision under the supervision of a physiotherapist. Postoperative weight bearing was individualized according to the preferences of the surgeon.

Clinical evaluation

We evaluated the patients clinically with an interview and physical examination performed by one of the authors (MS) who had not been involved in the operations. We categorized the patients according to Charnley's clinical classification (Charnley 1972). At follow-up, 26 patients were classified as belonging to class C, i.e. they had disabilities other than the hip that interfered with their functional capacity (Table 1).

Clinical outcome was assessed with the Harris hip score (HHS) and with questions concerning mid-thigh pain. The mid-thigh pain was graded by the patient as mild, moderate, or severe.

Radiographic evaluation

Standardized anteroposterior and lateral radiographs after the index operation were compared with radiographs taken before and immediately after the revision, and with radiographs taken at the time of survey. A coefficient—the ratio of the actual diameter and the measured diameter of the femoral head—was calculated for each radiograph and was used to adjust all measurements for magnification.

We analyzed the radiographs in order to address 3 particular issues. Firstly, we classified bone defects prior to revision surgery. Secondly, we determined the degree of fixation of the stem, and thirdly, the amount of the periprosthetic bone remodeling. We classified bone defects according to the classifications of Gustilo and Pasternak (1988) and Endo-

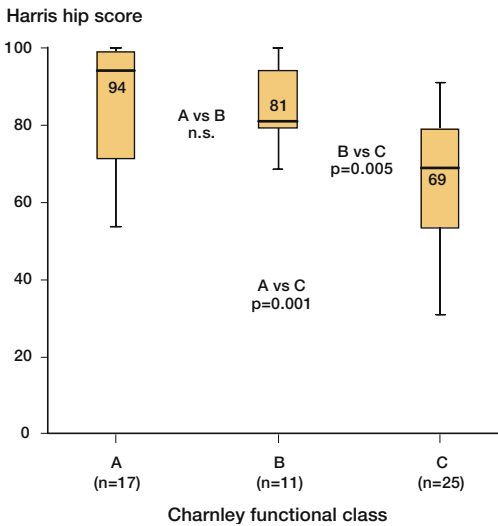


Figure 1. Box plot of Harris hip score (53 hips) in the different Charnley classes. (HHS; median, quartile and extreme values).

Klinik (Engelbrecht and Siegel 1989). Stem fixation was assessed using the criteria of Engh's fixation/stability score (FSS) for uncemented femoral implants (Engh et al. 1990): absence/appearance of endosteal bone bridges (spot welds), absence/appearance of reactive lines in the coated region of the stem, absence/appearance of reactive lines in the uncoated region, pedestal formation, calcar modeling, and interface deterioration (widening radiolucent lines). Migration of the femoral implant was defined as a change in the vertical distance between the easily identified inferior border of the coating to the most medial point of the lesser trochanter or as any change in alignment or rotation. The subsidence was considered definite if the change was more than 4 mm (Malchau et al. 1995).

We also assessed presence of focal osteolysis (scalloping) with defined borders and distal cortical hypertrophy, defined as new enlargement of the external femoral diameter around the distal part of the prosthesis, compared to the radiographs taken immediately postoperatively. We recorded the radiographic changes according to Gruen zones on the anteroposterior radiographs. Heterotopic ossification was recorded using the grading system of Brooker et al. (1973).

According to the Ethics Board of Karolinska Institutet, no permission was required for this

Table 2. Femoral bone defects at revision (53 hips)

Type	Gustilo and Pasternak	Endo-Klinik
I	17	4
II	35	38
III	1	11
IV	0	0

study (04-453/3). The investigation was approved by the committee for protection against radiation at Danderyd Hospital (2003-3).

Statistics

We used the Mann-Whitney U test for non-parametric variables (independent groups) to assess the association between HHS and Charnley's clinical classification. The statistical analyses were performed with the statistical package JMP 6.0 (SAS Institute, Cary, NC). The results were considered significant at p-values of < 0.05.

Results

Clinical results

Between the femoral revision operation and the follow-up, 5 patients had undergone a cup revision. At follow-up, the mean HHS score was 75 (30–100) points. 23 of the patients had a good or excellent result with an HHS of > 79 points, 18 patients had a poor outcome (HHS of < 70 points). We noted a lower HHS for patients in Charnley's class C compared to patients in class A ($p < 0.001$) and B ($p < 0.005$) (Figure 1). We found no difference in HHS between patients with different types of bone defects at revision. 4 patients complained of mild thigh pain and 4 other patients of moderate pain. None of the patients suffered from severe thigh pain. 28 patients used no support for walking and 28 patients had no limp at all.

Radiographic results

Bone defects were mostly of type II in both classifications, and no type IV defect was observed (Table 2). We saw no stem loosening. All stems showed several signs of rigid fixation. In 30 hips, endosteal bone bridges (spot welds) were noted and there was a total absence of reactive lines in

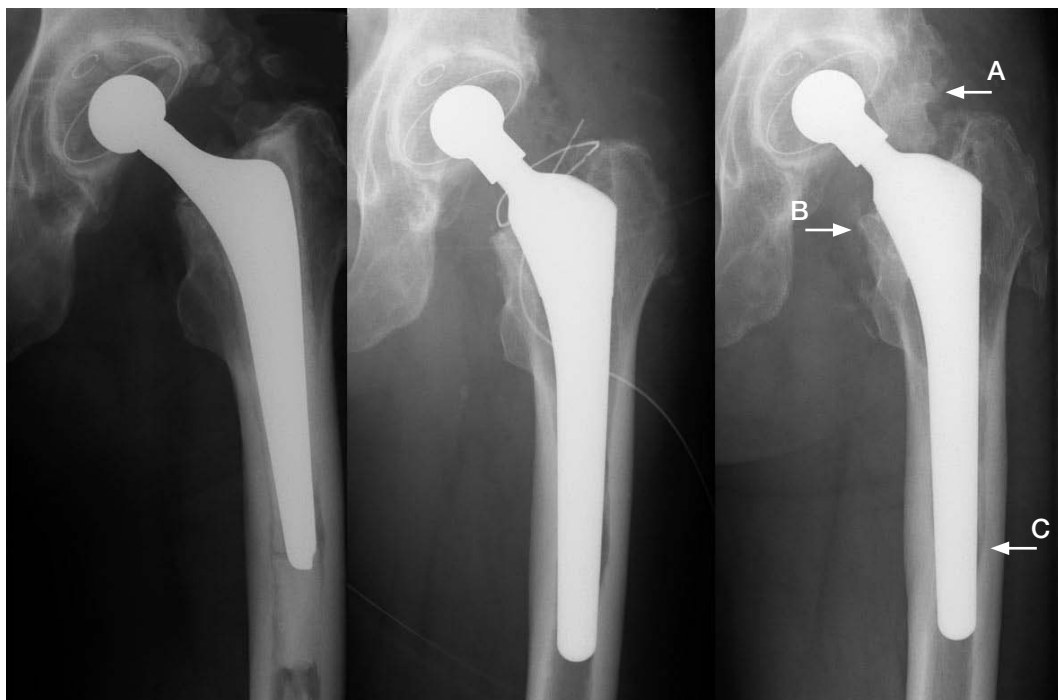


Figure 2. Remodeling changes around the stem. Arrows indicate heterotopic ossification (A), calcar round-off (B), and regression of osteolysis (C).

37 hips (Table 3). In 44 hips, initial lucencies had been obliterated—either partially or completely—with new bone formation at follow-up (Figure 2). 5 stems had subsided by more than 4 mm at follow-up; all showed other signs of stability. The maximum subsidence was 8 mm. None of the stems migrated into varus, valgus, or rotated. In 2 hips, new formation of focal osteolysis was detected in Gruen zone 1. Several additional signs of remodeling were observed; these are listed in Table 3.

Complications

9/62 hips had dislocations; 7 of these had only 1 dislocation and 2 had recurrent dislocations. Of the 2 latter patients, 1 was successfully treated with exchange of liner and a larger size of head. The other has cerebral palsy and has not been reoperated. We had 4 peroperative fissures during stem insertion. 3 were noted at operation and were treated with partial weight bearing, and 2 of them also with cerclage wires. The fourth patient, who got a fissure in the lesser trochanter peroperatively, suffered from pain and subluxations. The stem subsided and he was re-revised using impacted

morselized bone allograft and a cemented stem. 4 fractures were seen postoperatively. 2 of these were fissures without loosening of the stem. They were treated nonoperatively. 1 patient sustained a fracture, just after being operated, through a fenestration done at the revision operation. He was re-revised using a longer stem. The fourth patient fell on his hip 2 years after the revision and then complained of pain and subluxation phenomenon. During the revision that followed, we noted that the stem had subsided and rotated in retroversion—and had subsequently been osseointegrated again. In all, 4 hips have been re-revised on the femoral side. The 6-year prosthesis survival rate was 95% (95% CI: 0.83–0.98).

2 patients had a postoperative wound infection and 1 patient got a deep infection in the hip. 1 patient developed a clinically apparent deep vein thrombosis. 1 patient suffered from a sciatic nerve injury with partial loss of skin sensibility but no loss of motor function. No case of pulmonary embolus or vascular complication was seen.

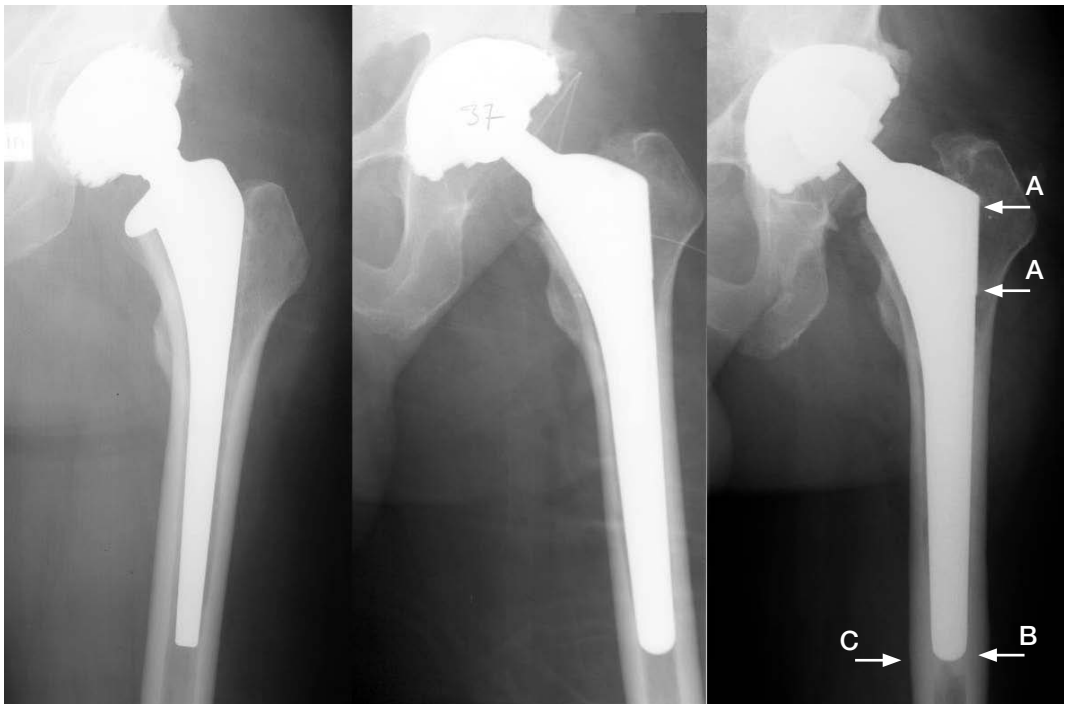


Figure 3. Remodeling changes around the stem. Arrows indicate spot welds (A), pedestal formation (B), and distal cortical hypertrophy (C).

Table 3. Bone remodeling at follow-up (53 hips)

	No.
<i>Stem stability parameters</i>	
Fixated stems	53
Subsidence (maximum 8 mm)	19
Change in varus-valgus alignment	0
Spot welds	30
<i>Stress-shielding parameters</i>	
Calcar resorption	16
Calcar "round-off"	7
Distal cortical hypertrophy (1–4 mm)	14
<i>Bone remodeling parameters</i>	
Osteolysis at revision	48
Regression of osteolysis	
total	7
partial	37
Newly formed osteolysis	2
<i>Unspecific parameters</i>	
Pedestal formation	36
Reactive lines	16
Heterotopic ossification	
grade 1	13
grade 2	6
grade 3	5
grade 4	0

Discussion

The frequency of loosening after revision with second-generation cementing technique is 15–20% at 10 years of follow-up, and third-generation cementing technique has not improved these results (Eisler et al. 2000). One cause of the high incidence of mechanical failure after cemented revision may be the lack of endosteal cancellous bone in the femur. This leads to a decrease in shear strength between the cement and the bone, due to inferior cement-bone micro-interlock (Dohmae et al. 1988, Berry 1998). If bone stock is poor, or if endosteal cancellous bone is lacking, other surgical methods are said to give better results. Impaction bone grafting with morselized allograft bone and cementation of the stem have been used in femoral revision arthroplasty. This technique has obvious advantages in bone stock restitution. Several authors have reported good or excellent results (Ullmark et al. 2002, Halliday et al. 2003, Mahoney et al. 2005). However, impaction bone grafting surgery is technically demanding and time consum-

ing. There are well-known complications associated with this technique, such as major subsidence and per- and postoperative fractures (Eldridge et al. 1997, Pekkarinen et al. 2000, van Biezen et al. 2000, Ornstein et al. 2002).

Another alternative in femoral revision is the use of uncemented implants. The aim of using these components is to achieve biological fixation, i.e. ingrowth of endosteal bone by new bone formation within the porous surface structure of the implant (Turner et al. 1986, Engh et al. 1987, Engh and Bobyn 1988, Rosenberg 1989). In a revision situation, proximal bone stock in the femur is often compromised. To achieve early postoperative stability, most uncemented stems are designed to bypass the proximally damaged zone and to achieve initial stability from press-fit distally. Distally anchored stems have shown good clinical results in the short- to medium-term (Wagner 1987, Kolstad et al. 1996, Isacson et al. 2000, Bohm and Bischel 2001). These long stems have the disadvantage of inducing severe stress-shielding, thus causing further bone loss proximally. Removal of such a stem would be more technically demanding and the outcome is likely to be worse thereafter. In an attempt to achieve sufficient initial stability with shorter stems, extensively porous-coated or HA-coated, canal-filling cobalt-chrome or titanium alloy stems have been used with good or excellent results (Lawrence et al. 1994, Paprosky et al. 1999, Moreland and Moreno 2001, Crawford et al. 2004, Raman et al. 2005, Trikha et al. 2005, Reikerås and Gunderson 2006). At least initially, the biological fixation is probably most pronounced in the distal part of the stem because the contact between the stem surface and the host bone is more intimate in this region, and the surrounding bone stock is of better quality distally than in the compromised proximal bone. Extensively coated stems get fixated both proximally and distally.

Stress-shielding is still of some concern to varying degrees. Reikerås and Gunderson (2006) concluded that they had no stress transfer in the distal direction because they had a low amount of proximal bone loss and a low incidence of distal cortical hypertrophy. In other studies with extensively coated stems, there were signs of stress-shielding (Paprosky et al. 1999, Moreland and Moreno 2001). These divergent results may have been caused by

different stem designs. The stem used in the study by Reikerås and Gunderson (2006) is of tapered titanium alloy with a narrow tip. Cylindrical stems probably cause more load transfer distally than tapered stems do, and titanium alloy stems are less stiff than cobalt-chrome stems—which might contribute to the degree of stress-shielding. Theoretically, stress-shielding could increase the risk of periprosthetic fractures, avulsions of muscle insertions in the trochanteric region, and even the risk of stem loosening. These theoretical problems have not been seen clinically yet, but the follow-up time may not be long enough.

In an attempt to reduce stress-shielding, stems with only proximal coating have been used. Depending on the length, shape, and surface of the stem, they are more or less likely to get fixated distally also. According to this, it would be difficult to strictly categorize these implants into a uniform group. The aim, though, of using any of these components is to enhance the proximal fixation in order to prevent further bone loss proximally and to minimize the load transfer distally. Earlier studies with stems aimed at proximal fixation have not shown entirely promising results (Table 4).

Our report deals with the results of using a proximally porous- and hydroxyapatite-coated uncemented tapered stem in femoral revisions because of aseptic loosening. We have used this stem in cases when it was judged that the bone stock at revision could give initial rigid stability to the implant. This seems to be a key factor in achieving good results in hip revisions using uncemented stems.

We chose to use 2 classification systems to determine bone defects prior to revision. The systems differ in their sensitivity in classification of bone defects. The classification from Endo-Klinik (Engelbrecht and Siegel 1989) is more sensitive to small bone defects. If the initial stem has subsided, it is referred to as a type II defect. That is not the case in the Gustilo and Pasternak (1988) classification, where there is also a large step between a type II and a type III defect. To be considered as a type II defect, there must be a large defect involving the lesser trochanter and the posterior-medial wall of the proximal femur. We had very few such extensive bone defects in our series which contributed to the excellent radiographic outcome. As a conse-

Table 4. Studies on uncemented femoral revisions with proximally coated stems

First author	Follow-up (years)	No. of hips	Type of stem	Survival rate	Comments
Berry (1995)	8	375	6 different types	58% aseptic survival rate	Insufficient fixation proximally due to inadequate bone stock
Peters et al. (1995)	5 (4–7)	49	Long, curved	Endpoints -revision 96%	Unacceptably high incidence of progressive subsidence
Malkani (1996)	3 (2–5)	69	Metaphyseal filling, long, curved	82% for entire group	Intraoperative fractures in 46%
Mulliken (1996)	5 (4–6)	52	Metaphyseal filling, long, curved	58% in fracture group 76% overall mechanical survival rate	Intraoperative fractures in 40% Insufficient fixation if moderate or severe bone defects
Suominen and Santavirta (1996)	5	39	Long, curved	Endpoints -revision 83% -rev. or stem loosening 72%	Unacceptably high incidence of revision or radiographical loosening
Emerson et al. (2003)	12 (9–15)	66	Metaphyseal filling, long, curved	94% overall and 97% aseptic survival rate	Used strut allografts if insufficient bone stock proximally
Kelly (2006)	5 (4–7)	33	Straight, tapered	100%	Good results if sufficient bone stock

quence of the small bone defects, we were able to achieve initial stability of almost all implants—and 100% well-fixated stems at follow-up. We could not see any difference in clinical result associated with the bone defects. This is probably due to the fact that there was rigid fixation of all stems in our study and—as compared to other materials—the great proportion of patients were in Charnley's functional class C, thus contributing to a lower HHS than would have been the case if it were only the operated hip that interfered with their functional capacity.

The clinical result, with a mean HHS of 75 points, is of the same order as in other studies of uncemented femoral revision using stems aimed at proximal fixation (Malkani et al. 1996, Mulliken et al. 1996). These studies concluded that the overall results, clinically and radiographically, were suboptimal. During the follow-up in our study, we found that the patients were satisfied with their reoperated hip but almost half of them had other disabilities impairing their functional capacity, for example inflammatory arthritis, knee osteoarthritis, or spinal stenosis (Figure 1). We believe that this is the reason for us not finding a higher HHS. 8 of 62 hips had mild-to-moderate thigh pain and

no patients suffered from severe thigh pain. This compares favorably with other studies (Moreland and Moreno 2001, Raman et al. 2005, Trikha et al. 2005). Radiographically, several patients showed signs of load transfer distally, which suggests a possible reason for their mid-thigh pain. The fact that few of the patients suffered from pain was probably due to the rigid fixation of the stem. Although the pain parameter is referred to in many studies concerning uncemented stems, we consider that this parameter is difficult to evaluate because of its low specificity.

Compared to other studies, we had a larger proportion of stem subsidence (19/53 hips). Although some of the stems had subsided when we compared the radiographs taken immediately after revision with the radiographs taken at follow-up, they all had several radiographic signs of stable fixation. It is possible that a proximally-coated, tapered stem is more likely to subside initially in the smooth femoral canal with lack of cancellous bone than a cylindrical, extensively coated implant. We saw no continuous subsidence or progressive radiolucent lines in the coated region of the stems. The radiolucent lines adjacent to the stems on the radiographs taken immediately after revision had been filled out

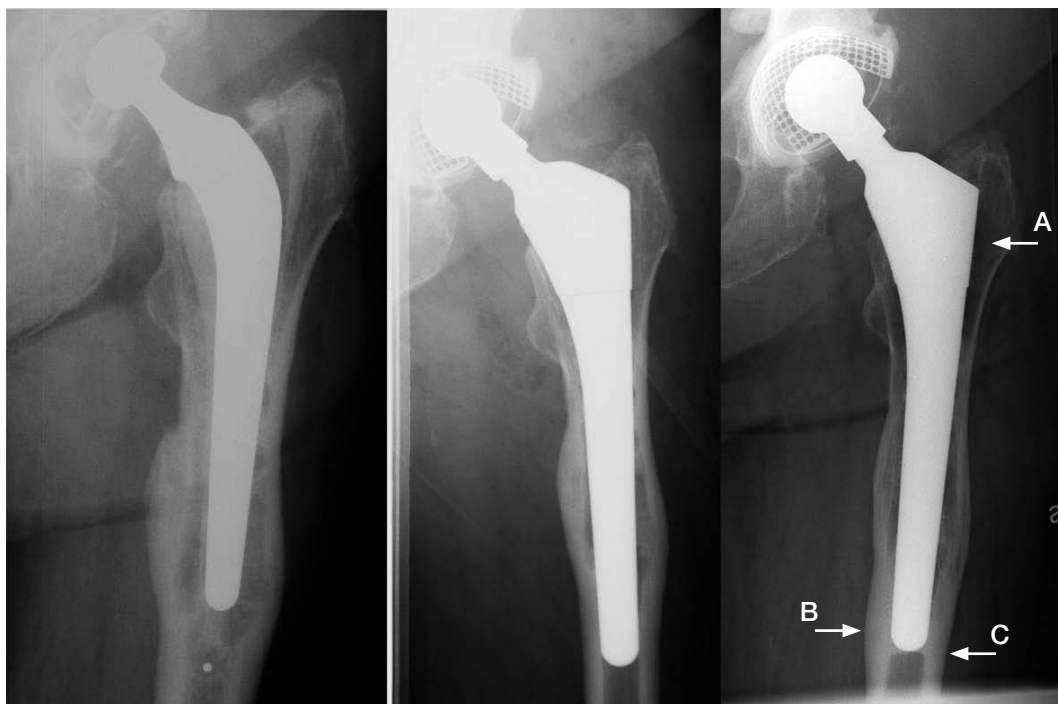

Figure 4. Remodeling changes around the stem. Arrows indicate proximal osteopenia (A), distal cortical hypertrophy (B), and pedestal formation (C).

with new bone in four-fifths of the hips at follow-up (Figure 2). Spot welds were seen in half of the hips, and they were usually distributed in Gruen's zones 1 and 7, i.e. in the coated region of the stem (Figure 3). In primary arthroplasty, using the same prosthesis, the incidence of spot welds is higher (Bodén et al. 2006). The reason for this may be that the endocortex in the proximal femur is smooth with less trabecular bone in a revision situation. In addition to this, as a result of earlier surgery, the femoral bone is altered—leading to unspecific skeletal findings on the radiographs. These signs, in combination with proximal osteopenia (Figure 4), sometimes made the evaluation regarding osteolysis and spot welds difficult.

This stem is designed to be osseointegrated in the proximal part of the femur, thus aiming at load transfer proximally and preventing from further bone loss in this region. However, our radiographic data revealed that this is not the case. The stem becomes osseointegrated both proximally and distally. We saw several signs of stress-shielding—such as calcar resorption, proximal cortical thinning, proximal osteopenia, and distal cortical

hypertrophy—of varying degrees (Figures 2–4). The larger stems used in femoral revision are stiffer than the stems used in primary arthroplasty, and patients in need of femoral revision have lower femoral bone density than patients in need of a primary hip arthroplasty. Both of these factors will contribute to a more pronounced stress-shielding after femoral revision than after a primary arthroplasty. It is important to mention that both the sensitivity and the specificity of evaluating bone loss radiographically are low. On plain radiographs, bone loss is not detected until about one-third of the bone is lost and the loss is not reproducibly recognized until two-thirds of the bone is resorbed (Engh et al. 2000); thus, it is sometimes difficult to differentiate whether bone remodeling seen in the femur is due to osteopenia or to osteolysis.

We had 2 cases with proximal focal osteolysis. Several hips showed signs of proximal osteopenia. Even though the stem is designed to prevent unloading of the proximal part of the femur, we found no other explanation for the proximal osteopenia than that the stems also get a distal fixation

in the diaphysis, contributing to partial unloading of the proximal part of the femur.

During the revision operation, after insertion of the uncemented stem, we often noted a non-circumferential space between the proximal body of the stem and the surrounding bone. We did not always fill this space with impacted bone chips. Despite the presence of this gap, we found no distal osteolysis at follow-up. A possible explanation for this is that the HA coating has sealed off the interface between the bone and the implant, thus preventing migration of debris into the peri-implant space (Rahbek et al. 2005). HA was introduced to enhance the osteoconductive properties of uncemented hip implants (Geesink et al. 1987). It has been found that supplementary HA also has osteogenetic capacity (Furlong and Osborn 1991). Within the gap between host bone and implant, bone formation is induced not only from the side of the host bone but also from the side of the HA-coated implant, enabling bone to bridge over wider gaps and to do so more rapidly than without the use of HA.

Dislocation was the most common complication in our series (9 of 62 hips). This is higher than in other studies. We believe that this was caused by our use of 22- to 29-mm head size (except in 3 cases in which the head diameter was 32 mm), and that we only had 1 offset option available at that time. We had 4 peroperative fractures during stem insertion and also noted 4 postoperative fractures. These figures are lower than what other groups have reported (Malkani et al. 1996, Mulliken et al. 1996).

One strength of our study is that we were able to re-examine all patients. The weaknesses are the retrospective design and the fact that we did not have recordings of HHS prior to revision.

Contributions of authors

MS examined all patients, collected the data, analyzed the radiographs, and prepared the manuscript. OS contributed with manuscript preparation, some statistical analyses, and examination of several patients. HB and TA scrutinized the radiographs and revised the manuscript. PA designed the study, supervised the statistical analyses, and proofread the manuscript.

No competing interests declared.

- Berry D J, Harmsen W S, Ilstrup D, Lewallen D G, Cabanela M E. Survivorship of uncemented proximally porous-coated femoral components. *Clin Orthop* 1995; (319): 168-77.
- Berry D J. Cemented femoral revision. In: *Hip surgery: materials and developments* (Eds. Sedel L, Cabanela M E). Martin Duniz, London 1998: 287.
- Bodén H, Salemyr M, Sköldenberg O, Ahl T, Adolphson P. Total hip arthroplasty with an uncemented hydroxyapatite-coated tapered titanium stem. Excellent results at a minimum of 10-years follow-up in 104 hips. *J Orthop Sci* 2006; 11 (2): 175-9.
- Bohm P, Bischel O. Femoral revision with the Wagner SL revision stem. Evaluation of one hundred and twenty-nine revisions followed for a mean of 4.8 years. *J Bone Joint Surg (Am)* 2001; 83 (7): 1023-31.
- Brooker A F, Bowerman J W, Robinson R A, Riley L H Jr. Ectopic ossification following total hip replacement. Incidence and a method of classification. *J Bone Joint Surg (Am)* 1973; 55 (8): 1629-32.
- Charnley J. The long-term results of low-friction arthroplasty of the hip performed as a primary intervention. *J Bone Joint Surg (Br)* 1972; 54 (1): 61-76.
- Crawford C H, Malkani A L, Incavo S I, Morris H B, Krupp R J, Baker D. Femoral component revision using an extensively hydroxyapatite-coated stem. *J Arthroplasty* 2004; 19 (1): 8-13.
- Dohmae Y D, Bechtold J E, Sherman R E, Puno R M, Gustilo R B. Reduction in cement-bone interface shear strength between primary and revision arthroplasty. *Clin Orthop* 1988; (236): 214-20.
- Eisler T, Svensson O, Iyer V, Wejkner B, Schmalholz A, Larsson H, Elmstedt E. Revision total hip arthroplasty using third-generation cementing technique. *J Arthroplasty* 2000; 15 (8): 974-81.
- Eldridge J D, Smith E J, Hubble M J, Whitehouse S L, Learmonth I D. Massive early subsidence following femoral impaction grafting. *J Arthroplasty* 1997; 12 (5): 535-40.
- Emerson R H Jr, Head W C, Higgins L L. Clinical and radiographic analysis of the Mallory-Head femoral component in revision total hip arthroplasty. A minimum 8.8-year and average eleven-year follow-up study. *J Bone Joint Surg (Am)* 2003; 85 (10): 1921-6.
- Engelbrecht E, Siegel A. Endo-Klinik klassifikation. *Radio-loge* 1989; 29 (10): 508-18.
- Engh C A, Bobyn J D. The influence of stem size and extent of porous coating on femoral bone resorption after primary cementless hip arthroplasty. *Clin Orthop* 1988; (231): 7-28.
- Engh C A, Bobyn J D, Glassman A H. Porous-coated hip replacement. The factors governing bone ingrowth, stress shielding, and clinical results. *J Bone Joint Surg (Br)* 1987; 69 (1): 45-55.
- Engh C A, Massin P, Suthers K E. Roentgenographic assessment of the biologic fixation of porous-surfaced femoral components. *Clin Orthop* 1990; (257): 107-28.
- Engh C A Jr, McAuley J P, Sychterz C J, Sacco M E, Engh C A Sr. The accuracy and reproducibility of radiographic assessment of stress-shielding. A post-mortem analysis. *J Bone Joint Surg (Am)* 2000; 82 (10): 1414-20.

- Furlong R J, Osborn J F. Fixation of hip prostheses by hydroxyapatite ceramic coatings. *J Bone Joint Surg (Br)* 1991; 73 (5): 741-5.
- Geesink R G, de Groot K, Klein C P. Chemical implant fixation using hydroxyl-apatite coatings. The development of a human total hip prosthesis for chemical fixation to bone using hydroxyl-apatite coatings on titanium substrates. *Clin Orthop* 1987; (225): 147-70.
- Gie G A, Linder L, Ling R S, Simon J P, Slooff T J, Timperley A J. Impacted cancellous allografts and cement for revision total hip arthroplasty. *J Bone Joint Surg (Br)* 1993; 75 (1): 14-21.
- Gustilo R B, Pasternak H S. Revision total hip arthroplasty with titanium ingrowth prosthesis and bone grafting for failed cemented femoral component loosening. *Clin Orthop* 1988; (235): 111-9.
- Halliday B R, English H W, Timperley A J, Gie G A, Ling R S. Femoral impaction grafting with cement in revision total hip replacement. Evolution of the technique and results. *J Bone Joint Surg (Br)* 2003; 85 (6): 809-17.
- Haydon C M, Mehin R, Burnett S, Rorabeck C H, Bourne R B, McCalden R W, MacDonald S J. Revision total hip arthroplasty with use of a cemented femoral component. Results at a mean of ten years. *J Bone Joint Surg (Am)* 2004; 86 (6): 1179-85.
- Huiskes R. The various stress patterns of press-fit, ingrown, and cemented femoral stems. *Clin Orthop* 1990; (261): 27-38.
- Isacson J, Stark A, Wallensten R. The Wagner revision prosthesis consistently restores femoral bone structure. *Int Orthop* 2000; 24 (3): 139-42.
- Kelly S J, Incavo S J, Beynon B. The use of a hydroxyapatite-coated primary stem in revision total hip arthroplasty. *J Arthroplasty* 2006; 21 (1): 64-71.
- Kolstad K, Adalberth G, Mallmin H, Milbrink J, Sahlstedt B. The Wagner revision stem for severe osteolysis. 31 hips followed for 1.5-5 years. *Acta Orthop Scand* 1996; 67 (6): 541-4.
- Lawrence J M, Engh C A, Macalino G E, Lauro G R. Outcome of revision hip arthroplasty done without cement. *J Bone Joint Surg (Am)* 1994; 76 (7): 965-73.
- Mahoney C R, Fehringer E V, Kopjar B, Garvin K L. Femoral revision with impaction grafting and a collarless, polished, tapered stem. *Clin Orthop* 2005; (432): 181-7.
- Malchau H, Kärrholm J, Wang Y X, Herberts P. Accuracy of migration analysis in hip arthroplasty. Digitized and conventional radiography, compared to radiostereometry in 51 patients. *Acta Orthop Scand* 1995; 66 (5): 418-24.
- Malkani A L, Lewallen D G, Cabanela M E, Wallrichs S L. Femoral component revision using an uncemented, proximally coated, long-stem prosthesis. *J Arthroplasty* 1996; 11 (4): 411-8.
- Moreland J R, Moreno M A. Cementless femoral revision arthroplasty of the hip: minimum 5 years followup. *Clin Orthop* 2001; (393): 194-201.
- Mulliken B D, Rorabeck C H, Bourne R B. Uncemented revision total hip arthroplasty: a 4-to-6-year review. *Clin Orthop* 1996; (325): 156-62.
- Ornstein E, Atroshi I, Franzén H, Johnsson R, Sandquist P, Sundberg M. Early complications after one hundred and forty-four consecutive hip revisions with impacted morselized allograft bone and cement. *J Bone Joint Surg (Am)* 2002; 84 (8): 1323-8.
- Paprosky W G, Greidanus N V, Antoniou J. Minimum 10-year-results of extensively porous-coated stems in revision hip arthroplasty. *Clin Orthop* 1999; (369): 230-42.
- Pekkarinen J, Alho A, Lepistö J, Ylikoski M, Ylinen P, Paavilainen T. Impaction bone grafting in revision hip surgery. A high incidence of complications. *J Bone Joint Surg (Br)* 2000; 82 (1): 103-7.
- Peters C L, Riviero D P, Kull L R, Jacobs J J, Rosenberg A G, Galante J O. Revision total hip arthroplasty without cement: subsidence of proximally porous-coated femoral components. *J Bone Joint Surg (Am)* 1995; 77 (8): 1217-26.
- Rahbek O, Kold S, Bendix K, Overgaard S, Søballe K. Superior sealing effect of hydroxyapatite in porous-coated implants: experimental studies on the migration of polyethylene particles around stable and unstable implants in dogs. *Acta Orthop* 2005; 76 (3): 375-85.
- Raman R, Kamath R P, Parikh A, Angus P D. Revision of cemented hip arthroplasty using a hydroxyapatite-ceramic-coated femoral component. *J Bone Joint Surg (Br)* 2005; 87 (8): 1061-7.
- Reikerås O, Gunderson R B. Excellent results with femoral revision surgery using an extensively hydroxyapatite-coated stem: 59 patients followed for 10-16 years. *Acta Orthop* 2006; 77 (1): 98-103.
- Rosenberg A. Cementless total hip arthroplasty: femoral remodeling and clinical experience. *Orthopaedics* 1989; 12 (9): 1223-33.
- Suominen S, Santavirta S. Revision total hip replacement using the bias proximal porous-coated femoral component. *Ann Chir Gynaecol* 1996; 85 (4): 347-51.
- Trikha S P, Singh S, Raynham O W, Lewis J C, Mitchell P A, Edge A J. Hydroxyapatite-ceramic-coated femoral stems in revision hip surgery. *J Bone Joint Surg (Br)* 2005; 87 (8): 1055-60.
- Turner T M, Sumner D R, Urban R M, Riviero D P, Galante J O. A comparative study of porous coatings in a weight-bearing total hip-arthroplasty model. *J Bone Joint Surg (Am)* 1986; 68 (9): 1396-409.
- Ullmark G, Hallin G, Nilsson O. Impacted corticocancellous allografts and cement for revision of the femur component in total hip arthroplasty. *J Arthroplasty* 2002; 17 (2): 140-9.
- van Biezen F C, ten Have B L, Verhaar J A. Impaction bone-grafting of severely defective femora in revision total hip surgery. 21 hips followed for 41-85 months. *Acta Orthop Scand* 2000; 71 (2): 135-42.
- Wagner H. Revision prosthesis for the hip joint in severe bone loss. *Orthopäde* 1987; 16 (4): 295-300.

III

Risedronate given once weekly prevents periprosthetic bone resorption after total hip arthroplasty

A randomized, double-blind, placebo-controlled trial

Olof G Sköldenberg, Mats O Salemyr, Henrik S Bodén, Torbjörn E Ahl, Per Y Adolphson

ABSTRACT

BACKGROUND

Bone resorption around uncemented femoral stems is a well-known phenomenon which could increase the risk of periprosthetic fractures or loosening of the implant. The aim of this trial was to investigate the effect of risedronate on femoral periprosthetic bone resorption after total hip arthroplasty in patients with osteoarthritis of the hip.


METHODS

We enrolled 73 patients between 40 and 70 years of age scheduled for total hip arthroplasty in a single-center, randomized, double-blind, placebo-controlled trial. Subjects were randomly assigned to receive either 35 mg of risedronate (n=36) or placebo (n=37) orally once weekly for 6 months. The primary end point was change in bone mineral density in femoral Gruen zones 1 and 7. Bone mineral density scans were taken pre- and postoperatively and at 3, 6, 12 and 24 months. Secondary end points included migration of the stem and clinical outcome.

RESULTS

Of the 73 patients included, 70 were analyzed for the primary end point. In the placebo group (n=37) we found a continuous bone loss in zones 1 and 7 which amounted to 18% at 24 months. Postoperative bone loss was less with risedronate (n=33) during the treatment period and this effect was still significant up to 12, but not 24 months. Patients with a low preoperative bone mineral density of the hip lost significantly more bone during the study. The migration of the stem, the clinical outcome and the frequency of adverse events did not differ between the groups but in the risedronate group 4 participants discontinued the study drug due to adverse events.

CONCLUSIONS

Risedronate given once weekly for 6 months after total hip arthroplasty is effective in preventing periprosthetic bone resorption around an uncemented femoral stem up to 12 months postoperatively but has no effect on implant migration. Future studies of bisphosphonate treatment after THA should focus on patients who have both osteoarthritis and a low BMD of the hip (ClinicalTrials.gov number, NCT00772395). 

ARTICLE INFORMATION

All authors at Karolinska Institutet, Department of Clinical Sciences, Division of Orthopaedics at Danderyd Hospital, Stockholm, Sweden.

Investigation performed between 2005 and 2010 at the Orthopaedic Department of Danderyd Hospital, Stockholm, Sweden.

CORRESPONDENCE

Dr. Olof Sköldenberg
olof.skoldenberg@ds.se

KEYWORDS

Bisphosphonates
Femoral stem
Bone resorption
Stress shielding
Total hip arthroplasty

ACKNOWLEDGMENTS

We would like to thank the research nurses Helene Sjöö and Paula Kelly-Pettersson for their invaluable help with inclusion of the patients and the clinical evaluations.

We would also like to extend our gratitude to Hans-Jerker Lundberg, Department of Nuclear Medicine, Danderyd Hospital for his technical assistance with the DEXA analyses.

INTRODUCTION

Adaptive bone resorption around a femoral stem after total hip arthroplasty (THA) is a well-known phenomenon.^{10,20} Since a well-fixated stem, which is stiffer than the surrounding femur, bears the majority of the load, the bone is stress-shielded and a disuse atrophy results.¹¹

This locally induced osteoporosis progress more rapidly than the natural ageing of the femur,¹³ thereby possibly explaining the increase in the annual incidence of late presenting periprosthetic fractures.³³

There is also a concern that this bone resorption, in the long-time perspective, can lead to aseptic loosening of the stem, as well as increasing the difficulty involved in revision surgery.

Several clinical trials have been performed involving bisphosphonates and THA.^{7,48-50,52-53} The clinical insight gained from these trials have been hampered by the small study sizes, often with a short follow-up period and varying methods of analyzing the effect. Nevertheless, earlier studies have indicated that bisphosphonates can significantly influence periprosthetic bone resorption after THA. Bisphosphonates have also been shown to reduce the migration of

uncemented acetabular components in THA and cemented tibial components in total knee arthroplasty (TKA).^{22,28} These are important findings since the continuous migration of implants is associated with an increased risk for future revision.^{30,32}

Risedronate is a bisphosphonate with potent antiresorptive activity that is used in the treatment of Paget's disease of bone and multiple myeloma. It can reduce the risk of vertebral fractures and hip fractures in osteoporotic patients.²⁵

In the current study, we tested the hypothesis that 35 mg of risedronate, given postoperatively once weekly for 6 months, would reduce the periprosthetic bone resorption around the stem for up to 2 years. We also studied if risedronate had an impact on the migration of the stem and the general bone mineral density (BMD) of the patients or if it affected the clinical outcome. ○

PATIENTS AND METHODS

This randomized, double-blind, placebo-controlled study followed the guidelines of the CONSORT statement.³ The study was carried out between August 2006 and May 2010 at the Orthopaedic Department of Danderyd Hospital, Stockholm, Sweden and was performed in accordance with Good Clinical Practice (GCP) and the ethical principles of the Helsinki declaration.

The Ethics Committee of the Karolinska Institutet (Dnr 04-745/4), the Committee for protection against radiation at Danderyd Hospital (Dnr 005-4) and the Swedish Medical Products agency (Dnr 151:2005/8091) approved the study.

The trial was initiated, designed and performed as an academic investigation. The pharmaceutical company Sanofi-Aventis/Warner Chilcott Pharmaceuticals Inc. funded in part the risedronate and placebo used. Beyond this, the company had no further input or participation in the trial.

STUDY SUBJECTS

All patients planned for primary THA were screened for participation in the study. Patients who met the inclusion criteria were given written information about the trial and were contacted by a research nurse. Those who agreed to participate gave their written informed consent at a screening visit 2 weeks preoperatively. Patients aged 40-70 years, with primary osteoarthritis of the hip, and a type A or B femur according to Dorr et al.¹⁸ were eligible for inclusion in the study.

Patients were excluded if they had a condition that could affect bone mineral density (BMD) or its measurement, for example, an abnormal anatomy of the proximal femur. Patients were also excluded if they had had previous surgery of the hip or received drugs known to affect bone metabolism, for example, ongoing oestrogen or oestrogen related drugs within 1 month prior to

the screening visit; bisphosphonates, cortisol or chemotherapy drugs within 6 months of screening. Patients with a hypersensitivity to risedronate, who had hypocalcaemia, or who, for any reason, were unsuitable to take part of a randomized controlled trial were also excluded.

Since fracture healing is impossible to differentiate from adaptive bone remodeling with measurements of bone mineral density (BMD), we also excluded patients who sustained a periprosthetic fracture during stem insertion.

SURGERY

THA was performed with an uncemented, tapered, proximally porous- and hydroxyapatite (HA)-coated femoral stem manufactured of a titanium alloy (Ti-6Al-4V), (Bi-Metric HA™, Biomet, Warsaw, Indiana, U.S.A.) and a 28 mm chrome-cobalt head.

The acetabular component was a cemented (ZCA™, Zimmer, Warsaw, Indiana, U.S.A) or an uncemented titanium-backed and HA-coated press-fit cup (Trilogy™, Zimmer, Warsaw, Indiana, U.S.A). Regardless of the type of fixation, a highly cross-linked polyethylene liner (Longevity™, Zimmer, Warsaw, Indiana, U.S.A.) was used.

The procedures were performed by 9 experienced surgeons using a standard posterior approach with repair of the posterior capsule and external rotator muscles. Intravenous tranexamic acid (Cyclokapron®, Pfizer, Sweden) was administered before the start of surgery to reduce bleeding. Prophylactic antibiotics (Cloxacillin®, Meda, Sweden) were given in the first 24 hours postoperatively and dalteparin (Fragmin®, Astra-Zeneca, Sweden) was given 10 days postoperatively to prevent thromboses.

The patients were mobilized using a standard physiotherapy program. They were encouraged to weight bear fully using crutches for support.

RANDOMIZATION, INTERVENTION AND BLINDING

The patients were randomized on the second postoperative day to take either a tablet of 35 mg risedronate or the placebo once weekly for 6 months. Patients were instructed to take the tablet on an empty stomach 30 minutes before breakfast and to remain in an upright position for 1 hour after

TABLE 1. Baseline characteristics of the patients

	risedronate (n=36)	placebo (n=37)
Age, yrs ^a	61±7	60±7
Sex ^b		
Female	22 (61)	21 (57)
Male	14 (39)	16 (43)
Weight, kg ^a	79±14	86±17
Height, cm ^a	171±8	174±9
BMI ^a	27±4	28±6
ASA classification ^b		
1-2	35 (97)	34 (92)
3-4	1 (3)	3 (8)
Charnley class ^b		
A	20 (56)	16 (43)
B	13 (36)	16 (43)
C	3 (8)	5 (14)
Total hip (WHO) ^b		
Normal bone density	27 (75)	32 (87)
Osteopenia	9 (25)	3 (8)
Osteoporosis	0 (0)	2 (5)
BMD (g/cm ³) ^a	1.02±0.16	1.05±0.19
Vertebrae L1-L4 (WHO) ^b		
Normal bone density	27 (75)	29 (78)
Osteopenia	8 (22)	6 (16)
Osteoporosis	1 (3)	2 (6)
BMD (g/cm ³) ^a	1.24±0.20	1.29±0.27
Surgery		
Cup cemented/uncemented (n)	27/9	26/11
Stem size 8-10/11-13/14-15 mm (n)	15/16/5	7/24/6
Surgery time (min) ^a	88±21	92±19

^a = mean ±SD, ^b = n (%)

ingestion of the tablet. All patients received oral supplements of calcium carbonate (1000 mg) and vitamin-D (400 IU) daily for 6 months.

The computerized randomization and blinding procedure was carried out by the central pharmacy (Apoteket AB, Stockholm, Sweden), which produced the study drug and the placebo tablets in physically indistinguishable and coded containers. Patients were block-randomized in groups of 10 using sealed envelopes and randomization was stratified to ensure that the gender distribution would be the same in both groups.

All patients, staff and investigators were blinded as to the treatment assignment during the study. Two patients in the risedronate group were unblinded due to adverse events. Compliance (≥80% of study drug taken) was controlled at the 6 week, 3 and 6 monthly follow-up visit.

/ Study III

END POINTS

The primary end point was a change in the BMD in the Gruen²³ zones 1 and 7 around the femoral stem in subjects receiving risedronate compared to those receiving placebo during a 2 year period with measurement points 2 days postoperatively and at 3, 6, 12 and 24 months.

Secondary end points included change in BMD in the entire periprosthetic region (zones 1-7) and in the individual zones 2, 3, 4, 5 and 6. Vertical migration of the stem, radiological results, clinical outcome and the occurrence of adverse events were also examined. The study protocol is shown in Figure 1.

BONE MINERAL DENSITY MEASUREMENTS

BMD was measured using dual-energy x-ray

absorptiometry (DXA), (DPX-L™, Lunar Co., Madison, Wisconsin, U.S.A.). During scanning, the patients were placed in a supine position with a foot support to ensure that the femur was positioned in a neutral rotation. Two days postoperatively and at each follow-up visit, the BMD was measured around the femoral stem in the 7 Gruen²³ zones in the frontal plane. Using double scans, we had previously established the precision error of the method.¹²

The longitudinal change in periprosthetic BMD in individual zones, as well as the entire periprosthetic region (zone 1-7), was calculated by dividing the BMD value at each follow-up visit with the first postoperative BMD value and calculating a percentage value. Preoperatively, we measured BMD of the proximal femur of the diseased hip (WHO total hip) and vertebrae L₁-L₄ (WHO lumbar spine) to assess the patient's general bone mass. The BMD of the L₁-L₄ vertebrae were also measured at 24 months postoperatively (Figure 1).

RADIOLOGICAL ANALYSIS

Digital anteroposterior and lateral radiographs (Bucky Diagnostics™, Philips, Eindhoven, Netherlands) were taken and uploaded to a workstation. Migration of the femoral stem was measured with Einzel-Bild-Roentgen-Analyse Femoral Component Analysis (EBRA-FCA), (University of Innsbruck, Austria). This is an accurate method used to analyze clinically relevant migration of a femoral stem after THA.^{9,30} The method has an accuracy of 1.5 mm and it can detect a migration larger than 1.0 mm with a specificity of 100% and a sensitivity of 78%.⁹

Stem fixation and stability were assessed according to the criteria of Engh et al.²¹ Radiolucent lines between bone and cement (for cemented cups) or bone and porous coating (for uncemented cups) in DeLee and Charnley¹⁷ zones around the cup were recorded. Heterotopic ossification was evaluated according to Brooker et al.¹⁴

CLINICAL OUTCOME

Hip function was evaluated with Harris hip score (HHS).²⁶ Health-related Quality of Life was assessed using EQ-5D.^{15-16,38} EQ-5D describes health status in 5 dimensions: mobility, self-care,

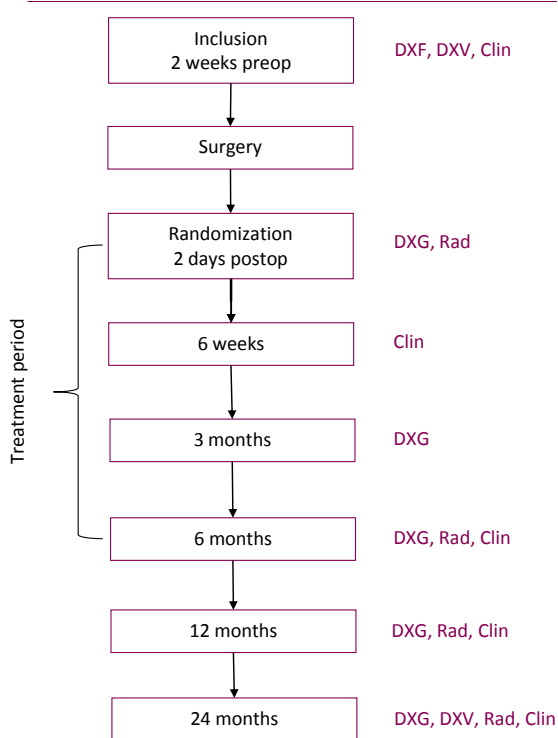


FIGURE 1. Study protocol

DXF=DXA scan of proximal femur (WHO total hip), DXV=DXA scan of vertebrae L₁-L₄ (WHO lumbar spine), DXG=DXA scan of Gruen zones, Rad=Anteroposterior and lateral radiographs, Clin=Clinical outcome including Harris hip score, EQ-5D and Pain Numeric Rating Scale

usual activity, pain/discomfort and anxiety/depression. Each dimension is divided into 3 levels: 1 – no problem, 2 – some problems and 3 – extreme problems. This generates 243 different “health states” and the EQ-5D index score assigns each “health state” to a value, ranging from -0.59, indicating the worst possible health state, to a value of 1, indicating full health.

Pain in the operated hip was recorded using Pain Numeric Rating Scale (PNRS).¹⁹ PNRS is an 11-point (0-10) numerical rating scale, were patients were asked to evaluate the level of pain they experienced in the operated hip during the previous week. A score of 0 denotes no pain and 10 indicates the most pain imaginable.

SAMPLE SIZE AND STATISTICAL ANALYSIS

A power analysis (two-sided, $p=0.05$) based upon one of our studies with the Bi-Metric stem⁴⁴ was performed in advance on the primary end point. A total of 30 patients in each group indicated a power of 90% to detect a clinically relevant difference of 10% (SD 11%) in BMD in the periprosthetic zones 1 and 7 between the 2 treatment arms. We estimated that we could have a loss of data of up to 20% and therefore planned to recruit 37 patients in each group.

Analyses of efficacy were based on the intention-to-treat principle and all patients, who received at least 1 dose of either risedronate or placebo, were included in the final analysis. Subjects with missing BMD data at any of the follow-ups (5 individual follow-up visits in the risedronate group and 4 in the placebo group) were analyzed with the last observation carried forward. The analyses were repeated with the use of only the available data, and the same results were produced (data not shown).

We used a one-way repeated measures analysis of variance (ANOVA) to detect an overall effect of treatment throughout the study period. Factors known to influence periprosthetic bone loss (sex,² age, BMI, stem size⁴⁴ and preoperative BMD of the hip³⁹) were included as covariates in the analyses. Stem size was categorized into sizes 8-10/11-13/14-15 (size 8-10 as reference). Median preoperative hip BMD (1.014 g/cm²) was used to dichotomize the subjects into 2 groups; pa-

tients with high or low BMD (mean 1.173 ± 0.130 g/cm² and 0.896 ± 0.096 g/cm², respectively). Our reference category was made up of patients with a high BMD. The effect of general bone mass (WHO total hip and WHO lumbar spine) on periprosthetic bone loss was also analyzed using the Pearson's correlation coefficient at 24 months.

For BMD and migration data, we used the Kolmogorov-Smirnov and Levene's tests to test for normality and homogeneity of variance of data. Thereafter the unpaired Student's t-test was used for between-group comparisons at follow-ups and the paired Student's t-test for longitudinal changes. Between-group comparisons of not normally distributed clinical outcome scores at follow-up visits were analyzed with the Mann-Whitney U-test and within-group comparisons between baseline and follow-up values were analyzed with the Wilcoxon signed-rank test. P-values ≤ 0.05 were considered significant. ◉

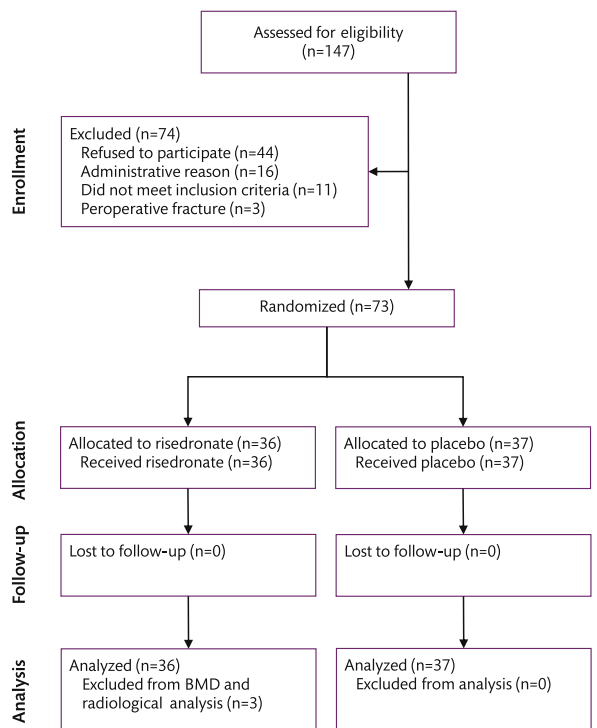


FIGURE 2. CONSORT diagram. Flow of patients in accordance with CONSORT (Consolidated Standards of Reporting Trials).

RESULTS

CHARACTERISTICS OF SUBJECTS

We enrolled 73 patients, 36 in the risedronate group and 37 in the placebo group (Figure 2). All patients received at least 1 dose of study medication and completed 24 months of follow-up. The compliance was 93% in the risedronate and 97% in the placebo group. Baseline characteristics were similar between the groups (Table 1).

EFFICACY FOR PRIMARY END POINT

In the placebo group, a continuous bone loss was seen with a BMD decrease of 18% in zone 1 and 7 after 24 months.

In the risedronate group, bone resorption was effectively reduced during the first 6 months with an efficacy (difference between the 2 groups) of 9.2% and 8.0% at 6 months in zone 1 and 7 respectively ($p < 0.001$ and $p = 0.003$). In zone 1, the difference between the groups was still statistically significant at 12 months (risedronate vs. placebo; -7.4% versus -14.5%, $p = 0.006$) with a trend towards a difference at 24 months (risedronate vs. placebo; -13.6% versus -17.7%, $p = 0.066$). In zone 7, there was no statistically significant difference between the risedronate and placebo groups at 12 and 24 months (Table 2).

The protective effect of risedronate on bone resorption during the entire study period was statistically significant when controlling for sex, age, BMI, stem size and preoperative BMD of the operated hip (zone 1, $p = 0.005$ and zone 7, $p = 0.006$, ANOVA), (Figure 3). In addition, the larger stem sizes (size 11-13 and 14-15) were associated with increased bone loss in zone 1 ($p = 0.045$).

Low preoperative BMD of the hip correlated with an increased bone resorption post surgery in zone 1 and 7 ($p = 0.05$ and $p < 0.001$, respectively), (Figure 4 and 5). Sex, age or BMI did not affect the primary end point at any time (data not shown).

EFFICACY FOR SECONDARY END POINTS

In the combined periprosthetic regions (zones 1-7), the patients in the risedronate group had a significantly lower bone resorption at all follow-

ups compared to patients in the placebo group (Table 2). Bone resorption was also reduced in the risedronate group in zones 2, 3 and 6 with the same tendency as for zone 1 and 7; reduced resorption during the first 6 and 12 months and then increased resorption up till 24 months (Figure 3). In zone 3, the difference between the risedronate and placebo group was still statistically significant at 24 months.

The vertical migration of the stem did not differ between the groups and was mean -1.7 mm in both groups at 24 months (Table 2). The patients' Harris hip score, EQ-5D and PNRs all improved compared to the preoperative value and did not differ between the groups at any time (Table 2, Figure 6). At 24 months, we found no difference between the groups in vertebral BMD or the rate of heterotopic ossification.

All stems were stable according to the fixation/stability score,²¹ but the score was higher in the placebo group (risedronate vs. placebo; 15.5 versus 18.0, $p = 0.004$, Mann-Whitney U-test). This was due to a higher number of spot welds in the placebo group (risedronate vs. placebo; 9 of 33 versus 21 of 37, $p = 0.013$). There was no difference between the groups with regards to other fixation/stability parameters (data not shown).

On the acetabular side, we found radiolucent lines between bone and cement in DeLee and Charnley¹⁷ zone 1 in 2 hips in the risedronate group and 1 in the placebo group. There was no radiolucent line around the uncemented cups.

ADVERSE EVENTS

The frequency of adverse events was similar in both groups (risedronate vs. placebo; 20 versus 24, $p = 0.416$, Table 3).

In the risedronate group, compared to the placebo group, a significantly larger number of patients discontinued the study drug because of adverse events [2 due to urticaria and 2 due to nausea ($p = 0.037$ versus placebo)].

Two patients in the placebo group suffered from a non-traumatic dislocation of the hip; 1 patient had to undergo a stem revision 6 days postoperatively and 1 patient was treated with

TABLE 2. The effect of risedronate on primary and secondary end points

Outcome	risedronate	placebo	difference (95% CI)	p value
PRIMARY END POINT				
Change in BMD zone 1 (%) ^a				
3 months	1.2±7.6	-5.9±9.0	7.2 (3.2 - 11.1)	<0.001
6 months	-0.5±10.8	-9.7±9.9	9.2 (4.2 - 14.1)	<0.001
12 months	-7.4±14.7	-14.5±11.2	7.2 (1.0 - 13.3)	0.006
24 months	-13.6±12.3	-17.7±13.1	4.1 (-2.0 - 10.2)	0.066
Change in BMD zone 7 (%) ^a				
3 months	-3.6±10.2	-10.3±10.9	6.7 (1.6 - 11.7)	0.007
6 months	-5.1±10.6	-13.1±11.7	8.0 (2.7 - 13.4)	0.003
12 months	-11.9±12.3	-16.1±12.0	4.3 (-1.5 - 10.1)	0.318
24 months	-17.2±13.2	-18.1±14.9	0.9 (-5.9 - 7.7)	0.699
SECONDARY END POINTS				
Change in BMD zone 1-7 (%) ^a				
3 months	-0.9±3.6	-3.4±4.1	2.5 (0.7 - 4.4)	0.005
6 months	-0.3±3.7	-4.0±5.0	3.8 (1.6 - 5.9)	<0.001
12 months	-0.9±4.8	-4.5±4.9	3.6 (1.3 - 5.9)	0.001
24 months	-2.9±4.9	-5.1±4.9	2.2 (0.2 - 4.6)	0.032
Vertical migration of the stem (mm) ^a				
6 months	-1.2±1.2	-1.0±0.8	-0.2 (-0.7 - 0.3)	0.520
12 months	-1.5±1.5	-1.4±1.0	-0.1 (-0.7 - 0.5)	0.809
24 months	-1.7±1.5	-1.7±1.2	0.1 (-0.6 - 0.8)	0.807
Harris hip score ^b				
Preoperatively	45 (13-69)	48 (13-69)		0.688
24 months	100 (81-100)	98 (46-100)		0.084
EuroQoL ^b				
Preoperatively	0.42 (-0.14-0.85)	0.30 (-0.18-0.73)		0.081
24 months	1.0 (0.52-1.0)	0.80 (-0.07-1.0)		0.134
PNRS ^b				
Preoperatively	7 (4-10)	7 (3-10)		0.761
24 months	0 (0-3)	0 (0-8)		0.183
OTHER END POINTS				
BMD L1-L4 24 months (g/cm ²) ^a				
	1.27±0.24	1.30±0.27	-0.03 (-0.16 - 0.10)	0.631
Fixation/Stability score ^b				
	15.5 (7.5 - 23.5)	18.0 (9.5 - 23.5)		0.004
Heterotopic ossification ^c				
None	25 (69)	28 (76)		
Class I-II	11 (31)	8 (22)		0.551
Class III-IV	0 (0)	1 (2)		

^a mean ±SD, p-value Student's t-test, ^b median (range), p-value Mann-Whitney U test, ^c n (%), p-value chi-square test

closed reduction 8 weeks postoperatively. Both hips have been stable thereafter.

One patient suffered a pulmonary embolism and another a deep vein thrombosis, both in the placebo group.

PATIENTS WHO DECLINED PARTICIPATION

The 44 patients who declined to participate in the study did not differ from the study subjects with regards to sex (participants vs. non-participants;

male/female: 30/43 versus 14/30, p=0.316) or age (participants vs. non-participants; mean ±SD 61±7 versus 62±6 years, p=0.361) but there was a tendency for higher ASA class in those patients who declined to participate (participants vs. non-participants; ASA 1-2/3-4: 69/4 versus 37/7, p=0.061). The clinical outcome for non-participants, as registered in the hospital records, did not differ from the patients included in the study (data not shown). ○

/ Study III

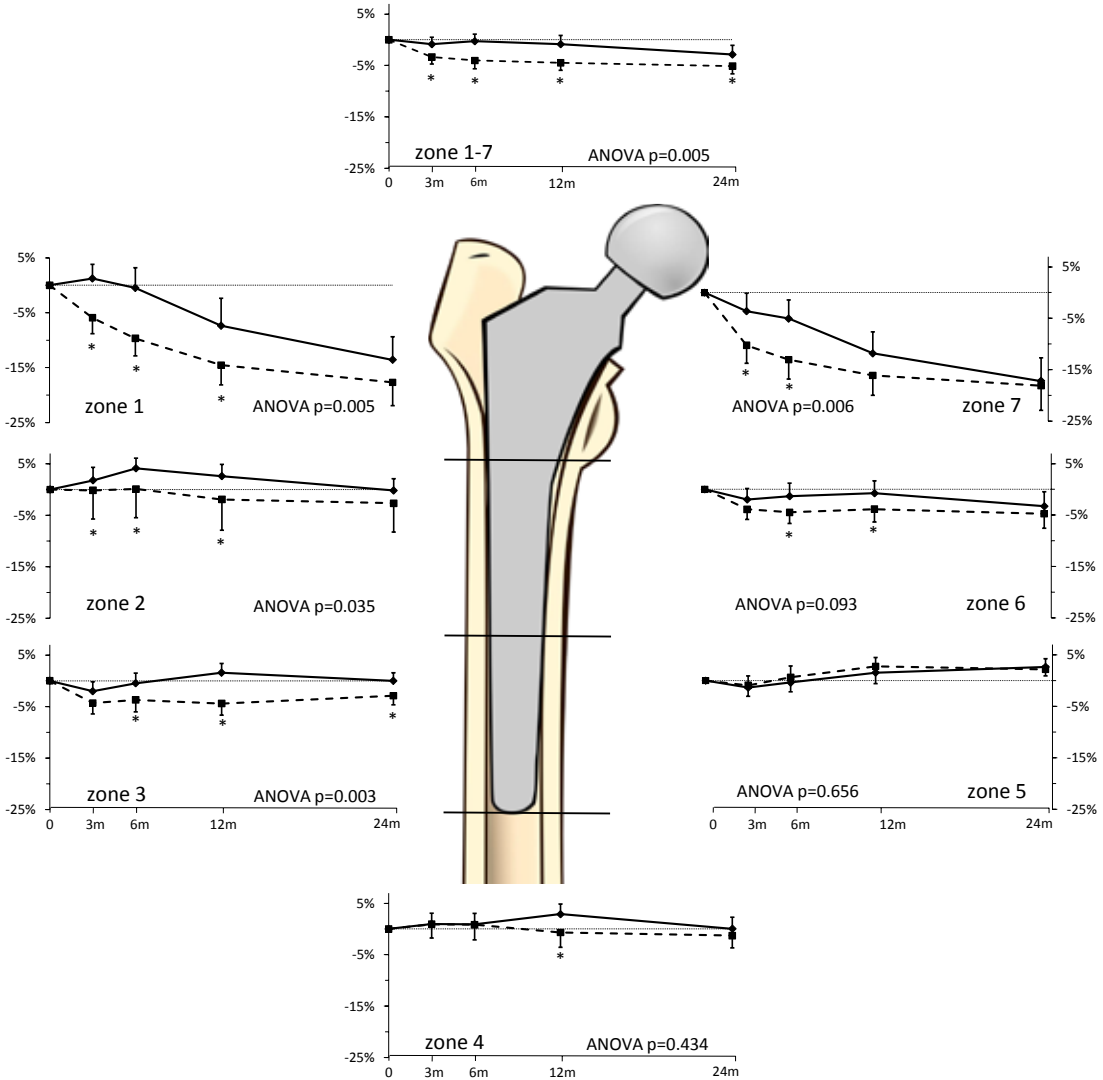


FIGURE 3. Periprosthetic bone remodelling

The mean (95% CI) percentage change in BMD around the stem in patients receiving risedronate (solid line) or placebo (dashed line).

*p<0.05

DISCUSSION

In patients with osteoarthritis, 6 months of oral risedronate treatment taken weekly is effective in reducing proximal femoral periprosthetic bone resorption up to 12 months after THA with a trend towards an effect up to 24 months.

The potentially adverse effect of bone resorption around hip implants has been widely discussed.^{4,13,20,29}

Besides an increased risk for periprosthetic fractures,³³ a long-term negative effect on implant stability and loosening has also been feared. The length of time that prosthesis has to serve in a younger patient, puts focus on the continuous accommodation and ageing of the host bone in the proximal femur.

There is no study with a long enough follow-up period to rule out the potential danger of this effect on stem stability after several decades. Also, if, for any reason, a reoperation is required, the prerequisite of an acceptable bone quality is crucial for a satisfactory surgical result.

The most pronounced stress-shielding effect is known to occur within 6 months postoperatively.^{7,41} Several attempts to reduce this influence on BMD have been made. Design variations such as ultra-short stems,¹ only proximally porous coated stems,¹³ custom made stems,³⁴ iso-elastic stems³¹ etc. have all shown a moderate effect on bone resorption. A more aggressive postoperative weight bearing regime also seems to be of limited importance.^{12,46}

The possibility to reduce bone resorption with bisphosphonates has also been addressed by several researchers and positive effects have been noted in the short and mid-term perspective (Table 4).^{6-7,27,35,48-50,52-54}

In animal models, bisphosphonates can cause augmentation of bony ingrowth around and onto orthopaedic implants,^{37,45} increase pull-out strength of screws⁴³ and reduce wear-induced osteolysis.⁴² Indirect evidence for positive effects also in humans includes decreased migration of prosthetic implants.²⁸

This is important since early migration of implants is a risk factor for later revision.^{32,40} Hilding et al. used radiostereometry (RSA) to show

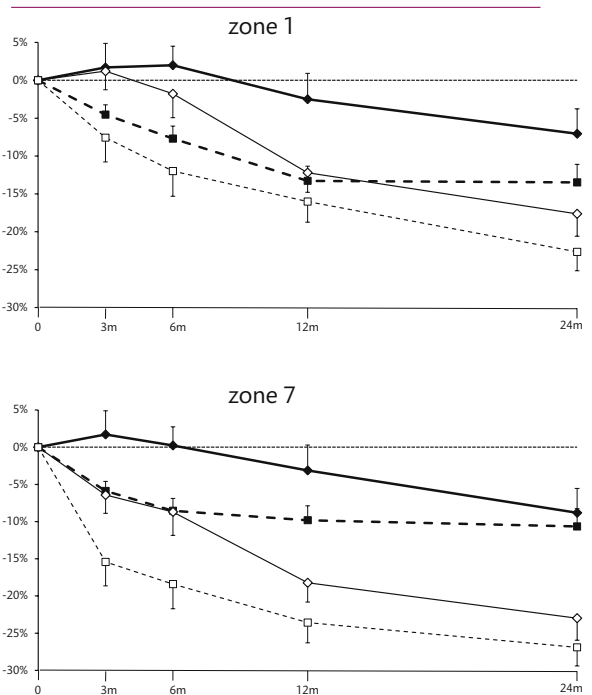


FIGURE 4. Bone loss in relation to preoperative BMD

The mean (95% CI) percentage change in BMD in patients with high (bold lines) or low (thin lines) preoperative BMD of the hip in the risedronate (solid lines) and placebo (dashed lines) groups.

that intravenous administration of clodronate in humans reduced the migration of the cemented tibial component in TKA.²⁸ The same research group later demonstrated a similar effect of a local elution of ibandronate applied to the freshly cut bone surfaces, but failed to show any effect on migration in uncemented components with the use of oral alendronate.²⁴

The method used to assess the migration of our implants, EBRA, has a lower resolution than RSA, and, even though 1 study, using EBRA, has shown less migration of uncemented acetabular

/ Study III

components after bisphosphonate treatment,²² another study, has failed to do so.⁴⁹ For TKA, the mean effect of bisphosphonate treatment is in the magnitude of 0.1 mm^{24,28} which is far too small to be detected by EBRA. To date, there is no published study showing effect of bisphosphonates on femoral or acetabular implant migration after THA using RSA.

Our primary outcome variable, prevention of

bone resorption, is, like migration of implants, a proxy variable for clinical success. When the trial was designed, our hypothesis was an efficacy up to 2 years with 6 months of treatment, a result we almost managed to show.

Trying to decrease the effect of stress-shielding using bisphosphonates, 6 months of treatment has been advocated since the bone loss is largest during the first postoperative period.^{7,51} Arabmotlagh et al.⁷ studied the duration of anti-resorptive treatment and suggested that the minimum time needed for treatment is 6 months, at least when using alendronate. They compared 4 and 6 months of treatment with alendronate and found that the protective effect of alendronate on bone resorption in the 4-month group decreased so that the 4-month group did not differ after 1 year compared to placebo. They concluded that 6 months of treatment should protect against bone loss up to 1 year. On the other hand, the same research team recently published a 6-year follow-up of a smaller material where they have shown and effect after only 5 weeks and 10 weeks treatment with alendronate.⁶ Though this study had the drawback of too few subjects being included and 2 different implants being used.

In a recently published study by Yamasaki et al.⁵⁴ on patients with osteoarthritis secondary to dysplasia of the hip, they found a marked reduction of bone resorption in zones 1, 2, 3, 6 and 7 after 6 months with risedronate given once daily. This is well in accordance with our results even if their dosage was lower (2.5 mg orally once daily whereas we gave 35 mg each week). The same researchers also found a positive effect in zone 7 after 30 months if early treatment with cyclic therapy with etidronate for 12 months was applied.⁵³ However, as in our study, a significant decrease in BMD was noticed in the proximal zones after withdrawal of therapy.

Thus, the proxy variables periprosthetic bone atrophy and migration of implants after bisphosphonate treatment have been extensively studied, as opposed to the outcome variables that truly are of interest; clinical outcome and risk for revision.

In a recent nationwide population-based study, results concerning postoperative use of

TABLE 3. Adverse events

	risedronate (n=36)	placebo (n=37)	p-value
Any adverse event	20	24	0.416
Drug-related adverse event^a	5	3	0.429
Urticaria	3	1	
Nausea	2	0	
Dyspepsia	0	2	
Surgery-related adverse event^a	8	10	0.634
Leg swelling or leg pain operated side	3	5	
Postoperative anaemia requiring transfusion	2	1	
Superficial wound infection	2	1	
Deep venous thrombosis	0	1	
Pulmonary embolism	0	1	
Dislocation	1	1	
Other adverse event^b	7	11	0.308
Contusion lower extremity	4	0	
Upper respiratory tract infection	0	4	
Other minor infections	0	2	
Hypothyroidism	0	1	
Fracture upper extremity	1	0	
Vertigo	0	3	
Conjunctivitis	1	0	
Hypoglycemia	1	0	
Urinary tract infection	0	1	
Serious adverse event^c	1	2	
Discontinuation of study drug due to adverse event	4	0	0.037

Number of events are given.

^a Adverse events classified as having a certain or probable relationship to study drug or surgery.

^b Adverse events classified as having no relationship to study drug or surgery.

^c 3 subjects were hospitalized during the study period, 2 due to dislocation and 1 due to pulmonary embolism.

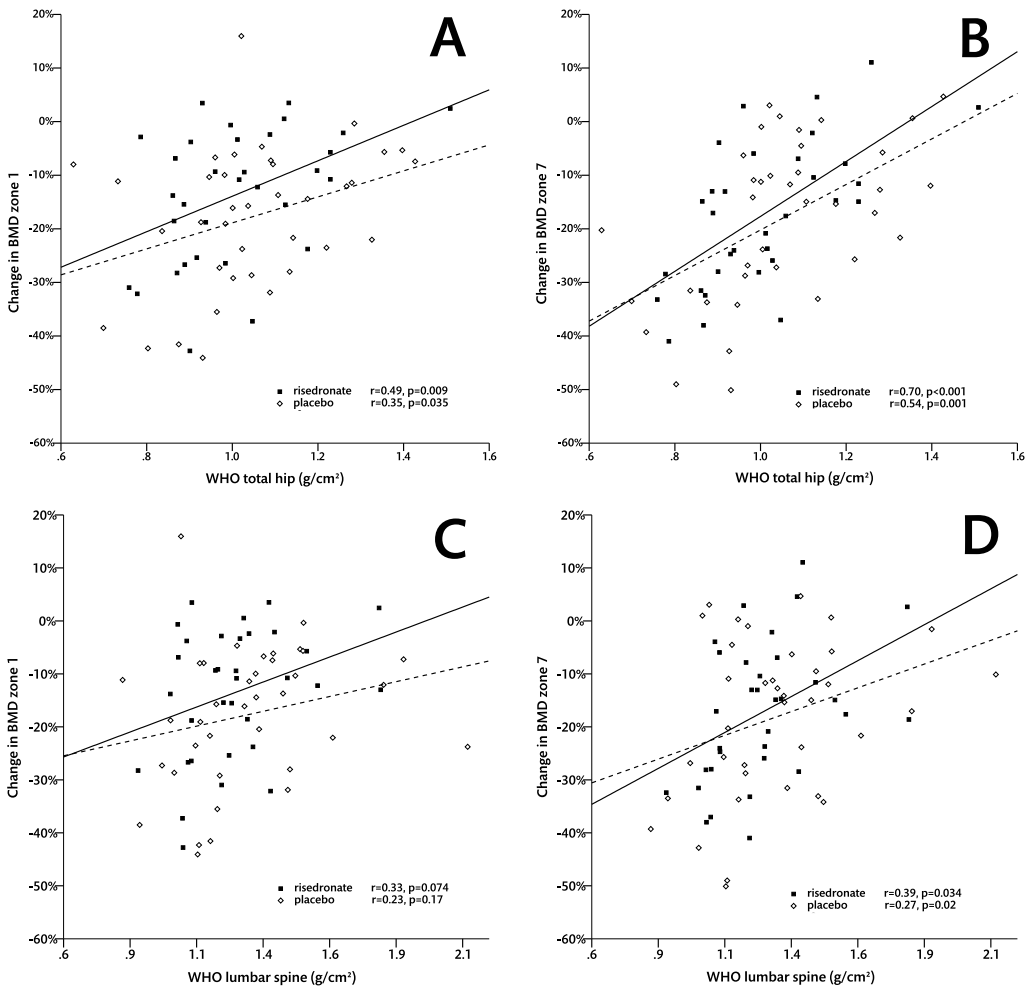


FIGURE 5. Effect of general bone mass on primary end point after 24 months.

Scatter plot of periprosthetic bone loss in zone 1 and 7 at 24 months against preoperative BMD in the hip (A, B) and lumbar spine (C, D) with regression lines for risedronate (solid line) and placebo (dashed line).

bisphosphonates and risk for revision after primary THA in osteoporotic patients were presented.⁴⁷ A total of 632 patients who were revised after primary THA were compared to 1.262 non-revised controls. No overall difference in risk for revision due to aseptic loosening was detected between users and non-users of bisphosphonates. However, a subgroup analysis of patients with bisphosphonate treatment for more than 240 days, showed a tendency towards a decreased

risk for revision.

In our study, we found that patients with a lower preoperatively BMD lose significantly more bone after THA (Figure 4 and 5). Before surgery, we measured BMD of the proximal femur and vertebrae L₁-L₄ and found that patients in the placebo group with low preoperative bone mass had lost 23% and 27% in zone 1 and 7 of the operated hip after 2 years whereas patients with high systemic BMD lost only 14% and 11%,

/ Study III

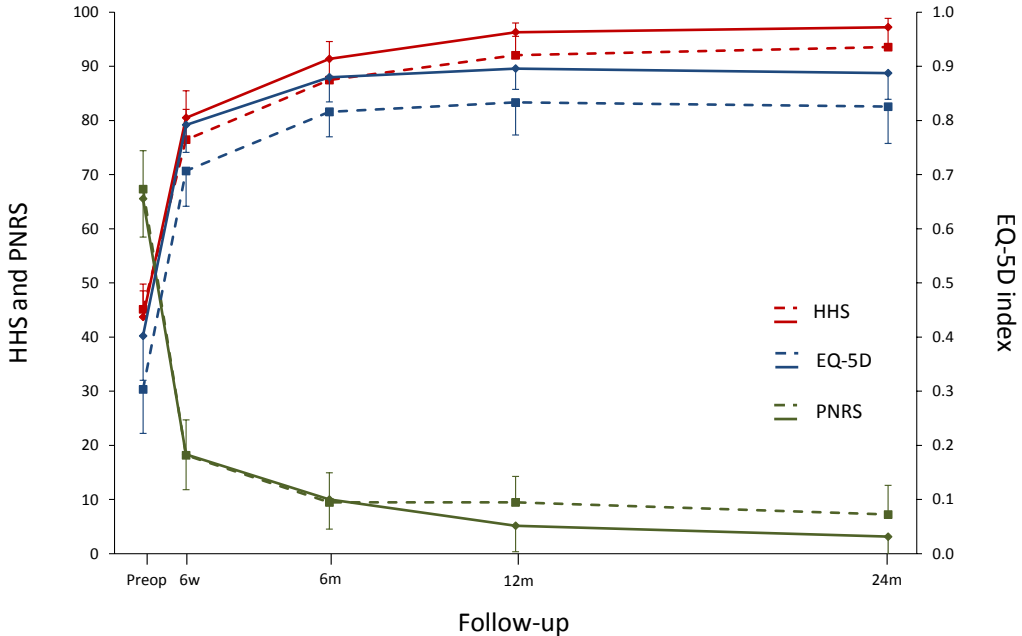


FIGURE 6. Clinical outcome

Mean (95% CI) values in patients receiving either risedronate (solid line) or placebo (dashed line) for Harris Hip Score (HHS), Health-related Quality of Life (EuroQoL) and Pain Numeric Rating Scale (PNRS).

respectively. This is consistent with results from other studies showing a correlation between low preoperative bone mass and increased bone loss around uncemented stems.^{5,39}

Together with the results from Thillemann et al.⁴⁷ above, this may indicate that prolonged treatment with bisphosphonate after THA in osteoporotic patients is warranted. Bone loss around THA is suspected to be continuous and to be faster than normal ageing, at least in zone 7.¹³ The length of treatment must be long enough to reach the normal steady state in bone metabolism, maybe life-long.

We found a statistically significant higher number of endosteal bone bridges (spot welds) in the placebo group. Despite this, all stems were firmly fixed and the migration did not differ between the groups. There are two possible explanations who alone, or together, could explain this.

First, the higher regional bone resorption identified in the placebo group lowers the at-

tenuation and makes the bone bridges easier to observe on plain X-ray film. Typically spot-welds are found in the proximal regions where the stress-shielding effect is most obvious and the bone bridges contrast distinctly with the surrounding bone. In the treatment group where the stems apparently are just as well fixed according to other parameters, the spot welds are blurred by the high attenuation.

Second, normally, foci of traumatized and devitalized cancellous bone trabeculae are remodeled post-operatively by osteoclasts followed by an osteoblast phase. Since risedronate effectively aborts the osteoclast response at the interface, we hypothesize that bone repair is slower and probably more homogenous which would explain absence of spot-welds seen on the radiographs in the treatment group.

This finding requires further investigation, since this study was not power calculated for this end point.

STRENGTHS AND WEAKNESSES

The strengths of our study include a high follow-up rate and a large sample size. To our knowledge this is the largest randomized clinical trial studying the effect of bisphosphonates after an arthroplasty. The study was also double-blinded and analysis of efficacy was done according to intention-to-treat, an approach that is lacking, or not reported, in most previously published studies.^{48,50,52-54}

One aim of this trial was to replicate the clinical setting; patients will stop taking the study medication if there are side-effects, something that occurred in 4 of our subjects in the treatment group. This is important, because if you exclude patients not taking their medication this will boost the effect of the studied drug.

A weakness of this study is the 2 different concepts of fixation of the acetabular component. However, the polyethylene was the same for both types of fixation and different types of articulation have not been shown to affect adaptive bone remodelling after THA.³⁶

CONCLUSION

In accordance with other studies, we demonstrate the antiresorptive effect of a bisphosphonate after THA but also that this effect is time-dependent and the bone sparing effect diminishes in the year following cessation of therapy. Whether the initial benefit of a time-limited bisphosphonate treatment in adjunction with THA can be justified is unclear.⁸ A prolonged treatment (life-long?) may show other results.

In conclusion, risedronate given once weekly for 6 months after THA is effective in preventing periprosthetic bone resorption around an uncemented femoral stem up to 12 months, with a trend towards an effect up to 24 months post-operatively.

Future studies of bisphosphonate treatment after THA should focus on patients who have both osteoarthritis and a low BMD of the hip. ◉

TABLE 4. Studies on bisphosphonates and THA in humans, the current study in the bottom for comparison.

A	B	C	D	E	F	G	H	I	J	K
Venesmaa et al. ³²	2001	oral alendronate 10 mg q.d. 6 m	I:8, C:5	OA	UPP	BMD	DXA	6 m	no	n.r.
Wilkinson et al. ³⁴	2001	i.v. pamidronate 90 mg bol.	I:23, C:24	M	CT	BMD	DXA	6 m	yes	no
Hennigs et al. ³⁰	2002	I1: oral alendronate 10 mg q.d. 10 w I2: oral alendronate 20 mg q.d. 5 w	I1:21, I2:21, C:24	M	UPP/GB	BMD	DXA	12 m	no	n.r.
Nehme et al. ³¹	2003	oral alendronate 10 mg q.d. 24 m	I:18, C:20	N/A	CT	BMD	DXA	24 m	yes	n.r.
Yamaguchi et al. ³⁶	2003	oral cyclic ethidronate q.d. 12 m	I:23, C:30	CDH	UFP/UPP	BMD	DXA	12 m	no	no
Yamaguchi et al. ³⁵	2004	I1: oral cyclic ethidronate q.d. 12 m, start postop I2: oral cyclic ethidronate q.d. 12 m start after 18 m	I1:16, I2:15, C:24	CDH	UFP/UPP	BMD	DXA	30 m	no	no
Wilkinson et al. ³³	2005	trial extension ⁵⁵	I:23, C:24	M	CT	BMD/migration	DXA/EBRA	24 m	yes	no
Arabmotlagh et al. ²⁹	2006	oral alendronate 20 mg q.d. 2 m, then 10 mg q.d. 2 (I1) or 4 (I2) m	I1:13, I2:14, C:24	OA	UPP/GB	BMD	DXA	12 m	yes	n.r.
Yamasaki et al. ³⁷	2007	oral risedronate 2.5 mg q.d. 6 m	I:19, C:21	CDH	UFP/UPP	BMD	DXA	6 m	no	no
Arabmotlagh et al. ²⁸	2009	trial extension ⁷	I1:14, I2:15, C:20	M	UPP/GB	BMD	DXA	72 m	no	n.r.
Friedl et al. ³⁹	2009	i.v. zoledronic acid 4 mg bol.	I:25, C:24	ON	GB	migration	EBRA	36 m	yes	n.r.
Sköldenberg et al.	2010	oral risedronate 35 mg q.w. 6 m	I:36, C:37	OA	UPPH	BMD	DXA/EBRA	24 m	yes	yes

A Author

B Year published

C Bisphosphonate regimen: q.d.=once daily, bol.=single bolus dose, q.w.=once weekly

D Sample size: I=intervention group, C=control group

E Diagnosis: OA=osteoarthritis, M=mixed

diagnoses, CDH=congenital dysplasia of the hip, ON=osteonecrosis of the femoral head

F Design of stem: GB=uncemented grit-blasted, CT=cemented tapered, UFP=uncemented full porous-coated, UPP= uncemented proximally porous-coated, UPPH=uncemented proximally porous-coated with hydroxyapatite

G Primary outcome variable

H Method used for determining efficacy

I Length of follow-up

J Blinding

K Study analyzed according to intention-to-treat. n.r. = not reported

REFERENCES

- Albanese CV, Santori FS, Pavan L, Learmonth ID, Passariello R. Periprosthetic DXA after total hip arthroplasty with short vs. ultra-short custom-made femoral stems: 37 patients followed for 3 years. *Acta Orthop*. 2009;80(3):291-7.
- Alm JJ, Makinen TJ, Lankinen P, Moritz N, Vahlberg T, Aro HT. Female patients with low systemic BMD are prone to bone loss in Gruen zone 7 after cementless total hip arthroplasty. *Acta Orthop*. 2009;80(5):531-7.
- Altman DG, Schulz KF, Moher D, Egger M, Davidoff F, Elbourne D, Gotzsche PC, Lang T. The revised CONSORT statement for reporting randomized trials: explanation and elaboration. *Ann Intern Med*. 2001;134(8):663-94.
- Ang KC, Das De S, Goh JC, Low SL, Bose K. Periprosthetic bone remodelling after cementless total hip replacement. A prospective comparison of two different implant designs. *J Bone Joint Surg Br*. 1997;79(4):675-9.
- Arabmotlagh M, Hennigs T, Warzecha J, Rittmeister M. Bone strength influences periprosthetic bone loss after hip arthroplasty. *Clin Orthop Relat Res*. 2005;440:178-83.
- Arabmotlagh M, Pilz M, Warzecha J, Rauschmann M. Changes of femoral periprosthetic bone mineral density 6 years after treatment with alendronate following total hip arthroplasty. *J Orthop Res*. 2009;27(2):183-8.
- Arabmotlagh M, Rittmeister M, Hennigs T. Alendronate prevents femoral periprosthetic bone loss following total hip arthroplasty: prospective randomized double-blind study. *J Orthop Res*. 2006;24(7):1336-41.
- Bhandari M, Bajammal S, Guyatt GH, Griffith L, Busse JW, Schunemann H, Einhorn TA. Effect of bisphosphonates on periprosthetic bone mineral density after total joint arthroplasty. A meta-analysis. *J Bone Joint Surg Am*. 2005;87(2):293-301.
- Biedermann R, Krismer M, Stockl B, Mayrhofer P, Ornstein E, Franzen H. Accuracy of EBRA-FCA in the measurement of migration of femoral components of total hip replacement. *Einzel-Bild-Röntgen-Analyse-femoral component analysis*. *J Bone Joint Surg Br*. 1999;81(2):266-72.
- Bobyn JD, Mortimer ES, Glassman AH, Engh CA, Miller JE, Brooks CE. Producing and avoiding stress shielding. Laboratory and clinical observations of noncemented total hip arthroplasty. *Clin Orthop Relat Res*. 1992(274):79-96.
- Bobyn JD, Tanzer M, Glassman AH. Stress-related bone resorption. In: Shanbhag A, et al., editors. *Joint replacement and bone resorption: pathology, biomaterials, and clinical practice* / edited by Arun Shanbhag, Harry E Rubash, Joshua J Jacobs. New York: Taylor & Francis group; 2006. p. 375-97.
- Bodén H, Adolphson P. No adverse effects of early weight bearing after uncemented total hip arthroplasty: a randomized study of 20 patients. *Acta Orthop Scand*. 2004;75(1):21-9.
- Bodén HS, Sköldenberg OG, Salemyr MO, Lundberg HJ, Adolphson PY. Continuous bone loss around a tapered uncemented femoral stem: a long-term evaluation with DEXA. *Acta Orthop*. 2006;77(6):877-85.
- Brooker AF, Bowerman JW, Robinson RA, Riley LH, Jr. Ectopic ossification following total hip replacement. Incidence and a method of classification. *J Bone Joint Surg Am*. 1973;55(8):1629-32.
- Brooks R. EuroQol: the current state of play. *Health Policy*. 1996;37(1):53-72.
- Burström K, Johannesson M, Diderichsen F. Swedish population health-related quality of life results using the EQ-5D. *Qual Life Res*. 2001;10(7):621-35.
- DeLee JG, Charnley J. Radiological demarcation of cemented sockets in total hip replacement. *Clin Orthop Relat Res*. 1976(121):20-32.
- Dorr LD, Faugere MC, Mackel AM, Gruen TA, Bogner B, Malluche HH. Structural and cellular assessment of bone quality of proximal femur. *Bone*. 1993;14(3):231-42.
- Downie WW, Leatham PA, Rhind VM, Wright V, Branco JA, Anderson JA. Studies with pain rating scales. *Ann Rheum Dis*. 1978;37(4):378-81.
- Engh CA, Bobyn JD, Glassman AH. Porous-coated hip replacement. The factors governing bone ingrowth, stress shielding, and clinical results. *J Bone Joint Surg Br*. 1987;69(1):45-55.
- Engh CA, Massin P, Suthers KE. Roentgenographic assessment of the biologic fixation of porous-surfaced femoral components. *Clin Orthop Relat Res*. 1990(257):107-28.
- Friedl G, Radl R, Stihsen C, Rehak P, Aigner R, Windhager R. The effect of a single infusion of zoledronic acid on early implant migration in total hip arthroplasty. A randomized, double-blind, controlled trial. *J Bone Joint Surg Am*. 2009;91(2):274-81.
- Gruen TA, McNeice GM, Amstutz HC. "Modes of failure" of cemented stem-type femoral components: a radiographic analysis of loosening. *Clin Orthop Relat Res*. 1979(141):17-27.
- Hansson U, Toksvig-Larsen S, Ryd L, Aspenberg P. Once-weekly oral medication with alendronate does not prevent migration of knee prostheses: A double-blind randomized RSA study. *Acta Orthop*. 2009;80(1):41-5.
- Harris ST, Watts NB, Genant HK, McKeever CD, Hangartner T, Keller M, et al. Effects of risedronate treatment on vertebral and nonvertebral fractures in women with postmenopausal osteoporosis: a randomized controlled trial. Vertebral Efficacy With Risedronate Therapy (VERT) Study Group. *JAMA*. 1999;282(14):1344-52.
- Harris WH. Traumatic arthritis of the hip after dislocation and acetabular fractures: treatment by mold arthroplasty. An end-result study using a new method of result evaluation. *J Bone Joint Surg Am*. 1969;51(4):737-55.
- Hennigs T, Arabmotlagh M, Schwarz A, Zichner L. Dose-dependent prevention of early periprosthetic bone loss by alendronate. *Z Orthop Ihre Grenzgeb*. 2002;140(1):42-7.
- Hilding M, Ryd L, Toksvig-Larsen S, Aspenberg P. Clodronate prevents prosthetic migration: a randomized radiostereometric study of 50 total knee patients. *Acta Orthop Scand*. 2000;71(6):553-7.
- Kilgus DJ, Shimaoka EE, Tipton JS,

- Eberle RW. Dual-energy X-ray absorptiometry measurement of bone mineral density around porous-coated cementless femoral implants. Methods and preliminary results. *J Bone Joint Surg Br.* 1993;75(2):279-87.
30. **Krismer M, Biedermann R, Stockl B, Fischer M, Bauer R, Haid C.** The prediction of failure of the stem in THR by measurement of early migration using EBRA-FCA. Einzel-Bild-Roentgen-Analyse-femoral component analysis. *J Bone Joint Surg Br.* 1999;81(2):273-80.
31. **Kärholm J, Anderberg C, Snorrason F, Thanner J, Langeland N, Malchau H, Herberts P.** Evaluation of a femoral stem with reduced stiffness. A randomized study with use of radiostereometry and bone densitometry. *J Bone Joint Surg Am.* 2002;84-A(9):1651-8.
32. **Kärholm J, Borsen B, Lowenhjelm G, Snorrason F.** Does early micromotion of femoral stem prostheses matter? 4-7-year stereoradiographic follow-up of 84 cemented prostheses. *J Bone Joint Surg Br.* 1994;76(6):912-7.
33. **Lindahl H.** Epidemiology of periprosthetic femur fracture around a total hip arthroplasty. *Injury.* 2007;38(6):651-4.
34. **Muller S, Irgens F, Aamodt A.** A quantitative and qualitative analysis of bone remodelling around custom uncemented femoral stems: a five-year DEXA follow-up. *Clin Biomech (Bristol, Avon).* 2005;20(3):277-82.
35. **Nehme A, Maalouf G, Tricoire JL, Giordano G, Chiron P, Puget J.** [Effect of alendronate on periprosthetic bone loss after cemented primary total hip arthroplasty: a prospective randomized study]. *Rev Chir Orthop Reparatrice Appar Mot.* 2003;89(7):593-8.
36. **Nygaard M, Zerahn B, Bruce C, Soballe K, Borgwardt A.** Early periprosthetic femoral bone remodelling using different bearing material combinations in total hip arthroplasties: a prospective randomised study. *European cells & materials.* 2004;8:65-73.
37. **Peter B, Gauthier O, Laib S, Bujoli B, Guicheux J, Janvier P, van Lenthe GH, Muller R, Zambelli PY, Boulter JM, Pioletti DP.** Local delivery of bisphosphonate from coated orthopedic implants increases implants mechanical stability in osteoporotic rats. *J Biomed Mater Res A.* 2006;76(1):133-43.
38. **Rabin R, de Charro F.** EQ-5D: a measure of health status from the EuroQol Group. *Ann Med.* 2001;33(5):337-43.
39. **Rahmy AI, Gosens T, Blake GM, Tonino A, Fogelman I.** Periprosthetic bone remodelling of two types of uncemented femoral implant with proximal hydroxyapatite coating: a 3-year follow-up study addressing the influence of prosthesis design and preoperative bone density on periprosthetic bone loss. *Osteoporos Int.* 2004;15(4):281-9.
40. **Ryd L, Albrektsson BE, Carlsson L, Dansgard F, Herberts P, Lindstrand A, Regner L, Toksvig-Larsen S.** Roentgen stereophotogrammetric analysis as a predictor of mechanical loosening of knee prostheses. *J Bone Joint Surg Br.* 1995;77(3):377-83.
41. **Sabo D, Reiter A, Simank HG, Thomsen M, Lukoschek M, Ewerbeck V.** Periprosthetic mineralization around cementless total hip endoprosthesis: longitudinal study and cross-sectional study on titanium threaded acetabular cup and cementless Spotorno stem with DEXA. *Calcif Tissue Int.* 1998;62(2):177-82.
42. **Shanbhag AS, Hasselman CT, Rubash HE.** The John Charnley Award. Inhibition of wear debris mediated osteolysis in a canine total hip arthroplasty model. *Clin Orthop Relat Res.* 1997(344):33-43.
43. **Skoglund B, Holmertz J, Aspenberg P.** Systemic and local ibandronate enhance screw fixation. *J Orthop Res.* 2004;22(5):1108-13.
44. **Sköldenberg OG, Bodén HS, Salemyr MO, Ahl TE, Adolphson PY.** Periprosthetic proximal bone loss after uncemented hip arthroplasty is related to stem size: DXA measurements in 138 patients followed for 2-7 years. *Acta Orthop.* 2006;77(3):386-92.
45. **Tanzer M, Karabasz D, Krygier JJ, Cohen R, Bobyn JD.** The Otto Aufranc Award: bone augmentation around and within porous implants by local bisphosphonate elution. *Clin Orthop Relat Res.* 2005;441:30-9.
46. **Thien TM, Ahnfelt L, Eriksson M, Stromberg C, Kärholm J.** Immediate weight bearing after uncemented total hip arthroplasty with an anteverted stem: a prospective randomized comparison using radiostereometry. *Acta Orthop.* 2007;78(6):730-8.
47. **Thillemann TM, Pedersen AB, Mehnert F, Johnsen SP, Soballe K.** Postoperative use of bisphosphonates and risk of revision after primary total hip arthroplasty: a nationwide population-based study. *Bone.* 2010;46(4):946-51.
48. **Venesmaa PK, Kroger HP, Miettinen HJ, Jurvelin JS, Suomalainen OT, Alhav EM.** Alendronate reduces periprosthetic bone loss after uncemented primary total hip arthroplasty: a prospective randomized study. *J Bone Miner Res.* 2001;16(11):2126-31.
49. **Wilkinson JM, Eagleton AC, Stockley I, Peel NF, Hamer AJ, Eastell R.** Effect of pamidronate on bone turnover and implant migration after total hip arthroplasty: a randomized trial. *J Orthop Res.* 2005;23(1):1-8.
50. **Wilkinson JM, Stockley I, Peel NF, Hamer AJ, Elson RA, Barrington NA, Eastell R.** Effect of pamidronate in preventing local bone loss after total hip arthroplasty: a randomized, double-blind, controlled trial. *J Bone Miner Res.* 2001;16(3):556-64.
51. **Yamaguchi K, Masuhara K, Ohzono K, Sugano N, Nishii T, Ochi T.** Evaluation of periprosthetic bone remodeling after cementless total hip arthroplasty. The influence of the extent of porous coating. *J Bone Joint Surg Am.* 2000;82-A(10):1426-31.
52. **Yamaguchi K, Masuhara K, Yamasaki S, Fuji T, Seino Y.** Effects of discontinuation as well as intervention of cyclic therapy with etidronate on bone remodeling after cementless total hip arthroplasty. *Bone.* 2004;35(1):217-23.
53. **Yamaguchi K, Masuhara K, Yamasaki S, Nakai T, Fuji T.** Cyclic therapy with etidronate has a therapeutic effect against local osteoporosis after cementless total hip arthroplasty. *Bone.* 2003;33(1):144-9.
54. **Yamasaki S, Masuhara K, Yamaguchi K, Nakai T, Fuji T, Seino Y.** Risedronate reduces postoperative bone resorption after cementless total hip arthroplasty. *Osteoporos Int.* 2007;18(7):1009-15.

IV

A new uncemented hydroxyapatite-coated femoral stem for treatment of femoral neck fractures

A two-year radiostereometric and bone densitometric evaluation in 50 hips

Olof G Sköldenberg¹, Mats O Salemyr¹, Henrik S Bodén¹, Torbjörn E Ahl¹, Arne Lundberg², Per Y Adolphson¹

ABSTRACT

BACKGROUND

The aim of this study was to evaluate the fixation of, bone remodelling around, and clinical outcome after surgery of a new, uncemented, fully hydroxyapatite-coated, collared and tapered femoral stem, designed specifically for elderly patients with a femoral neck fracture.

METHODS

We enrolled 50 patients, of at least 70 years of age, with an acute displaced femoral neck fracture in this prospective single cohort study. The patients received a total hip arthroplasty using the new stem and were followed up at regular intervals for a period of 2 years.

RESULTS

The fixation was evaluated with radiostereometric analysis and dual-energy x-ray absorptiometry was used to investigate bone remodelling. Hip function and health-related quality of life were assessed using the Harris hip score and EQ-5D. Up to 6 weeks post surgery, we noted a mean subsidence of 0.2 mm and a retroversion of a mean of 1.2°. No stem migrated after the 3 month follow-up. The patients had a continuous loss of periprosthetic bone that amounted to 16% at 2 years. At the 2-year follow-up the mean Harris hip score was 82.

CONCLUSIONS

A total hip arthroplasty with this new uncemented stem can be used for osteoporotic fractures of the femoral neck. ⊙

ARTICLE INFORMATION

¹ Karolinska Institutet, Department of Clinical Sciences, Division of Orthopaedics at Danderyd Hospital, Stockholm, Sweden.

² Karolinska Institutet, Department of Clinical Science, Intervention and Technology at Karolinska University Hospital Huddinge, Stockholm, Sweden.

Investigation performed between 2005 and 2010 at the Orthopaedic Department, Danderyd Hospital, Stockholm, Sweden.

CORRESPONDENCE

Dr. Olof Sköldenberg
olof.skoldenberg@ds.se

KEYWORDS

Femoral neck fracture
Total hip arthroplasty
Uncemented femoral stem
Migration
Radiostereometry
Bone resorption

ACKNOWLEDGEMENTS

We would like to thank the research nurses Helene Sjöö and Paula Kelly-Pettersson for their invaluable help with inclusion of the patients and the clinical evaluations.

We would also like to extend our gratitude to Hans-Jerker Lundberg, Department of Nuclear Medicine, Danderyd Hospital for his technical assistance with the DEXA analyses and to Eva Hofmann and Lise-Lotte Widmark for all their help with the RSA examinations.

INTRODUCTION

*There is solid evidence to support recommending a primary hip arthroplasty instead of internal fixation (IF) for a displaced femoral neck fracture in elderly patients who are independent walkers and have no severe cognitive impairment.*¹⁻⁴

Cemented femoral stems are used both in total hip arthroplasty (THA) and hemiarthroplasty and earlier studies have supported the use of cemented stems in hip fracture patients, mainly due to decreased post-operative pain during rehabilitation.⁵⁻⁷

However, the concept of inserting an uncemented stem, even in elderly patients, is attractive to many surgeons⁸ as bone cement has several major, albeit uncommon, negative side-effects. These are mainly cardiac arrhythmias and cardio-respiratory collapse which can occur during the cementing process.⁹

The mechanisms involved are not yet fully understood but are most likely caused by pulmonary embolization of bone marrow and methyl-methacrylate particles.¹⁰⁻¹¹ The mortality rate in this frail patient group may therefore be higher after cemented rather than uncemented arthroplasty.¹²⁻¹³

The potential advantages of an uncemented femoral stem are also related to the shorter duration of surgery (thereby possibly minimizing intraoperative bleeding and decreasing the risk of infection).⁵ The disadvantages include an

increased risk for periprosthetic fractures, thigh pain and stress-shielding of the proximal femur.

A new uncemented femoral stem, based on a successful earlier design,¹⁴⁻¹⁵ with full hydroxyapatite (HA) coating to enable fast ingrowth in osteoporotic bone,¹⁶ and a collar to avoid excessive subsidence, has been developed specifically for femoral neck fractures [Biomet Fracture Stem (BFX®)].

The purpose of this investigation was to study the fixation of and bone remodelling around the new stem in a representative sample of elderly patients with a displaced femoral neck fracture.

We used radiostereometric analysis (RSA)¹⁷ to evaluate the fixation of the stem and although RSA has been used to study the healing of femoral neck fractures after IF,¹⁸ no study using RSA has been carried out after hip arthroplasty in this patient group.

Similarly, bone remodelling around femoral stems after THA in patients with degenerative joint disease has been extensively studied using dual-energy x-ray absorptiometry (DXA) but, to our knowledge, it has never been used before in this patient group.¹⁹⁻²¹ ◉

PATIENTS AND METHODS

This prospective single cohort study was carried out between October 2005 and April 2010 (inclusion period October 2005 to April 2008) at the Orthopaedic Department, Danderyd Hospital, Stockholm, Sweden. The study was performed in accordance with Good Clinical Practice (GCP) and the ethical principles of the Helsinki declaration. Both the Ethics Committee of the Karolinska Institute (Dnr 04-086/4) and the Committee for Protection Against Radiation at Danderyd Hospital (Dnr 005-5) approved the study.

The trial was initiated, designed and performed as an academic investigation. Biomet (Biomet Orthopaedics AB, Sjöbo, Sweden)

marked the femoral implants but took no other part of the study.

PATIENTS

All 229 patients who were admitted to our emergency department with an acute (<24h before admission) femoral neck fracture during the inclusion period between October 2005 and April 2008 were screened for participation in the study.

The inclusion criteria were a displaced fracture (Garden III or IV),²² an age of at least 70 years, intact cognitive function [at least 8 correct answers on a 10-item (SPMSQ) mental test],²³ the ability to walk independently with or with-

out the help of walking aids and a willingness to participate in the study. Patients with a previous fracture in the same hip, a pathological fracture, those deemed not suitable for THA by the anaesthesiologist or those who for any other reason were unsuitable to participate in the study, were excluded (Figure 1).

A research nurse gave the patients oral and written information about the study, and those who agreed to take part of the study gave their written informed consent (Table 1).

STEM DESIGN

The new implant, Biomet Fracture Stem, BFX® (Biomet UK Ltd, Bridgend, U.K.), (Figure 2) is a

tapered, collared, stem intended for uncemented fixation in the femur. It is made of a titanium alloy (Ti-6Al-4V) with a grit-blasted surface roughness of 7.5-10 µm. It has a straight 3° proximal-to-distal taper in 2 planes and a taper from the lateral shoulder to the medial calcar area.

The geometry of the stem, except for the collar, is identical to the Bi-Metric® stem.¹⁴⁻¹⁵ The stem has plasma-sprayed HA on the entire surface (thickness 65-95 µm, crystallinity 50-70%, purity >95%) to enable fast ingrowth in osteoporotic bone.²⁴

The stem is available in 6 sizes (7-17 mm, uneven sizes only), all with a neck/shaft angle of 140°.

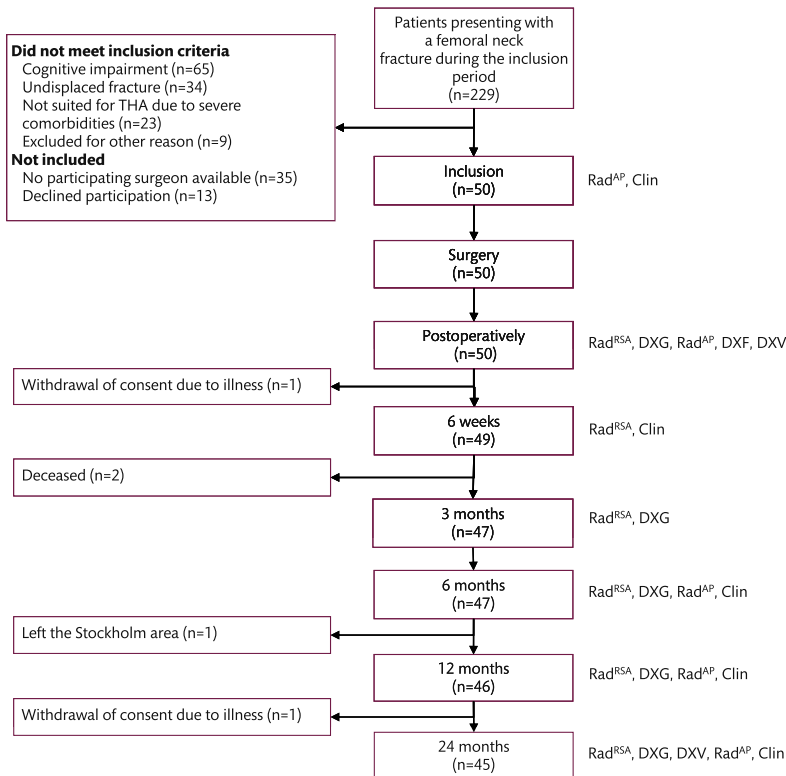


FIGURE 1. Study protocol

Rad^{RSA}=Calibrated stereo radiographs for RSA, DXG=DXA scan of Gruen zones, DXF=DXA scan of the contralateral proximal femur (WHO), DXV=DXA scan of vertebrae L₁-L₄, Rad^{AP}= anteroposterior and lateral radiographs, Clin=clinical outcome scores (HHS, EQ-5D and PNRs). Patients lost to follow-up have been contacted by phone, they have no hip related pain and their hips have not dislocated or been revised. Their RSA, DXA and clinical data have been included in the analyses until the last follow-up.

/ Study IV



FIGURE 2. Biomet Fracture Stem (BFX®)

The implant has been modified for RSA with tantalum marker beads at the shoulder, collar and tip of the prosthesis.

SURGERY

Preoperative planning was performed with a digital templating software (mDesk®, RSA Biomedical, Umeå, Sweden). The patients underwent surgery with a THA using the new stem articulating on a 32 mm cobalt-chrome head against a cemented cup (ZCA®, Zimmer, Warsaw, Indiana, U.S.A.).

The operations were all done within the first 48 hours after admission by 1 of 4 surgeons (OS, MS, HB or TA). A posterior approach, with repair of the posterior capsule and external rotator muscles, was used in all patients.

The resection of the femoral neck was done using a template and the femur was reamed until cortical bone contact was obtained. Thereafter, the proximal femur was prepared with broaches of increasing size until rotational stability was achieved. With the final broach in place, the calcar femoris was planed flush using a planing tool. Thus, the prosthetic collar rests on the calcar femoris when the prosthesis is fully seated and rotationally stable (collar-calcus contact).

For some hips, the fracture line was more

distal than the ideal collar resection line; in these hips, the collar of the stem did not rest on bone when the stem was rotationally stable (no prosthetic collar-calcus contact).

Before the final implant was inserted, 5 to 9 tantalum marker beads (1.0 mm in diameter) were inserted in the cancellous bone of the proximal femur.

Intravenous tranexamic acid (Cyclokapron®, Pfizer, Sweden) was administered before the start of surgery to reduce bleeding. Prophylactic antibiotics (Cloxacillin®, Meda, Sweden) were given in the first 24 hours post-operatively and daltaparin (Fragmin®, AstraZeneca, Sweden) was given 10 days post-operatively to prevent thromboses.

The patients were mobilized using a standard physiotherapy program. They were encouraged to weight bear fully using crutches for support.

OUTCOME MEASURES

The primary end point of the study was migration of the stem. Secondary end points included change in bone mineral density (BMD) in 7 Gruen zones²⁵ around the stem and clinical outcome. The study protocol is shown in Figure 1.

Radiostereometric analysis

RSA is a high-precision method to measure three dimensional (3-D) micro-motions from calibrated stereo radiographs¹⁷ and is a standard for evaluating new implants since early migration can predict implant loosening.²⁶ The RSA method in this study follows the published guidelines for RSA.²⁷

We took digital calibrated radiographs (Bucky Diagnostic®, Philips, Eindhoven, Netherlands) using 1 fix and 1 mobile Roentgen source (120 kV, 4-6 mAs), and a uniplanar calibration cage (Uniplanar digital 43, RSA Biomedical AB, Umeå, Sweden). All data were analysed using the UmRSA® computer software (RSA Biomedical AB, Umeå, Sweden).

The markers in the proximal femoral bone form one segment. The centre of the prosthetic head, in combination with the tantalum marker beads in the femoral stem, forms another segment. The 3-D translations and rotations of the calculated centre of gravity of the femoral stem segment in relation to the femoral bone segment

were calculated at each follow-up visit with the immediate post-operative examination as baseline. We also measured the maximum total point motion (MTPM). This is the 3-D translation vector of the femoral stem marker that has the largest movement and is seen as an indicator of the overall magnitude of migration.

At 12 months, we performed double examinations 15 minutes apart on 25 patients with complete repositioning of the roentgen tubes and the calibration cage. We calculated the precision as the 99% confidence limits (SD 2.7) of the difference between these examinations. For translation along the x (transverse), y (vertical) and z (anterioposterior) axes, it was 0.27, 0.19 and 0.52 mm, respectively. For rotation about the x-axis (flexion/extension), y-axis (ante-/retroversion) and z-axis (varus/valgus) it was 0.52, 0.76 and 0.27°, respectively and for MTPM it was 0.74 mm. The precision for our RSA-setting is similar to previously reported trials.^{16,28}

The mean error of rigid body fitting²⁹ is used to evaluate the stability of marker position over time. We excluded examinations where this value was >0.3 mm, indicating migration of markers. Condition number²⁹ is used to evaluate marker distribution and a high value precludes accurate measurements of z-translation as well as segment rotation and MTPM. Therefore, in examinations where the condition number exceeds 100, only transverse (x) and vertical (y) translations were calculated.

Bone mineral density and radiological evaluation

BMD of the periprosthetic femur was measured in the 7 Gruen zones²⁵ in the frontal plane using DXA (DPX-L™, Lunar Co., Madison, Wisconsin, U.S.A.). During scanning, the patient was placed in the supine position with standard knee and foot supports and the femur was positioned in neutral rotation. The change in periprosthetic BMD ratio in all individual zones, as well as the entire periprosthetic region (zone 1-7), was calculated by dividing the BMD value at each follow-up visit by the post-operative BMD and converting it to percentage change.

We have previously made double measurements in 10 patients with complete repositioning

TABLE 1. Baseline data for the 50 patients.

Age – years, mean (range)	81 (70-92)
Female/male (n)	36/14
Height – cm, mean ±SD	168±9
Weight – kg, mean ±SD	66±14
BMI, mean ±SD	23±4
Charnley classification (A/B/C) (n)	31/5/14
Total hip (WHO) ^a	
Normal bone density (n)	9
Osteopenia (n)	14
Osteoporosis (n)	16
BMD – g/cm ² , mean ±SD	0.775±0.136
Lumbar spine (WHO) ^b	
Normal bone density (n)	16
Osteopenia (n)	13
Osteoporosis (n)	16
BMD – g/cm ² , mean ±SD	1.050±0.254
Injured hip (right/left) (n)	22/28
Concurrent medical disease (1-5) (n)	3/16/20/8/3
ASA classification (1-4) (n)	2/27/19/2
Stem size (9/11/13/15/17) (n)	3/10/22/10/5

^a Measured in 39 patients with a healthy contralateral hip at inclusion

^b Measured in 45 patients where lumbar spine BMD could be evaluated at inclusion

of the patients and the scanner.³⁰ Postoperatively, we measured BMD of the proximal femur of the healthy hip (WHO total hip) for patients in Charnley class A, and vertebrae L₁-L₄ (WHO lumbar spine) of all patients to assess the patient's general bone mass. The BMD of the L₁-L₄ vertebrae were also measured at 24 months postoperatively.

Varus/valgus angle and fill³¹ of the stem in the femoral canal were measured on radiographs with the digital templating software. The proximal fill was measured at the upper border of the lesser trochanter and the distal fill 3 cm proximally from the tip of the prosthesis. Fill was defined as good when there was an 80% fill on the anteroposterior radiograph and 70% fill on the lateral radiograph.³¹ At 24 months, the presence of heterotopic ossification was evaluated according to Brooker et al.³²

/ Study IV

Clinical outcome

Hip function was evaluated with Harris hip score (HHS).³³ This score has been validated for patients with femoral neck fractures.³⁴

Health-related quality of life was assessed with the EQ-5D (EuroQoL).³⁵ It describes health status in terms of 5 dimensions: mobility, self-care, usual activity, pain/discomfort and anxiety/depression. Each dimension is divided into 3 levels: 1 – no problems, 2 – some problems and 3 – extreme problems. This generates 243 different “health states” and the EQ-5D index score assigns each “health state” to a value, ranging from -0.59, indicating the worst possible health state, to 1, indicating full health. In this score, it is possible to have negative values, i.e. a perceived health state worse than death.

Pain from the operated hip was recorded using Pain Numeric Rating Scale (PNRS).³⁶ PNRS is an 11-point (0-10) numerical rating scale, the patients were asked to record their average pain in the operated hip during the last week. 0 denotes no pain and 10 indicates unbearable pain.

STATISTICAL ANALYSIS

With 20 patients, the study had a power (two-sided, $p=0.01$) of more than 99% and 93% to detect a continuous migration in MTPM and y-translation, respectively. These estimates were based upon a previous RSA study with the HA-coated version of the Bi-Metric stem¹⁶ where MTPM was mean (SD) 1.9 (1.3) mm and y-translation was 0.2 (0.2) mm. We recruited 50 patients to allow for loss to follow-up and to allow for sub-group analysis in subjects with high and low BMD.

We used analysis of covariance (ANCOVA) to study covariates affecting implant migration and bone loss. Firstly; to evaluate the effect of periprosthetic BMD on implant migration and bone loss, we used MTPM and BMD change in zone 1-7 as dependent variables and sex, age, BMI, stem size and immediate post-operative BMD in zone 1-7 as covariates. Median BMD was used to dichotomize the subjects into 2 groups, patients with either high or low BMD (high vs. low: mean BMD 1.77 ± 0.33 g/cm² and 1.35 ± 0.11 g/cm², respectively).

In the second analysis, we evaluated the effect of preoperative BMD on bone loss in a subgroup of 36 patients. These patients had a healthy contralateral femur at inclusion and we had complete follow-up data at the 24-month visit. These patients were all in Charnley class A or C, but did not differ from the rest of the patients with regards to anthropometrical data (data not shown).

Post-operative DXA scans of the healthy hip and vertebrae L1-L4 (WHO total hip and lumbar spine) were used as a proxy for preoperative BMD and categorized as normal (T-score >-1 SD), osteopenia (-1 SD \geq T-score >-2.5 SD) and osteoporosis (T-score ≤ -2.5 SD). In the analysis, BMD change in zone 1-7 was then used as the dependent variable and sex, age, BMI, stem size and T-score category of the hip or lumbar spine as covariates.

Between-group comparisons of continuous variables at follow-up were analyzed with the Mann-Whitney U test and within-group comparisons between baseline and follow-up values were analyzed with the Wilcoxon signed-rank test. We used chi-square test for nominal variables. P-values ≤ 0.05 were considered significant. We used the statistical software PASW Statistics 18.0 for Windows (IBM Corporation, Armonk, New York, U.S.A.).

RESULTS

COMPLICATIONS

One stem was revised during the study, it was removed and another uncemented stem was implanted 3 weeks after the initial surgery due to a deep wound infection; the infection has since healed uneventfully.

We noted 1 intraoperative fracture of the greater trochanter. The trochanter was reattached during surgery. Post-operatively, in the same patient, an undisplaced femoral fracture at the distal tip of the prosthesis was discovered. The patient was treated with protected weight bearing for 6 weeks.

At 18 months post-operatively this patient presented with a deep infection in the operated hip and was treated with an open synovectomy and antibiotics. The infection healed but the hip dislocated repeatedly after the reoperation. The cup was later replaced with a double-mobility press-fit cup and there has been no further dislocation since then.

The stem was not replaced and RSA results show that there has been no migration of the stem and the patients' hip function is excellent.

In all, 7 hips (14%) dislocated, 3 of these hips

had recurrent dislocations, only the cup which was converted to a double-mobility cup has been replaced. Two patients were treated with antibiotics due to a superficial wound infections.

SURGICAL AND RADIOLOGICAL RESULTS

Median operation time was 85 (range, 59-140) minutes and the intraoperative bleeding was 400 (range, 100-1400) ml. Thirteen patients required 1-2 and 3 patients required 3-4 blood transfusions during the hospital stay. Patients stayed in the hospital for a median of 7 (range, 5-11) days before continued rehabilitation at home (17 patients) or at a rehabilitation centre (33 patients).

Two stems were placed in 3° of varus; all other stems had neutral alignment.

The fill of the implant in the femoral canal was classified as good in 17 hips (34%) and we succeeded in achieving a collar-calcus contact in 33 hips (66%). The fill or collar-calcus contact did not affect migration or bone loss (data not shown).

At 24 months, 25 hips had no evidence of heterotopic ossification, 13 had class I-II and 7 class III-IV ossification.³²

TABLE 2. Migration of the stem

RSA data are missing for the hip that was revised as the result of a deep wound infection. In one dislocating hip, the stem retroverted 15 degrees and had a MTPM of 13 mm at 6 weeks. The stem has been stable on all subsequent examinations but due to the large initial migration, the stem is treated as an outlier and is not included in the RSA analysis. Mean \pm SD values are shown.

		Follow-up					p-value				
		6 weeks (n=44)	3 months (n=43)	6 months (n=44)	12 months (n=43)	24 months (n=43)	p ^a	p ^b	p ^c	p ^d	p ^e
Translation (mm)	transverse (x)	-0.03 \pm 0.27	-0.03 \pm 0.22	-0.04 \pm 0.23	-0.04 \pm 0.25	-0.02 \pm 0.25	0.37	0.80	0.81	0.97	0.57
	vertical (y)	-0.16 \pm 0.48	-0.18 \pm 0.48	-0.17 \pm 0.49	-0.16 \pm 0.52	-0.16 \pm 0.50	0.03	0.57	0.25	0.89	0.66
	anterioposterior (z)	-0.31 \pm 0.60	-0.33 \pm 0.56	-0.34 \pm 0.52	-0.19 \pm 0.60	-0.18 \pm 0.58	0.002	0.69	0.78	0.01	0.88
Rotation (°)	flexion/extension (x)	-0.16 \pm 0.53	-0.30 \pm 0.55	-0.27 \pm 0.62	-0.40 \pm 0.64	-0.56 \pm 0.76	0.02	0.05	0.86	0.001	0.01
	ante-/retroversion (y)	-1.16 \pm 1.88	-1.33 \pm 1.79	-1.29 \pm 1.91	-1.17 \pm 1.90	-1.16 \pm 1.99	<0.001	0.11	0.25	0.11	0.48
	varus/valgus (z)	0.01 \pm 0.62	0.03 \pm 0.52	0.02 \pm 0.53	0.01 \pm 0.55	-0.03 \pm 0.60	0.23	0.92	0.99	0.92	0.80
Total migration	MTPM	1.83 \pm 1.34	1.81 \pm 1.32	1.85 \pm 1.27	2.00 \pm 1.44	2.17 \pm 1.30	<0.001	0.22	0.51	0.32	0.47

n is the number of examinations analyzed after loss to follow-up, technical error, high values for mean error of rigid body fitting or a condition number over 100

^a calculated between postop and 6 weeks

^b calculated between 6 weeks and 3 months

^c calculated between 3 months and 6 months

^d calculated between 6 months and 12 months

^e calculated between 12 months and 24 months

/ Study IV

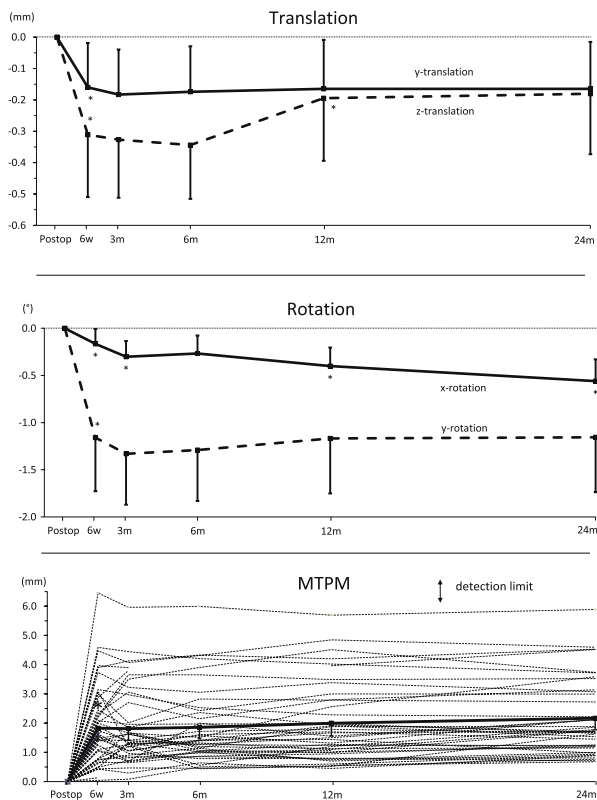


FIGURE 3. Migration of the stem

The mean (95% CI) migration of the stem in translation (A) and rotation (B). The mean (95%CI) (solid line) and individual MTPM (dashed line) with arrow showing the detection limit of true (at 99% level) migration (C). *indicates a significant ($p \leq 0.05$) mean migration compared to the previous examination.

MIGRATION OF THE STEM

Thirty-four stems migrated above the detection limit up to 6 weeks post-operatively and 4 stems had further migrated at the 3 month follow-up. After 3 months, all stems had stabilized.

The mean (SD) initial translation in the x, y and z-axes was -0.03 ± 0.27 , -0.16 ± 0.48 and -0.26 ± 0.56 mm with the corresponding rotation -0.16 ± 0.53 , -1.16 ± 1.88 and 0.01 ± 0.62 degrees at 6 weeks. MTPM was 1.83 ± 1.30 mm at 6 weeks. After this, the mean migration stopped except for rotation in flexion/extension (x), which indicated a small, but statistically significant, continuous migration between 12 and 24 months (Table 2, Figure 3).

Migration of the stem was significantly more pronounced in patients with a low periprosthetic BMD (Figure 4).

BONE REMODELLING

We found a continuous decrease of periprosthetic BMD, with the highest rate of bone loss occurring during the first 12 months, in all zones but zone 4, with a reduction of the total periprosthetic BMD with mean 16% at 24 months (Table 3 and Figure 5).

The bone loss was greatest in zone 1 and 7, with a decrease of 30% and 26%, respectively, at 24 months. Bone loss was significantly related to both the initial BMD surrounding the implant and the patients' general bone mass (Figure 4 and 6).

The 24-month BMD of vertebrae L1-L4 did not differ from that immediately postoperatively.

CLINICAL OUTCOME

There was a slight deterioration in function and an increased pain in the operated hip during the study period (HHS and PNRS pre-fracture vs. 24 months; mean 87 ± 11 and 0.4 ± 1.3 versus 82 ± 13 and 1.0 ± 1.9 , $p=0.006$ and 0.033 , respectively).

The outcome was worse for patients in Charnley class C where degenerative disease in other joints and/or associated medical comorbidities affected outcome. The median (range) HHS was 88 (100-52), 90 (91-80) and 76 (88-51) in class A, B and C, respectively.

Health-related quality of life also declined during the study but did not reach statistical significance (EQ-5D pre-fracture vs. 24 months; mean 0.71 ± 0.23 versus 0.63 ± 0.37 , $p=0.112$), (Table 4).

We found no correlation between clinical outcome and migration or bone loss (data not shown). ◉

Study IV /

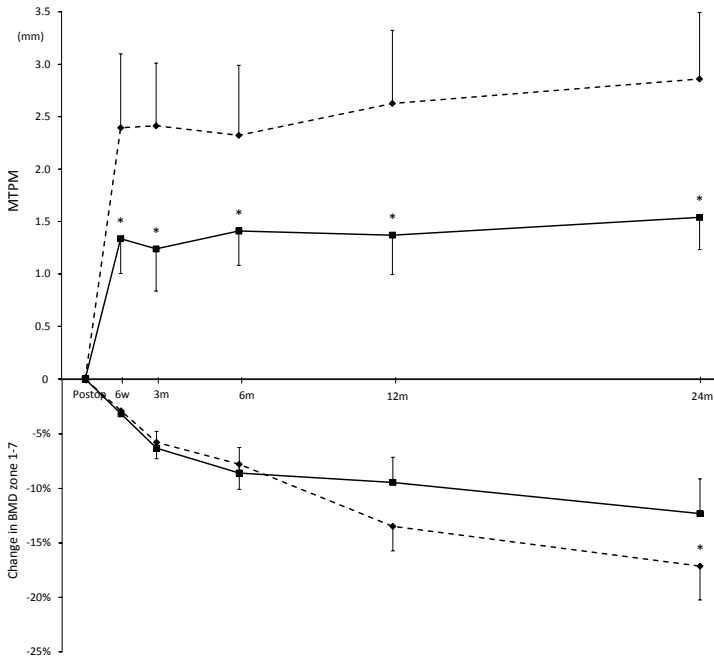


FIGURE 4. The effect of periprosthetic BMD on implant migration and bone loss

The mean (95%CI) MTPM and percentage change in BMD in zone 1-7 for patients with a high (solid line) or low (dashed line) post-operative periprosthetic BMD in zone 1-7.

MTPM was at all follow-ups and bone loss was at 24 months significantly larger in patients with low BMD after controlling for sex, age, BMI and stem size (ANCOVA).

The bone loss, but not the migration, was continuous between 12 and 24 months for patients with low BMD ($p=0.001$).

The difference in migration between the groups was similar for y- and z-translation as well as y-rotation during the study (data not shown). * $p \leq 0.05$ for between-group comparison.

DISCUSSION

In a cognitively intact cohort of elderly patients operated with a new HA-coated stem due to a displaced FNF, all stems were stable after 3 months. The mean subsidence, retroversion and total migration were of the same, or smaller, magnitude than those reported from other RSA studies of clinically successful uncemented stems.^{16,37} We also found a continuous decrease in BMD around the stems up to 2 years after surgery.

The stem was designed to be easy to use by traumatologists or general orthopaedic surgeons and is marketed with a unipolar or bipolar hemi-articulation. In clinical practice, operation with a hemiarthroplasty is still the most common procedure for a displaced femoral neck fracture in elderly patients despite recent evidence that a THA provides better hip function than a hemiarthroplasty.³⁸

In this study, we wanted to exclude the possibility of acetabular erosion and the pain associated with this, and therefore used THA in all patients.

A stepwise clinical introduction of new implants and methods has been advocated.³⁹⁻⁴⁰ This involves pre-clinical testing, small prospective

trials using high precision methods like RSA¹⁷ to assess implant fixation, larger multicenter trials and finally population-based register studies. In this study, we have used 2 methods validated for fixation of implants and bone remodelling, RSA and DXA. To our knowledge, there is no other study using this combination of high-precision methods to evaluate a new hip prosthesis in osteoporotic patients with a femoral neck fracture.

Our results should be interpreted with caution since we have no control group. The study was designed as a pilot study and the next step in evaluating this implant will be to conduct a large randomized controlled trial in which this implant is compared to a cemented stem.

/ Study IV

To be able to access the influence of the injury on clinical outcome scores (HHS, EQ-5D and PNRs), the patients were asked to report their prefracture status when they were included in the study. It is obvious that the patients' ability to correctly record this when waiting for acute surgery may be questioned. It is however impossible to collect this data in a prospective manner and the method is regularly used in trauma studies on hip fracture patients.¹⁻²⁴

Our dislocation rate was high even though we used posterior repair and 32 mm heads in all cases. A high dislocation rate for the posterolateral approach after THA in patients with a femoral neck fracture has previously been reported,⁴¹ and after the completion of the current trial we have subsequently reduced the dislocation rate after arthroplasty for femoral neck fractures by adopting the anterolateral approach.⁴²

WHY USE UNCEMENTED FEMORAL STEMS IN TREATMENT OF FEMORAL NECK FRACTURES?

Uncemented stems in THA are popular implants. In younger patients with osteoarthritis, some perform as well, or better, than cemented stems in the 10-year perspective.⁴³

The rationale for using these devices for displaced femoral neck fractures in osteoporotic elderly patients, often with a stove-pipe femur, is mainly theoretical. During pressurization, ce-

ment and fat embolism are known to occur¹⁰⁻¹¹ and can have an impact on mortality.¹²⁻¹³

In the literature, there is evidence for an improved functional outcome in hip fracture patients when using a cemented implant, mainly when comparing uncemented Austin-Moore and cemented Thompson stems.⁴⁴ However, a new study showed equivalence between a modern HA-coated stem and a modern cemented stem.⁴⁵ Nevertheless, we acknowledge that there are several potential problems when using an uncemented stem in this patient group. The most obvious is the increased risk for periprosthetic fractures. In a coming report from the Swedish Hip Arthroplasty Register, modern HA-coated uncemented stems used for hemiarthroplasty in this elderly population are, compared to modern cemented stems, associated with an increased risk for revision due to femoral fractures (odds ratio 3.8, 95%CI 2.0-7.1).⁴⁶ Similar results can be seen in the Australian National Arthroplasty register where uncemented stems in fracture patients have a significantly higher risk of revision compared to cemented stems.⁴⁷

In our study, we only had 1 fracture; a femoral crack distal to the tip of the prosthesis. We have not had any femoral split fracture or calcar fractures. However, all the surgeons who performed the operations in this trial are experienced hip surgeons, and therefore we cannot be sure that our results can be translated to a standard clinical setting.

The risk for femoral split fractures is perhaps also implant-specific; the most commonly used uncemented stem for femoral neck fractures in Sweden is a press-fit type of stem (Corail®), where the technique is to use increasing sizes of broaches and to impact as much cancellous bone as possible.

So, despite the fact that a HA-coated femoral stem can work quite well in osteoporotic patients, there is still little evidence to recommend it. In fact, the rate of calcar split/periprosthetic fractures in this patient group in published papers range between 0-17% and is typically around 4% (Table 5), a risk that perhaps is unacceptable when compared to the low risk of adverse events during cementation of the stem.

TABLE 3. Percentage change in BMD for the whole periprosthetic region and in zone 1 and 7

	mean	SD	95% CI	n
ZONE 1-7				
3 months	-6.0	6.9	-8.2 - -3.9	46
6 months	-8.2	9.6	-11.1 - -5.3	46
12 months	-11.4	10.9	-14.8 - -8.1	45
24 months	-15.9	13.0	-20.0 - -11.7	44
ZONE 1				
3 months	-9.6	11.8	-13.1 - -6.0	46
6 months	-14.2	15.6	-19.0 - -9.5	46
12 months	-23.3	14.2	-27.6 - 19.0	45
24 months	-30.0	13.1	-34.2 - -25.8	44
ZONE 7				
3 months	-12.5	13.8	-16.7 - -8.3	46
6 months	-17.5	15.3	-22.1 - -12.8	46
12 months	-20.9	16.6	-26.0 - -15.8	45
24 months	-25.7	20.1	-32.1 - -19.3	44

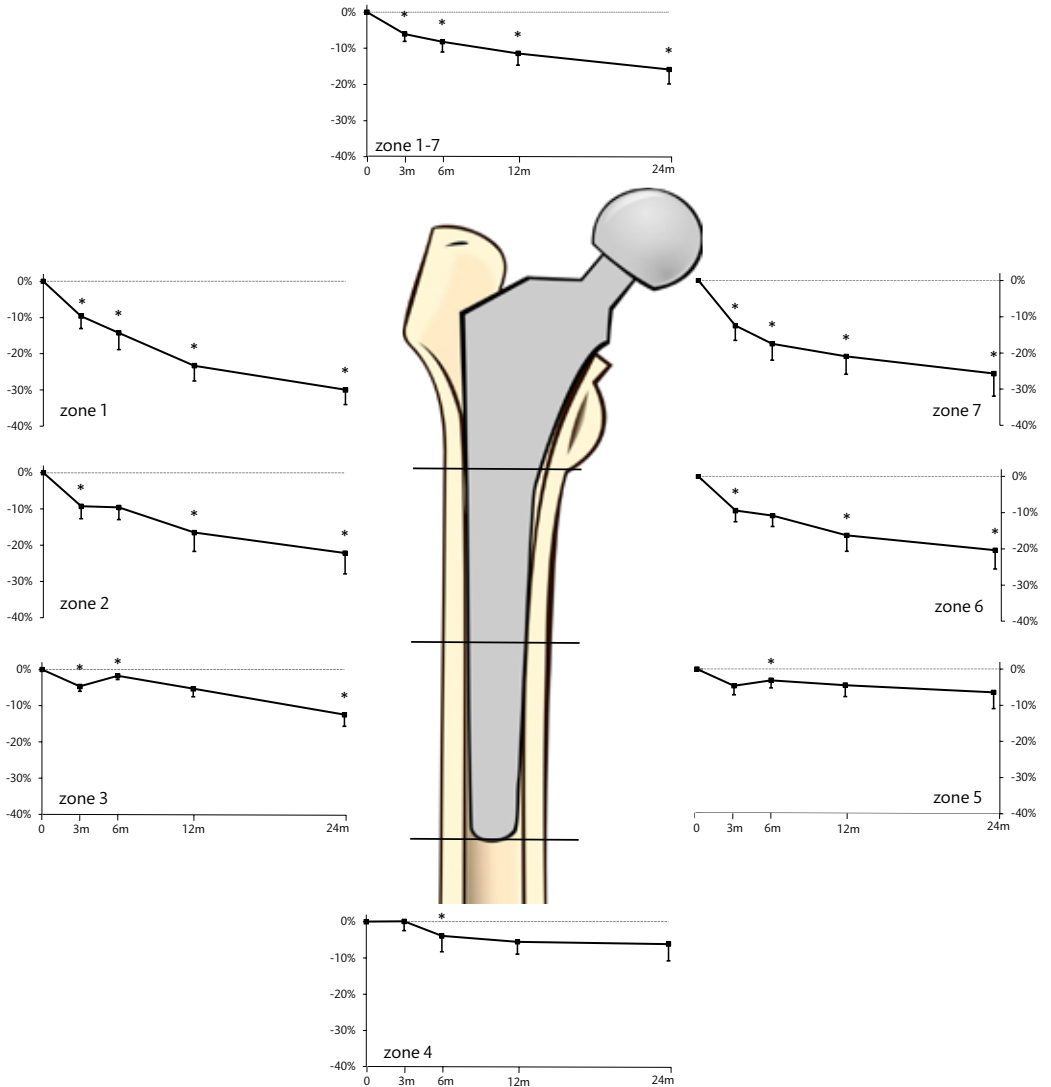


FIGURE 5. Periprosthetic bone remodelling

The mean (95% CI) percentage change in BMD around the stem. * indicates a significant ($p < 0.05$) change in BMD compared to the preceding value.

/ Study IV

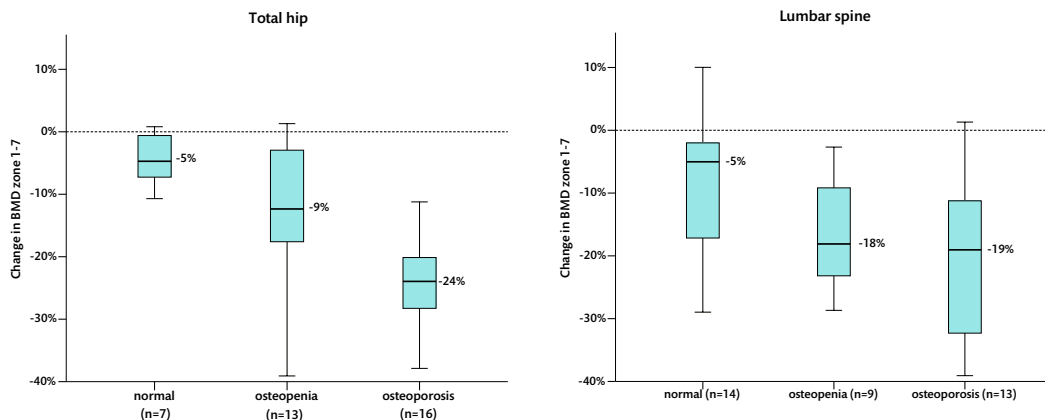


FIGURE 6. The relation between BMD and bone loss

Change in BMD in zone 1-7 shown for 36 patients who were included in a substudy of what effect the BMD of total hip (the non-operated contralateral hip) and lumbar spine had on bone loss after 24 months. Low BMD was significantly related to periprosthetic bone loss after controlling for sex, age, BMI and stem size (total hip $p=0.015$, $p<0.001$ and lumbar spine $p=0.021$, $p=0.027$, ANCOVA).

ASPECTS OF IMPLANT DESIGN

The BFX stem is modified compared to the original Bi-Metric design. It is marketed in uneven sizes only, has a single offset option and has a collar. The first 2 factors are unnecessary limitations of the stem; particularly in respect to males, as more than one offset option is lacking and the high dislocation rate seen in this study can, in part, be attributed to this fact.

We cannot prove that the collar is either an advantage or disadvantage concerning migration. Still, we believe that it makes insertion of the implant safer with regards to the risk of accidentally causing calcar split fractures at final impaction of the stem.

The full HA-coating is probably also advantageous in this patient group since it has strong osteoconductive properties. Despite the fact that we only attained a tight fill in the femoral canal in about one third of the hips, all stems were fixated after 3 months.

MIGRATION AND BONE REMODELLING

In RSA studies, the amount of migration that increases the risk of revision, varies between implants and the method of fixation. For the cemented Lubinus SP I stem, a subsidence exceeding 1.2 mm during the first post-operative

year indicates a 50% risk for revision within 5-7 years.²⁶ In uncemented stems, there is evidence that subsidence should be lower than 1-1.5 mm and retroversion less than 3° during the first year to avoid revision surgery.⁴⁸

HA coating has been advocated for uncemented femoral stems since the HA coating decreases migration. In 1 study on patients with osteoarthritis, the MTPM of the Bi-Metric stem was 1.7 (HA coating) and 3.9 mm (no HA coating) after 12 months.¹⁶ The subsidence (0.2 mm at 12 months) did not differ between the groups but the retroversion was smaller in the HA group.

However, the Bi-Metric stem, with and without HA coating, has excellent long-term results, so the relevance of this small difference in migration can be of negligible clinical relevance.⁴⁹

Migration of stems in elderly patients with a femoral neck fracture has only been investigated once before. Klestil et al.⁵⁰ evaluated the migration of the uncemented Zweimüller stem in 23 patients with a femoral neck fracture using Einzel-Bild-Roentgen-Analyse Femoral Component Analysis⁵¹ and found that active patients had a significant migration, 30% of all stems subsided more than 2 mm. Whether this migration was continuous was not evident from the study.

Even though there was no stem revision or calcar split fracture, they did not recommend the stem for this patient group because of high migration and thereby fear of early loosening.

In the present study, we observed that some patients had a large initial migration, at most 13 mm in MTPM (Table 2). Despite this, all stems stabilized. However, there was a tendency for a continuous migration (z-rotation and MTPM) at 24 months. This could be attributed to the bone resorption that occurred around the stem.

Stress related bone loss around femoral stems has been extensively studied,¹⁹⁻²¹ but so far, only with few reports of clinical consequences.⁵² This bone loss is also related to stem size and, as in our investigation, the initial BMD of the patients.⁵³⁻⁵⁵ Investigation of bone remodelling in this patient group has, to our knowledge, only been done once before involving a new acetabular component.⁵⁶ The bone remodelling around the stem in this study can therefore serve as a reference for other implants in this patient group.

Our patients lost significant amount of bone but, up to 2 years, this had no certain effect on the stability of the implant. However, we cannot rule out a negative effect of this bone loss in a longer perspective.

Recently, electrochemically deposited HA, compared to plasma sprayed HA as in our study, has been found to yield a higher BMD in zone 1 in osteoarthritic patients operated with an uncemented press-fit stem.⁵⁷ A randomized trial would be required to investigate if this bone sparing effect also occurs in patients with a femoral neck fracture.

We found a difference in stem migration between patients with high or low periprosthetic BMD (Figure 4). BMD around the stem was the strongest predictor for migration. Since the subjects who were osteopenic or osteoporotic before the fracture, as estimated by the BMD of the contralateral femur, also had lost more bone around the stem at 2 years, this is a potentially problematic situation as this bone loss could lead to loosening of the stem or predispose to a fracture.

COMPARISON TO OTHER CLINICAL TRIALS

The majority of data on modern uncemented stems (i.e. not Thompson or Austin-Moore types) in patients with a femoral neck fracture is from single cohort studies^{50,58-62} and there are only 2 trials where HA-coated stems were compared to other stem types (Table 5).^{45,63}

Livesley et al.⁶³ compared a HA-coated Furlong hemiarthroplasty (JRI) and the conventional uncemented Austin-Moore stem and found better functional results in the JRI group.

However, the trial was not randomized; patients were allocated to treatment by week of admission. They also compared the HA-coated implant against an implant that we now know is inferior; the revision rate for the Austin-Moore prosthesis is high in the Swedish Hip Arthroplasty Register and its use is no longer recommended.⁶⁴

Figved et al. has performed the only randomized study comparing a modern cemented implant (Spectron) and a HA-coated press-fit implant (Corail).⁴⁵

TABLE 4. Clinical outcome scores with pre-fracture status as baseline for comparison

Outcome score	mean	SD	95% CI	n	p-value
HHS					
Pre-fracture	87	11	84 - 90	50	
6 weeks	73	15	69 - 77	49	<0.001
6 months	83	12	80 - 87	47	0.021
12 months	83	13	79 - 87	46	0.013
24 months	82	13	79 - 86	45	0.006
EQ-5D INDEX					
Pre-fracture	0.71	0.23	0.65 - 0.78	50	
6 weeks	0.58	0.24	0.51 - 0.65	49	0.005
6 months	0.72	0.22	0.65 - 0.78	47	0.988
12 months	0.70	0.29	0.61 - 0.79	46	0.516
24 months	0.63	0.37	0.52 - 0.74	45	0.112
PNRS					
Pre-fracture	0.4	1.3	0 - 0.8	50	
6 weeks	1.6	2.2	1.0 - 2.2	49	0.001
6 months	1.0	1.7	0.5 - 1.4	47	0.048
12 months	1.1	2.2	0.5 - 1.7	46	0.032
24 months	1.0	1.9	0.5 - 1.6	45	0.033

P-values derived from Wilcoxon signed-rank test

/ Study IV

TABLE 5. Studies on modern uncemented stems (not Thompson or Moore type) in femoral neck fractures with the current study for comparison

A	B	C	D	E	F	G	H	I	J	K	L	M	N	O	P
Livesley ⁶³	JRI/Austin-Moore	1993	HA	BHA	RCT	1	hip function	48	81	n.r.	17/0	2/1	n.r.	n.r.	4
Bezuada ⁶²	Taperloc	2004	PP	BHA	PSC	3.5	hip function	168	77	69	0	2	82	n.r.	n.r.
Klestil ⁵⁰	Zweimüller	2006	GB	UHA	PSC	2	migration	46	76	65	0	0	n.r.	AL	0
Klein ⁵⁹	Taperloc, Accolade	2006	PP	THA	RSC	3.8	complications	85	78	74	4	0	82	AL	4
Chandran ⁵⁸	Furlong	2006	HA	BHA	RSC	4	revision	112	78	96	2	5	n.r.	AL	n.r.
Öztürkmen ⁶¹	F40, Helios	2008	FP	BHA	RSC	4.2	n.r.	48	88	76	n.r.	1	84	PL	2
Barnett ⁶⁰	Corail	2009	HA	THA	PSC	1	dislocation	46	72	72	7	0	n.r.	AL	0
Figved ⁴⁵	Corail/Spectron	2009	HA	BHA	RCT	1	hip function	200	83	76	6/3	2/1	79/80	PL	5
Sköldenberg	BFX	2010	HA	THA	PSC	2	migration	50	81	72	2	1	82	PL	14

A Author
B Implants used
C Year published
D Design of stem:
 HA=hydroxyapatite-coated, FP=fully porous-coated, PP=proximally porous-coated, GB=grit-blasted
E Type of articulation: THA=total hip arthroplasty, UHA=unipolar hemiarthroplasty, BHA=bipolar hemiarthroplasty
F Type of study: PSC=prospective single cohort, RSC=retrospective single cohort, RCT=randomized controlled trial
G Follow-up (years)
H Primary outcome variable
I Hips (n)
J Mean age (years)
K Females (%)
L Intra- and post-operative periprosthetic fractures (%)
M Stem revisions (n)
N Harris hip score (mean)
O Surgical approach:
 AL=anterolateral, PL=posterolateral
P Dislocation rate (%)
 n.r.= not reported

Their study showed equivalence between the groups in Harris hip score after 1 year. The patient selection was similar to our study, with a mean age of 83 years, and predominantly female patients. Hip function and health-related quality of life were similar to our results.

They had more intra- and post-operative periprosthetic fractures in the uncemented group, compared to the cemented group; 6% versus 2% after 1 year. They also excluded 4 patients during surgery because they could not achieve primary stability with uncemented fixation of the stem. Despite this, they concluded that both femoral implants in the study could be used with good results in displaced femoral neck fractures.

CONCLUSION

In conclusion, the short-time results from this trial indicate that the new femoral stem can be used for elderly patients with osteoporotic fractures of the femoral neck.

Additional research should, in the context of multicentre randomized trials or population-based register studies, focus on whether uncemented HA-coated femoral stems are superior, equivalent or inferior to cemented stems in the treatment of femoral neck fractures. ◉

REFERENCES

- Rogmark C, Johnell O.** Primary arthroplasty is better than internal fixation of displaced femoral neck fractures: a meta-analysis of 14 randomized studies with 2,289 patients. *Acta Orthop* 2006;77-3:359-67.
- Tidermark J, Ponzer S, Svensson O, Söderqvist A, Törnkvist H.** Internal fixation compared with total hip replacement for displaced femoral neck fractures in the elderly. A randomised, controlled trial. *J Bone Joint Surg Br* 2003;85-3:380-8.
- Neander G.** Displaced femoral neck fractures: studies on osteosynthesis and total hip arthroplasty. Thesis. Stockholm: Karolinska Institutet, 2000.
- Baker RP, Squires B, Gargan MF, Bannister GC.** Total hip arthroplasty and hemiarthroplasty in mobile, independent patients with a displaced intracapsular fracture of the femoral neck. A randomized, controlled trial. *J Bone Joint Surg Am* 2006;88-12:2583-9.
- Parker MJ, Gurusamy K.** Arthroplasties (with and without bone cement) for proximal femoral fractures in adults. *Cochrane Database Syst Rev* 2006;3:CD001706.
- Khan RJ, MacDowell A, Crossman P, Datta A, Jallali N, Arch BN, Keene GS.** Cemented or uncemented hemiarthroplasty for displaced intracapsular femoral neck fractures. *Int Orthop* 2002;26-4:229-32.
- Lo WH, Chen WM, Huang CK, Chen TH, Chiu FY, Chen CM.** Bateman bipolar hemiarthroplasty for displaced intracapsular femoral neck fractures. Uncemented versus cemented. *Clin Orthop Relat Res* 1994-302:75-82.

8. Keisu KS, Orozco F, Sharkey PF, Hozack WJ, Rothman RH, McGuigan FX. Primary cementless total hip arthroplasty in octogenarians. Two to eleven-year follow-up. *J Bone Joint Surg Am* 2001;83-A-3:359-63.
9. Parvizi J, Holiday AD, Ereth MH, Lewallen DG. The Frank Stinchfield Award. Sudden death during primary hip arthroplasty. *Clin Orthop Relat Res* 1999;369:39-48.
10. Christie J, Burnett R, Potts HR, Pell AC. Echocardiography of transatrial embolism during cemented and uncemented hemiarthroplasty of the hip. *J Bone Joint Surg Br* 1994;76-3:409-12.
11. Pitto RP, Koessler M, Kuehle JW. Comparison of fixation of the femoral component without cement and fixation with use of a bone-vacuum cementing technique for the prevention of fat embolism during total hip arthroplasty. A prospective, randomized clinical trial. *J Bone Joint Surg Am* 1999;81-6:831-43.
12. Lennox IA, McLauchlan J. Comparing the mortality and morbidity of cemented and uncemented hemiarthroplasties. *Injury* 1993;24-3:185-6.
13. Parvizi J, Ereth MH, Lewallen DG. Thirty-day mortality following hip arthroplasty for acute fracture. *J Bone Joint Surg Am* 2004;86-A-9:1983-8.
14. Meding JB, Keating EM, Ritter MA, Faris PM, Berend ME. Minimum ten-year follow-up of a straight-stemmed, plasma-sprayed, titanium-alloy, uncemented femoral component in primary total hip arthroplasty. *J Bone Joint Surg Am* 2004;86-A-1:92-7.
15. Bodén H, Salemyr M, Sköldenberg O, Ahl T, Adolphson P. Total hip arthroplasty with an uncemented hydroxyapatite-coated tapered titanium stem: results at a minimum of 10 years' follow-up in 104 hips. *J Orthop Sci* 2006;11-2:175-9.
16. Soballe K, Toksvig-Larsen S, Gelineck J, Fruensgaard S, Hansen ES, Ryd L, Lucht U, Bunger C. Migration of hydroxyapatite coated femoral prostheses. A Roentgen Stereophotogrammetric study. *J Bone Joint Surg Br* 1993;75-5:681-7.
17. Selvik G. Roentgen stereophotogrammetry. A method for the study of the kinematics of the skeletal system. *Acta Orthop Scand Suppl* 1989;232:1-51.
18. Ragnarsson JI, Kärrholm J. Stability of femoral neck fracture. Roentgen stereophotogrammetry of 29 hook-pinned fractures. *Acta Orthop Scand* 1991;62-3:201-7.
19. Bodén HS, Sköldenberg OG, Salemyr MO, Lundberg HJ, Adolphson PY. Continuous bone loss around a tapered uncemented femoral stem: a long-term evaluation with DEXA. *Acta Orthop* 2006;77-6:877-85.
20. Kilgus DJ, Shimaoka EE, Tipton JS, Eberle RW. Dual-energy X-ray absorptiometry measurement of bone mineral density around porous-coated cementless femoral implants. Methods and preliminary results. *J Bone Joint Surg Br* 1993;75-2:279-87.
21. Ang KC, Das De S, Goh JC, Low SL, Bose K. Periprosthetic bone remodelling after cementless total hip replacement. A prospective comparison of two different implant designs. *J Bone Joint Surg Br* 1997;79-4:675-9.
22. Garden R. Low-angle fixation in fractures of the femoral neck. *J Bone Joint Surg Br* 1961;43-B:647-63.
23. Pfeiffer E. A short portable mental status questionnaire for the assessment of organic brain deficit in elderly patients. *J Am Geriatr Soc* 1975;23-10:433-41.
24. Coathup MJ, Blunn GW, Flynn N, Williams C, Thomas NP. A comparison of bone remodelling around hydroxyapatite-coated, porous-coated and grit-blasted hip replacements retrieved at post-mortem. *J Bone Joint Surg Br* 2001;83-1:118-23.
25. Gruen TA, McNeice GM, Amstutz HC. "Modes of failure" of cemented stem-type femoral components: a radiographic analysis of loosening. *Clin Orthop Relat Res* 1979-141:17-27.
26. Kärrholm J, Borssen B, Lowenhielm G, Snorrason F. Does early micromotion of femoral stem prostheses matter? 4-7-year stereoradiographic follow-up of 84 cemented prostheses. *J Bone Joint Surg Br* 1994;76-6:912-7.
27. Valstar ER, Gill R, Ryd L, Flivik G, Borlin N, Kärrholm J. Guidelines for standardization of radiostereometry (RSA) of implants. *Acta Orthop* 2005;76-4:563-72.
28. Hansson U, Toksvig-Larsen S, Ryd L, Aspenberg P. Once-weekly oral medication with alendronate does not prevent migration of knee prostheses: A double-blind randomized RSA study. *Acta Orthop* 2009;80-1:41-5.
29. Söderqvist I, Wedin PA. On condition numbers and algorithms for determining a rigid-body movement. *Bit* 1994-34:424-36.
30. Bodén H, Adolphson P. No adverse effects of early weight bearing after uncemented total hip arthroplasty: a randomized study of 20 patients. *Acta Orthop Scand* 2004;75-1:21-9.
31. Kim YH, Kim VE. Uncemented porous-coated anatomic total hip replacement. Results at six years in a consecutive series. *J Bone Joint Surg Br* 1993;75-1:6-13.
32. Brooker AF, Bowerman JW, Robinson RA, Riley LH, Jr. Ectopic ossification following total hip replacement. Incidence and a method of classification. *J Bone Joint Surg Am* 1973;55-8:1629-32.
33. Harris WH. Traumatic arthritis of the hip after dislocation and acetabular fractures: treatment by mold arthroplasty. An end-result study using a new method of result evaluation. *J Bone Joint Surg Am* 1969;51-4:737-55.
34. Frihagen F, Grotle M, Madsen JE, Wyller TB, Mowinckel B, Nordsetten L. Outcome after femoral neck fractures: a comparison of Harris Hip Score, Eq-5d and Barthel Index. *Injury* 2008;39-10:1147-56.
35. Rabin R, de Charro F. EQ-5D: a measure of health status from the EuroQol Group. *Ann Med* 2001;33-5:337-43.
36. Downie WW, Leatham PA, Rhind VM, Wright V, Branco JA, Anderson JA. Studies with pain rating scales. *Ann Rheum Dis* 1978;37-4:378-81.
37. Campbell D, Mercer G, Nilsson KG, Wells V, Field JR, Callary SA. Early migration characteristics of a hydroxyapatite-coated femoral stem: an RSA study. *Int Orthop* 2009.
38. Blomfeldt R, Törnkvist H, Eriksson K, Söderqvist A, Ponzer S, Tide- rmark J. A randomised controlled trial comparing bipolar hemiarthroplasty with total hip replacement for displaced intracapsular fractures of the femoral neck in elderly patients. *J Bone Joint Surg Br* 2007;89-2:160-5.
39. Malchau H. On the importance of stepwise introduction of new hip implant technology: Assessment of total hip replacement using clinical evaluation, radiostereometry, digitized radiography and a national hip

/ Study IV

- registry. Göteborg, Sweden: Göteborg University, 1995.
40. Malchau H. Introducing new technology: a stepwise algorithm. *Spine* 2000;25-3:285.
 41. Enocson A, Hedbeck CJ, Tidermark J, Pettersson H, Ponzer S, Lapidus LJ. Dislocation of total hip replacement in patients with fractures of the femoral neck. *Acta Orthop* 2009;80-2:184-9.
 42. Sköldenberg O, Ekman A, Salemyr M, Bodén H. Reduced dislocation rate after hip arthroplasty for femoral neck fractures when changing from posterolateral to anterolateral approach. *Acta Orthop* 2010;81-5:583-7.
 43. Eskelinen A, Remes V, Helenius I, Pulkkinen P, Nevalainen J, Paavolainen P. Total hip arthroplasty for primary osteoarthritis in younger patients in the Finnish arthroplasty register. 4,661 primary replacements followed for 0-22 years. *Acta Orthop* 2005;76-1:28-41.
 44. Parker MJ, Gurusamy KS, Azegami S. Arthroplasties (with and without bone cement) for proximal femoral fractures in adults. *Cochrane Database Syst Rev* 2010;6:CD001706.
 45. Figved W, Opland V, Frihagen E, Jervidal T, Madsen JE, Nordsetten L. Cemented versus uncemented hemiarthroplasty for displaced femoral neck fractures. *Clin Orthop Relat Res* 2009;467-9:2426-35.
 46. Garellick G, Kärrholm J, Rogmark C, Herberts P. <http://www.jru.orthop.gu.se/>.
 47. Graves S, Davidson D, de Steiger R. www.dmac.adelaide.edu.au/aoan-jrr/.
 48. Kärrholm J, Herberts P, Hultmark P, Malchau H, Nivbrant B, Thanner J. Radiostereometry of hip prostheses. Review of methodology and clinical results. *Clin Orthop Relat Res* 1997-344:94-110.
 49. Paulsen A, Pedersen AB, Johnsen SP, Riis A, Lucht U, Overgaard S. Effect of hydroxyapatite coating on risk of revision after primary total hip arthroplasty in younger patients: findings from the Danish Hip Arthroplasty Registry. *Acta Orthop* 2007;78-5:622-8.
 50. Klestil T, Biedermann R, Kruger A, Gfoller P, Schmoelz W, Rangger C, Krismer M, Blauth M. Cementless hemiarthroplasty in femoral neck fractures: evaluation of clinical results and measurement of migration by EBRA-FCA. *Arch Orthop Trauma Surg* 2006;126-6:380-6.
 51. Biedermann R, Krismer M, Stockl B, Mayrhofer P, Ornstein E, Franzen H. Accuracy of EBRA-FCA in the measurement of migration of femoral components of total hip replacement. Einzel-Bild-Röntgen-Analyse-femoral component analysis. *J Bone Joint Surg Br* 1999;81-2:266-72.
 52. Hsieh PH, Chang YH, Lee PC, Shih CH. Periprosthetic fractures of the greater trochanter through osteolytic cysts with uncemented MicroStructured Omnifit prosthesis: retrospective analyses of 23 fractures in 887 hips after 5-14 years. *Acta Orthop* 2005;76-4:538-43.
 53. Engh CA, Bobyn JD. The influence of stem size and extent of porous coating on femoral bone resorption after primary cementless hip arthroplasty. *Clin Orthop Relat Res* 1988-231:7-28.
 54. Sköldenberg OG, Bodén HS, Salemyr MO, Ahl TE, Adolphson PY. Periprosthetic proximal bone loss after uncemented hip arthroplasty is related to stem size: DXA measurements in 138 patients followed for 2-7 years. *Acta Orthop* 2006;77-3:386-92.
 55. Rahmy AI, Gosens T, Blake GM, Tonino A, Fogelman I. Periprosthetic bone remodelling of two types of uncemented femoral implant with proximal hydroxyapatite coating: a 3-year follow-up study addressing the influence of prosthesis design and preoperative bone density on periprosthetic bone loss. *Osteoporos Int* 2004;15-4:281-9.
 56. Field RE, Cronin MD, Singh PJ, Burtenshaw C, Rushton N. Bone remodeling around the Cambridge cup: a DEXA study of 50 hips over 2 years. *Acta Orthop* 2006;77-5:726-32.
 57. Bøe B, Heier T, Snorrason L, Nordsetten L. A clinical study comparing electrochemically deposited hydroxyapatite and plasma sprayed hydroxyapatite on titanium stems. 2 years follow-up with RSA and DXA in 55 hips. A prospective randomized study. *Acta Orthop* (Epub) 2010.
 58. Chandran P, Azzabi M, Burton DJ, Andrews M, Bradley JG. Mid term results of Furlong LOL uncemented hip hemiarthroplasty for fractures of the femoral neck. *Acta Orthop Belg* 2006;72-4:428-33.
 59. Klein GR, Parvizi J, Vegari DN, Rothman RH, Purtill JJ. Total hip arthroplasty for acute femoral neck fractures using a cementless tapered femoral stem. *J Arthroplasty* 2006;21-8:1134-40.
 60. Barnett AJ, Burston BJ, Atwal N, Gillespie G, Omari AM, Squires B. Large diameter femoral head uncemented total hip replacement to treat fractured neck of femur. *Injury* 2009;40-7:752-5.
 61. Öztürkmen Y, Karamehmetoğlu M, Caniklioğlu M, Ince Y, Azboy I. Cementless hemiarthroplasty for femoral neck fractures in elderly patients. *Indian J Orthop* 2008;42-1:56-60.
 62. Bezwada HP, Shah AR, Harding SH, Baker J, Johanson NA, Mont MA. Cementless bipolar hemiarthroplasty for displaced femoral neck fractures in the elderly. *J Arthroplasty* 2004;19-7 Suppl 2:73-7.
 63. Livesley PJ, Srivastava VM, Needoff M, Prince HG, Moulton AM. Use of a hydroxyapatite-coated hemiarthroplasty in the management of subcapital fractures of the femur. *Injury* 1993;24-4:236-40.
 64. Garellick G, Kärrholm J, Rogmark C, Herberts P. Swedish Hip Arthroplasty Register Annual Report 2008. 2009.



**Karolinska
Institutet**

200
1810 – 2010 *Years*