

From the Divisions of Cariology and Endodontology,
Department of Dental Medicine
Karolinska Institutet, Sweden

OPTICAL BASED TECHNOLOGIES FOR DETECTION OF DENTAL CARIES

Lena Karlsson



**Karolinska
Institutet**

Doctoral Thesis
Huddinge 2009

External Examiner

Professor Lars Gahnberg, University of Gothenburg
Folktandvården Västra Götalandsregionen, Institute of Odontology
Göteborg, Sweden

Examining committee

Professor Jan van Dijken, Umeå University
Dental Hygienist Education, Department of Odontology
Umeå, Sweden

Associate Professor Gunilla Johnson, Karolinska Institutet
The Department of Learning, Informatics, Management and Ethics
Stockholm, Sweden

Professor Jan Olsson, University of Gothenburg
Department of Prosthodontics, Institute of Odontology
Göteborg, Sweden

Supervisors

DDS, PhD Sofia Tranæus, Karolinska Institutet
Divisions of Cariology and Endodontology, Department of Dental Medicine
Huddinge, Sweden

Professor Walter Margulis, Acreo and the Royal Institute of Technology
Stockholm, Sweden

Professor Jan Ekstrand, Karolinska Institutet
Divisions of Cariology and Endodontology, Department of Dental Medicine
Huddinge, Sweden

Cover:

Fluorescence mouth mirror

Photo kindly provided by Lars Frithiof, Svenska Tandläkare-Sällskapets samlingar

All published papers are reproduced with permission from the respective publisher

Published by Karolinska Institutet. Printed by Larserics, Landsvägen 65, Sundbyberg

© Lena Karlsson, 2009
ISBN 978-91-7409-565-4

DEN HÖGSTA VISHETEN ÄR ATT MAN INGET VET

SOKRATES

ABSTRACT

Background: A conservative, non-invasive or minimally invasive approach to clinical management of dental caries requires diagnostic techniques capable of detecting and quantifying lesions at an early stage, when progression can be arrested or reversed. Objective evidence of initiation of the disease can be detected in the form of distinct changes in the optical properties of the affected tooth structure. Caries detection methods based on changes in a specific optical property are collectively referred to as optically based methods. The present thesis evaluated the feasibility of three such technologies for quantitative or semi-quantitative assessment of caries lesions. Two of the techniques are well-established: quantitative light-induced fluorescence (QLF), which is used primarily in caries research and laser-induced fluorescence (LF), a commercially available method used in clinical dental practice. The third technique, based on near-infrared transillumination (TI), is in the developmental stages. **Aims:** The general aims of this thesis were twofold: firstly, to evaluate the LF and QLF methods, with special reference to validity and reliability in detecting lesions; and secondly, to implement a procedure to characterise an imaging technique based on TI of dental enamel with near-infrared light (NIR). **Material and Methods:** In **Study I** (*in vivo*) the LF method was validated for occlusal dentinal caries detection by comparing LF readings with the actual lesion depth, determined by opening the fissures. LF readings obtained on smooth surface white spot lesions were compared with corresponding measurements by QLF, which served as a reference method. Operator agreement was also tested. In **Study II** (*in vivo*) QLF was applied to monitor a preventive intervention: caries active adolescents were instructed to brush weekly with amine fluoride gel to test whether this treatment could enhance the remineralisation of early caries lesions on smooth surfaces. In **Study III** (*in vitro*) LF readings and colour and surface texture of root caries lesions were investigated in relation to histopathological lesion depths. The influence of discolouration and surface texture on LF readings, as well as the operator agreement, was investigated. In **Study IV** (*in vitro*) a procedure to characterise a TI imaging system, using wavelengths in the NIR spectrum, was developed for detection of early caries lesions. The performance of the system with reference to high resolution and low noise of captured images was characterised and quantified by the modulation transfer function. The potential for this imaging technique to detect and indicate the relative position of a lesion on the approximal surface was also explored. **Results:** LF readings of occlusal dentinal caries (**Study I**) showed very poor correlation with clinically

assessed lesion depth ($r < 0.15$). With respect to root caries lesions (**Study III**), LF readings showed extremely low correlation with histopathological lesion depth ($r < 0.01$). The agreement between LF readings and corresponding measurements by QLF (**Study I**) was satisfactory. For root caries, discolouration and surface texture denoted as hard were associated with higher LF values (**Study III**): the study disclosed moderate correlation between colour and histological depth, as well as between surface texture and histological depth. Operator agreements (**Study I, III**) were good to excellent. Monitoring by QLF disclosed no enhancement of remineralisation of white spot lesions by additional weekly brushing with amine fluoride gel (**Study II**). **Study IV** demonstrated that the TI system was able to detect features as small as $250 \mu\text{m}$ with 30 % modulation in captured images. The location of a caries lesion on the approximal surface was demonstrated in thin tooth sections. **Conclusions:** In their present form, neither of the two established optical methods evaluated in this thesis can be regarded as ideal for clinical application. LF readings showed very poor correlation with lesion depth, both on occlusal and root surfaces. The QLF method was appropriate for monitoring small changes in white spot lesions. When illuminated through dental enamel, the novel TI imaging system disclosed extremely small features. Reduction of modulation indicated the relative position of a simulated approximal caries lesion in thin tooth sections. These promising results indicate that the TI method warrants further investigation and development as an aid to traditional caries detection and assessment methods.

ABSTRAKT

Kariesprocessen vanligtvis långsamma förlopp ger oss möjlighet att bevara tandsubstansen och behandla kariesskadan icke-invasivt, dvs. utan att borra i tanden. Tidigt insatta åtgärder kan avstanna och vända kariesprogressionen. Det är därför mycket viktigt att så långt det går undvika invasiv fyllningsterapi. Bra information om det enskilda kariesangreppet (i form av objektiv, tillförlitlig och kvantitativ data) möjliggör tidigt insatta preventiva åtgärder och att utfallet av dessa behandlingar sedan kan följas över tiden. Inom klinisk kariesforskning skulle t ex studier av olika fluorinnehåll i tandkrämer kunna genomföras med färre antal försökspersoner och kortare försöksperioder.

Det är svårt att säkert veta om det finns ett dentinkariesangrepp under intakt emalj i en ocklusalyta (tuggytan på de bakre tänderna). Att sen avgöra hur djupt angreppet är kan vara ännu svårare. Visuell inspektion, användning av sond, samt tolkning av röntgenbilder är inte tillräckligt känsliga metoder för att på ett säkert sätt mäta små kariesangrepp. De har låg sensitivitet (förmågan att identifiera kariesskadade ytor rätt), ibland under 50 %, d v s en ren gissning kan bli lika rätt. De senaste åren har flera tekniskt avancerade metoder utvecklats för att möta behovet. Alla har dock både möjligheter och begränsningar.

Det övergripande syftet med den här avhandlingen var att utvärdera två optiska metoder: laserinducerad fluorescens (LF) och kvantitativ ljusinducerad fluorescens (QLF). Dessa prövades på kron- och rotytor, i emalj och i dentin. En ny genomlysningsmetod med nära infrarött ljus (NIR) teknik utvecklades för att upptäcka kariesangrepp i emalj.

I laboratoriestudier har LF-metoden visat hög diagnostisk precision och hög reproducerbarhet för att upptäcka och mäta djupet på kariesangrepp. I **Studie I** undersöktes om detta även gällde mätning av ockluskaries på patienter. Resultaten visade en mycket låg överensstämmelse mellan kariesangreppens djup och LF-mätningarna. Metoden fungerade dock bättre för att avgöra om det fanns ett dentinkariesangrepp eller ej under den intakta emaljytan, dvs. den gav god kvalitativ information.

Studie II var en randomiserad, kontrollerad klinisk studie (RCT). Under ett år fick kariesaktiva ungdomar borsta dagligen med aminfluorid tandkräm. Testgruppen fick borsta ytterligare en gång i veckan med aminfluoridgel och placebogruppen med gel utan verksamt substans. Effekten på kariesskadad emalj, mätt med QLF-metoden var tredje månad, visade ingen statistisk säkerställd skillnad mellan test- och placebogruppen. Med QLF-

metoden kunde små förändringar i kariesangreppens djup mätas över tid. Metoden bedöms därför vara lämplig för liknade studiedesign.

I **Studie III** prövades LF-metoden i ett laboratorieförsök för mätning av kariesangrepp på rotytor. Överensstämmelsen mellan LF-mätningarna, bedömd ytstruktur och missfärgning av kariesangreppen samt kariesangreppens histologiska djup testades. Bedömning av om ytstruktur och missfärgning av kariesangreppet påverkade LF-mätningarna gjordes. Resultatet visade att det inte fanns någon statistiskt signifikant överensstämmelse mellan LF-mätningarna och det histologiska djupet hos kariesangreppet. LF-mätningar överensstämde dock med grad av missfärgning och hård ytstruktur. Även mellan missfärgning, ytstruktur och lesionsdjup fanns statistiskt signifikant överensstämmelse. Baserat på resultat från denna studie rekommenderas inte LF-instrumentet för mätning av karies på rotytor.

I **Studie I** och **Studie III** testades även överensstämmelsen av mellan olika operatörer vid användning av LF-instrumentet. Reliabiliteten bedömdes som god till utmärkt. I **Studie III** fungerade LF-instrumentet utmärkt på gruppnivå, men med stora mätvärdeskillnader mellan två upprepade mätningar på individnivå.

I det fjärde delarbetet, **Studie IV**, utvecklades ett tillvägagångssätt för att kvantifiera och karaktärisera ett genomlysningssystem (TI) av tandemalj, samt en metod för bildtagning av emaljbitar av olika tjocklek. TI-systemets förmåga att återge små detaljer med hög kontrast testades med två våglängder i det nära infraröda spektrumet, ett våglängdsområde utan hälsofarlig strålning. Resultatet visade att den längre våglängden (1.4 μm) kunde lysa igenom en 6 mm tjock tandskiva med god bildkvalitet. Detaljer ner till 250 μm storlek kunde återges med god skärpa. Metoden gav även information om var på approximalytan kariesangreppet var placerat, dvs. ytan mellan tänderna som vanligtvis endast kan ses med hjälp av röntgenbild. Då kariesangreppets läge var närmast kameran kunde angreppet ses i samtliga tjocklekar av tandpreparaten.

Den här avhandlingen handlar om två metoder avsedda för att mäta exakt hur djupa kariesangrepp är. Dessa testades på patient och på extraherade tänder. En ny metod för genomlysning av emalj teknik utvecklades. Resultaten visar att LF metoden kan användas som hjälpmedel för att upptäcka kariesangrepp på ocklusal- och buccal(kind)ytor men inte för mätning av karies på rotyta. QLF-metoden bedöms som lämplig att följa små förändringar i emaljkariesangrepp över tid. Vid genomlysning av emalj med TI metoden kan ytterst små detaljer avbildas med god bildåtergivning.

LIST OF PUBLICATIONS

This thesis is based on the following papers, which will be referred to in the text by their Roman numerals:

- I. Tranæus S, Lindgren L-E, KARLSSON L, Angmar-Månsson B.
***In vivo* validity and reliability of infrared fluorescence measurements for caries detection and quantification.** *Swed Dent J.* 2004;28:173-82.
- II. KARLSSON L, Lindgren L-E, Trollsås K, Angmar-Månsson B, Tranæus S.
Effect of supplementary amine fluoride gel in caries-active adolescents. A clinical QLF study. *Acta Odontol Scand.* 2007;65:1-8.
- III. KARLSSON L, Johansson E, Tranæus S.
Validity of infrared fluorescence measurements on sound and carious root surfaces *in vitro*. *Caries Research, under revision*
- IV. KARLSSON L, Araújo A, Kyotoku B, Tranæus S, Gomes ASL, Margulis W
Near-infrared transillumination of tooth - Measurement of a system performance. *Journal of Biomedical Optics, submitted manuscript*

Lena Karlsson
Divisions of Cariology and Endodontology
Department of Dental Medicine
P.O. Box 4064
S-141 04 Huddinge
Sweden

lena.karlsson@ki.se

CONTENTS

Introduction	1
Physical principles underlying optical caries detection methods.....	5
Scattering.....	7
Absorption with fluorescence.....	7
Transillumination.....	8
Optical caries detection methods in this thesis.....	9
Laser-induced fluorescence.....	9
Quantitative light-induced fluorescence.....	10
Transillumination with near-infrared light.....	11
Aims	13
Material and Methods	14
Ethical considerations.....	14
Paper I.....	14
Paper II.....	17
Paper III.....	18
Paper IV.....	19
Statistical analyses.....	22
Results	23
Validity of LF for detection of coronal and root caries lesions (Papers I and III).....	23
Reliability of the LF method (Papers I and III).....	24
Application of QLF to monitor changes in white spot lesions (Paper II).....	24
Characterisation of TI system performance (Paper IV).....	26
Discussion	27
Conclusion.....	36
Tillkännagivanden	37
References	40

LIST OF ABBREVIATIONS

QLF™	Quantitative Light-induced Fluorescence
LF	Laser Fluorescence
TI	Transillumination
DIFOTI	Digital Imaging Fiber-Optic Transillumination
UV	UltraViolet
NIR	Near-InfraRed
IR	InfraRed
MTF	Modulation Transfer Function
Nm	Nanometer
DEJ	Dentino-enamel Junction
GBI	Gingival Bleeding Index
PTC	Professional Tooth Cleaning
ΔF	Average change in fluorescence, in %
LP/mm	Line pairs per millimetre
CCD	Charge Couple Device
<i>In vitro</i>	Study conducted in laboratory
<i>In vivo</i>	Clinical study

INTRODUCTION

Dental caries is one of the most prevalent chronic diseases of humans worldwide. When different stages of the disease are taken into account, from the initial to the clinically manifest lesion, very few individuals are truly unaffected. In most industrialised countries 60-90% of school-aged children are affected. The prevalence among adults is even higher and in most countries the disease affects nearly 100% of the population [Petersen et al., 2005].

During the last thirty years, however, major changes have occurred in the pattern of the disease. Progression of enamel caries is now slower [Mejàre et al., 1999; Mejåre et al., 1998; Mejåre et al., 2004], allowing time for preventive intervention before irreversible destruction of tooth substance occurs. During the early stages of the disease the process is reversible and can be arrested: non-invasive intervention can convert a lesion from an active to an inactive state [Featherstone, 2008; Fejerskov and Kidd, 2008]. Appropriate diagnostic techniques are necessary to support such decisions about management of the individual lesion [Featherstone, 1999]. The clinician needs to be able to monitor the outcome of non-invasive measures and in cases where there is evidence of lesion progression, make a timely decision to intervene, using minimally invasive techniques and restoring damaged tooth structure without weakening the tooth.

Failure to detect early caries activity may leave the clinician with no option but restorative treatment, rather than the application of non-invasive measures to reverse or arrest the lesion. Applying strategies to control, arrest or reverse the disease process can reduce the economic burden, pain and suffering of placing and replacing restorations [Choo-Smith et al., 2008].

This modern, conservative approach to clinical management of dental caries, which has been evolving during the past twenty years, has necessitated a critical appraisal of methods used today for clinical detection of carious lesions.

Complementing traditional diagnostic methods with advanced, more sensitive methods will improve caries diagnostic routines and hence the dental care and treatment of patients. The application of such complementary methods should offer objective information about the presence and severity of a lesion, to complement the clinician's subjective interpretation, providing evidence-based clinical caries diagnosis. In this context, there is also a place for more sensitive caries detection methods in clinical caries research. Clinical trials in which lesions are monitored in

thousands of subjects over several years are no longer commercially viable. A quantitative method capable of measuring small changes would allow trials of much shorter duration and fewer subjects [Angmar-Månsson, 2001; Pretty, 2006].

Conventional examination for caries detection is based primarily on subjective interpretation of visual examination and tactile sensation, aided by radiographs. The clinician makes a dichotomous decision (absence or presence of a lesion) based on subjective interpretation of colour, surface texture and location, using rather crude instruments such as a dental explorer and bitewing radiographs [Selwitz et al., 2007].

Studies based on these methods often show low sensitivity and high specificity, *i.e.* a large number of lesions may be missed [Bader et al., 2002; Hopcraft and Morgan, 2005; Ridell et al., 2008; The Swedish Council on Technology Assessment in Health Care, 2008; Yang and Dutra, 2005]. Sensitivity and specificity are widely used measures to describe and quantify the diagnostic ability of a test [Altman and Bland, 1994]. In the context of caries research, sensitivity is a measure of the method's ability to correctly identify all surfaces damaged by caries, and specificity the measure of correctly identified all sound surfaces. Sensitivity and specificity are expressed as values between 0 and 1 (100%), values closer to 1 indicating a high quality result. For caries diagnostic methods, values should be at least 0.75 for sensitivity and over 0.85 for specificity [The Swedish Council on Technology Assessment in Health Care, 2007].

Diagnostic techniques are also evaluated in terms of validity and reliability. To determine validity, the outcome as measured by the method is compared with a reference standard, a 'true' situation. Reliability expresses the consistency of a set of measurements performed with the method. High validity is considered to confirm the absence of systematic errors and high reliability the absence of random errors of the method. The generalisability of a diagnostic technique is also described in terms of external and internal validity. The external validity reflects the extent to which the results of a study can be extrapolated to other subjects or settings, whereas internal validity reflects the degree to which conclusions about causes or relationships are likely to be true, in view of the measures used, the research setting, and the overall study design. Good experimental design will filter out the most confounding variables, which could compromise the internal validity of an experiment.

Table 1 is a modified version by Pretty and Maupome [2004] and presents a summary of two extensive systematic reviews of conventional caries detection methods and their performance in terms of sensitivity and specificity [Bader et al., 2001, 2002]. Another recently published comprehensive review [The Swedish Council on Technology Assessment in Health Care, 2007] stated that the evaluations of diagnostic performance are based on limited numbers of studies of questionable internal and external validity attributable to incomplete descriptions of selection and diagnostic criteria and observer reliability. The quality of published studies is further compromised by the use of small numbers of observers, non-representative teeth, samples with high lesion prevalence, a variety of reference standards of unknown reliability and variations in statistical analysis of the reported results.

Method, surface and extent	No. of studies	No. of examiners		Prevalence of lesions (%)		Sensitivity (%)		Specificity (%)	
		Mean	Median	Mean	Median	Mean	Median	Mean	Median
Visual									
<i>Occlusal surfaces</i>									
Cavitated	4	1	1	56	51	63	51	89	89
Dentinal	10	9	4	50	44	37	25	87	91
Enamel	2	2	2	21	21	66	66	69	69
Any	4	12	7	78	75	59	62	72	74
Visual-Tactile									
<i>Occlusal surfaces</i>									
Dentinal	2	12	6	29	29	19	19	97	97
Any	2	4	4	40	40	39	39	94	94
<i>Proximal surfaces</i>									
Cavitated	3	3	3	5	6	52	32	98	99
Radiographic									
<i>Occlusal surfaces</i>									
Dentinal	26	4	3	54	55	53	54	83	85
Enamel	4	2	2	18	18	30	28	76	76
Any	7	5	4	82	84	39	27	91	95
<i>Proximal surfaces</i>									
Cavitated	7	3	3	13	9	66	66	95	97
Dentinal	8	39	5	27	27	38	40	95	96
Enamel	2	10	10	25	25	41	41	78	78
Any	11	6	3	62	66	50	49	87	88

Table 1. Effectiveness of conventional methods for detection of caries

Summary based on reviews by Bader et al., [2001, 2002] modified by Pretty and Maupomé [2004].

It is apparent that conventional methods for the detection of dental caries do not fulfil the criteria for an ideal caries detection method. These methods rely on subjective interpretation and are insensitive to early caries detection. It is widely recognised that

the current methods cannot detect caries lesions until a relatively advanced stage, involving as much as one-third or more of the thickness of enamel [Stookey and Gonzalez-Cabezas, 2001].

The shortcomings of conventional caries detection methods and the need for supplementary methods have long been acknowledged. The series of published proceedings from the three “Indiana Conferences on Early Detection of Dental Caries” contains a wealth of detail of work in this area [Stookey, 1996; Stookey, 2000; Stookey, 2004a]. Over the past twenty years there has been intensive research into more sophisticated methods for early detection of dental caries [Angmar-Månsson et al., 1996; Angmar-Månsson and ten Bosch, 1993; Bader and Shugars, 2004, 2006; Bader et al., 2001, 2002; Choo-Smith et al., 2008; Hall and Girkin, 2004; Karlsson and Tranæus, 2008; Lussi et al., 2004; Neuhaus et al., 2009; Pereira et al., 2009; Pitts, 1997; Pretty, 2006; Pretty and Maupome, 2004; Selwitz et al., 2007; Stookey, 2004b; Tranæus et al., 2005; Young, 2002; Zandona and Zero, 2006].

An initial effect of the disease process, increased porosity, results in a distinct change in the optical properties of the affected dental tissue, providing objective evidence of a caries-induced change. Caries detection methods based on changes in a specific optical property are referred to in the literature as optically based methods, optical methods or dental tissue optics. The optical methods for detection and quantification of dental caries investigated in this thesis are based on the measurement of a physical signal, derived from the interaction of light with dental hard tissue. The following section presents a brief description of the principles underlying these methods.

PHYSICAL PRINCIPLES UNDERLYING OPTICAL CARIES DETECTION

METHODS

Optical caries detection methods are based on observation of the interaction of energy which is applied *to* the tooth, or the observation of energy which is emitted *from* the tooth [Hall and Girkin, 2004]. Such energy is in the form of a wave in the electromagnetic spectrum, **Fig. 1**. The caries detection methods described in this thesis use light in the visible and near-infrared range (NIR).

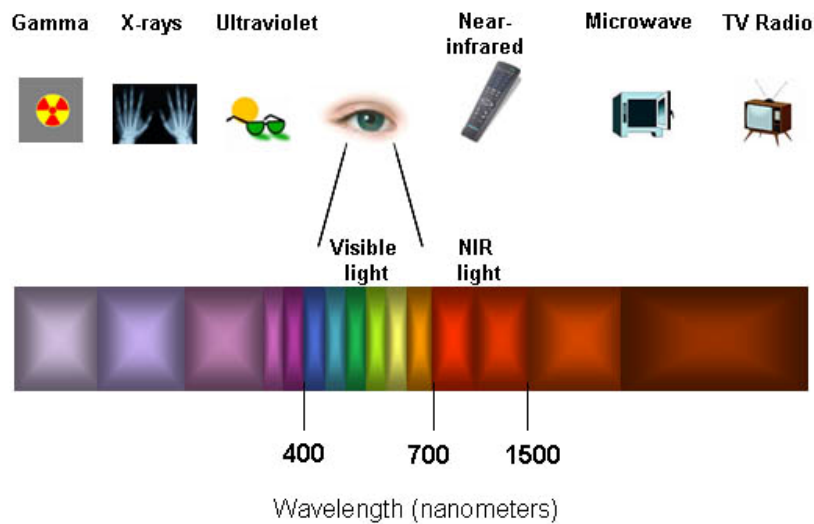


Illustration by Lena Karlsson

Figure 1. The electromagnetic spectrum

Wavelengths of interest in this thesis are the visible light spectrum from 400 nm to 700 nm and the range of near-infrared light from 750 nm to 1500 nm.

In its simplest form, caries can be described as a process resulting in structural changes to the dental hard tissue. The diffusion of calcium, phosphate and carbonate out of the tooth, the demineralisation process, will result in loss of mineral content. The resultant area of demineralised tooth substance is filled mainly by bacteria and water. The porosity of this area is greater than that of the surrounding structure. Increased scattering of incident light due to this structural change appears to the human eye as a so-called white spot. Hence, the caries process leads to distinct optical

changes that can be measured and quantified with advanced detection methods based on light that shines on and interacts with the tooth, **Fig. 2**.

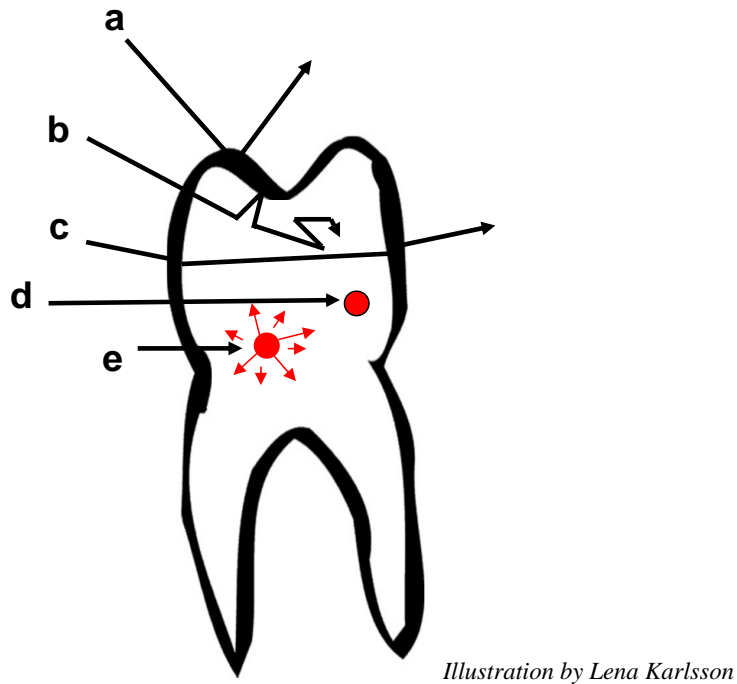


Figure 2. Light interactions with a tooth

How waves can interact with the dental hard tissue; a) reflection, the wave rebounds; b) scattering, the incident wave enters the tooth and changes direction. The photons then leave the tooth either as backscattering, where the photons leave through the surface by which they entered, or through another surface (scattering with diffuse transmission); c) transmission, the wave is illuminated through the tooth and refracts on the surfaces; d) absorption with heat production; and e) absorption with fluorescence. Most interactions of waves are a combination of these processes.

Scattering

Scattering is the process in which the direction of a photon is changed without loss of energy. The incident light is forced to deviate from a straight path when it interacts with small particles or objects in the medium through which the light passes. In physical terms scattering is regarded as a material property. A glass of milk is seen as white because incident light on the milk is scattered in all directions, leaving the milk without absorption [Zijp, 2001]. Snow appears white because light incident in the snow is scattered in all directions by the small ice crystals. Light of all visible wavelengths exit snow without suffering absorption. Scattering is highly wavelength sensitive, shorter wavelengths scattering much more than longer ones [Hall and Girkin, 2004]. Therefore, caries detection methods employing wavelengths in the visible range of the electromagnetic spectra (400 nm to 700 nm) are highly limited by scattering. An early enamel lesion looks whiter than the surrounding healthy enamel because of strong scattering of light within the lesion [Angmar-Månsson and ten Bosch, 1993]. Methods measuring lesion severity are based on differences in scattering between sound and carious enamel.

Absorption with fluorescence

Absorption is the process in which photons are stopped by an object and the wave energy is taken in by the object. The energy lost is mostly converted into heat or into another wave which has less energy and hence longer wavelengths. In physical terms absorption is also regarded as a material property. The previous analogy of the glass of milk appearing white can be extended to a cup of tea [Zijp, 2001]; the tea is seen as transparent because it does not scatter light, but it looks brown because much of the light is absorbed by the tea. Likewise, mud and pollution in white snow can be seen as dark spots because certain wavelengths are absorbed by these polluted spots. Absorption of light in tissue is strongly dependent on the wavelength. Water is an example of a strong absorber in the infrared (IR) range. After absorption the energy can be released by emission of light at a longer wavelength, through the process of fluorescence. Fluorescence occurs as a result of the interaction of the wavelength illuminating the object and the molecule in this object. The energy is absorbed by the molecule with subsequent electronic transition to the next state, to a higher level state where the electrons remain for a short period of time. From here the electrons may fall back to the ground state and release the gained energy in terms of longer wavelength and colour, which is related to the energy given off and fluorescent light

can be emitted. Autofluorescence, the natural fluorescence of dental hard tissue without the addition of other luminescent substance has been known for a long time [Benedict, 1928]. Demineralisation will result in loss of autofluorescence [Borisova et al., 2006] which can be quantified using caries detection methods based on the differences in fluorescence between sound and carious enamel.

Transillumination

The caries lesion may also be examined by shining white light through the tooth [Schneiderman et al., 1997]. Wavelengths in the visible range (400-700 nm) are limited by strong light scattering, making it difficult to image through more than 1 mm or 2 mm of tooth structure [Darling and Fried, 2008]. Research has shown that enamel is highly transparent in the NIR range (750 nm to 1500 nm) due to the weak scattering and absorption in dental hard tissue at these wavelengths [Buhler et al., 2005; Darling and Fried, 2005; Darling et al., 2006; Fried et al., 1995; Jones et al., 2003; Wu and Fried, 2009]. Therefore, this region of the electromagnetic spectrum is ideally suited to the development of new optical diagnostic tools based on transillumination (TI).

This is a promising technique for detecting the presence of caries and measuring its severity. The method is non-destructive, non-ionising and reportedly more sensitive to detect early demineralisation than dental x-rays [Darling et al., 2006]. Identification of dental caries by TI is based on the fact that increased mineral loss in an enamel lesion leads to a twofold increase in scattering coefficient at a wavelength of 1.3 μm [Darling and Fried, 2005; Darling et al., 2006]. Most research to date has used this wavelength, where low-cost light sources are available. When light illuminates the tooth the strong scattering effect in the enamel caries lesion results in less transparency. The decreased light transmission associated with the lesion can be detected when compared to that of the surrounding sound tissue.

OPTICAL CRIES DETECTION METHODS IN THIS THESIS

Laser-induced fluorescence

The DIAGNOdent™ (KaVo, Biberach, Germany) is a portable commercially available device (**Fig. 3A**) for detection and quantification of caries [Hibst and Gall, 1998; Lussi et al., 2004]. Red laser light ($\lambda = 655 \text{ nm}$) is emitted by the device via an optical fibre and a probe to the caries lesion (**Fig. 3B**). When the light interacts with certain organic molecules that have been absorbed into the porous structure the light is re-emitted as invisible fluorescence in the NIR region. The NIR fluorescence is believed to originate from protoporphyrin IX and related metabolic products of oral bacteria [Gostanian et al., 2006]: these products are chiefly responsible for the absorption of red light. The emitted light is channelled through the handpiece to the detector and digitally displayed on a screen (0-99). A higher number indicates greater fluorescence and by inference a more extensive subsurface lesion.

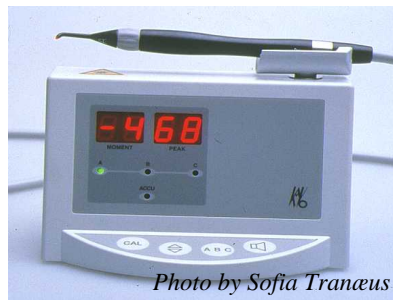

Figure 3A

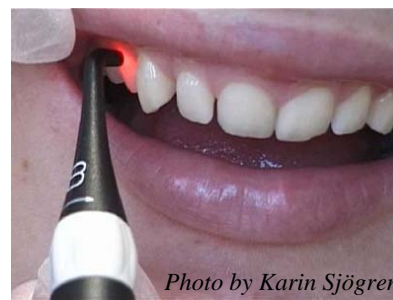

Figure 3B

A) The LF device operates with light from a diode laser transmitted through a descendent optic fibre to a hand held probe with a fibre optic eye. The emitted fluorescence is collected through the tip, passes into ascending fibres, and is finally processed and presented on the display as an integer between 0-99; B) in the presence of carious tooth substance, fluorescence increases.

Two versions of the laser fluorescence (LF) device are currently available commercially. As well as the DIAGNOdent 2095™ for application to smooth and occlusal surfaces investigated in this thesis, the latest version, the LF-pen, has been

designed for easier access to approximal surfaces. The original LF device has shown good performance and reproducibility for detection and quantification of occlusal and smooth surface caries lesions in *in vitro* studies, but the results of *in vivo* studies have been somewhat contradictory [Abalos et al., 2009; Akarsu and Koprulu, 2006; Angnes et al., 2005; Anttonen et al., 2004; Astvaldsdóttir et al., 2004; Bamzahim et al., 2005; Chu et al., 2009; Khalife et al., 2009; Reis et al., 2006; Rocha et al., 2003]. The LF method has also been investigated for longitudinal monitoring of the caries process, and for assessing the outcome of preventive interventions [Aljehani et al., 2006; Andersson et al., 2007; Anttonen et al., 2004; Kronenberg et al., 2009; Sköld-Larsson et al., 2004]. The potential role of the LF device in detection of root caries lesions has not been extensively investigated and hitherto only two validity studies are available [Wicht et al., 2002; Zhang et al., 2009].

Quantitative Light-induced Fluorescence

This method is based on the principle that the autofluorescence of the tooth alters as the mineral content of the dental hard tissue changes. Increased porosity due to a subsurface enamel lesion scatters the light either as it enters the tooth or as the fluorescence is emitted, resulting in a loss of its natural fluorescence. Bjelkhagen et al., [1982], Sundström et al., [1985] and subsequently de Josselin de Jong et al., [1995] developed a technique based on this optical phenomenon. The underlying theory has been described extensively in several publications [Angmar-Månsson and ten Bosch, 2001; Tranæus et al., 2001b; van der Veen and de Josselin de Jong, 2000]. The changes in enamel fluorescence can be detected and measured when the tooth is illuminated by violet-blue light (wavelengths 290-450 nm, average 380 nm) from a camera hand piece, following image capturing using a camera fitted with a yellow 520-nm high pass filter (QLF; Inspektor™ Research Systems, Amsterdam, the Netherlands), **Fig. 4A**. The image is captured, saved and processed: it is first converted to black-and-white so that thereafter the lesion site can be reconstructed by interpolating the grey level values in the sound enamel around the lesion. The difference between measured and reconstructed values gives three quantities; ΔF (average change in fluorescence, %), lesion area (mm^2), and in later versions of the QLF software, ΔQ (area x ΔF), which gives a measure of the extent and severity of the lesion. **Figure 4B** shows the analytical stages of the method.

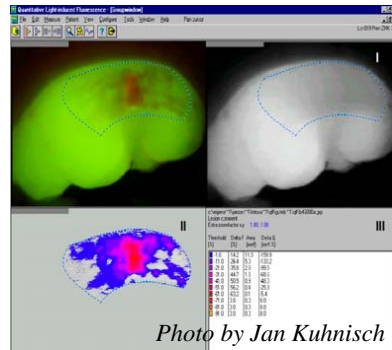
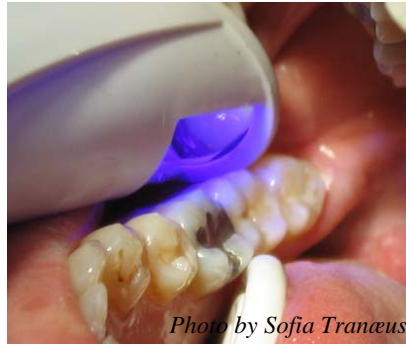

Figure 4A

Figure 4B

A) Light of certain wavelengths is lead by an optic fibre from the light source to a hand piece with a micro Charge Couple Device video camera. B) The image can be captured and saved for later analysis. Computer program: QLF 1.97e Inspector Research System BV, Amsterdam, The Netherlands.

A high positive correlation is reported between QLF and absolute mineral loss, $r=0.82-0.92$ [al-Khateeb et al., 1997; Gmur et al., 2006; Heinrich-Weltzien et al., 2003b]. At a consensus meeting in 2002, The International Consensus Workshop on Caries Clinical Trials (ICW-CCT) [Pitts and Stamm, 2004] it was agreed that QLF may offer one solution in the effort to reduce both the number of subjects and the duration of caries clinical trials. The method seems to have been rapidly adopted as a standard reference measure in clinical tests of the efficacy of preventive measures.

Transillumination with near-infrared light

A methodology to characterise a TI system (**Fig. 5**) was implemented, using two wavelengths of choice, $1.28 \mu\text{m}$ and $1.4 \mu\text{m}$. In order to quantify the spatial resolution of acquired images and in this way determine optical changes within caries lesions, *i.e.* to contrast sound and demineralised areas, a procedure to determine the spatial frequency of the imaging system was implemented. To this end, rather than working with caries tissue of undetermined contrast, artificial patterns recorded on masks were used. The periodic patterns had a known number of line pairs per millimeter (LP/mm), where a line pair consisted of an absorbing and its adjacent lucent space. The spatially periodic patterns were projected on the surface of intact teeth of various thicknesses, resulting in a distribution of shallow regions that were entirely dark, simulating an array of “perfect” shallow caries lesions. This known input image then

passed through the enamel tissue to the detector and the contrast of the recorded image was used for the measurement of the resolution of the system. Since highly subjective perception and judgment is involved when estimating the contrast, the quality of the imaging system was characterised by the entire Modulation Transfer Function (MTF) [Feltz and Karim, 1990; Park et al., 1984]. MTF is the function that describes the modulation at a given spatial frequency. Imaging systems reproduce high spatial frequency signals with poorer contrast than low spatial frequency, and consequently their MTF's decreases with increasing spatial frequency. The TI method also offers the advantage of allowing repeated projection of the tooth without exposure to ionising radiation and the potential to estimate the relative position of an approximal caries lesion.

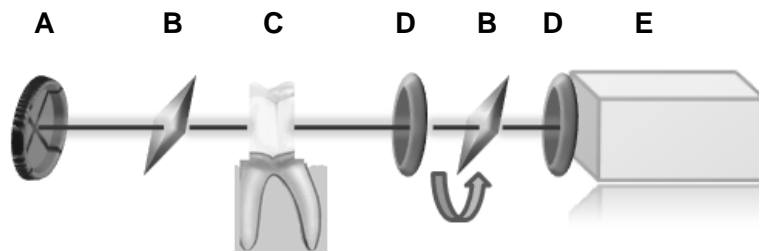


Illustration by Ana Marly Araújo Maia

Figure 5.

Experimental set-up of the transillumination system: A) near-infrared light source; B) polarizer; C) tooth section; D) lens; E) Charge Couple Device camera.

AIMS

A conservative, non-invasive, or minimally invasive approach to clinical management of caries lesions requires diagnostic methods which can detect and quantify very small changes in lesions. This cannot be achieved by conventional methods alone. Thus, the main theme of the present thesis is the evaluation of optical methods to supplement conventional routines for caries detection on coronal and root surfaces, in enamel and dentin. Although two such methods, laser-induced fluorescence (LF) and quantitative light-induced fluorescence (QLF) are well-established, a review of the research to date does not confirm that either method meets all the requirements for practical clinical application. A novel method, transillumination (TI) with near-infrared (NIR) light has undergone initial laboratory investigations with promising results and warrants further investigation as a potential alternative to the above methods. The general aim of this thesis was therefore to evaluate two established optical technologies, LF and QLF, for detection and quantification of dental caries, and to implement and characterise an imaging technique for caries detection based on TI with NIR.

Specific aims

- ✚ To validate the LF method clinically for occlusal caries detection and quantification, by comparing LF readings with actual lesion depth. Secondly, to compare LF readings on smooth surfaces with corresponding measurements by QLF (ΔF), served as a reference standard. (**Study I**)
- ✚ To evaluate the feasibility of applying the QLF method to monitor small changes (ΔF and lesion area) in white spot lesions on smooth surfaces, in a clinical study investigating the potential of weekly brushing with amine fluoride gel to enhance remineralisation. (**Study II**)
- ✚ To validate LF, visual inspection and surface texture for detection of root caries lesions *in vitro*, against histological lesion depths. Secondly, to investigate the possible influence of discolouration and surface texture on LF readings (**Study III**)
- ✚ To develop a procedure to characterise the performance of a TI system for detection of early caries lesions, at two wavelengths within the NIR spectrum. Secondly, to investigate the potential of the method to indicate the relative position of a simulated approximal enamel caries lesion. (**Study IV**)

MATERIAL AND METHODS

The methods are briefly described in this section: detailed descriptions are presented in each individual paper.

The material and methods in the four papers are summarised in **Table 1**.

Paper	Study type	No of subjects / Samples	Remarks	Surface examined	Optical method
I_{part I}	clinical	30	52 test sites	occlusal	LF
I_{part II}	clinical	30		smooth	LF and QLF
II	clinical	135		smooth	QLF
III	laboratory	93	Reliability	root	LF
	laboratory	64 out of 93	Validity	root	LF
IV	laboratory			enamel	TI

Table 1.

Overview of material and methods applied in the four papers included in the thesis

Ethical considerations

Studies I-IV were approved by the Ethics Committee at Huddinge University Hospital, Huddinge, Sweden, as follows: Paper I (155/01 and amendment 2001-01-14 to study 430/97); Paper II (430/97); Paper III (2006/380-31/3); and Paper IV (2006/380-31/3) which was also approved by the Ethical Committee in Universidade Federal of Pernambuco-Recife, Brazil (268/2007). The clinical studies (I and II) were conducted according to ICH/GCP regulations.

Paper I

Part one (*occlusal surface*)

Subjects

The material comprised 30 subjects, 18-42 years of age, with a total of 52 test sites on the occlusal surface of the 1st or 2nd molar. All examinations were undertaken independently by the two operators, who were calibrated before the start. A third person undertook collection of all data including the LF readings, which were unavailable to the operators.

Documentation, visual inspection and bitewing radiography

All test sites were documented with a digital camera, Nikon COOLPIX 990, before opening, at the end of caries removal/cavity preparation, and after restoration. These images provided a permanent record of the appearance of the teeth and the extent of the lesions, as well as a guide for repositioning. The images were digitally stored. An initial visual inspection, using magnification at 2.6x, with or without the explorer, was recorded according to codes adapted from Ekstrand's visual scoring system [Ekstrand et al., 1998], shown in **Table 2A**. Bitewing radiographs were taken of all teeth according to standard clinical protocol, unless the patient had bitewings less than 6 months old. The radiographs were then evaluated according to the criteria in **Table 2B**.

2A. Visual inspection criteria

- 0 No or slight change in enamel translucency after prolonged air drying
- 1 Opacity or discoloration distinctly visible after air drying
- 2 Localised enamel breakdown in opaque or discoloured enamel and/or greyish discolouration from the underlying dentin

2B. Radiographic criteria

- 0 No radiolucency visible
- 1 Radiolucency visible in the enamel
- 2 Radiolucency visible in the outer dentin, just beyond DEJ
- 3 Radiolucency visible in the inner dentin, clearly beyond the DEJ

2C. Clinical criteria

- 0 No caries
- 1 Caries in the enamel
- 2 Caries in the outer dentin, just beyond DEJ
- 3 Caries in the inner dentin, clearly beyond the DEJ

Table 2.

Criteria used in: A) visual inspection; B) radiographic examination; and C) after fissure was opened.

LF measurements

Two LF devices (DIAGNOdent 2095™, KaVo, Biberach, Germany), LF 1 and LF 2, were tested separately. Before the LF measurement was undertaken, the surface of the tooth was cleaned with bicarbonate spray utilising the Prophy Flex 2 device (KaVo, Biberach, Germany). The tooth surface was air-dried for 5 s with a compressed air syringe prior to measurement. Each test site was measured twice, using the conical tip, with water spraying and air-drying in between to standardise the humidity. The devices were calibrated against a ceramic standard before every measurement session and the standard value for each tooth was calibrated by measuring at a sound enamel reference point [Karlsson et al., 2004]. The highest reading obtained was recorded and the site was indicated as a dot on the photograph.

Treatment decisions

On the basis of visual inspection, bitewing evaluation, and clinical judgement, a decision was made as to whether to treat the tooth invasively or not. If the tooth was judged to be sound, and not in need of opening, it would be classed as sound clinically. However, if the LF reading indicated that the tooth had a hidden lesion (LF reading of 15 units or higher), the surface was minimally explored with a fine bur.

Validation of lesion depth

When the suspicious or definitely carious lesion was opened with the appropriate bur, the examiner determined the depth of the lesion according to the criteria in **Table 2C**. Depending on the depth and extent of the cavity after careful caries removal, the area was restored with fissure sealant or composite restorative material.

Part two (smooth surfaces)

Subjects

Thirty patients, 13-15 years of age with a total of 30 test teeth participated in the second part of the study, which was conducted in conjunction with an on-going clinical trial using QLF for longitudinal caries quantification (Study II). The test teeth were standardised to the lower left first molar (tooth no. 36), with active incipient enamel lesions on the buccal smooth surface. All examinations were made independently by two operators, who were calibrated before study start.

Measurements with QLF and LF

Firstly, images of the test sites were captured using the QLF device. Thereafter the test sites were carefully scanned with the LF device, using the flat probe. The procedure for device calibration as well as for the standard value for each tooth was carried out as described above in part one of the study. The site of highest LF reading was recorded. The two operators independently performed the measurement cycle twice at each test site, with water spraying in between to standardise the humidity.

The QLF images were digitally stored until the study was completed and then analysed by one operator using special software (Inspector QLF 1.97e, Amsterdam, The Netherlands). The QLF data (ΔF) were subsequently used as a reference standard for validation purposes.

Paper II

Subjects

The participants comprised 135 caries-active adolescents, 65 in the test group and 75 in the placebo group, with two or more white spot lesions on the buccal surfaces of the premolars or permanent molars. Four operators, highly experienced in the use of QLF, examined the same group of subjects throughout the study period.

Experimental design

The study period was 12 months from baseline to closed file, with subjects recalled every 3rd month (baseline, 3, 6, 9, and 12 months). The participants were issued with an amine fluoride dentifrice (1250 ppm F) to be used twice a day, and either a test (4000 ppm F) or a placebo gel for brushing 2 min once a week. At each visit, ΔF (average change in fluorescence, in %), and lesion area (in mm²) were measured by QLF, followed by dietary counselling, oral hygiene instruction, and professional tooth cleaning. At baseline, 6 and 12 months, saliva was sampled for mutans streptococcus and lactobacillus counts, and gingival bleeding index (GBI) was registered, (**Fig. 6**). The QLF images were digitally stored until the study was completed and then analysed by one operator, using special software (Inspector QLF 1.97e, Amsterdam, The Netherlands).

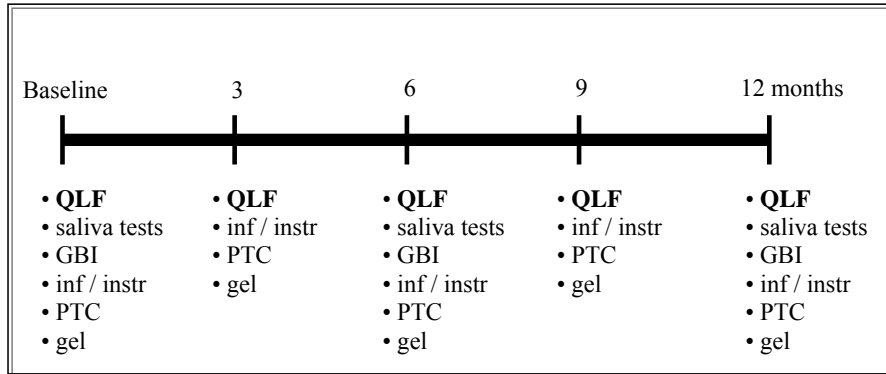


Figure 6.

Study design. At each visit, ΔF and lesion area were monitored by QLF and oral hygiene instruction (instr), dietary counselling (inf), and Professional Tooth Cleaning (PTC) were carried out. A test gel or placebo gel was provided. At baseline, 6 and 12 months, Gingival Bleeding Index (GBI) was registered and saliva was sampled to estimate levels of mutans streptococci and lactobacilli.

Paper III

The material comprised 93 extracted teeth, nine with visually intact root surfaces and eighty-four with various stages of root surface caries lesions. The teeth were photographed to facilitate repositioning at the test site, a reference which was also used for the subsequent orientation of the tooth slice for histopathological analysis. Calibrated operators assessed lesion colour and surface texture according to **Table 3A and B**.

Discolouration	Surface texture
Intact	Intact
Yellowish	Soft
Yellowish-Brown	Leathery
Brownish - Black	Hard

Table 3A

Table 3B

A) Visual and B) tactile criteria for determining root caries lesions.

Four operators recorded two measurements on each test site, using two LF devices (DIAGNOdent 2095™, KaVo Biberach, Germany) with the flat tip recommended for

smooth surfaces. Operator one performed all measurements twice with LF device 1 (LF 1), and immediately afterwards with LF device 2 (LF 2). The same operator repeated this procedure one week later, and after a further interval of one week made a third, final series of measurements. Operators two, three and four repeated the same series of measurements, following the same time schedule. The procedure for device calibration as well as for the standard value for each tooth was carried out as previously described.

Each tooth was embedded in methyl-methacrylate and sectioned into approximately 300 µm thick slices, using a water-cooled diamond saw [Borsboom et al., 1987]. Due to saw machine failure, not all the slices could be retrieved. Slices of the remaining 64 teeth were examined in a light microscope at x16 magnification. Lesion depth was assessed using two references: from the delineated borderline of the original exposed root surface (Ref I), or in cases of loss of surface continuity, the absolute lesion depth (Ref II) as seen in **Figure 7**.




Figure 7.

- Reference I
- Reference II
- Histopathological depth

Paper IV

Two extracted intact human third molars teeth were selected for the study. A buccolingual section, approximately 7 mm thick, was sawn perpendicularly to the occlusal surface from each tooth using a Low Speed Diamond Wheel Saw (Model 650, South Bay Technology, USA). The TI system under evaluation (**Fig. 5**) was operated at two wavelengths, 1.28 µm and 1.4 µm. Eight test charts, set by the United State Air Force in 1951 (MIL-STD-150A standard) (**Fig. 8**) and with various values

of spatial periods, *i.e.* one dark line and one light space per period, also known as LP/mm, were attached to tooth sections.




Figure 8.

*Spatial resolution of test chart used in the experiment. The scale (ruler) gives about 2 LP/mm, *i.e.* 250 μm per line.*

The tooth section was transilluminated and the transmitted image was captured, using both wavelengths. The sections were then consecutively reduced in thickness by a Micro Electrical Motor (Beltec, LB 100 Model, São Paulo, Brazil) and a sequence of all sizes of the test charts were used for repeated imaging procedures, (**Fig. 9**). The contrast (C) and spatial frequency (LP/mm) of acquired TI images were calculated by plotting the profile of intensity values of pixels along a line set on a designated area of all images. The modulation (M), *i.e.* Michelson contrast, was calculated as: $M = (I_{\text{max}} - I_{\text{min}}) / (I_{\text{max}} + I_{\text{min}})$, with I_{max} and I_{min} representing the highest and the lowest mean intensities of the peaks.

In order to investigate the potential of the method to indicate the relative position of a simulated approximal enamel caries lesion, a 1-mm deep cavity was prepared and filled in a tooth, using a diamond bur (0.9 mm in diameter, no. 1011, KG Sorensen, São Paulo, Brazil). A buccolingual section, approximately 6 mm thick, was sawn perpendicularly to the occlusal surface. TI images were acquired from both sides of the tooth section using uniform illumination at both wavelengths. Each sample was then consecutively reduced in thickness to 5, 4, 3 and 1.8 mm sections. The image capturing procedure was repeated for each thickness. Here, the modulation was calculated from $M = (I_{\text{enamel}} - I_{\text{lesion}}) / (I_{\text{enamel}} + I_{\text{lesion}})$, where I_{lesion} is the average intensity measured in a lesion and I_{enamel} is the average intensity measured at

neighboring healthy tissue. The modulation was determined from both sides of the tooth section.

The illumination sources used were a Raman Fiber Laser (Key Optical System, China) and a super luminescent diode (SLD-571, SUPERLUM, Moscow, Russia). All images were detected using a Charge Couple Device (CCD) camera (MicronViewer 7290A, Electrophysics, Fairfield, NJ, USA), captured with a software program, Spiricon Laser Beam Diagnostics (LBA-PC, Version 2.5, Utah, USA) and analysed with a downloadable image processing program, ImageJ (NIH, Maryland, USA).

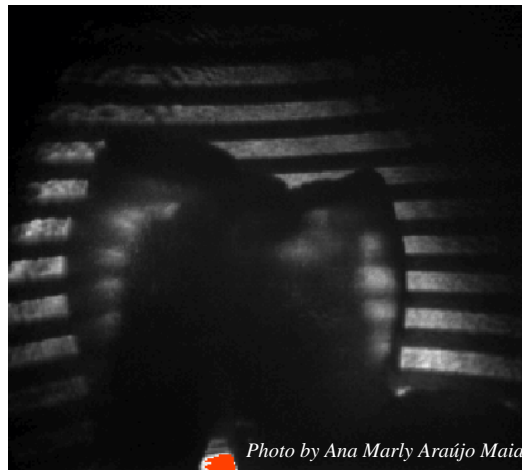

Figure 9.

Image obtained through a 4 mm section of a molar tooth with 0.4 mm period resolution test chart, i.e. 2.5 LP/mm which indicates 200 μm thick features, transilluminated with 1.28 μm wavelength radiation.

STATISTICAL ANALYSES

In **Paper I**, the correlation between LF measurement, visual inspection, bitewing radiographs and the clinically assessed lesion depth was evaluated by Spearman's rank correlation coefficient. One-way ANOVA with repeated measures was used to determine systematic differences or interactions between devices, operators or measurements. Spearman's rank correlation coefficient was also used to determine the inter-device, inter-operator and intra-operator agreement, as well as the agreement between LF readings and QLF readings (ΔF), the reference standard. In **Paper II**, repeated measures ANOVA were applied to determine differences between the experimental groups, and changes over time in terms of ΔF and lesion area. Inter-group interactions and differences were determined and evaluated, and finally completed with multivariate statistical methods. One-way ANOVA was used in **Paper III** to analyse the correlation between LF measurements, lesion colour, surface texture and lesion depth, as well as the influence of lesion colour and surface texture on the LF readings. Repeated measurements ANOVA were used to estimate sum of squares to calculate the Intraclass Correlation Coefficient (ICC) and inter-device, inter-operator, and intra-operator agreement. Two absolute measures of variation - the Repeatability Coefficient and the Measurement Error – were also calculated. The standard deviation of repeated measurement provided an estimate of measurement error. The Repeatability Coefficient as a measure of repeatability, which was adopted by the British Standards Institute 1979, was calculated as 2.77 times the standard deviation. Repeatability is expected to cover 95% of differences between repeated measurements [Bland and Altman, 1999]. The operator reliability for the analytical stage in **Paper IV** was evaluated by ICC.

All statistical tests were two-sided and the level of significance was set to $p < 0.05$.

RESULTS

The results are briefly described in this section: detailed descriptions are presented in each individual paper.

Validity of LF for detection of coronal and root caries lesions (Papers I and III)

In **Paper I** (*occlusal surfaces*), analysis by Spearman's rank correlation coefficient of LF readings for occlusal dentinal caries showed very poor correlation with clinically assessed lesion depth ($r < 0.15$), regardless of the device used. The corresponding values for visual inspection were 0.31 to 0.61 and for bitewing radiographs 0.40 to 0.52, depending on the operator. In the second part of **Paper I** (*smooth surfaces*) the correlation between LF and QLF (the reference method) was acceptable, with values ranging 0.57 to 0.73. In **Paper III** (*root surfaces*), analysis by one-way ANOVA of the correlation between LF measurements and histopathological depth of the lesions, disclosed an extremely low correlation ($r < 0.01$). As seen in **Table 4**, a moderately significant correlation was found between the depth and colour of the lesion (values at best 0.48) and between the depth and surface texture of the lesion (values at best 0.50). The influence of lesion colour and surface texture on the LF readings ranged from 0.33 to 0.36.

	n=64				n=93			
	Histological depth				Clinical examination			
	Reference I		Reference II		Colour		Surface texture	
	r	p	r	p	r	p	r	P
LF 1	0.0027	NS	0.0075	NS	0.35	<0.05	0.36	<0.05
LF 2	0.0095	NS	0.0006	NS	0.33	NS	0.33	NS
Colour	0.48	<0.01	0.37	<0.001				
Surface	0.42	<0.01	0.50	<0.05				

Table 4.

Correlation between LF readings and histological depth of lesions, LF readings and lesion colour and surface texture and lesion colour and surface texture and histological depth of lesions

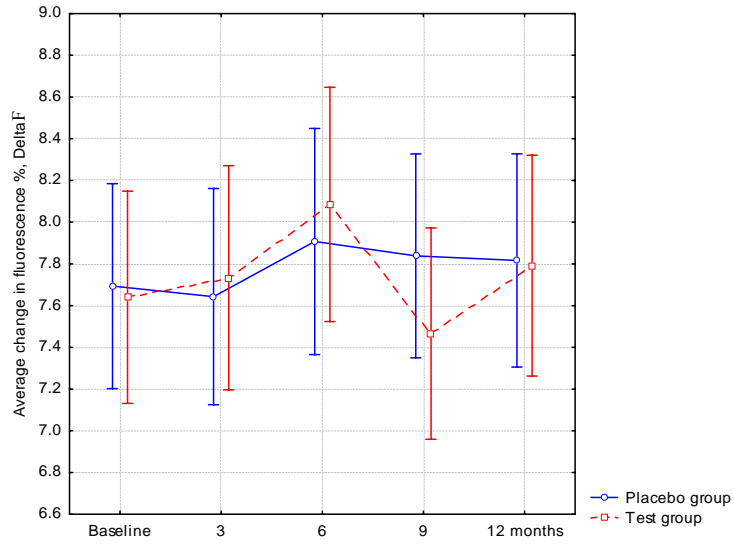
Reliability of the LF method (Papers I and III)

In **Paper I**, analysis by repeated measures ANOVA disclosed significant systematic inter-device and inter-operator differences ($p < 0.001$ and $p = 0.008$, respectively). However, there was no significant systematic difference between the measurements in general ($p = 0.72$). No significant systematic interactions between devices, operators or measurements were disclosed. The levels of agreement were 0.67 to 0.89 at inter-device level and 0.71 to 0.87 and 0.80 to 0.92 at inter-operator and intra-operator level respectively. In **Paper III**, the reliability of LF measurement for root caries lesions, expressed as intraclass correlation coefficient, was 0.99 (intra-operator), 0.97 (inter-operator), and 0.98 (inter-device). There were pronounced differences between two consecutive measurements and high measurement errors, indicating considerable deviation of individual measurements.

Application of QLF to monitor changes in white spot lesions (Paper II)

In **Paper II**, analysis of QLF monitoring by repeated measures ANOVA disclosed no enhancement of remineralisation of white spot lesions in those subjects using supplementary weekly brushing with amine fluoride gel. **Figure 10A** shows that in the test group, ΔF values at the 6-month recall (8.09%) were significantly different from both the baseline and 9-month recall values (7.63% and 7.48% respectively). In the test group, the lesion area recorded at the 3-month visit (1.58 mm²) was significantly different from those at baseline (1.78 mm²) and after 9 and 12 months (1.75 mm² and 1.73 mm² respectively), as shown in **Figure 10B**. In the placebo group, no corresponding significant differences in ΔF and lesion area were disclosed. The changes in fluorescence radiance (ΔF and lesion area) observed over time in the test group as well as between the experimental groups were relatively minor, and although some were statistically significant they were considered of no clinical relevance. With respect to salivary counts of mutans streptococci and lactobacilli, there were no statistically significant differences between the experimental groups after 12 months. However, mutans streptococci increased significantly over time in the placebo group ($p < 0.05$). GBI showed a highly significant improvement over time in both groups.

A)



B)

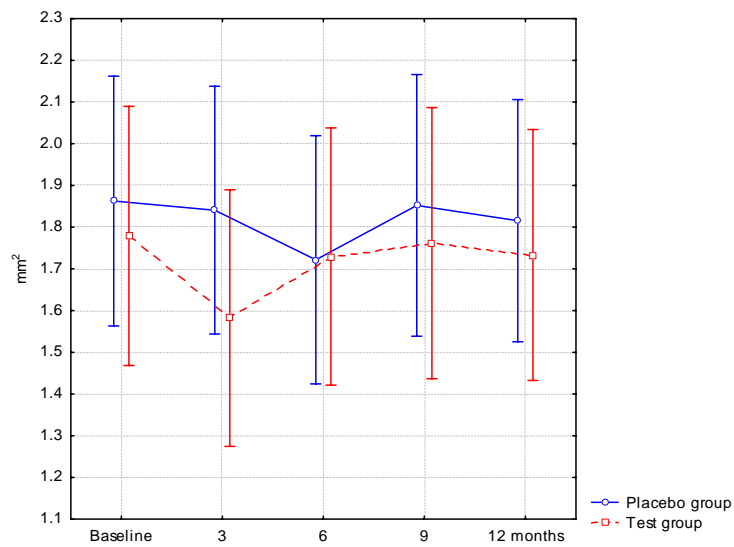


Figure 10A. ΔF with -5% threshold, for all teeth over time ($n=135$). Vertical bars denote 0.95 confidence intervals. **B.** Lesion area with -5% threshold, for all teeth over time ($n=135$). Vertical bars denote 0.95 confidence intervals.

Characterisation of TI system performance (Paper IV)

The TI system evaluated in **Paper IV** showed that useful images could be obtained at 1.4 μm wavelength, transmitted through enamel in tooth sections as thick as 6 mm and at the 1.28 μm wavelength, through sections as thick as 5 mm. The system is capable of detecting spatial frequencies of ~ 2 LP/mm at approximately 30% modulation and about 5 LP/mm at approximately 20% modulation. This indicates that features of 250 μm and 100 μm , respectively, can be resolved with relative ease. The graph in **Figure 11A** shows the modulation transfer function and spatial frequency for tooth sections of 1, 2, and 3mm thickness illuminated with the shorter wavelength. **Figure 11B** shows the MTF's at 1.4 μm wavelength for tooth sections of 2, 3 and 5mm thickness. The simulated approximal enamel caries lesion was clearly detectable in all images obtained in the case of the caries lesion near the CCD, regardless of the sample thickness or the wavelength used. The modulation was relatively constant ($47 \pm 6\%$). The potential for estimating the relative position of a simulated approximal enamel caries lesion was demonstrated: when tooth sections of different thicknesses were illuminated from both sides in sequences, the resultant image degraded as it traversed through thicker layers of enamel and modulation values decreased with thickness. This was reflected in a large ratio (R) between the two modulation values obtained from each side of the 6 mm section: $R(6\text{ mm}) = M_{\text{near}}(6\text{ mm}) / M_{\text{far}}(6\text{ mm}) = 16$. When the thickness of the tooth section was reduced to 3 mm and the lesion was 2.05 mm and 0.95 mm from the respective faces, the ratio declined to $R(3\text{ mm}) = 3$ and the modulation values were 0.45 and 0.15 respectively.

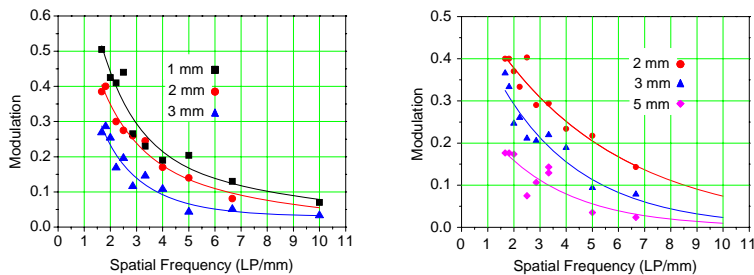


Figure 11A. Modulation Transfer Function of imaging system for sample 1 at 1.28 μm wavelength. From top to bottom: results for 1, 2 and 3mm thick sections. **B.** Modulation Transfer Function of TI system for sample 2 at 1.40 μm wavelength. From top to bottom: results for 2, 3 and 5 mm thick sections.

DISCUSSION

A caries detection method intended for application in clinical practice should meet the following requirements: the new method should be more sensitive than currently available methods; should detect early, shallow lesions, differentiate between shallow and deep lesions; should give a low proportion of false positive readings, present data in a quantitative form so that lesion activity can be monitored, and be precise so that measurements can be repeated by several operators. The method must also meet safety regulations, be cost-effective and user friendly.

Although the optical technologies evaluated in this thesis do not fulfil all these requirements, they offer distinct advantages over the more subjective methods generally relied on today and may be regarded as aids to supplement conventional methods of caries detection.

The studies on which this thesis is based were designed to evaluate the LF method for detection of occlusal dentinal and root caries lesions. The QLF method was applied to determine whether longitudinal measurements of enamel autofluorescence could detect differences in remineralisation of early enamel caries following preventive intervention. One novel method, the TI technique, was implemented, characterised and quantified with special reference to optical resolution of images captured by the system.

Both QLF and the TI method enable imaging detection of enamel caries that can be digitally stored and viewed later. The QLF method also includes image analysis software which measures the difference in fluorescence between sound and demineralised enamel. Changes in fluorescent radiance and lesion area can be followed over time, to measure lesion development.

Transillumination of enamel with NIR light is a promising technique for the detection and imaging of occlusal and approximal lesions [Buhler et al., 2005; Jones et al., 2003], *i.e.* surfaces most susceptible to caries [Hopcraft and Morgan, 2005; Mejäre et al., 1998]. Application of repeatable, non-ionising radiation of the tooth allows the TI method to be used without restriction to monitor the caries process. The method overcomes some of the limitations of dental radiography such as overlapping. Moreover, the method can indicate the relative position of a lesion on approximal surfaces by calculating the ratio of modulation values obtained by illuminating tooth from the lingual or buccal surface respectively. The method uses a range of wavelengths where low-cost light sources are available and the transmitted

image can be detected by an ordinary CCD camera, similar to the one in mobile phones. The method can therefore be developed at reasonable cost as a fibre optic probe for intra-oral use, connected to an ordinary computer screen.

New methods for transilluminating teeth, such as digital imaging fiber-optic transillumination (DIFOTI) [Schneiderman et al., 1997] have been introduced for more accurate and reliable diagnosis of caries lesions. The principle underlying the DIFOTI imaging system is similar to the TI system investigated in this thesis: the technology involves light, a CCD camera and computer-controlled image acquisition. However, the DIFOTI method involves high-intensity white light within the visible range of the electromagnetic spectrum and is therefore highly limited by scattering [Hall and Girkin, 2004]. The method has demonstrated poor correlation to clinical lesion depth [Bin-Shuwaish et al., 2008]. When compared to radiographic film and the depth of approximal lesions, it was found that DIFOTI was not able to measure the lesion depth at all [Young and Featherstone, 2005]. Methods that use longer wavelengths, such as in the NIR spectra (780 to 1550 nm), can penetrate the tissue more deeply. This deeper penetration is crucial for TI.

The LF method, which has been available commercially for some years, generates a simple numerical index of de- and remineralisation in enamel and dentin that can be recorded in the patient's file and monitored over time. The instrument is easy to handle and can also be purchased at a reasonable price. The *in vitro* and *in vivo* performance of the instrument (2095™) has been quite extensively investigated. A review by Bader and Shugars [2004] disclosed that although several evaluations of diagnostic performance have appeared in the literature, the range of the LF device performances is extensive. For detection of dentinal caries, sensitivity values ranged widely (0.19 to 1.0), although most tended to be high. Specificity values exhibited a similar pattern, ranging from 0.52 to 1.0. In comparison with visual assessment methods, the LF exhibited a sensitivity value that was almost always higher and a specificity value that was almost always lower. The body of evidence was based primarily on *in vitro* studies. Extrapolation to the clinical setting is uncertain.

In this thesis, the LF method was evaluated under both *in vitro* and *in vivo* conditions. In **Paper I** the purpose was to determine whether the high validity and reliability for occlusal caries detection that had been reported from previous *in vitro* studies could also be achieved under clinical conditions.

The present study was unable to confirm the earlier *in vitro* findings. The correlation between LF measurement and clinical lesion depth was very low, $r <$

0.15. The range of readings for enamel as well as dentin lesions was wide: 4-99. However, when suggested threshold values for dentinal lesions (20 and 25 reading units, respectively) were applied, the overall correct observation was high (85% and 77%). This finding could indicate that clinical readings on occlusal surfaces from the LF method give good qualitative information, *i.e.* presence / absence of a dentinal lesion, rather than quantitative information about lesion depth. This weak correlation between LF readings and occlusal lesion depth has since been confirmed in numerous studies [Abalos et al., 2009; Akarsu and Koprulu, 2006; Angnes et al., 2005; Anttonen et al., 2004; Astvaldsdóttir et al., 2004; Chu et al., 2009; Heinrich-Weltzien et al., 2003a; Khalife et al., 2009; Reis et al., 2006; Rocha et al., 2003].

The NIR fluorescence is believed to originate from protoporphyrin IX and related compounds from oral bacteria [Gostanian et al., 2006; Lussi et al., 2004], chiefly responsible for the absorption of red light. Hence, there is a poor correlation between LF readings and the mineral content, but possibly better correlation with the presence of infected dentin.

For the clinician to have confidence in using a caries detection method to support clinical treatment decisions, it is important that interpretation of readings is based on an understanding of the principles underlying the method and an awareness of potential shortcomings. With reference to LF, the question of what the method really measures has yet to be resolved. More research is needed to clarify the origin of the increased fluorescence caused by the excitation of 655 nm wavelength light.

The limitations of radiographs and visual inspection for detecting occlusal caries are widely acknowledged [Bader et al., 2001, 2002; Lussi, 1991; The Swedish Council on Technology Assessment in Health Care, 2008; Tveit et al., 1994; Yang and Dutra, 2005]. The results of **Paper I** are no exception. In many cases, the actual lesion depth proved to be deeper than predicted by visual inspection and bitewing radiographs.

Among LF studies there is a wide variation in specific design features (the number of teeth included, the threshold for LF scores, validation methods, the outcomes expressed, etc.). This reflects not only the subjective nature of most diagnostic methods but also the state of the science of dental diagnostic studies in general [Bader and Shugars, 2004].

A common way to express the diagnostic accuracy of detection/quantification methods is to calculate sensitivity and specificity. In **Paper I**, teeth that were considered sound were not included. For ethical reasons, teeth can be

validated invasively only where disease is thought to be present. This partial validation method of the sample cannot detect false-negative results and therefore sensitivity and specificity were not presented. However, a model was constructed in which the teeth examined in **Paper I** were included, with 0 scores for visual inspection and bitewing radiography and LF readings <15, *i.e.* teeth that were not validated and either true-negative or false-negative. Despite the authors' efforts to find balanced sensitivity and specificity values, with a specificity >0.80 combined with sensitivity >0.80, it was not possible to obtain a suitable threshold value. With a specificity >0.80, the sensitivity was as low as 0.14-0.43, which is unacceptable for a diagnostic method. Studies in which sensitivity and specificity scores are reported thus include non-validated teeth and/or high threshold values for dentin caries and/or a great number of observations. However, in general, *in vivo* studies of LF for occlusal caries detection indicate moderate to high sensitivity and lower specificity [Abalos et al., 2009; Bader and Shugars, 2004; Chu et al., 2009; Reis et al., 2006]. Lack of specificity, the increased likelihood of false-positive readings due to stain and plaque, and the absence of a single threshold are factors underlying the reluctance among authors to recommend the LF method unequivocally for caries detection. Therefore, the LF device should be regarded at most as a supplementary aid for detection of caries on coronal surfaces.

Since the introduction of the original LF device tested in this thesis, a new device, offering improved intraoral access, has been introduced. The LF-pen (KaVo) is based on the same principle as the original LF device, but with sapphire tips. *In vitro*, the new device performed as well as the original on occlusal surfaces [Lussi and Hellwig, 2006]. *In vitro* reproducibility tests on occlusal surfaces by Kuhnisch et al., [2007] gave unsatisfactory results for both the new and the original device. To date, there is only one published study of the clinical performance of the LF pen on occlusal surfaces [Huth et al., 2008]. At a cut-off value of 25 for the threshold between enamel and dentinal caries, sensitivity was 0.67 and specificity was 0.79. A moderately positive correlation (Spearman's rank) was demonstrated, and greater variation of measurements was recorded with increasing clinically evaluated lesion depth. The reliability disclosed a range of very good to good agreement. Thus at present the clinical applicability of this new LF device must be regarded as unconfirmed, pending the publication of further clinical studies.

With respect to validation of the LF method for root caries detection (**Paper III**), the results were even more discouraging than for occlusal caries. The

correlation between LF readings and histopathological lesion depth was extremely low ($r < 0.01$). The present study applied essentially the same methods, except for statistical analysis, as Wicht et al., [2002] who reported a moderate correlation for Spearman rank correlation ($r = 0.45$). Zhang et al., [2009] recently presented a clinical study evaluating the LF method for assessing root caries with reference to visual-tactile criteria. Lesions assessed as active (yellowish discolouration and soft on light probing) yielded a significantly higher LF mean value than those assessed as inactive (mean readings 29.0 ± 21.4 and 16.7 ± 14.7 , respectively). Sensitivity and specificity were both around 0.80 using a considerably low LF threshold value of 5 reading units. For reference, for detecting coronal caries under clinical conditions, a threshold value of 20 or even 30-40 is recommended [Anttonen et al., 2003; Bader and Shugars, 2004; Bamzahim et al., 2005; Chu et al., 2009; Heinrich-Weltzien et al., 2003a; Lussi et al., 2001; Rocha et al., 2003]. However, when Zhang et al., [2009] applied a threshold value of 20 for root caries, the sensitivity decreased to 0.40, which is unacceptable. The selection of a suitable threshold value for root caries detection is thus a cause for concern. The standard deviations of LF values in the paper by Zang et al., [2009] were large in all dimensions, which implies a wide range of measurements and, hence, a considerable weakness. Moreover, areas of dark discolouration were assessed as inactive lesions, yielding lower LF values. This is in contrast to the results in **Paper III**, where both LF devices gave higher readings for sites with pronounced discolouration and soft surfaces than for sites with intact and leathery-dull surfaces respectively. Therefore, the use of these subjective clinical signs of unknown accuracy as a validated outcome is questionable.

Clinical management of root caries is an issue of concern in most developed countries which have aging, dentate populations [Hugoson et al., 2005; US Department of Health and Human Services, 2000] with heavily restored dentitions at relatively high risk for root caries [Avlund et al., 2004; Fure, 1997, 2003, 2004; Gilbert et al., 2001; Griffin et al., 2004; Luan et al., 2000; Morse et al., 2002; Shay, 2004; Thomson, 2004]. A primary goal is early intervention, to avoid the need for technically difficult, invasive restorative dentistry. An active root caries lesion can be converted to inactive in response to preventive measures [Arneberg et al., 2005; Baysan et al., 2001; Johnson and Almqvist, 2003; Nyvad and Fejerskov, 1986; Schaecken et al., 1991; Schupbach et al., 1992]. For the clinician, a major advantage would be the availability of a caries detection method which would help to determine whether a lesion is active, arrested or undergoing remineralisation.

However, the detection of root caries lesions relies today on subjective observation of clinical signs: visual inspection (colour, cavitations, and location) and tactile examination (surface texture). These signs are open to broad clinical interpretation and practitioners are left with diagnostic methods for which the accuracy is unknown [Banting, 2001; Leake, 2001]. Rosén et al., [1996] demonstrated the highly subjective detection of root caries and lack of intra- and inter-operator consistency. Different operators found varying numbers of caries lesions within the same patient, and also the same operator often recorded different numbers of lesions from one occasion to another.

Clinically, root caries lesions on accessible surfaces are often readily detectable by visual examination. However, an indication of the depth of the lesion would support the clinician in choosing the appropriate treatment, invasive or non-invasive. Such treatment decisions should be based on a valid, reliable diagnosis. The results of **Paper III** do not demonstrate that the LF method can provide this information. Thus the application of the LF device for root caries detection must be considered highly questionable.

The LF method has shown good reliability in *in vitro* studies, but somewhat more contradictory results *in vivo*, both in the primary and permanent dentitions [Abalos et al., 2009; Akarsu and Koprulu, 2006; Angnes et al., 2005; Anttonen et al., 2004; Astvaldsdóttir et al., 2004; Bamzahim et al., 2005; Chu et al., 2009; Khalife et al., 2009; Reis et al., 2006; Rocha et al., 2003]. In **Paper I**, the reliability of the LF method *in vivo* disclosed a range of good to very good agreement at operator level and acceptable to very good agreement at device level. The results of the *in vitro* study (**Paper III**) disclosed excellent values at operator and device level (ICC 0.97 – 0.99). The relatively poor performance by LF under clinical conditions may be attributable to several factors such as the presence of saliva, plaque and stain and limited access to the test site.

An interesting finding from **Paper III** was the test-retest exercises which showed that repeated measurements are relatively stable with respect to lesion, instrument, and operator at group level, but agreement at individual level was poor, with pronounced scattering of measurements. The Repeatability Coefficient and the Measurement Error [Bland and Altman, 1999] were large in all dimensions. Thus the instruments lack precision in the single case situation. Kuhnisch et al., [2004] confirmed these points in an earlier study assessing the reliability of LF measurements on occlusal caries: excellent reproducibility was reported in terms of

ICC values (0.74-0.98), but when estimating limits of agreement, the range of measurements was broad.

The second part of **Paper I** (*smooth surfaces*) showed satisfactory correlation of LF and QLF measurements. However, QLF has demonstrated very high correlation with mineral content [al-Khateeb et al., 1997; Gmur et al., 2006; Heinrich-Weltzien et al., 2003b] and the latter remains the preferred method for research purposes.

Conventional methods of caries assessment are obsolete for research requiring detection of very early phases of mineral changes. QLF may offer one solution, recording the continuum of the early caries process and hence reducing the number of subjects required and the duration of clinical trials [Angmar-Månsson, 2001; Chesters et al., 2004; Feng et al., 2007; Karlsson and Tranæus, 2008; Pitts and Stamm, 2004; Tranæus et al., 2001a; Tranæus et al., 2005]. In the context of clinical trials, consecutive measures of lesion behaviour provide sufficient information to establish the efficacy of test products [Pitts and Stamm, 2004].

The results of **Paper II** in this thesis confirm QLF as a sensitive and precise method for monitoring white spot lesion behaviour. In this study, caries active adolescents, recruited from suburbs of low socio-economic status, were instructed to brush daily with amine fluoride (AMF) toothpaste, and to brush for two minutes twice a week with either an AMF test gel or a placebo gel. Tests of baseline characteristics were performed, confirming that all the recruited subjects had elevated salivary counts of mutans streptococci and lactobacilli and bleeding gingivae, indicating caries risk. A subjective interpretation of the selected lesions as active (located close to the gingival margin, the presence of plaque and the colour and surface texture of the lesion) was also made. The results of **Paper II** showed only minor changes in fluorescent radiance of the lesions over time (12 months), considered to be of no clinical relevance.

One possible confounding was that some of the lesions included for study had been incorrectly assessed as active. As older lesions may not respond to fluoride [Zantner et al., 2006] the possibility that some of the lesions had reached a plateau was further investigated. To complement the data in the study, it was decided to investigate lesion development within each individual over a 4-year period, by collecting data from the subjects' regular annual dental examinations 2 years and 1 year before study start, at study start, and 1 year after the end of the study. All clinics

had changed from analogue to digital radiographic technique during this period and the regular check-ups had been conducted by numerous dentists. The information obtained was therefore not considered reliable.

Another potentially confounding factor was that the duration of the study (1 year) was too short. However, earlier studies have shown that QLF can disclose remineralisation of white spot lesions at intervals of only 6 weeks [Tranæus et al., 2001a] as well as 6 months [Feng et al., 2007]. Even though it must be considered trials of much shorter duration and fewer subjects may be under-powered without large enough sample sizes and to short duration. Dental caries is a dynamic disease process resulting from many cycles of demineralisation and remineralisation.

A further factor influencing the results could be microabrasion of the initial lesions [Artun and Thylstrup, 1986; Backer Dirks, 1966]. The slight acidity of AMF, improved tooth brushing and PTC could initially cause an abrasive effect [Kielbassa et al., 2005], resulting in the initial significant decrease in lesion fluorescence noted in the study. This might result in a more vulnerable lesion, thus leading to increased caries susceptibility and subsequently to the increased loss of lesion fluorescence noted in the study.

While in theory the study should have included a negative control group, this was not permissible on ethical grounds. The preventive measures provided, such as dietary counselling, oral hygiene instruction and professional tooth cleaning (PTC), were considered appropriate for the subjects' level of caries risk. At the end of the study, there were no statistically significant differences between the groups regarding salivary bacterial counts. However, GBI decreased significantly over time in both groups, indicating improved oral hygiene.

The TI system evaluated in **Paper IV** showed that useful images could be obtained in tooth sections as thick as 6 mm. This can be considered equivalent to imaging the contact area of approximal surfaces on molar and premolar teeth, convex in shape and therefore likely to be thinner than 6 mm. These findings are in accordance with similar research by Jones et al., [2003], using an NIR imaging system operating at 1310 nm to image simulated approximal enamel caries. The authors concluded that resolving caries lesions through 5 mm enamel is clinically feasible. In **Paper IV** evaluation of the optical resolution of acquired images disclosed no overall trend favoring either of the wavelengths used. This indicates that the lower quantum efficiency of the CCD camera at 1.4 μm is compensated for by the higher optical

power used at this wavelength. If all other parameters are maintained, the cheaper light source should be preferred.

The TI system was capable of detecting very small lesions. However, it should be noted that this study was conducted under strict laboratory conditions, using the 'perfect' caries lesion, *i.e.* frequency charts composed of line pairs of a perfect absorber and adjacent lucent space, to estimate the optical resolution. While contrast is a highly subjective evaluation, [Workman and Brettle, 1997] it is easier to detect lines of constant frequency than an irregular object such as a natural caries lesion. The fact that the TI system performed well under laboratory conditions indicates that it warrants further investigation, *e.g.* similar studies on teeth with natural caries lesions.

The spatial resolution results in **Paper IV** cannot be compared with those of other TI systems, as there appear to be no previously published studies. The literature is, however, more extensive regarding digital oral radiographic systems where spatial frequency is one of the parameters used to describe image quality. Kashima [1995] reported that for dentistry, the minimum spatial frequency for producing diagnostically acceptable intraoral x-ray images was between 2 and 5 LP/mm, depending on the radiographic details being investigated. There are studies assessing the diagnostic accuracy of digital imaging systems for the detection of caries lesions using spatial frequency and in general the greater the number of LP/mm the better. These reports cannot be considered as a comparison of the effect of diagnostic accuracy and the theoretical spatial resolution *per se* is not related to improved detection of caries [Li et al., 2008]. As with all imaging systems, the image and consequently, the diagnosis, needs to be consistent.

Although the *in vitro* reliability for the analytical stage was excellent, further studies are required with several operators analysing TI images on several computer screens, evaluating the importance of differences in sample characteristics and of variation in image capturing procedure.

An important advantage of the TI method is that the tooth can be illuminated repeatedly without exposure to ionising radiation. A further advantage is that the method allows the use of miniature- or fiber-coupled light sources and imaging cameras. *In vivo* this should allow repeated projection onto the tooth to estimate the location of the caries lesion on the approximal surface from the ratio between the modulations of images captured from opposite sides of the tooth. In the *in vitro* measurements in **Paper IV**, the estimated error was ± 0.5 mm when the caries

image traversed ~4.6 mm of sound enamel, potentially corresponding to a total tooth thickness in excess of 9 mm. This compares favorably with the DIFOTI method [Schneiderman et al., 1997] which utilizes wavelengths in the visible range (400-700 nm) and therefore is highly limited by strong light scattering, making it difficult image through more than 1 or 2 mm of tooth structure [Darling and Fried, 2008].

CONCLUSIONS

The studies undertaken in the present thesis to evaluate the application of optical techniques for caries detection highlight the importance of rigorous clinical studies to confirm promising laboratory results. New methods should be critically appraised according to strict criteria. Based on the four studies, it may be concluded that:

- Clinical evaluation of the LF method could not confirm the high validity previously reported in *in vitro* studies for occlusal caries detection.
- Validation of the LF method for root caries detection disclosed an extremely low correlation between LF readings and histopathological lesion depth, *in vitro*. The instrument is therefore highly questionable for root caries detection.
- The correlation between readings from the LF device and the reference standard, QLF, was acceptable. The QLF with its closer correlation to the enamel mineral content remains the preferred method for quantification of white spot lesion on smooth surfaces.
- QLF is appropriate for *in vivo* monitoring of small changes (ΔF and lesion area) in white spot enamel lesions and useful for the evaluation of preventive measures in caries-susceptible individuals.
- When illuminated through dental enamel, the novel TI imaging system disclosed extremely small features, clearly detectable in resultant images. Reduction of modulation indicated the relative position of a simulated approximal caries lesion in thin tooth sections.

In their present form, neither of the two established optical methods evaluated in this thesis can be regarded as ideal for clinical application. The initial laboratory tests of TI have shown promising results and further development of the method is warranted.

TILLKÄNNAGIVANDEN

Denna avhandling har blivit möjlig tack vare ekonomiskt stöd från Karolinska Institutet och institutionen för odontologi, Patentmedelsfonden för odontologisk profylaxforskning, GABA International, Schweiz och Universidade Federal of Pernambuco, Recife, Brasilien.

Att genomföra en doktorsavhandling är en lång och stundtals svårnavigerad process och på intet sätt en ensamsegling. Det har varit ett privilegium att arbeta med och fått stöd utav så många kloka, intresserade, generösa och hjälpsamma människor. Vill tacka er alla, kollegor, patienter, familj och vänner – den här avhandlingen är också delvis eran.

Ett särskilt tack riktas till:

Sofia, inte bara har du visat ett utmärkt handledarskap, du har dessutom varit en sann vän under flera år. Denna kombination, handledarskap – vän kan vara svår att balansera. Du har bevisat att så är möjligt. Med kunskap, entusiasm och stöd när jag kroknat har du baxat mig hela vägen fram.

Walter, det är en ynnest att få arbeta med en sådan begåvad person. Med ditt aldrig sinande tålamod har du tagit ett stort ansvar och lotsat mig igenom 'hyperbolic functions' och andra obegripligheter. Du har med tilltro till bärigheten i mina texter ledsagat mig i delarbete IV. Tack för att du orkade.

Jan, för ditt stöd och för att välvilligt delat med dig utav din tid och ditt breda vetenskapligt kunnande till delarbete II. Tack för att du ombesörjt så att jag har haft tillgång till bra arbetsutrustning och för att du generöst berett mig möjligheten att delta i nationella och internationella forskarkonferenser och studieresor.

Birgit Angmar-Månsson, min mentor, för att du introducerade mig till forskningsvärden och gav mig möjlighet att starta denna spännande resa. Du, **Gunilla Johnson, Joan Bevenius och Heléne Almqvist** är starka, kloka kvinnor samt goda förebilder som fått mig att utmana mig själv och lita till min förmåga. Ett speciellt tack till dig **Joan** för gedigen språkbearbetning som inte bara innefattade rättstavning

och grammatikkontroll. *You're an excellent Master Chef: your apprentices do the hard work and then you come along and garnish the dish with a sprig of parsley, contributing to a tasteful dish, i.e. the thesis.* Ansvaret för de återstående bristerna i denna avhandling ligger helt och hållet hos mig.

Lars-Erik Lindgren, alltid lika snäll, omtänksam och arbetsvillig. Utan din stora insats hade inte "Lasse-studien" (dvs. delarbete I) eller delarbete II varit möjligt. **Folke Lagerlöf**, du livs levande Wikipedia som kan det mesta om väldigt mycket. Tack för att du alltid generöst delar med dig utav din kunskap och erfarenhet och för många års gott samarbete.

Mina vänner, nuvarande och f.d. kollegor på forskningsavdelningen **Karin, Hong, Heiða, Peggy, Aron, Margret, Anna P, Anna K, Tove, Tülay**. För omtanke, stöd och att ni har stått ut och fortsatt att fråga om jag vill följa med och äta lunch, fika etc. trots att jag allt som oftast suttit arbetandes bakom en stängd dörr och varit allmänt otillgänglig, fåordig och trist. Tack också till **alla kollegor** på enheten för cariologi, det är till stor del er förtjänst att jag trivts så bra med mitt arbete under alla år. **Kåre**, för att du alltid arbetar och finns när man vill chit-chatta.

Professor **Anderson Gomes** for generously putting your laboratory resources of the Department of Physics, Universidade Federal of Pernambuco, at my disposal. I am indebted to you, your lovely wife Dalva and your friends for your warmth and hospitality during my research visit, making my stay unforgettable.

Ph.D. student **Ana Marly Araújo Maia** for excellent collaboration, without your hard work there would have been no paper IV. Thanks for your friendship and putting up with my sometimes confusing chats on Skype.

Jag hade aldrig haft kraft att genomföra min forskarutbildning om jag inte hade haft alla mina vänner utanför akademien: **Eva J, Mia P, Hasse, Sanne, Nina, Stefan, Jenny, Ingela J, Anita, Annette, Inger, Monica, Lena J, innebandymammorna** och många, många fler. Tack vare er har jag fått äta god mat, druckit mycket vin, dansat, skrattat, sett på film ... ja, allt det där som gör att man orkar lite till.

Tack **Micke** för att du har delat glädjeämnen och vedermödor.

Mina föräldrar **Ann** och **Gunnar** för att ni är de bästa föräldrar som önskas kan. Ni har oftast med stolthet men ibland med viss skepsis följt mina förehavanden men alltid hjälpt och stöttat mig oavsett vad. Jag kan inte tacka er nog. Bror **Claes** och syskonbarnen **Pontus** och **Hanna**, för att ni finns i min närhet.

William och **Vega**, mina stoltheter och ojämförligt de största glädjekällorna i mitt liv.

REFERENCES

- Abalos C, Herrera M, Jimenez-Planas A, Llamas R: Performance of laser fluorescence for detection of occlusal dentinal caries lesions in permanent molars: an in vivo study with total validation of the sample. *Caries Res* 2009;43:137-141.
- Akarsu S, Koprulu H: In vivo comparison of the efficacy of DIAGNOdent by visual inspection and radiographic diagnostic techniques in the diagnosis of occlusal caries. *J Clin Dent* 2006;17:53-58.
- al-Khateeb S, ten Cate JM, Angmar-Månsson B, de Josselin de Jong E, Sundström G, Exterkate RA, Oliveby A: Quantification of formation and remineralization of artificial enamel lesions with a new portable fluorescence device. *Adv Dent Res* 1997;11:502-506.
- Aljehani A, Bamzahir M, Yousif MA, Shi XQ: In vivo reliability of an infrared fluorescence method for quantification of carious lesions in orthodontic patients. *Oral Health Prev Dent* 2006;4:145-150.
- Altman DG, Bland JM: Diagnostic tests. 1: Sensitivity and specificity. *BMJ* 1994;308:1552.
- Andersson A, Sköld-Larsson K, Hallgren A, Petersson LG, Twetman S: Effect of a dental cream containing amorphous cream phosphate complexes on white spot lesion regression assessed by laser fluorescence. *Oral Health Prev Dent* 2007;5:229-233.
- Angmar-Månsson B: How to measure the effects of fluoride treatments in clinical trials? Assessment: modern versus traditional methods. *Caries Res* 2001;35 Suppl 1:30-33.
- Angmar-Månsson B, al-Khateeb S, Tranæus S: Monitoring the caries process. Optical methods for clinical diagnosis and quantification of enamel caries. *Eur J Oral Sci* 1996;104:480-485.
- Angmar-Månsson B, ten Bosch JJ: Advances in methods for diagnosing coronal caries - a review. *Adv Dent Res* 1993;7:70-79.
- Angmar-Månsson B, ten Bosch JJ: Quantitative light-induced fluorescence (QLF): a method for assessment of incipient caries lesions. *Dentomaxillofac Radiol* 2001;30:298-307.

- Angnes V, Angnes G, Batistella M, Grande RH, Loguercio AD, Reis A: Clinical effectiveness of laser fluorescence, visual inspection and radiography in the detection of occlusal caries. *Caries Res* 2005;39:490-495.
- Anttonen V, Seppa L, Hausen H: Clinical study of the use of the laser fluorescence device DIAGNOdent for detection of occlusal caries in children. *Caries Res* 2003;37:17-23.
- Anttonen V, Seppa L, Hausen H: A follow-up study of the use of DIAGNOdent for monitoring fissure caries in children. *Community Dent Oral Epidemiol* 2004;32:312-318.
- Arneberg P, Hossain AN, Jokstad A: Fluoride tablet programs in healthy elderly subjects: distribution of fluoride in saliva and plaque with tablets in different sites. *Acta Odontol Scand* 2005;63:65-72.
- Artun J, Thylstrup A: Clinical and scanning electron microscopic study of surface changes of incipient caries lesions after debonding. *Scand J Dent Res* 1986;94:193-201.
- Astvaldsdóttir A, Holbrook WP, Tranæus S: Consistency of DIAGNOdent instruments for clinical assessment of fissure caries. *Acta Odontol Scand* 2004;62:193-198.
- Avlund K, Holm-Pedersen P, Morse DE, Viitanen M, Winblad B: Tooth loss and caries prevalence in very old Swedish people: the relationship to cognitive function and functional ability. *Gerodontology* 2004;21:17-26.
- Backer Dirks O: Post-eruptive changes in dental enamel. *J Dent Res* 1966;503-511.
- Bader JD, Shugars DA: A systematic review of the performance of a laser fluorescence device for detecting caries. *J Am Dent Assoc* 2004;135:1413-1426.
- Bader JD, Shugars DA: The evidence supporting alternative management strategies for early occlusal caries and suspected occlusal dentinal caries. *J Evid Based Dent Pract* 2006;6:91-100.
- Bader JD, Shugars DA, Bonito AJ: Systematic reviews of selected dental caries diagnostic and management methods. *J Dent Educ* 2001;65:960-968.
- Bader JD, Shugars DA, Bonito AJ: A systematic review of the performance of methods for identifying carious lesions. *J Public Health Dent* 2002;62:201-213.
- Bamzahim M, Aljehani A, Shi XQ: Clinical performance of DIAGNOdent in the detection of secondary carious lesions. *Acta Odontol Scand* 2005;63:26-30.

- Banting DW: The diagnosis of root caries. *J Dent Educ* 2001;65:991-996.
- Baysan A, Lynch E, Ellwood R, Davies R, Petersson L, Borsboom P: Reversal of primary root caries using dentifrices containing 5,000 and 1,100 ppm fluoride. *Caries Res* 2001;35:41-46.
- Benedict H: Note on the fluorescence of teeth in ultra-violet rays. *Science* 1928;67:442.
- Bin-Shuwaish M, Yaman P, Dennison J, Neiva G: The correlation of DIFOTI to clinical and radiographic images in Class II carious lesions. *J Am Dent Assoc* 2008;139:1374-1381.
- Bjelkhagen H, Sundström F, Angmar-Månsson B, Rydén H: Early detection of enamel caries by the luminescence excited by visible laser light. *Swed Dent J* 1982;6(1):1-7.
- Bland JM, Altman DG: Measuring agreement in method comparison studies. *Stat Methods Med Res* 1999;8:135-160.
- Borisova E, Uzunov T, Avramov L: Laser-induced autofluorescence study of caries model in vitro. *Lasers Med Sci* 2006;21:34-41.
- Borsboom PC, Wolfs BH, Leydsman H, Doorn N, ten Bosch JJ, Liem KG: A machine for sawing 80-micrometer slices of carious enamel. *Stain Technol* 1987;62:119-125.
- Buhler CM, Ngaothepitak P, Fried D: Imaging of occlusal dental caries (decay) with near-IR light at 1310-nm. *Optics Express* 2005;13:573-582.
- Chesters RK, Ellwood RP, Biesbrock AR, Smith SR: Potential modern alternative designs for caries clinical trials (CCTs) and how these can be validated against the conventional model. *J Dent Res* 2004;83 Spec No C:C122-124.
- Choo-Smith LP, Dong CC, Cleghorn B, Hewko M: Shedding new light on early caries detection. *J Can Dent Assoc* 2008;74:913-918.
- Chu CH, Lo EC, You DS: Clinical diagnosis of fissure caries with conventional and laser-induced fluorescence techniques. *Lasers Med Sci* 2009: Mar 4.
- Darling CL, Fried D: Optical properties of natural caries lesions in dental enamel at 1310-nm; in P Rechmann, D Fried, (eds): *Conference on Lasers in Dentistry XI*. San Jose, CA, Spie-Int Soc Optical Engineering, 2005, pp 102-110.
- Darling CL, Fried D: Real-time near IR (1310 nm) imaging of CO2 laser ablation of enamel. *Optics Express* 2008;16:2685-2693.
- Darling CL, Huynh GD, Fried D: Light scattering properties of natural and artificially demineralized dental enamel at 1310 nm. *J Biomed Opt* 2006;11:34023.

- de Josselin de Jong E, Sundström F, Westerling H, Tranæus S, ten Bosch JJ, Angmar-Månsson B: A new method for in vivo quantification of changes in initial enamel caries with laser fluorescence. *Caries Res* 1995;29:2-7.
- Ekstrand KR, Ricketts DN, Kidd EA, Qvist V, Schou S: Detection, diagnosing, monitoring and logical treatment of occlusal caries in relation to lesion activity and severity: an in vivo examination with histological validation. *Caries Res* 1998;32:247-254.
- Featherstone JD: Prevention and reversal of dental caries: role of low level fluoride. *Community Dent Oral Epidemiol* 1999;27:31-40.
- Featherstone JD: Dental caries: a dynamic disease process. *Aust Dent J* 2008;53:286-291.
- Fejerskov O, Kidd E: *Dental Caries: The Disease and Its Clinical Management*, 2nd Edition. 2008;Copenhagen, Denmark. Blackwell Munksgaard, 2008:Chapter IV.
- Feltz JC, Karim MA: Modulation transfer function of charge-coupled devices. *Appl Opt* 1990;29:717-722.
- Feng Y, Yin W, Hu D, Zhang YP, Ellwood RP, Pretty IA: Assessment of autofluorescence to detect the remineralization capabilities of sodium fluoride, monofluorophosphate and non-fluoride dentifrices. A single-blind cluster randomized trial. *Caries Res* 2007;41:358-364.
- Fried D, Glens RE, Featherstone JDB, Seka W: Nature of light scattering in dental enamel and dentin at visible and near-infrared wavelengths. *Appl Opt* 1995;34:1278-1285.
- Fure S: Five-year incidence of coronal and root caries in 60-, 70- and 80-year-old Swedish individuals. *Caries Res* 1997;31:249-258.
- Fure S: Ten-year incidence of tooth loss and dental caries in elderly Swedish individuals. *Caries Res* 2003;37:462-469.
- Fure S: Ten-year cross-sectional and incidence study of coronal and root caries and some related factors in elderly Swedish individuals. *Gerodontology* 2004;21:130-140.
- Gilbert GH, Duncan RP, Dolan TA, Foerster U: Twenty-four month incidence of root caries among a diverse group of adults. *Caries Res* 2001;35:366-375.
- Gmur R, Giertsen E, van der Veen MH, de Josselin de Jong E, ten Cate JM, Guggenheim B: In vitro quantitative light-induced fluorescence to measure changes in enamel mineralization. *Clin Oral Investig* 2006;10:187-195.

- Gostanian HV, Shey Z, Kasinathan C, Caceda J, Janal MN: An in vitro evaluation of the effect of sealant characteristics on laser fluorescence for caries detection. *Pediatr Dent* 2006;28:445-450.
- Griffin SO, Griffin PM, Swann JL, Zlobin N: Estimating rates of new root caries in older adults. *J Dent Res* 2004;83:634-638.
- Hall A, Girkin JM: A review of potential new diagnostic modalities for caries lesions. *J Dent Res* 2004;83 Spec No C:C89-94.
- Heinrich-Weltzien R, Kuhnisch J, Oehme T, Ziehe A, Stosser L, Garcia-Godoy F: Comparison of different DIAGNOdent cut-off limits for in vivo detection of occlusal caries. *Oper Dent* 2003a;28:672-680.
- Heinrich-Weltzien R, Kuhnisch J, van der Veen M, de Josselin de Jong E, Stosser L: Quantitative light-induced fluorescence (QLF)-a potential method for the dental practitioner. *Quintessence Int* 2003b;34:181-188.
- Hibst R, Gall R: Development of a diode laser-based fluorescence caries detector. *Caries Res* 1998;32:294.
- Hopcraft MS, Morgan MV: Comparison of radiographic and clinical diagnosis of approximal and occlusal dental caries in a young adult population. *Community Dent Oral Epidemiol* 2005;33:212-218.
- Hugoson A, Koch G, Göthberg C, Helkimo AN, Lundin SA, Norderyd O, Sjödin B, Sundell K: Oral health of individuals aged 3-80 years in Jönköping, Sweden during 30 years (1973-2003) - II. Review of clinical and radiographic findings. *Swed Dent J* 2005;29:139-155.
- Huth KC, Neuhaus KW, Gygax M, Bucher K, Crispin A, Paschos E, Hickel R, Lussi A: Clinical performance of a new laser fluorescence device for detection of occlusal caries lesions in permanent molars. *J Dent* 2008;36:1033-1040.
- Johnson G, Almqvist H: Non-invasive management of superficial root caries lesions in disabled and infirm patients. *Gerodontology* 2003;20:9-14.
- Jones RS, Huynh GD, Jones GC, Fried D: Near-infrared transillumination at 1310-nm for the imaging of early dental decay. *Optics Express* 2003;11:2259-2265.
- Karlsson L, Angmar-Månsson B, Tranæus S: Infrared fluorescence measurements – The influence of calibration frequency on longitudinal in vitro measurements with KaVo DIAGNOdent. *International Journal of Dental Hygiene* 2004;2:142-143.
- Karlsson L, Tranæus S: Supplementary Methods for Detection and Quantification of Dental Caries. *J Laser Dent* 2008;16:8-16.

- Kashima I: Computed radiography with photostimulable phosphor in oral and maxillofacial radiology. *Oral Surg Oral Med Oral Pathol Oral Radiol Endod* 1995;80:577-598.
- Khalife MA, Boynton JR, Dennison JB, Yaman P, Hamilton JC: In vivo evaluation of DIAGNOdent for the quantification of occlusal dental caries. *Oper Dent* 2009;34:136-141.
- Kielbassa AM, Gillmann L, Zantner C, Meyer-Lueckel H, Hellwig E, Schulte-Monting J: Profilometric and microradiographic studies on the effects of toothpaste and acidic gel abrasivity on sound and demineralized bovine dental enamel. *Caries Res* 2005;39:380-386.
- Kronenberg O, Lussi A, Ruf S: Preventive effect of ozone on the development of white spot lesions during multibracket appliance therapy. *Angle Orthod* 2009;79:64-69.
- Kuhnisch J, Bucher K, Hickel R: The intra/inter-examiner reproducibility of the new DIAGNOdent Pen on occlusal sites. *J Dent* 2007;35:509-512.
- Kuhnisch J, Ziehe A, Brandstadt A, Heinrich-Weltzien R: An in vitro study of the reliability of DIAGNOdent measurements. *J Oral Rehabil* 2004;31:895-899.
- Leake JL: Clinical decision-making for caries management in root surfaces. *J Dent Educ* 2001;65:1147-1153.
- Li G, Berkhout WE, Sanderink GC, Martins M, van der Stelt PF: Detection of in vitro proximal caries in storage phosphor plate radiographs scanned with different resolutions. *Dentomaxillofac Radiol* 2008;37:325-329.
- Luan WM, Baelum V, Fejerskov O, Chen X: Ten-year incidence of dental caries in adult and elderly Chinese. *Caries Res* 2000;34:205-213.
- Lussi A: Validity of diagnostic and treatment decisions of fissure caries. *Caries Res* 1991;25:296-303.
- Lussi A, Hellwig E: Performance of a new laser fluorescence device for the detection of occlusal caries in vitro. *J Dent* 2006;34:467-471.
- Lussi A, Hibst R, Paulus R: DIAGNOdent: an optical method for caries detection. *J Dent Res* 2004;83 Spec No C:C80-83.
- Lussi A, Megert B, Longbottom C, Reich E, Francescut P: Clinical performance of a laser fluorescence device for detection of occlusal caries lesions. *European Journal of Oral Sciences* 2001;109:14-19.

- Mejäre I, Källestål C, Stenlund H: Incidence and progression of approximal caries from 11 to 22 years of age in Sweden: A prospective radiographic study. *Caries Res* 1999;33:93-100.
- Mejäre I, Källestål C, Stenlund H, Johansson H: Caries development from 11 to 22 years of age: a prospective radiographic study. Prevalence and distribution. *Caries Res* 1998;32:10-16.
- Mejäre I, Stenlund H, Zelezny-Holmlund C: Caries incidence and lesion progression from adolescence to young adulthood: a prospective 15-year cohort study in Sweden. *Caries Res* 2004;38:130-141.
- Morse DE, Holm-Pedersen P, Holm-Pedersen J, Katz RV, Viitanen M, von Strauss E, Winblad B: Prosthetic crowns and other clinical risk indicators of caries among old-old Swedish adults: findings from the KEOHS Project. *Kungsholmen Elders Oral Health Study. Gerodontology* 2002;19:73-79.
- Neuhaus KW, Longbottom C, Ellwood R, Lussi A: Novel Lesion Detection Aids. *Monogr Oral Sci* 2009;21:52-62.
- Nyvad B, Fejerskov O: Active Root Surface Caries Converted into Inactive Caries as a Response to Oral Hygiene. *Scand J Dent Res* 1986;94:281-284.
- Park SK, Schowengerdt R, Kaczynski M-A: Modulation-transfer-function analysis for sampled image systems. *Appl Opt* 1984;23:2572-2582.
- Pereira AC, Eggertsson H, Martinez-Mier EA, Mialhe FL, Eckert GJ, Zero DT: Validity of caries detection on occlusal surfaces and treatment decisions based on results from multiple caries-detection methods. *Eur J Oral Sci* 2009;117:51-57.
- Petersen PE, Bourgeois D, Ogawa H, Estupinan-Day S, Ndiaye C: The global burden of oral diseases and risks to oral health. *Bull World Health Organ* 2005;83:661-669.
- Pitts NB: Patient caries status in the context of practical, evidence-based management of the initial caries lesion. *J Dent Educ* 1997;61:861-865.
- Pitts NB, Stamm JW: International Consensus Workshop on Caries Clinical Trials (ICW-CCT)--final consensus statements: agreeing where the evidence leads. *J Dent Res* 2004;83 Spec No C:C125-128.
- Pretty IA: Caries detection and diagnosis: novel technologies. *J Dent* 2006;34:727-739.

- Pretty IA, Maupome G: A closer look at diagnosis in clinical dental practice: part 5. Emerging technologies for caries detection and diagnosis. *J Can Dent Assoc* 2004;70:540, 540a-540i.
- Reis A, Mendes FM, Angnes V, Angnes G, Grande RH, Loguercio AD: Performance of methods of occlusal caries detection in permanent teeth under clinical and laboratory conditions. *J Dent* 2006;34:89-96.
- Ridell K, Olsson H, Mejäre I: Unrestored dentin caries and deep dentin restorations in Swedish adolescents. *Caries Res* 2008;42:164-170.
- Rocha RO, Ardenghi TM, Oliveira LB, Rodrigues CR, Ciamponi AL: In vivo effectiveness of laser fluorescence compared to visual inspection and radiography for the detection of occlusal caries in primary teeth. *Caries Res* 2003;37:437-441.
- Rosén B, Birkhed D, Nilsson K, Olavi G, Egelberg J: Reproducibility of clinical caries diagnoses on coronal and root surfaces. *Caries Res* 1996;30:1-7.
- Schaeken MJM, Keltjens H, Vanderhoeven JS: Effects of Fluoride and Chlorhexidine on the Microflora of Dental Root Surfaces and Progression of Root-Surface Caries. *J Dent Res* 1991;70:150-153.
- Schneiderman A, Elbaum M, Shultz T, Keem S, Greenebaum M, Driller J: Assessment of dental caries with Digital Imaging Fiber-Optic Transillumination (DIFOTI): in vitro study. *Caries Res* 1997;31:103-110.
- Schupbach P, Lutz F, Guggenheim B: Human Root Caries - Histopathology of Arrested Lesions. *Caries Res* 1992;26:153-164.
- Selwitz RH, Ismail AI, Pitts NB: Dental caries. *Lancet* 2007;369:51-59.
- Shay K: The evolving impact of aging America on dental practice. *J Contemp Dent Pract* 2004;5:101-110.
- Sköld-Larsson K, Fornell AC, Lussi A, Twetman S: Effect of topical applications of a chlorhexidine/thymol-containing varnish on fissure caries assessed by laser fluorescence. *Acta Odontol Scand* 2004;62:339-342.
- Stookey G: Proceedings of the first annual Indiana Conference: Early detection of dental caries. Indiana University School of Dentistry, Indiana, USA 1996.
- Stookey G: Proceedings of the second annual Indiana Conference: Early detection of dental caries. Indiana University School of Dentistry, Indiana, USA 2000.
- Stookey G: Proceedings of the third annual Indiana Conference: Early detection of dental caries. Indiana University School of Dentistry, Indiana, USA 2004a.

- Stookey GK: Optical methods--quantitative light fluorescence. *J Dent Res* 2004b;83 Spec No C:C84-88.
- Stookey GK, Gonzalez-Cabezas C: Emerging methods of caries diagnosis. *J Dent Educ* 2001;65:1001-1006.
- Sundström F, Fredriksson K, Montan S, Hafström-Björkman U, Ström J: Laser-induced fluorescence from sound and carious tooth substance: spectroscopic studies. *Swed Dent J* 1985;9:71-80.
- The Swedish Council on Technology Assessment in Health Care: Karies - diagnostik, riskbedömning och icke-invasiv behandling. 2007;nr 188:84.
- The Swedish Council on Technology Assessment in Health Care: Caries – Diagnosis, Risk Assessment and Non-Invasive Treatment 2008;no 510-39.
- Thomson WM: Dental caries experience in older people over time: what can the large cohort studies tell us? *Br Dent J* 2004;196:89-92; discussion 87.
- Tranæus S, Al-Khateeb S, Björkman S, Twetman S, Angmar-Månsson B: Application of quantitative light-induced fluorescence to monitor incipient lesions in caries-active children. A comparative study of remineralisation by fluoride varnish and professional cleaning. *Eur J Oral Sci* 2001a;109:71-75.
- Tranæus S, Heinrich-Weltzien R, Kuhnisch J, Stösser L, Angmar-Månsson B: Potential applications and limitations of Quantitative Light-induced fluorescence in dentistry. *Med Laser Appl* 2001b;16:195-204.
- Tranæus S, Shi XQ, Angmar-Månsson B: Caries risk assessment: methods available to clinicians for caries detection. *Community Dent Oral Epidemiol* 2005;33:265-273.
- Tveit AB, Espelid I, Fjellveit A: Clinical diagnosis of occlusal dentin caries. *Caries Res* 1994;28:368-372.
- US Department of Health and Human Services: Oral Health in America: A Report of the Surgeon General-- Executive Summary. Rockville, MD: US Department of Health and Human Services, National Institute of Dental and Craniofacial Research, National Institutes of Health 2000:66-67.
- van der Veen MH, de Josselin de Jong E: Application of quantitative light-induced fluorescence for assessing early caries lesions. *Monogr Oral Sci* 2000;17:144-162.
- Wicht MJ, Haak R, Stutzer H, Strohe D, Noack MJ: Intra- and interexaminer variability and validity of laser fluorescence and electrical resistance readings on root surface lesions. *Caries Res* 2002;36:241-248.

- Workman A, Brettle DS: Physical performance measures of radiographic imaging systems. *Dentomaxillofac Radiol* 1997;26:139-146.
- Wu J, Fried D: High contrast near-infrared polarized reflectance images of demineralization on tooth buccal and occlusal surfaces at $\lambda = 1310\text{-nm}$. *Lasers Surg Med* 2009;41:208-213.
- Yang J, Dutra V: Utility of radiology, laser fluorescence, and transillumination. *Dent Clin North Am* 2005;49:739-752, vi.
- Young DA: New caries detection technologies and modern caries management: merging the strategies. *Gen Dent* 2002;50:320-331.
- Young DA, Featherstone JD: Digital imaging fiber-optic trans-illumination, F-speed radiographic film and depth of approximal lesions. *J Am Dent Assoc* 2005;136:1682-1687.
- Zantner C, Martus P, Kielbassa AM: Clinical monitoring of the effect of fluorides on long-existing white spot lesions. *Acta Odontol Scand* 2006;64:115-122.
- Zandona AF, Zero DT: Diagnostic tools for early caries detection. *J Am Dent Assoc* 2006;137:1675-1684.
- Zhang W, McGrath C, Lo EC: A comparison of root caries diagnosis based on visual-tactile criteria and DIAGNOdent in vivo. *J Dent* 2009;37:509-513.
- Zijp JR: Optical properties of dental hard tissue. Thesis, Rijksuniversiteit Groningen, The Netherlands 2001:Chapter 1, Introduction.

