

Prevention of complications in pediatric cataract surgery

Maria Kugelberg



Department of Clinical Neuroscience

Division of Ophthalmology

St. Erik's Eye Hospital, Karolinska Institute, Stockholm,

Sweden

December 2004

All previously published papers were reproduced with permission from the publisher.

Published and printed by Karolinska University Press

Box 200, SE-171 77 Stockholm, Sweden

© Maria Kugelberg, 2004

ISBN 91-7140-111-3

1 Contents

1	<i>Contents</i>	4
2	<i>Summary</i>	6
3	<i>Popular summary in Swedish</i>	8
4	<i>List of papers</i>	11
5	<i>Abbreviations</i>	12
6	<i>Introduction</i>	13
6.1	Background	13
6.2	Congenital cataract	13
6.3	Surgery for congenital cataract	14
6.3.1	Animal model	15
6.3.2	Optical Correction	15
6.4	After-cataract	16
6.4.1	Surgical techniques	17
6.5	Secondary glaucoma	18
6.6	Systemic uptake from topical administration	18
6.6.1	Glucocorticoid induced growth inhibition	19
6.6.2	Glucocorticoid induced osteoporosis	20
7	<i>Aims</i>	21
8	<i>Materials and methods</i>	22
8.1	Subjects and methods (I)	22
8.1.1	Surgery	22
8.1.2	Follow-up	22
8.1.3	Statistics	22
8.2	Subjects and methods (II)	23
8.2.1	Surgery	23
8.2.2	Follow-up	23
8.2.3	Evaluation of Posterior Capsule Opacification (EPCO)	23

8.2.4	Rhexis position _____	24
8.2.5	Statistics _____	24
8.3	Animal model and methods (III, IV, V) _____	25
8.3.1	Animals _____	25
8.3.2	Surgery _____	25
8.3.3	Postoperative treatment (III) _____	25
8.3.4	Postoperative treatment (IV, V) _____	26
8.3.5	Measurements (III) _____	26
8.3.6	Measurements (IV) _____	26
8.3.7	Dual X-ray Absorptiometry (DXA) (V) _____	27
8.3.8	Peripheral Quantitative Computerized Tomography (pQCT) (V) _____	27
8.3.9	Statistics (III) _____	27
8.3.10	Statistics (IV) _____	27
8.3.11	Statistics (V) _____	28
9	Results and discussion _____	29
9.1	Surgical technique (I, II) _____	29
9.2	IOL in small eyes (III) _____	34
9.3	Topical glucocorticoids, growth retardation and bone parameters (IV, V) _____	37
10	Conclusions _____	42
11	Future projects _____	43
12	Acknowledgements _____	44
13	References _____	46
14	Papers I-V _____	55

2 Summary

This thesis was performed to find ways to lessen the complications to pediatric cataract surgery, which is an increasingly safe procedure, also in infants. However, there are some complications to the surgery, which threatens the visual development. The most common complication is after-cataract. The most feared complication is secondary glaucoma, which is hard to manage, and can lead to blindness and a cosmetically disturbing eye.

The younger the infant is at surgery, the higher the risk of secondary glaucoma, and the more the after-cataract develops. The children must have surgery early in life though, to avoid irreversible amblyopia.

The first study is a retrospective evaluation of a new surgical technique that was developed to inhibit after-cataract. A dry anterior vitrectomy was performed after implantation of the intraocular lens (IOL), through the anterior chamber. The study showed that an anterior vitrectomy was needed in younger children, below the age of seven. In older children, anterior vitrectomy was not necessary. It also showed that an AcrySof IOL seems to be a better choice in the pediatric eye than an HSM-PMMA IOL since patients implanted with the first IOL developed less after-cataract.

The second study is a prospective randomised study of the same surgical method used in the first study. Children aged 3-15 years in Ukraine received cataract surgery with posterior capsulorhexis, with or without anterior vitrectomy and were implanted with a single-piece AcrySof SA30AL IOL. The IOL stayed centered and fitted well into the pediatric eye. Results showed that anterior vitrectomy was advantageous in younger children, approximately below the age of five years, concerning after-cataract.

In the third study we evaluated a single-piece IOL in the small eyes of newborn rabbits, which have an anterior segment approximately the same size as the newborn child. The results showed the AcrySof SA30AT IOL seems to inhibit secondary glaucoma compared to aphakic eyes, lessen the total amount of after-cataract compared to aphakic eyes, and it also makes the eye grow better than most intraocular lenses studied in this animal model.

The cause of secondary glaucoma is yet not fully understood. It might be the strong postoperative inflammatory response in the smallest children that causes synechiae in the chamber angle, thereby the intraocular pressure rises. Treatment with glucocorticoid eye drops would then lessen the secondary glaucoma. However, it is known that treatment with systemic-, peroral-, intranasal- and inhalation glucocorticoids can cause growth retardation in

children. The fourth study in the thesis was performed in the above-mentioned animal model to investigate the effect on growth of topical treatment with glucocorticoids. The results showed that dexamethasone eye drops caused impaired body growth in a dose-dependant way.

In the fifth study the left femurs of the rabbits in the fourth study were analysed with Dual X-ray Absorptiometry and peripheral Quantitative Computerized Tomography to measure different bone parameters. It showed that the glucocorticoid eye drops causes osteoporosis. The rabbits had a dose dependent reduction in bone mineral density, cortical bone mineral content, cortical thickness, femur periosteal and endosteal circumference. This is in accordance with earlier studies when glucocorticoids were given systemically.

3 Popular summary in Swedish

Barn som föds med, eller utvecklar gråstarr inom de första levnadsåren behöver gråstarrskirurgi snarast för att undvika oåterkallelig synnedsättning. Vid gråstarrskirurgin gör man en främre kapsulorexis, dvs river bort den främre delen av linskapseln i ögat, suger ut linsinnehållet samt gör även ett hål i den bakre kapseln. Hos vuxna, och oftast även hos barn ersätts den egna linsen med en konstgjord, så kallad intraokulär lins. Den vanligaste komplikationen efter gråstarrskirurgi är efterstarr. Efterstarr produceras av linsepitel celler, dessa finns normalt i den främre delen av linskapseln, samt vid kapselns ekvator. Efter en gråstarrsoperation växer dessa celler över den bakre kapseln och patienterna ser åter suddigt. Hos vuxna behandlas efterstarr med laserstrålar som skjuter hål i den bakre kapseln, vilken spricker upp, och patienterna ser åter klart.

Barn utvecklar mycket mer, och snabbare efterstarr. De flesta kirurger gör därför på barn och tonåringar även en bakre kapsulorexis, dvs tar bort en bit av den bakre kapseln, så att inte linsepitelcellerna ska kunna växa på denna. Dock räcker detta ändå oftast inte hos mindre barn, utan de utvecklar efterstarr ändå. Hos barn räcker det då oftast inte att behandla efterstarren med laser som man gör hos vuxna, då linsepitel cellerna kan växa även på det främre glaskroppsmembranet eller på den inopererade linsens baksida. De behöver istället en andra operation, då man tar bort den främre delen av glaskroppen. Nya kirurgiska tekniker studeras och provas nu för att undvika att barnen utvecklar efterstarr.

Barnen kan också få det fruktade sekundärglaukomet, dvs tryckstegring i ögat efter gråstarrsoperationen. Sekundärglaukom är svårt att behandla och kan leda till blindhet. Orsaken till sekundärglaukom är ej helt klarlagd. Det skulle kunna vara den postoperativa inflammationen som är mycket kraftigare hos små barn än hos äldre barn, som leder till sammanväxningar i kammarvinkeln och därmed ett ökat tryck i ögat. Inflammationen skulle eventuellt kunna behandlas intensivt med kortisonögondroppar. Dock är det allmänt känt att kortison givet systemiskt, peroralt, och även i inhalationsform och som näsdroppar, kan ge tillväxthämning hos barn. Därför är det av vikt att utvärdera om även ögondroppar innehållande kortison kan ge tillväxthämning.

Nyfödda barn med dubbelsidig gråstarr får ofta ingen intraokulär lins vid den primära operationen, då det inte finns något riktigt bra lins som passar i det lilla ögat. Däremot får nyfödda barn med ensidig sjukdom oftast en lins vid den primära operationen. För att studera komplikationer till gråstarrskirurgi hos barn, använder vi en djurmodell med

tre veckor gamla kaniner, vilka har en ögonstorlek i främre segmentet, motsvarande det hos ett nyfött barn.

Målen med denna avhandling är:

1. Att hämma bildningen av efterstarr hos barn genom att utveckla nya kirurgiska tekniker.
2. Att hitta en optimal intraokulär lins för det nyfödda ögat.
3. Att hindra sekundärglaukom hos barn och att studera komplikationer, i form av tillväxthämning och minskad benträthet, till behandling med kortisonögondroppar i en djurmodell.

Arbete I:

Retrospektiv studie där vi studerade en ny operationsmetod, då man tar bort även den främre glaskroppen vid gråstarrsoperationen (främre vitrektomi), för att hämma efterstarrsbildningen hos barn. Det visade sig att det är fördelaktigt att använda den nya operationsmetoden hos barn som är yngre än sju år.

Arbete II:

Prospektiv randomiserad studie på barn av samma operationsmetod som i arbete I, dvs gråstarrskirurgi med eller utan främre vitrektomi. Det visade sig att yngre barn har en ökad risk för bildning av efterstarr, och att den nya operationsmetoden hämmade efterstarr betydligt. Det är bra att använda operationsmetoden med främre vitrektomi hos yngre barn. I studien implanterades en ny intraokulär lins in i ögonen, en akryllins som är i endast ett material, så kallad single-piece lins. Linsen, AcrySof SA30AL, passade mycket bra i de små ögonen hos barn, inga komplikationer i samband med operationen, eller i det postoperativa förloppet förekom. Inga barn utvecklade sekundärglaukom.

Arbete III:

Som nämnts ovan får små barn med dubbelsidig sjukdom ofta ingen intraokulär lins, eftersom de linser som finns är för stora för ögat hos nyfödda. Linsen kan då bli deformerad och kan okkludera pupillen. Vi utvärderade därför en ny lins, en single-piece AcrySof SA30AT, som skulle kunna passa det lilla ögat. Tre veckor gamla kaniner genomgick klar linsextraktion på bägge ögon och en intraokulär lins implanterades i ena ögat. Vi studerade hur linsen passade i

ögat och mätte olika parametrar för ögats tillväxt. Den intraokulära lins vi utvärderade verkar hämma ögats tillväxt mindre än andra linser, minska förekomsten av sekundärglaukom, ge mindre inflammation än i ett öga som inte har lins, och passa bra i det lilla ögat.

Arbete IV:

För att undersöka de systemiska effekterna av kortisonögondroppar genomförde vi en studie på nyfödda kaniner som genomgått klar linsextraktion på ett öga. En grupp kaniner fick intensiv medicinerings med kortisonögondroppar, en grupp fick hälften av denna dos och hälften placebodroppar, och en grupp fick endast placebodroppar. Effekten av utvärtes kortison utvärderades genom att vi mätte utvecklingen av vikt och längd hos djuren, och vid studiens slut mätte vi längden av vänster lårben samt jämförde gruppernas fettdepåer. De kaniner som fick intensiv medicinerings med kortisonögondroppar växte långsammare, ökade långsammare i vikt, och hade vid studiens slut kortare lårben, vilket är ett ofta använt mått på tillväxt. Det verkar alltså som att kortison i ögondroppar tas upp i blodet i mycket större utsträckning än vad man tidigare vetat.

Arbete V:

I denna studie analyserade vi benparametrar från vänster lårben från studien ovan med olika röntgenmetoder. Det visade sig att kortikala bentätheten, benets tjocklek, omkrets med mera reducerades på samma sätt hos kaniner som fått kortisonögondroppar, som setts tidigare i litteraturen då man gett kortison systemiskt.

Betydelse

Det är viktigt att minska efterstarren hos barn, då behandlingen är ytterligare kirurgi, vilket innebär mer narkos och en ökad risk för barnen. Det är angeläget att hitta en intraokulär lins som passar det lilla ögat, då spädbarnen som genomgår gråstarrskirurgi måste ha kontaktlinser resten av livet, vilket är arbetsamt för familjen och dyrt för sjukvården. Sekundärglaukom kan leda till blindhet, ögat kan bli mycket stort och kosmetiskt störande, varför det är viktigt att hitta orsaken och behandlingen av denna komplikation, och även viktigt att denna behandling i sig inte är skadlig för barnet.

4 List of papers

This thesis is based on the following original articles, referred to in the text by their Roman numerals:

- I. Kugelberg M, Zetterström C. Pediatric cataract surgery with or without anterior vitrectomy. *J Cataract Refract Surg* 2002;28:1770-1773.
- II. Kugelberg M, Kugelberg, U, Bobrova N, Tronina S, Zetterström C. After-cataract in children having cataract surgery with or without anterior vitrectomy, implanted with a single-piece AcrySof[®] IOL. In press *J Cataract Refract Surg* 2004.
- III. Kugelberg M, Shafiei K, Zetterström C. Single-piece AcrySof in the newborn rabbit eye. *J Cataract Refract Surg* 2004;30:1347-1352.
- IV. Kugelberg M, Shafiei K, Ohlsson C, Sävendahl L, Zetterström C. Glucocorticoid eye drops inhibit growth in the newborn rabbit. Submitted.
- V. Kugelberg M, Ohlsson C, Sävendahl L. Reduced bone mineral density and radial bone growth in young rabbits treated with dexamethasone eye drops. In manuscript.

Reprints of papers I-IV were made with permissions from the journals.

5 Abbreviations

BMC	bone mineral content
BMD	bone mineral density
DXA	Dual X-ray Absorptiometry
EPCO	evaluation of posterior capsule opacification
HSM-PMMA	heparin-surface-modified poly(methyl methacrylate)
IOL	intraocular lens
LEC	lens epithelial cell
Nd: YAG	Neodymium: YAG
PFV	peristent foetal vasculature
pQCT	peripheral Quantitative Computerized Tomography

6 Introduction

6.1 Background

In Sweden about 36 children per 100.000 births are born with cataract (Abrahamsson et al. 1999). Unless they have surgery quickly they develop irreversible amblyopia (Awaya et al. 1979, Taylor et al. 1979, Vaegan and Taylor 1979, Dutton et al. 1990). Pediatric cataract surgery is nowadays an increasingly safe procedure, however there are some complications to the surgery. After-cataract is the most common complication, which threatens the vision again and can lead to amblyopia if not managed. Secondary glaucoma is the most feared complication and can lead to blindness and a cosmetically disturbing eye (Lundvall and Kugelberg 2002, Rabiah 2004). It is very hard to treat and often leads to repeated surgical procedures. Developmental cataract, which is not dense at birth, is more common and could be operated on much later. This would lead to fewer complications and a better outcome. The main objective in this thesis was to find ways to diminish the complications in cataract surgery in infants and children, by studying different surgery techniques, a new intraocular lens (IOL), and evaluate the postoperative treatment.

6.2 Congenital cataract

Congenital cataract can be either unilateral or bilateral. It is hereditary in approximately one third of the cases and is often inherited autosomal dominant but can also be inherited autosomal recessive or X-linked. In approximately one third of the cases other diseases can be found. Metabolic disorders, such as galactosaemia and hypocalcaemia are rare causes. Intrauterine infections such as rubella, toxoplasmosis, herpes, varicella and syphilis can cause congenital cataract. Genetic syndromes such as trisomy 21 or Turner's syndrome and a variety of neurological disorders are often associated with congenital cataract. Other ocular anomalies such as iris coloboma, aniridi, microphthalmia, retinopathy of prematurity, or persistent foetal vasculature (PFV) are often combined with cataract. This is of course important to investigate. In the rest of the patients, the congenital cataract is idiopathic. In unilateral cases, the cause is as a rule idiopathic and in a clinically healthy child, or if the cataract is inherited, there is no need for an extensive pre-operative evaluation (Zetterstrom 2000).

5-20% of childhood blindness worldwide is caused by cataracts (Foster and Gilbert 1992). There are different types of cataract; nuclear (figure 1), lamellar, sutural, polar, lenticonus, membranous and associated with PFV.

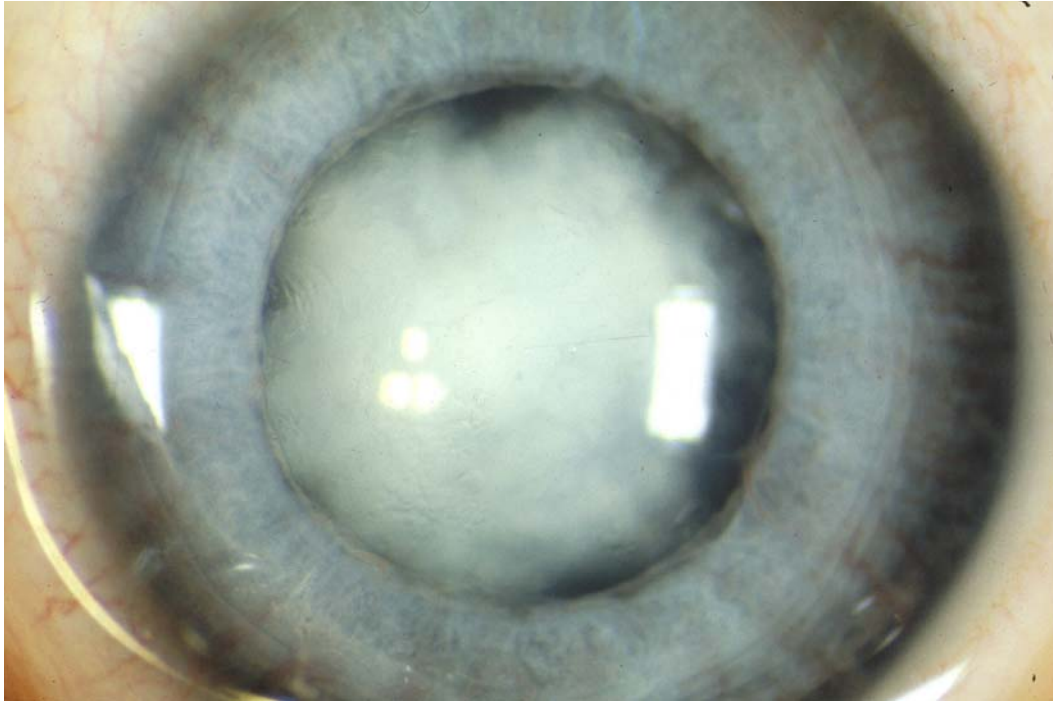


Figure 1. Dense nuclear congenital cataract in a 5-day-old child, immediately before surgery.

The size, density, laterality of the cataract and the presence of associated ocular abnormalities decide how strong the indication is for surgery. The more central and the more posteriorly located, the more visually significant the cataract will be (Fallaha and Lambert 2001). Since there are more complications after early surgery as discussed below, it is important to wait if the cataract is not visually significant.

6.3 Surgery for congenital cataract

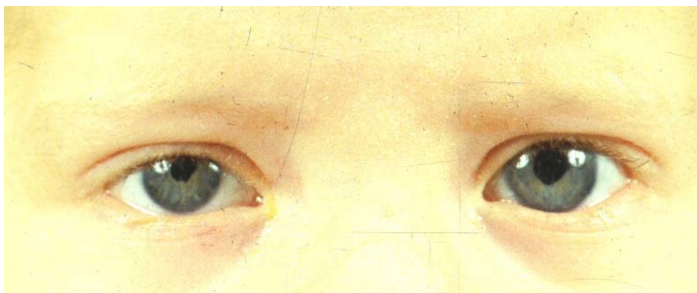

Figure 2. Secondary glaucoma in the left eye.

In cases with dense congenital cataract the cataract surgery must be performed early to prevent irreversible amblyopia and nystagmus (Kugelberg 1992, Birch and Stager 1996, Lundvall and Kugelberg 2002, Lundvall and Kugelberg 2002, Watts et al. 2003).

However, at the same time the risk of secondary glaucoma (figure 2) increases in these very small children. It is therefore very important to find ways to lessen the secondary glaucoma. Also, the after-cataract formation is much more pronounced in the youngest (Alexandrakis et al. 2002).

6.3.1 Animal model

To study different IOLs and treatments after pediatric cataract surgery our group uses a model with three-week-old rabbits, which have about the same size of the anterior segment as the newborn child (Lundgren et al. 1992, Zetterstrom et al. 1996, Kugelberg et al. 1997, Lundvall et al. 2001). Of course, the findings in rabbits can not be directly transferred to humans, however, it is important to study the behaviour of IOLs in the small eye, and the reaction to implants or drugs given in animals, since it is hard to perform controlled, randomised studies directly in the few children with early cataract.

6.3.2 Optical Correction

After pediatric cataract surgery implantation of an IOL is a common and accepted management of aphakia (Zetterstrom 1997, Cavallaro et al. 1998, Lesueur et al. 1998, Zetterstrom and Kugelberg 1998, Zwaan et al. 1998, O'Keefe et al. 2000, Pandey et al. 2001). For the very small eye of an infant most of the commercially available IOLs are too large. A bistable three-piece IOL can then vault and occlude the pupil (figure 3) and cause glaucoma (Lundvall et al. 2003).

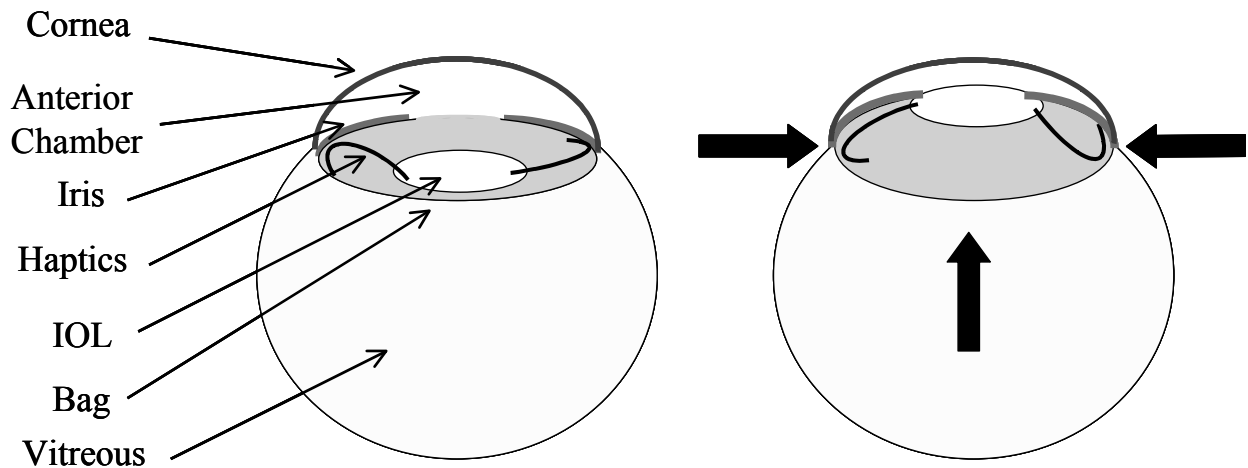


Figure 3. To the left the IOL is pushed back in the lens capsule (bag). To the right the three-piece IOL has vaulted and is pushing the iris forward to the anterior chamber and occludes the pupil, making the anterior chamber shallower.

Also, the haptics may exert too much force and put pressure on the ciliary bodies, which are then damaged (Zetterstrom and Kugelberg 1998). When implanting an IOL in the infant, there is also a problem with the myopic shift that occurs in the child's growing eye (Lambert et al. 1999, McClatchey et al. 2000, Crouch et al. 2002, Weakley et al. 2003). Lately, after surgery for unilateral cataract, many surgeons implant an IOL also in infants. However, for optical correction in bilateral cases with congenital cataract, contact lenses are still most often used in the west world. Contact lenses can cause infection, are sometimes hard to handle, tedious for the family and expensive. There is also bad compliance regarding the use of contact lenses. Therefore it would be of great interest if it were possible to develop an IOL that fits the small eye.

6.4 *After-cataract*

After-cataract is caused when lens epithelial cells (LECs) migrate and proliferate from the anterior capsule and the equator of the lens capsule, onto the posterior capsule (Marcantonio and Vrensen 1999, Spalton 1999). The visual axis is then disturbed, and the vision blurred again. Children develop more and faster after-cataract than adults. After-cataract, or posterior capsule opacification as it is called in adults, can be removed in a second procedure in adults, using Neodymium: YAG (Nd:YAG) laser (Dardenne et al. 1989). A hole is then made in the posterior capsule, and the vision is clear again. In most cases, after-cataract in children can

not be removed with only Nd:YAG laser, because the LECs will grow on the anterior vitreous surface over and over again (Hutcheson et al. 1999, O'Keefe et al. 2001). The after-cataract has to be removed in a second surgical procedure, when anterior vitrectomy (AV) is performed, often via the pars plana. The children then need a second anaesthesia, which is again a risk to the child. Furthermore, in the very small children the LECs grow on the posterior surface of the IOL, also after a vitrectomy is performed.

6.4.1 Surgical techniques

To diminish after-cataract in children, most cataract surgeons perform posterior capsulorhexis at surgery (Er et al. 2000, Ellis 2002). It is also debated whether or not an anterior vitrectomy should be performed at primary surgery (Dutton et al. 1990, Buckley et al. 1993, Basti et al. 1996, Koch and Kohnen 1997, Vasavada and Desai 1997, Fallaha and Lambert 2001). It could be performed through the pars plana (Buckley et al. 1993), or as in (I and II) through the anterior chamber after the posterior capsulorhexis and implantation of an IOL. The anterior vitreous is then removed, and the LECs most often cannot grow on the remaining vitreous. The technique seems to be a good way of preventing the formation of after-cataract (Jensen et al. 2002, Ram et al. 2003).

Another surgical technique that has been studied is to perform an optic capture, the IOL is then pressed through the posterior capsulorhexis, while the haptics remain in the bag (Gimbel and DeBroff 1994, Gimbel 1996, Gimbel 1997, Vasavada et al. 2001). However, the technique does not seem to fully prevent the formation of after-cataract, it is described that the anterior vitreous face became semi-opaque (Vasavada et al. 2001) and that the LECs can grow also on the anterior surface of the IOL (Koch and Kohnen 1997). Optic capture might be a good technique in some cases though, since it provides a good centration of the IOL, which is necessary in cases after trauma or an incomplete rhexis. For the IOLs studied in (II and III), optic capture is very hard or impossible to perform since the IOL is single-piece and does not have angulated haptics.

The size and position of the anterior capsulorhexis also has effect on the development of after-cataract. The rhexis can be either small or large, and it can be located either totally on the optic, decentered with part of the rhexis off the optic, or totally off the optic. The position of the anterior capsulorhexis on the optic has been evaluated in adults. It has shown that a large rhexis causes more opacification and wrinkling of the posterior capsule

(Hollick et al. 1999). Also, a decentered rhexis, as opposed to a centered rhexis, causes more opacification (Wejde et al. 2004).

6.5 Secondary glaucoma

The earlier the surgery is performed, the greater the risk of secondary glaucoma. It also seems the smaller the eye the greater the risk, as in microphthalmus with persistent fetal vessels (Lundvall and Kugelberg 2002, Lundvall and Kugelberg 2002, Miyahara et al. 2002). It is yet not totally clear what causes the secondary glaucoma. However, an IOL seems to decrease the risk. In a study (Asrani et al. 2000) they found a much higher rate of glaucoma following cataract surgery in patients who were left aphakic (14/124 patients), than if they were implanted with an IOL (1/377 patients). They also reviewed the literature and found no reported case of open-angle glaucoma in the over 1.000 pseudophakic patients from the studies. However, in the report, most children were not infants but older.

In (III) no eye with an AcrySof SA30AT IOL developed secondary glaucoma, but three aphakic eyes did during the follow-up time. However in other animal studies with different IOLs the frequency of secondary glaucoma was similar in aphakic and pseudophakic eyes (Lundvall et al. 2001, Lundvall et al. 2003). It might also be the increased inflammatory response in young children and infants, compared to older children. Treatment with glucocorticoids should then lessen the secondary glaucoma by decreasing the postoperative inflammation.

6.6 Systemic uptake from topical administration

Glucocorticoids are known to cause growth retardation when given systemically or topically as inhalations or intranasal administration (Doull et al. 1995, Allen 2000, Allen 2000, Skoner et al. 2000, Baraniuk and Murray 2001, Szeffler 2001). A study on prepubertal children with asthma showed a reduction of the bone mineral acquisition when glucocorticoid inhalations were administered (Allen et al. 2000). The absorption occurs from the fraction swallowed and absorbed through the gastrointestinal tract, and from the fraction that is absorbed through the nasal mucosa (Szeffler 2001). From the nasal mucosa, the steroids are absorbed directly into the systemic circulation and do not go through the first-pass hepatic metabolism. Probably, the glucocorticoids eye drops in (IV and V) go through the lacrimal ducts and are absorbed through the nasal mucosa.

6.6.1 Glucocorticoid induced growth inhibition

Glucocorticoid therapy inhibits growth when given orally (Allen 1996, Touati et al. 1998). Glucocorticoids are known to interfere with the somatotrophic axis by suppression of pituitary growth hormone, inhibition of insulin-like growth factor activity and down regulation of hepatic growth hormone receptors (Allen and Goldberg 1992, Tonshoff and Mehls 1996, Guest et al. 1998, Mehls et al. 2001). Also, glucocorticoids acts locally, as shown by Baron et al (Baron et al. 1992, Baron et al. 1994). Glucocorticoids were administered locally to one tibial growth plate, to the other growth plate, only balanced salt solution was given (Baron et al. 1994). The growth was unilaterally inhibited in the growth plate treated with glucocorticoids, and when administration ceased, catch-up growth occurred only in the glucocorticoid-treated growth plate, and not in the control growth plate.

Growth is often inhibited if the individual is ill or malnourished. However, when the individual recovers, the growth rate is often greater than expected for age, catch-up growth is observed (Gafni and Baron 2000). Rabbits treated systemically with dexamethasone for five weeks had a significantly impaired femur growth (Gafni et al. 2001), however, when the treatment ceased and the rabbits were able to recover, catch-up growth was observed, and after 11 weeks the femur length was comparable to the control animals.

The pharmacokinetics and systemic effects of eye drops has been widely investigated and discussed (Rosenblum et al. 1967, Wood et al. 1967, Wood et al. 1967, Novack 1987, McGhee et al. 1989, McGhee 1992, Spiess et al. 1999, Yamada et al. 2001, Tan et al. 2002). For example, ophthalmic beta-blockers can cause clinical depression (Schweitzer et al. 2001) and reduce the heart rate (Dickstein et al. 2001).

The growth inhibiting effect of glucocorticoid eye drops has to our knowledge not earlier been described clearly. Studies have shown some effect on the hypothalamic-pituitary-adrenal axis (Burch and Migeon 1968, Krupin et al. 1974, Baba et al. 1983), but no study clearly shows the effect on growth. To study the effect of glucocorticoid eye drops on growth, we performed a study (IV) using newborn rabbits. Of course, the findings in rabbits cannot be directly transferred to humans, since rabbits have a thinner cornea, lower blink rate, different vascularity of the orbital plexus, and a smaller body mass (McGhee et al. 2002). However, the rabbit is a good animal to study growth in, since rabbits have a similar growth

pattern as humans (Kilborn et al. 2002). It would be interesting to study also in this model, if catch-up growth occurs.

6.6.2 Glucocorticoid induced osteoporosis

Glucocorticoids affect bone formation by suppressing osteoblast numbers, life span and function. Bone formation is reduced, the number of osteoid seams is lowered and the mineral apposition rate is decreased (Lane 2001). Dexamethasone increases the apoptosis of the growth plate chondrocytes, which of course induces growth retardation (Chrysis et al. 2003). Also, glucocorticoids alter the production of gonadal hormones through a number of mechanisms (Lane 2001). Glucocorticoids modify the IGF axis (Klaus et al. 2000) and also decrease the calcium absorption in the gastrointestinal tract and increase the urinary excretion of calcium, which alters the bone metabolism (Canalis and Delany 2002).

Bone mineral density (BMD) is lowered in subjects treated with glucocorticoids (Gafni et al. 2002, Allen et al. 2003). Patients with a reduced BMD have a greater risk of fractures (Baroncelli et al. 2003, Van Staa et al. 2003), children treated with glucocorticoids for acute lymphoblastic leukaemia had a higher risk of fractures (Strauss et al. 2001). This is of course important to follow when treating children with glucocorticoids. We computed the study (V) to investigate if glucocorticoid eye drops have the same effect on the bone parameters as systemic treatment.

7 Aims

1. To prevent after-cataract in children by developing a new surgical technique, and to find out until what age it should be used (I, II).
2. To investigate an IOL that could fit the infant eye (III).
3. To study side effects of postoperative treatment with glucocorticoid eye drops using an animal model (IV, V).

8 Materials and methods

8.1 Subjects and methods (I)

Eighty-five children with a median age of 68 months (range 2 to 182 months) had cataract surgery performed by one single surgeon (C.Z.) at St. Erik's Eye Hospital between 1997 and 2000.

8.1.1 Surgery

Cataract surgery was performed with posterior capsulorhexis in all cases, and in approximately half of the patients, a dry anterior vitrectomy was also performed. The vitrectomy was made after the IOL implantation with Healon GV[®] remaining in the anterior chamber. Thirty-five patients received a heparin-surface-modified poly(methyl methacrylate) (HSM-PMMA) IOL 809C (Pharmacia & Upjohn). Fifty patients received an AcrySof[®] MA30BA foldable acrylic IOL with PMMA haptics (Alcon). Postoperatively, the children had topical treatment with dexamethasone 0.1% (Isopto-Maxidex[®]) three times a day for one week, two times a day for one week and once a day for one week.

8.1.2 Follow-up

The first postoperative examination was performed the day after surgery at St. Erik's Eye Hospital, the following examinations were performed at their home clinics. The study was retrospective, the patient records from their home clinics were obtained and we investigated if they had needed a second surgical procedure for after-cataract. Median follow-up time was 19 months (range 4-39 months).

8.1.3 Statistics

Statistical analyses were performed for each IOL type with Fischer's exact test. The patients in the largest group, the AcrySof group, were divided into two groups, the younger and the older half. Fischer's exact test was then performed investigating if there was any difference in after-cataract frequency for the two surgical methods between the groups.

8.2 Subjects and methods (II)

This randomised prospective study was performed in Ukraine, since there are many children with cataracts that have not had cataract surgery due to the hard economical situation in the country. Sixty-six children with a median age of 7.6 years (range 3.3-15.3 years) had cataract surgery performed by one single surgeon (C.Z.).

8.2.1 Surgery

Cataract surgery was performed with posterior capsulorhexis in all patients. All eyes were implanted with a single-piece AcrySof[®] SA30AL IOL. Before surgery axial length and corneal curvature were measured for IOL power calculation. They were then randomised to surgery either with or without anterior vitrectomy. Anterior vitrectomy was performed through the pupil and the two capsulorhexes, with Viscoat[®] remaining in the anterior chamber. No protective patch was given to any child. Topical treatment with dexamethasone 0.1% was started the day after surgery with 3 drops daily for one month.

8.2.2 Follow-up

Postoperative examinations were performed the day after surgery, six months and two years after surgery. If after-cataract obscured the visual axis, an anterior vitrectomy was performed through the pars plana. Seven patients failed to come to the two-year follow-up and were excluded from the statistical analyses.

8.2.3 Evaluation of Posterior Capsule Opacification (EPCO)

At the two-year follow-up, slit-lamp retroillumination pictures were taken of the remaining 59 patients and evaluated with EPCO (Tetz et al. 1997). With the EPCO software the after-cataract is scored on a scale from 0 to 4 and multiplied by the fractional area involved. The after-cataract scores are: 0 = none; 1 = minimal (mild capsule wrinkling, mild homogeneous layers or sheets of LECs); 2 = mild (honeycomb pattern of PCO, thicker homogeneous layers, denser fibrosis); 3 = moderate (classical Elschnig pearls, very thick homogeneous layer); 4 = severe (very thick Elschnig pearls with “darkening effect”, and severe opacification). EPCO is probably a more objective way of measuring the posterior capsule opacification in

adults, compared to for example Nd: YAG rates, however it is not so often used in children. Forty-four patients were possible to evaluate with EPCO; 7 patients had already had surgery for after-cataract before the two-year follow-up and we could not get an EPCO score from them, the pictures from 8 patients were not of enough quality to evaluate with EPCO.

8.2.4 Rhexis position

To evaluate if the anterior capsulorhexis position on the IOL has influence on the degree of after-cataract, the pictures were evaluated again, at another occasion than the EPCO evaluation. At this occasion we looked at if the rhexis was centered on the IOL or if any part of the rhexis margin was located off the optic, a decentered rhexis.

In 8 patients it was not possible to see the entire rhexis margin, therefore 36 patients remained to be evaluated statistically.

8.2.5 Statistics

Exact logistic regression (Agresti 2002) (LogXact version 5.0, CYTEL Inc, Cambridge, Mass) and exact Mann-Whitney test (StatXact version 5.0, CYTEL Inc, Cambridge, Mass) were used for statistical analyses. Two different models were estimated, one with surgery for after-cataract and one with EPCO as response variable. Exact logistic regression was used to model the probability of surgery for after-cataract being performed and to model the probability of an EPCO-value higher than 0.25. The predictors used were age at surgery and whether an anterior vitrectomy was performed. The interaction between the two predictors was also evaluated but preliminary analyses showed no significant interactions in any of the models. The final parsimonious model therefore assumes the absence of an interaction:

$$\log it[P(RV = 1)] = \alpha + \beta_1 AAS_i + \beta_2 AV_j$$

where RV = Response Variable

AAS_i = Age at surgery, $i=1, \dots, n$.

AV_j = Anterior vitrectomy, $j=1, \dots, n$.

Age at surgery was categorized into two categories, 62 months or younger and older than 62 months since age at surgery could not be included as a continuous variable, because the relationship with the response was not linear in the log odds.

A basic property of the logistic regression model is that e^β is an odds ratio. In the results and discussion section below, odds ratios will be presented together with confidence intervals and p-values. In article (II) results are presented in two by two tables as in (I).

8.3 Animal model and methods (III, IV, V)

8.3.1 Animals

Newborn (three-week-old) New Zealand White rabbits were fed tap water ad libitum, corn oil and sour cream the first week, then squeezed hay ad libitum and pellets. All studies were approved by the Northern Stockholm Animal Experiments Ethics Committee and adhered to the ARVO statement for the use of animals in ophthalmic and vision research. At two months postoperatively, the animals were killed injecting 3 ml of Pentobarbital 100 mg/ml intraperitoneally.

8.3.2 Surgery

At three weeks of age the rabbits were anaesthetized with 0.24 ml ketamine hydrochloride (Ketalar[®] 50 mg/ml) and 0.08 ml xylazine chloride (Rompun[®] 20 mg/ml). Clear lens extraction was performed in one (IV, V) or both (III) eyes after pupil dilation with a combination of cyclopentolate 0.75% and phenylephrine 2.5%. In (IV, V) the eye was left aphakic and at the end of surgery 2 mg (group 1) or 4 mg (group 2) of betamethasone (Betapred[®]) was given as a perioperative subconjunctival injection. In (III), one randomly selected eye was left aphakic, in the other eye an AcrySof[®] SA30AT foldable acrylic IOL, Alcon, was implanted. The IOL is of single-piece design and has sharp edges.

8.3.3 Postoperative treatment (III)

Starting the day after surgery, the rabbits received topical administration of 20 µl dexamethasone 0.1% (Isopto-Maxidex[®]) with a micropipette in both eyes six times a day the first week, four times a day for two weeks, three times a day for one week, then two times a day.

8.3.4 Postoperative treatment (IV, V)

Starting the day after surgery, 20 µl of eye drops were administered in the operated eye 10 times a day, de-escalating in frequency by two administrations every other week.

Dexamethasone 0.1% was Isopto-Maxidex[®], vehicle was the same solution but without dexamethasone.

The rabbits were randomly divided into three groups.

Group 1 (n= 13): Dexamethasone every time.

Group 2 (n= 11): Dexamethasone every other time, vehicle every other time.

Group 3 (n= 10): Only vehicle at all times.

8.3.5 Measurements (III)

Preoperatively, after one and two months, measurements were made of axial length using Sonomed A-scan A 1500 fitted with a short focal length crystal and software modified for use in the eyes of small rabbits. Corneal diameter was measured using a pair of compasses. Corneal thickness was measured at endpoint (two months postoperatively), using Tomey minipachymeter SP2000.

Posterior synechiae were measured by comparing pupil size with corneal diameter. Photographs were taken of the eyes at one and two months with dilated pupil. The pupil diameter was divided by the corneal diameter; a quote was obtained and used in statistical analyses.

At endpoint, in 10 animals the after-cataract was dissected out of the eyes and the wet mass of after-cataract determined as earlier described (Lundgren et al. 1992). In the other 9 surviving rabbits, the eyes were fixated in formaline for histologic evaluation of the chamber angle, signs of postoperative inflammation and cells on the posterior capsule.

8.3.6 Measurements (IV)

Before surgery and postoperatively once a week, measurements were made by the same examiner of body weight and crown-rump length. At endpoint, the left femur, the gonads and the gonadal fat were extracted. The femoral length was measured using a micrometer. The gonads and gonadal fat were weighed and compared with the total body weight.

8.3.7 Dual X-ray Absorptiometry (DXA) (V)

DXA was performed ex vivo as previously described (Windahl et al. 1999), with the Norland pDEXA Sabre (Norland, Fort Atkinson, WI, USA) and the Sabre Research software (v3.6). The interassay coefficient of variation for these measurements was below 5%.

8.3.8 Peripheral Quantitative Computerized Tomography (pQCT) (V)

Computerized tomography was performed as previously described (Vidal et al. 2000) with the Stratec pQCT XCT Research M (Norland; v5.4B) operating at a resolution of 70 μm . Trabecular volumetric bone mineral density (BMD) was determined ex vivo, with a metaphyseal pQCT scan of the distal femur, and defined as the inner 45% of the total cross-sectional area. Cortical bone parameters were determined ex vivo with a mid-diaphyseal pQCT scan of the femur. The interassay coefficient of variation for these measurements was less than 2%.

8.3.9 Statistics (III)

For the axial length and corneal thickness, 95% confidence intervals were performed. Analyses were based on the differences between the aphakic and pseudophakic eyes. A Wilcoxon's sign rank test was used when comparing the wet mass of after-cataract. Pupil size and histologic evaluation were analysed using sign tests (Bland 2000).

8.3.10 Statistics (IV)

Weight gain, increase in crown-rump length was analysed using two-way ANOVA. Femur length was analysed using one-way ANOVA. As post hoc tests, Bonferroni's corrections were used for individual comparisons. Wilcoxon's two-sample rank tests were used for comparisons between the sexes. There were no differences between the sexes; therefore, males and females were presented together.

8.3.11 Statistics (V)

One-way ANOVA was used for all statistics followed by post hoc comparisons with Tukey's HSD test. For differences between sexes, student's t-tests were used. There were no differences in the parameters between sexes, except for trabecular BMD, in which the control group males had a higher value than the control group females. Therefore, the males and females are presented together in the results.

9 Results and discussion

9.1 Surgical technique (I, II)

The retrospective study (I) showed that in the very young patients, it seems performing a posterior capsulorhexis is not enough to avoid after-cataract. We showed that cataract surgery in children below the age of seven should be performed with anterior vitrectomy to avoid after-cataract (table 1). Among the patients that did not have an anterior vitrectomy at primary surgery, significantly more patients had to have surgery for after-cataract ($p < 0.05$, Fisher's exact test with two by two tables and one-way test).

AcrySof younger		Surgery with anterior vitrectomy		
		Yes	No	
Surgery for after-cataract	Yes	0	5	5
	No	15	5	20
		15	10	25

Table 1. The results put in two by two table for the younger half of patients implanted with AcrySof® IOL. The figures in the table are number of patients. The table shows more patients had to have surgery for after-cataract if anterior vitrectomy was not performed at cataract surgery ($p < 0.05$).

In older children, above the age of seven, there was no significant difference in the need for after-cataract surgery ($p>0.05$, table 2). It therefore seems anterior vitrectomy is not necessary in older children.

AcrySof older		Surgery with		
		anterior vitrectomy		
		Yes	No	
Surgery for after-cataract	Yes	0	3	3
	No	4	18	22
		4	21	25

Table 2. The results put in two by two table for the older half of patients implanted with AcrySof® IOL. The figures in the table are number of patients. The table shows that there was no significant difference in after-cataract frequency if surgery was performed with anterior vitrectomy or not ($p>0.05$).

The results also showed that some patients implanted with an HSM-PMMA IOL developed after-cataract even though they had cataract surgery with anterior vitrectomy (table 3).

HSM-PMMA		Surgery with		
		anterior vitrectomy		
		Yes	No	
Surgery for after-cataract	Yes	6	3	9
	No	25	1	26
		31	4	35

Table 3. The results put in two by two table for children implanted with the HSM-PMMA IOL. The figures in the table are number of patients. The table shows more patients had to have surgery for after-cataract if anterior vitrectomy was not performed at cataract surgery ($p<0.05$). The table also shows that six patients had to have surgery for after-cataract even though they had cataract surgery with anterior vitrectomy.

In the AcrySof® group, no patient that had surgery with anterior vitrectomy had to have surgery for after-cataract, independent of age at surgery. It therefore seems the AcrySof® IOL is a better choice of IOL in children in this age group, concerning after-cataract.

The data from the prospective study (II) also showed that it is advantageous to perform pediatric cataract surgery with anterior vitrectomy until school age. There was a significantly increased odds ratio of having surgery for after-cataract if the primary surgery was performed without an anterior vitrectomy (table 4). Also, more patients had surgery for after-cataract if age at surgery was less than 62 months (table 4).

Predictor of surgery for after-cataract	Estimated Odds Ratio	95% Confidence interval		Significance
		Lower limit	Upper limit	
Age at surgery \leq or $>$ 62 months	8.6	1.9	49	p<0.01
Anterior vitrectomy or not	7.1	1.7	37	p<0.01

Table 4. Analyses with exact logistic regression, p-values and 95% confidence intervals for odds ratio of surgery for after-cataract, concerning age at surgery and if an anterior vitrectomy was performed or not. Age at surgery \leq 62 months and cataract surgery without anterior vitrectomy increased the risk of surgery for after-cataract.

The predictors age at surgery and anterior vitrectomy did not significantly affect the EPCO score (p>0.05). The EPCO score measures the after-cataract that is seen with a dilated pupil, that is, not only the central portion, but also the more peripheral after-cataract. Surgery for after-cataract was carried out if there was after-cataract in the central visual axis that affected the visual ability. In one way, the EPCO score is more objective, however, since surgery for after-cataract was performed only when necessary, surgery for after-cataract might be a better response variable in the study.

To investigate if EPCO score correlated to the rate of surgery for after-cataract, the EPCO score was evaluated for the patients that had surgery for after-cataract and the patients that did not have surgery for after-cataract, using exact Mann-Whitney test. The patients that had already had surgery for after-cataract before the last follow-up were excluded from the analyses as mentioned above. The patients that had surgery for after-cataract at last follow-up had a significantly higher EPCO score ($p < 0.001$) than the patients that did not need surgery for after-cataract (figure 4). It seems EPCO has some meaning as a method for measuring after-cataract also in children.

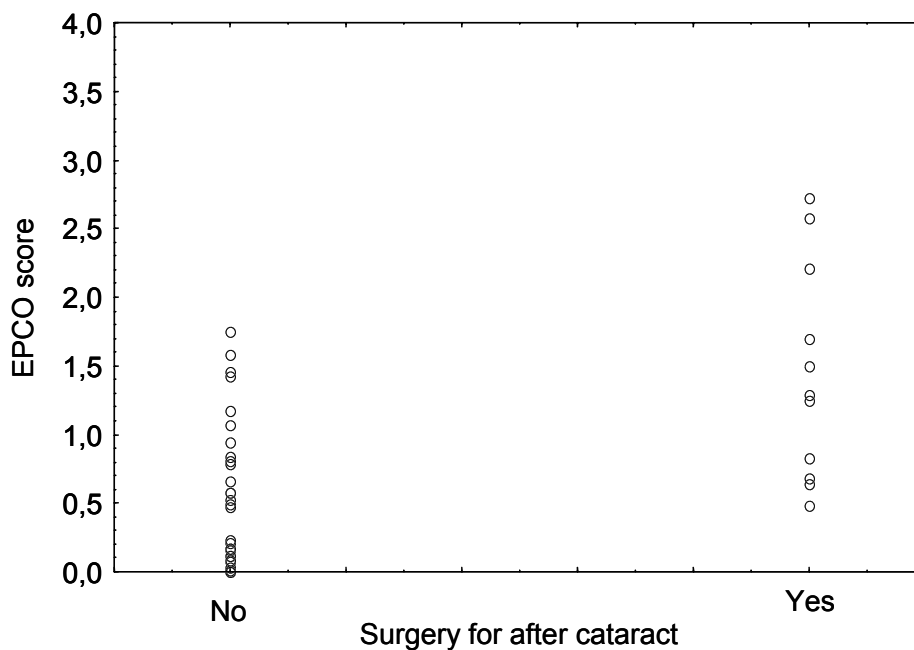


Figure 4. EPCO score for patients that had surgery for after-cataract or not at last follow-up. Patients that already had surgery for after-cataract before last follow-up are excluded.

Capsulorhexis position was evaluated using exact Mann-Whitney test. No significant difference in EPCO score could be observed if the rhexis was centered or decentered on the optic. However, only 8 patients out of 36 had the rhexis decentered and the difference in group size might affect the outcome of the statistics. In (II), the IOL did not move forward when the rhexis was decentered, which was seen in (III), when a similar IOL was implanted in the newborn rabbit eye.

The AcrySof[®] SA30AL IOL stayed clinically centered in all eyes and produced minimal inflammation. No eye developed posterior synechiae.

Posterior capsulorhexis and anterior vitrectomy is one way of preventing the after-cataract. Other ways to manage the after-cataract have been studied. As discussed in the introduction, some authors have investigated cataract surgery and optic capture, the IOL is then pushed behind the posterior capsulorhexis, the haptics remaining in the bag (Gimbel and DeBroff 1994, Gimbel 1996, Gimbel 1997, Vasavada et al. 2001). One study showed that when optic capture was performed in children between 5 and 12 years old, also anterior vitrectomy was needed to avoid after-cataract (Vasavada et al. 2001). The question of whether or not to perform anterior vitrectomy in children and infants at primary surgery has been debated in many articles (Wilson et al. 1994, Zetterstrom et al. 1994, Basti et al. 1996, Koch and Kohnen 1997, Vasavada and Desai 1997, Fenton and O'Keefe 1999, Ahmadih and Javadi 2001, Vasavada et al. 2001). However, to our knowledge, there was yet no randomised prospective study that has concluded the discussion. Study (I and II) clearly show that anterior vitrectomy is advantageous in children before the age of 5-7 years.

9.2 IOL in small eyes (III)

In (III), the implantation of a single-piece AcrySof® IOL did not retard eye growth compared to aphakic eyes, there was a significant difference in axial length at one month but not at two months (table 5).

Parameter	Preoperatively	Postoperatively	Postoperatively
	0 months	1 month	2 months
Mean axial length (mm)			
Aphakic eyes	11.28	12.5	13.41
Pseudophakic eyes	11.38	12.25	13.33
Differences between groups (95% CI)	0.10±0.13	0.24±0.16	0.08±0.40
Mean corneal diameter (mm)			
Aphakic eyes	9.22	9.78	10.72
Pseudophakic eyes	9.22	9.88	10.78
Differences between groups (95% CI)	0±0.10	-0.09±0.20	-0.06±0.57

Table 5. Axial length and corneal diameter in animals not developing signs of secondary glaucoma (n= 16). Significant difference only in axial length at one month ($p<0.05$). Difference between groups= mean of individual differences between aphakic and pseudophakic eye in each animal. CI= confidence interval.

There was no difference in corneal diameter between the eyes (table 5). Earlier studies have been performed using the same animal model looking for an ideal IOL for small eyes (Kugelberg et al. 1997, Lundvall et al. 2001). In most studies, the IOL has retarded eye growth more than if no IOL was implanted. Aphakic eyes already have less axial growth compared to phakic eyes (Wilson et al. 1987, Kugelberg et al. 1996) and also, eyes with cataract are smaller than eyes with a clear lens (Kugelberg et al. 1996). The AcrySof® SA30AT is quite soft yet it has good memory in the haptics compared to other tested IOLs, and it might be that more rigid IOLs destroy the peripheral retina, which can affect potential ocular growth.

In (III) the wet mass of after-cataract was less in pseudophakic eyes compared to aphakic eyes, which agrees with earlier studies using the same model (Zetterstrom et al. 1996, Kugelberg et al. 1997, Lundvall et al. 2003). When looking at central after-cataract, however,

this is opposite from the findings in humans (Lambert et al. 2001, Plager et al. 2002). Probably, in aphakic eyes, there is much more peripheral after-cataract, Sommering's ring, that with time can affect visual acuity, and also makes it hard to implant an IOL later in life. Also, in theory, the Sommering's ring could cause synechiae formation in the chamber angle and development of glaucoma later in life. In aphakic eyes the anterior and posterior capsule probably seal and the LECs cannot migrate into the centre of the pupil, while in pseudophakic eyes, the capsules do not seal because of the IOL optic, why the LECs can proliferate to the visual axis.

Implantation of AcrySof[®] SA30AT IOL seems to inhibit the development of secondary glaucoma. Three rabbits developed secondary glaucoma in the aphakic eye, but no rabbit developed glaucoma in the pseudophakic eye. The animals with secondary glaucoma were excluded from the statistical analyses of axial length, corneal diameter, pupil size and corneal thickness. The pupil size compared to the corneal diameter in each eye was significantly larger in pseudophakic eyes than aphakic eyes ($p < 0.05$ at 1 month, $p < 0.01$ at two months), indicating less posterior synechiae and not as much postoperative inflammation, which might explain a lesser amount of secondary glaucoma. In the histologic evaluation, there was no difference in signs of inflammation and the chamber angle was not narrower in any of the groups, but the formaline fixation was done at endpoint, two months postoperatively. In the histologic evaluation there was no difference in the amount of cells on the posterior capsule.

In these small eyes with a very elastic anterior capsule, it is technically hard to perform a perfectly round capsulorhexis that covers the IOL for 360 degrees. In 11 out of the 19 pseudophakic eyes, the IOL moved forward, and was in part in the anterior chamber (figure 5). In all these eyes, the capsulorhexis was not totally on the optic.

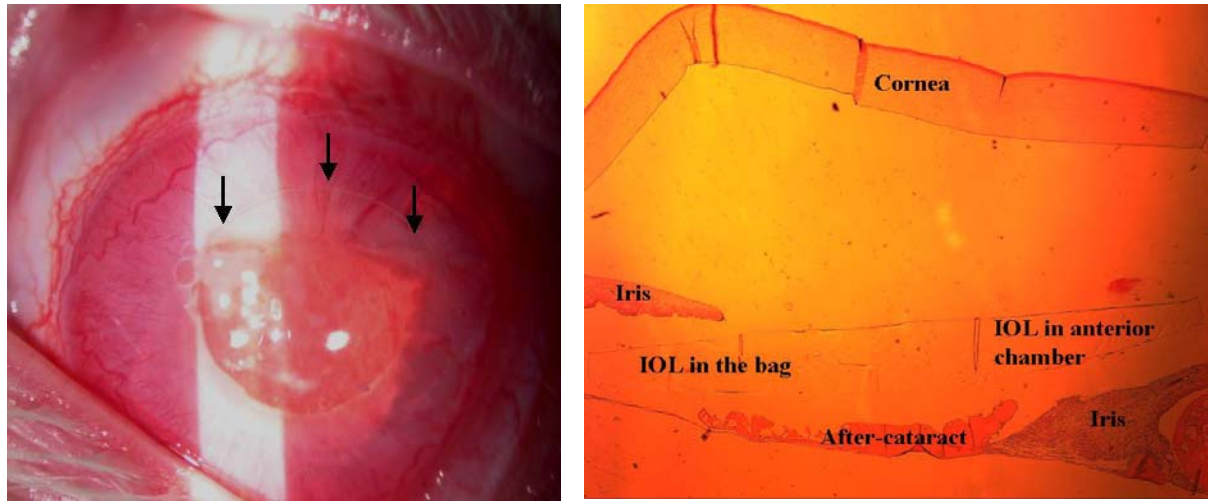


Figure 5. The IOL has moved forward and is in part in the anterior chamber, indicated with arrows (left). In this histologic slide it is evident that the IOL is in part in front of the iris. Some after-cataract can be seen behind the IOL (right).

Surprisingly and fortunately, none of these eyes developed secondary glaucoma. In another similar study evaluating a three-piece AcrySof[®], the bistable optic moved forward and vaulted, and occluded the pupil (Lundvall et al. 2003).

The AcrySof[®] SA30AT seems a suiting IOL in the small eye. Also, in (II) we showed that in humans, the IOL did not move forward to the anterior chamber when the rhexis was decentered on the optic.

9.3 Topical glucocorticoids, growth retardation and bone parameters (IV, V)

The study performed to elucidate the systemic effects of topical glucocorticoids showed that the high dose dexamethasone treatment group grew less than the low dose treatment group, and the low dose treatment group grew less than the control group. Hence, a dose-dependant longitudinal growth inhibitory effect was seen from glucocorticoid eye drops. A good and often used parameter of longitudinal growth is the femoral length. The femoral length in the three groups is shown in figure 6.

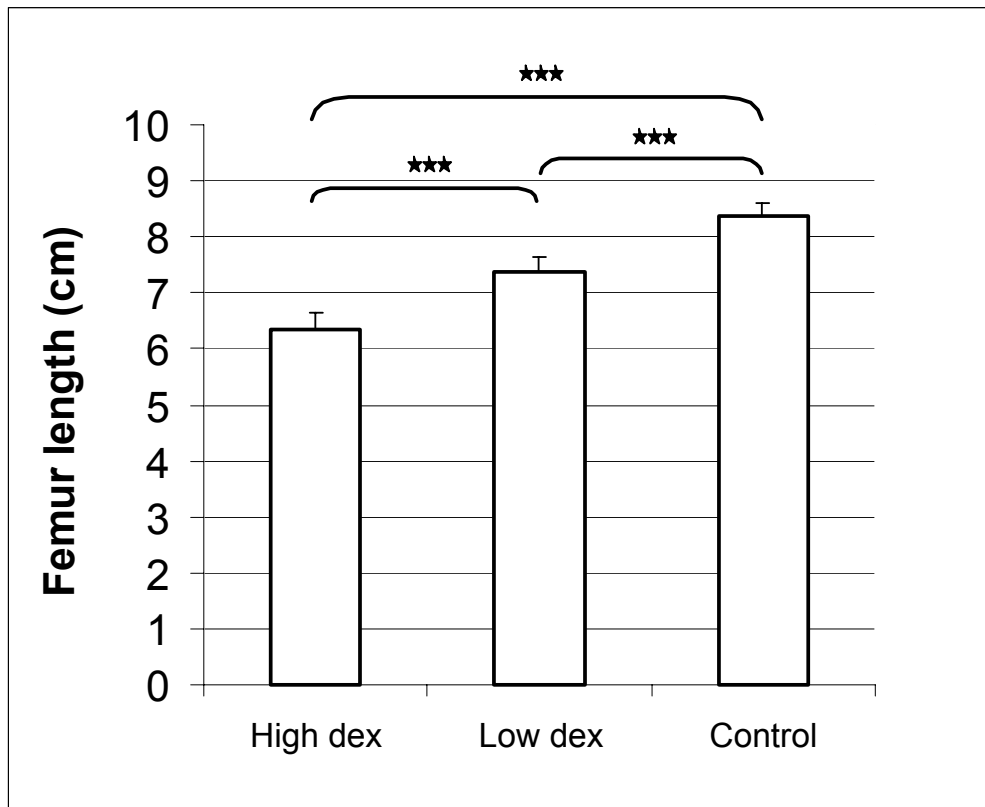


Figure 6. Average femur length +SD in the three groups, high (Group 1) or low (Group 2) dose of dexamethasone eye drops compared to control (Group 3) animals given vehicle drops only. Significance level; *** $p < 0.001$.

The increase in crown-rump length was less in the high dose group (figure 7) and also the increase in body weight (figure 8) was dose-dependently reduced by dexamethasone eye drops. No statistical differences between males and females were observed in femoral length, weight, crown-rump length or gonadal fat ($p > 0.05$ between males and females in all groups).

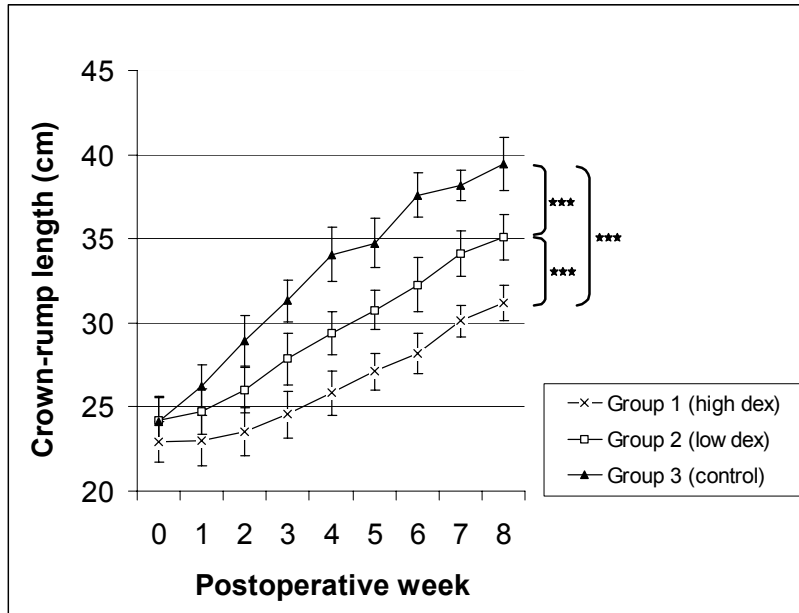


Figure 7. Average crown-rump length in the three groups. Error bars denote \pm SD. The significance levels of the differences between the groups are indicated; *** $p < 0.001$.

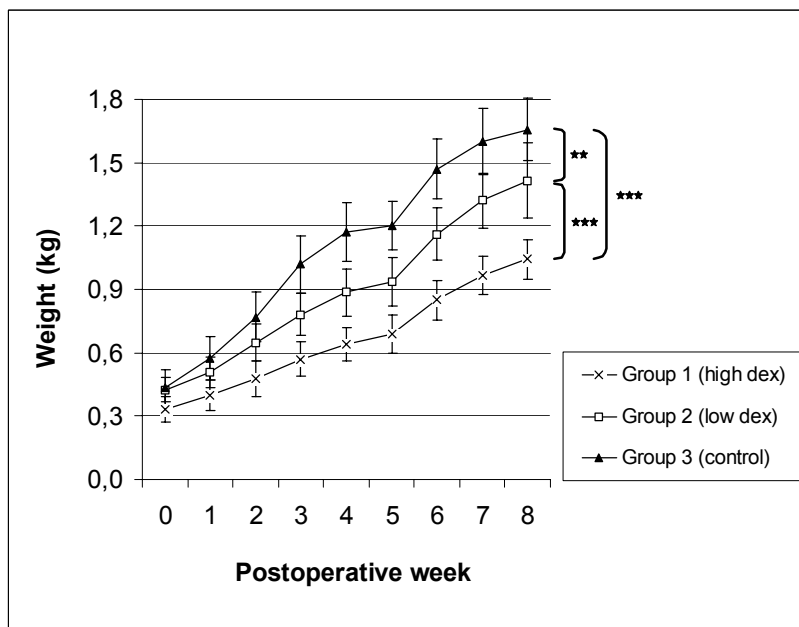


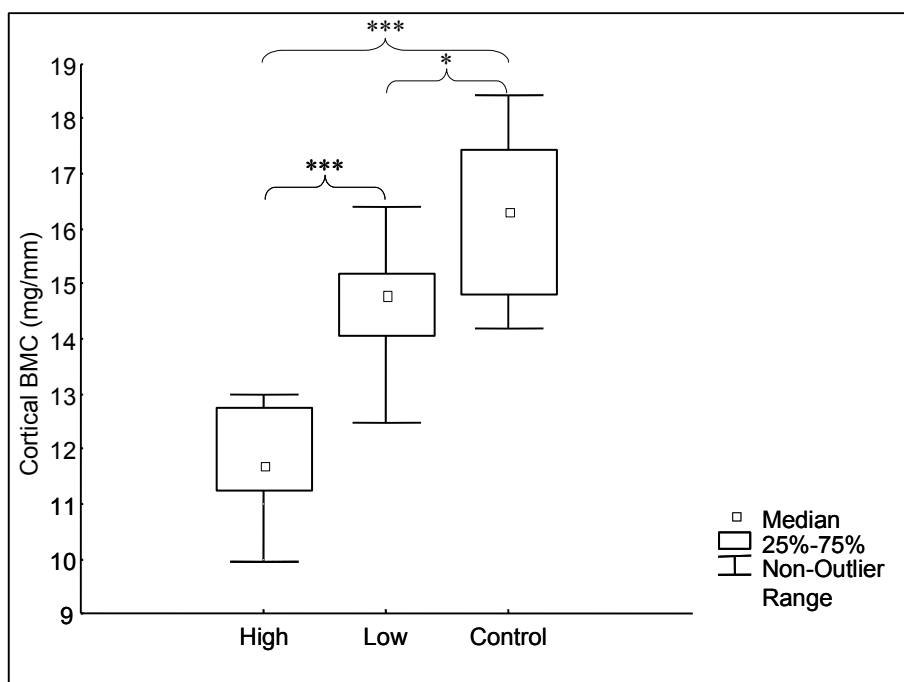
Figure 8. Average body weight. Error bars denote \pm SD. The significance levels of the differences between the groups are indicated; ** $p < 0.01$, *** $p < 0.001$.

The absorption mechanism of the eye drops is not totally clear. It is probable that the drops are transported through the lacrimal ducts to the vascular nasal mucosa where they are absorbed (McGhee et al. 2002). After absorption in the nasal mucosa, the glucocorticoids do not undergo first-pass hepatic metabolism, why they give more effect than if given orally.

The weight of the gonadal fat was compared with the total body weight and there was no statistical difference between the groups. Since treatment with cortisone can cause depression, and with depression anorexia can follow, malnutrition might be a cause of growth impairment in these animals (Lane 2001). However, the gonadal fat is a good parameter of the total body fat, and since there was no difference between the groups in gonadal fat, we conclude the rabbits in the dexamethasone group did not suffer from malnutrition. We believe that the growth inhibition was caused by systemic uptake of the glucocorticoid eye drops.

The bone parameters measured in (V) were all affected by the dexamethasone eye drops. Measurements with DXA showed that the area of the femur, the areal BMD and the total femur BMC was all dose-dependently reduced by the dexamethasone. Since DXA measure a combination of effects on trabecular and cortical bone, pQCT was performed to distinguish between the effects on trabecular and cortical bone.

Measurements with pQCT showed that glucocorticoid eye drops reduced the cortical BMC, which was caused by a reduction in cortical volumetric BMD and cortical cross sectional area (figure 9).



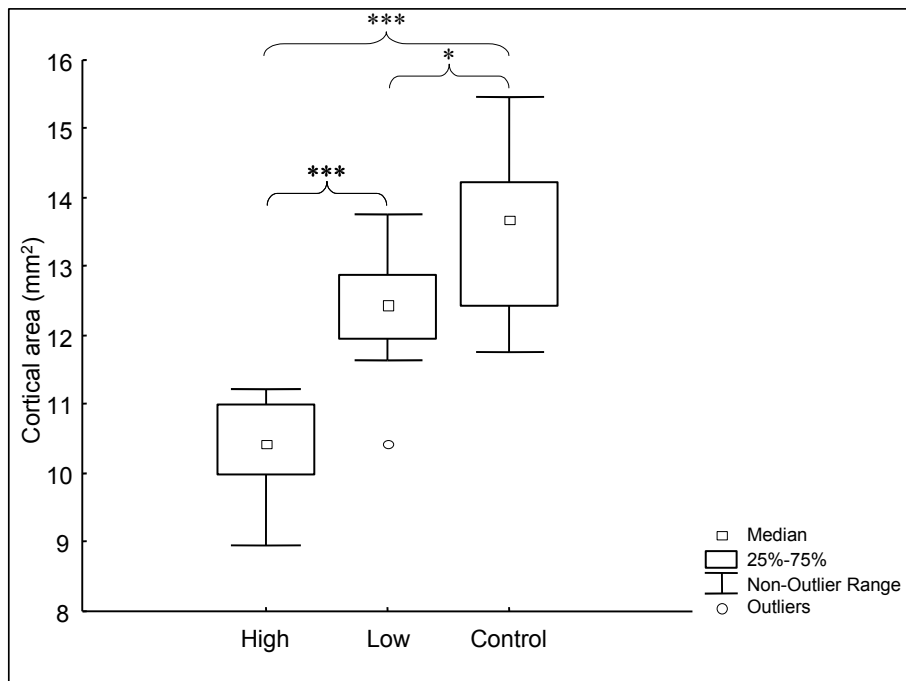
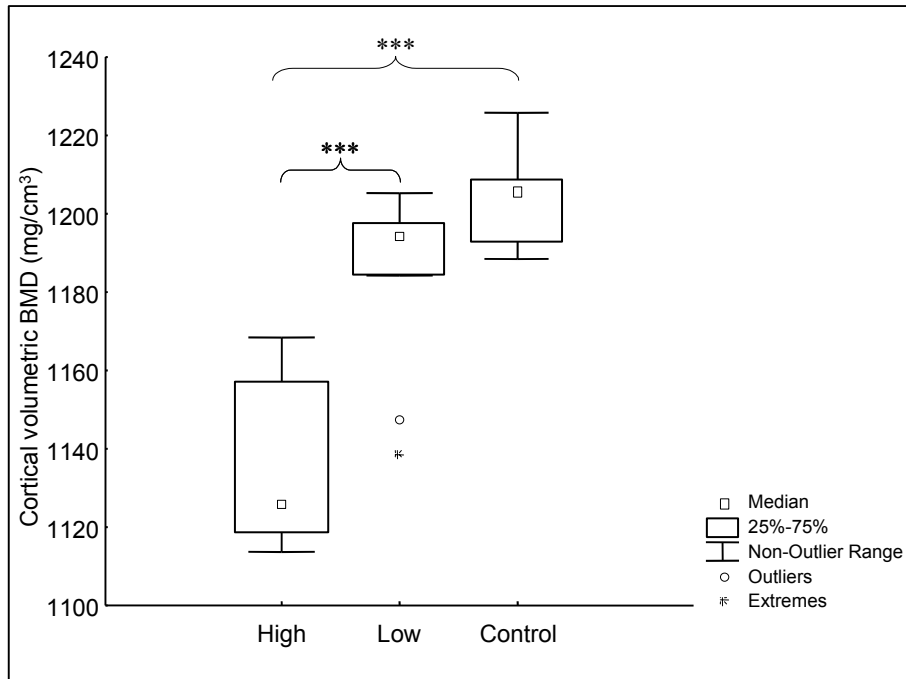


Figure 9. Boxplots showing the cortical BMC (previous page), cortical volumetric BMD (top) and cortical area (bottom). The significance levels of the differences between the groups are indicated; * $p < 0.05$, *** $p < 0.001$.

A significantly decreased cortical thickness and inner and outer circumference of the femur caused the reduced cross sectional area. An important aspect of the treatment with glucocorticoid eye drops is that a reduced BMD is known to increase the risk of fractured bones (Baroncelli et al. 2003, McIlwain 2003).

The effect of the dexamethasone eye drops on the bone parameters is similar to the effect observed when dexamethasone was given systemically in approximately the same dose as our high dose group to five-week-old rabbits for five weeks (Gafni et al. 2002). However, in that study, a recovery from the osteoporosis was seen when treatment was discontinued. Therefore, it is likely, that also when treatment with eye drops is discontinued, a recovery of the bone parameters would occur.

From these studies (IV and V), we conclude that topical treatment with glucocorticoids does inhibit growth in the newborn rabbit, and that the glucocorticoids reduce the bone mineral density and cause osteoporosis. Of course, since these are animal studies the results cannot be directly transferred to humans. However, also the low treatment group, with doses comparable to what infants get after cataract surgery, had significantly impaired growth and bone parameters, why we think that care should be taken when treating infants intensively with glucocorticoid eye drops. In another study looking at growth impairment of glucocorticoids in systemically treated rabbits, when treatment was finished, catch-up growth was observed (Gafni et al. 2001). Further studies are needed to investigate catch-up growth in the current animal model.

10 Conclusions

- When performing cataract surgery in children below school age, an anterior vitrectomy is needed together with a posterior capsulorhexis to avoid after-cataract. In older children, anterior vitrectomy is not necessary (I and II).
- The single-piece AcrySof[®] SA30AL IOL fits the pediatric eye well, it does not move forward if the rhexis is decentered (II).
- Implantation of AcrySof[®] SA30AT IOL in the newborn rabbit eye does not affect axial growth compared to aphakic eyes, and seems to inhibit secondary glaucoma (III).
- AcrySof seems to be a good choice of IOL in small eyes with less inflammation compared to the aphakic eye (III).
- Intensive topical treatment with glucocorticoid eye drops causes growth inhibition and osteoporosis in the newborn rabbit, indicating systemic effects (IV and V).
- Topical treatment with glucocorticoid eye drops should be used with care in infants and children (IV and V).

11 Future projects

- The treatment with topical dexamethasone was investigated because it might be a way of inhibiting the postoperative inflammation and thereby the secondary glaucoma. We plan to evaluate the data from eye growth and other parameters from the study, to see if glucocorticoids really can inhibit secondary glaucoma in the small eye.
- We plan further studies to find the perfect IOL for the infant eye.
- We will study other ways to manage the after-cataract, or posterior capsule opacification. Probably different substances should be further studied in a sealed system.

12 Acknowledgements

Several persons have contributed to my scientific education and to making this thesis possible, I especially want to thank:

Charlotta Zetterström, my supervisor and friend, for all the years of scientific guidance, for creating an open working atmosphere but still getting things done, for your courage and for your continuous support at all times.

Professor Jan Ygge and professor Gunnar Lennerstrand, head and former head of the ophthalmic division of the institute of clinical neuroscience, for providing excellent working facilities and allowing me to be a Ph.D. student at the department.

Per Montan, for all the excellent discussions and caffè lattes.

At the lab: Monica Aronsson, for your work, your flexibility and good humour in all situations. Ingeborg van der Ploeg for fruitful discussions and your scientific knowledge. Anne Winter-Wernersson and Susanne Ekenbark for learning me a lot about laboratorial things I didn't know. My co-author Kayvan Shafiei, for always being ready to work, and for all the fun.

My co-author Lars Sävendahl, for your help and good advise.

My co-author Claes Ohlsson for your help.

Erik Kock, for help with the histologic evaluations.

Margareta Oskarsson and Berit Spångberg, who prepared the tissue specimens in the pathology department so nicely.

Calle Oskarsson, for always fast help and good advice in technical questions.

My family, for your love and support.

Johanna, for your never-failing love, support and help at all times, for creative ideas, your knowledge in computer science and your patience.

Klara, for being so sweet.

This work was financially supported by:

FoU-grants

Stiftelsen Synfrämjandets Forskningsfond

Capios Forskningsstiftelse

Margit Thyselius fond för blind ungdom

Stiftelsen Kronprinsessan Margaretas Arbetsnämnd för Synskadade

Margareta och Elisabet Anderssons Donation

Karin Sandqvists Stiftelse.

13 References

- Abrahamsson M, Magnusson G, Sjöström A, Popovic Z, Sjöstrand J. The occurrence of congenital cataract in western Sweden. *Acta Ophthalmol Scand.* 1999;77:578-580.
- Agresti A. *Categorical Data Analysis.* Hoboken, New Jersey, John Wiley & Sons Inc., 2002; 251-257
- Ahmadih H, Javadi MA. Intra-ocular lens implantation in children. *Curr Opin Ophthalmol.* 2001;30-34.
- Alexandrakis G, Peterseim MM, Wilson ME. Clinical outcomes of pars plana capsulotomy with anterior vitrectomy in pediatric cataract surgery. *J Aapos.* 2002;6:163-167.
- Allen DB. Growth suppression by glucocorticoid therapy. *Endocrinol Metab Clin North Am.* 1996;25:699-717.
- Allen DB. Do intranasal corticosteroids affect childhood growth? *Allergy.* 2000;55 Suppl 62:15-18.
- Allen DB. Systemic effects of intranasal steroids: an endocrinologist's perspective. *J Allergy Clin Immunol.* 2000;106:S179-190.
- Allen DB, Bielory L, Derendorf H, Dluhy R, Colice GL, Szeffler SJ. Inhaled corticosteroids: past lessons and future issues. *J Allergy Clin Immunol.* 2003;112:S1-40.
- Allen DB, Goldberg BD. Stimulation of collagen synthesis and linear growth by growth hormone in glucocorticoid-treated children. *Pediatrics.* 1992;89:416-421.
- Allen HD, Thong IG, Clifton-Bligh P, Holmes S, Nery L, Wilson KB. Effects of high-dose inhaled corticosteroids on bone metabolism in prepubertal children with asthma. *Pediatr Pulmonol.* 2000;29:188-193.
- Asrani S, Freedman S, Hasselblad V, Buckley EG, Egbert J, Dahan E, Gimbel H, Johnson D, McClatchey S, Parks M, Plager D, Maselli E. Does primary intraocular lens implantation prevent "aphakic" glaucoma in children? *J Aapos.* 2000;4:33-39.
- Awaya S, Sugawara M, Miyake S. Observations in patients with occlusion amblyopia: results of treatment. *Trans Ophthalmol Soc U K.* 1979;99:447-454.
- Baba S, Mishima H, Okimoto M, Miyachi Y. Plasma steroid levels and clinical effects after topical application of betamethasone. *Graefes Arch Clin Exp Ophthalmol.* 1983;220:209-214.

- Baraniuk JN, Murray J. The linear relationship between changes in childhood growth velocity and topical glucocorticoid dose. [see comments.]. *Allergy Asthma Proc.* 2001;22:153-164.
- Baron J, Huang Z, Oerter KE, Bacher JD, Cutler GB, Jr. Dexamethasone acts locally to inhibit longitudinal bone growth in rabbits. *Am J Physiol.* 1992;263:E489-492.
- Baron J, Klein KO, Colli MJ, Yanovski JA, Novosad JA, Bacher JD, Cutler GB, Jr. Catch-up growth after glucocorticoid excess: a mechanism intrinsic to the growth plate. *Endocrinology.* 1994;135:1367-1371.
- Baroncelli GI, Federico G, Bertelloni S, Sodini F, De Terlizzi F, Cadossi R, Saggese G. Assessment of bone quality by quantitative ultrasound of proximal phalanges of the hand and fracture rate in children and adolescents with bone and mineral disorders. *Pediatr Res.* 2003;54:125-136.
- Basti S, Ravishankar U, Gupta S. Results of a prospective evaluation of three methods of management of pediatric cataracts. *Ophthalmology.* 1996;103:713-720.
- Birch EE, Stager DR. The critical period for surgical treatment of dense congenital unilateral cataract. *Invest Ophthalmol Vis Sci.* 1996;37:1532-1538.
- Bland M. Chapter 9: Significance tests. In: *An introduction to medical statistics*, 3d edition. New York, Oxford University Press Inc., 2000; 138-139
- Buckley EG, Klombers LA, Seaber JH, Scalise-Gordy A, Minzter R. Management of the posterior capsule during pediatric intraocular lens implantation. *Am J Ophthalmol.* 1993;115:722-728.
- Burch PG, Migeon CJ. Systemic absorption of topical steroids. *Arch Ophthalmol.* 1968;79:174-176.
- Canalis E, Delany AM. Mechanisms of glucocorticoid action in bone. *Ann N Y Acad Sci.* 2002;966:73-81.
- Cavallaro BE, Madigan WP, O'Hara MA, Kramer KK, Bauman WC. Posterior chamber intraocular lens use in children. *J Pediatr Ophthalmol Strabismus.* 1998;35:254-263.
- Chrysis D, Ritzen EM, Savendahl L. Growth retardation induced by dexamethasone is associated with increased apoptosis of the growth plate chondrocytes. *J Endocrinol.* 2003;176:331-337.
- Crouch ER, Crouch ER, Jr., Pressman SH. Prospective analysis of pediatric pseudophakia: myopic shift and postoperative outcomes. *J Aapos.* 2002;6:277-282.

- Dardenne MU, Gerten GJ, Kokkas K, Kermani O. Retrospective study of retinal detachment following neodymium:YAG laser posterior capsulotomy. *J Cataract Refract Surg.* 1989;15:676-680.
- Dickstein K, Hapnes R, Aarsland T. Comparison of aqueous and gellan ophthalmic timolol with placebo on the 24-hour heart rate response in patients on treatment for glaucoma. *Am J Ophthalmol.* 2001;132:626-632.
- Doull IJ, Freezer NJ, Holgate ST. Growth of prepubertal children with mild asthma treated with inhaled beclomethasone dipropionate. *Am J Respir Crit Care Med.* 1995;151:1715-1719.
- Dutton JJ, Baker JD, Hiles DA, Morgan KS. Viewpoints: visual rehabilitation in aphakic children. *Surv Ophthalmol.* 1990;34:365-384.
- Ellis FJ. Management of pediatric cataract and lens opacities. *Curr Opin Ophthalmol.* 2002;13:33-37.
- Er H, Doganay S, Evereklioglu C, Erten A, Cumurcu T, Bayramlar H. Retrospective comparison of surgical techniques to prevent secondary opacification in pediatric cataracts. *J Pediatr Ophthalmol Strabismus.* 2000;37:294-298.
- Fallaha N, Lambert SR. Pediatric cataracts. *Ophthalmol Clin North Am.* 2001;14:479-492.
- Fenton S, O'Keefe M. Primary posterior capsulorhexis without anterior vitrectomy in pediatric cataract surgery: Long term outcome. *J Cataract Refract Surg.* 1999;25:763-767.
- Foster A, Gilbert C. Epidemiology of childhood blindness. *Eye.* 1992;6:173-176.
- Gafni RI, Baron J. Catch-up growth: possible mechanisms. *Pediatr Nephrol.* 2000;14:616-619.
- Gafni RI, McCarthy EF, Hatcher T, Meyers JL, Inoue N, Reddy C, Weise M, Barnes KM, Abad V, Baron J. Recovery from osteoporosis through skeletal growth: early bone mass acquisition has little effect on adult bone density. *FASEB Journal.* 2002;16:736-738.
- Gafni RI, Weise M, Robrecht DT, Meyers JL, Barnes KM, De-Levi S, Baron J. Catch-up growth is associated with delayed senescence of the growth plate in rabbits. *Pediatr Res.* 2001;50:618-623.
- Gimbel HV. Posterior capsulorhexis with optic capture in pediatric cataract and intraocular lens surgery. *Ophthalmology.* 1996;103:1871-1875.

- Gimbel HV. Posterior continuous curvilinear capsulorhexis and optic capture of the intraocular lens to prevent secondary opacification in pediatric cataract surgery. *J Cataract Refract Surg.* 1997;23:652-656.
- Gimbel HV, DeBroff BM. Posterior capsulorhexis with optic capture: Maintaining a clear visual axis after pediatric cataract surgery. *J Cataract Refract Surg.* 1994;20:658-664.
- Guest G, Berard E, Crosnier H, Chevallier T, Rappaport R, Broyer M. Effects of growth hormone in short children after renal transplantation. *French Society of Pediatric Nephrology. Pediatr Nephrol.* 1998;12:437-446.
- Hollick EJ, Spalton DJ, Meacock WR. The effect of capsulorhexis size on posterior capsular opacification: one-year results of a randomized prospective trial. *Am J Ophthalmol.* 1999;128:271-279.
- Hutcheson KA, Drack AV, Elish NJ, Lambert SR. Anterior hyaloid face opacification after pediatric Nd:YAG laser capsulotomy. *J Aapos.* 1999;3:303-307.
- Jensen AA, Basti S, Greenwald MJ, Mets MB. When may the posterior capsule be preserved in pediatric intraocular lens surgery? *Ophthalmology.* 2002;109:324-327; discussion 328.
- Kilborn SH, Trudel G, Uthoff H. Review of growth plate closure compared with age at sexual maturity and lifespan in laboratory animals. *Contemp Top Lab Anim Sci.* 2002;41:21-26.
- Klaus G, Jux C, Fernandez P, Rodriguez J, Himmele R, Mehls O. Suppression of growth plate chondrocyte proliferation by corticosteroids. *Pediatr Nephrol.* 2000;14:612-615.
- Koch DD, Kohlen T. Retrospective comparison of techniques to prevent secondary cataract formation after posterior chamber intraocular lens implantation in infants and children. *J Cataract Refract Surg.* 1997;23:657-663.
- Krupin T, Waltman SR, Becker B. Ocular penetration in rabbits of topically applied dexamethasone. *Arch Ophthalmol.* 1974;92:312-314.
- Kugelberg U. Visual acuity following treatment of bilateral congenital cataracts. *Doc Ophthalmol.* 1992;82:211-215.
- Kugelberg U, Zetterstrom C, Lundgren B, Syren-Nordqvist S. Eye growth in the aphakic newborn rabbit. *J Cataract Refract Surg.* 1996;22:337-341.
- Kugelberg U, Zetterstrom C, Lundgren B, Syren-Nordqvist S. Ocular growth in newborn rabbit eyes implanted with a poly(methyl methacrylate) or silicone intraocular lens. *J Cataract Refract Surg.* 1997;23:629-634.

- Kugelberg U, Zetterstrom C, Syren-Nordqvist S. Ocular axial length in children with unilateral congenital cataract. *Acta Ophthalmol Scand.* 1996;74:220-223.
- Lambert SR, Buckley EG, Plager DA, Medow NB, Wilson ME. Unilateral intraocular lens implantation during the first six months of life. *J Aapos.* 1999;3:344-349.
- Lambert SR, Lynn M, Drews-Botsch C, Loupe D, Plager DA, Medow NB, Wilson ME, Buckley EG, Drack AV, Fawcett SL. A comparison of grating visual acuity, strabismus, and reoperation outcomes among children with aphakia and pseudophakia after unilateral cataract surgery during the first six months of life. *J Aapos.* 2001;5:70-75.
- Lane NE. An update on glucocorticoid-induced osteoporosis. *Rheum Dis Clin North Am.* 2001;27:235-253.
- Lesueur LC, Arne JL, Chapotot EC, Thouvenin D, Malecaze F. Visual outcome after paediatric cataract surgery: is age a major factor? *Br J Ophthalmol.* 1998;82:1022-1025.
- Lundgren B, Jonsson E, Rolfsen W. Secondary cataract. An in vivo model for studies on secondary cataract in rabbits. *Acta Ophthalmol Suppl.* 1992;205:25-28.
- Lundvall A, Kugelberg U. Outcome after treatment of congenital bilateral cataract. *Acta Ophthalmol Scand.* 2002;80:593-597.
- Lundvall A, Kugelberg U. Outcome after treatment of congenital unilateral cataract. *Acta Ophthalmol Scand.* 2002;80:588-592.
- Lundvall A, Kugelberg U, Lundgren B, vd Mooren M, Zetterstrom C. Intraocular lens designed for the newborn infant eye. *J Cataract Refract Surg.* 2001;27:928-933.
- Lundvall A, Zetterstrom C, Lundgren B, Kugelberg U. Effect of 3-piece AcrySof and downsized heparin-surface-modified poly(methyl methacrylate) intraocular lenses in infant rabbit eyes. *J Cataract Refract Surg.* 2003;29:159-163.
- Marcantonio JM, Vrensen GF. Cell biology of posterior capsular opacification. *Eye.* 1999;13:484-488.
- McClatchey SK, Dahan E, Maselli E, Gimbel HV, Wilson ME, Lambert SR, Buckley EG, Freedman SF, Plager DA, Parks MM. A comparison of the rate of refractive growth in pediatric aphakic and pseudophakic eyes. *Ophthalmology.* 2000;107:118-122.
- McGhee CN. Pharmacokinetics of ophthalmic corticosteroids. *Br J Ophthalmol.* 1992;76:681-684.

- McGhee CN, Dean S, Danesh-Meyer H. Locally administered ocular corticosteroids: benefits and risks. *Drug Saf.* 2002;25:33-55.
- McGhee CN, Noble MJ, Watson DG, Dutton GN, Fern AI, Healey TM, Midgley JM. Penetration of topically applied prednisolone sodium phosphate into human aqueous humour. *Eye.* 1989;3:463-467.
- McIlwain HH. Glucocorticoid-induced osteoporosis: pathogenesis, diagnosis, and management. *Prev Med.* 2003;36:243-249.
- Mehls O, Himmele R, Homme M, Kiepe D, Klaus G. The interaction of glucocorticoids with the growth hormone-insulin-like growth factor axis and its effects on growth plate chondrocytes and bone cells. *J Pediatr Endocrinol.* 2001;14 Suppl 6:1475-1482.
- Miyahara S, Amino K, Tanihara H. Glaucoma secondary to pars plana lensectomy for congenital cataract. *Graefes Arch Clin Exp Ophthalmol.* 2002;240:176-179.
- Novack GD. Ophthalmic beta-blockers since timolol. *Surv Ophthalmol.* 1987;31:307-327.
- O'Keefe M, Fenton S, Lanigan B. Visual outcomes and complications of posterior chamber intraocular lens implantation in the first year of life. *J Cataract Refract Surg.* 2001;27:2006-2011.
- O'Keefe M, Mulvihill A, Yeoh PL. Visual outcome and complications of bilateral intraocular lens implantation in children. *J Cataract Refract Surg.* 2000;26:1758-1764.
- Pandey SK, Wilson ME, Trivedi RH, Izak AM, Macky TA, Werner L, Apple DJ. Pediatric cataract surgery and intraocular lens implantation: current techniques, complications, and management. *Int Ophthalmol Clin.* 2001;41:175-196.
- Plager DA, Yang S, Neely D, Sprunger D, Sondhi N. Complications in the first year following cataract surgery with and without IOL in infants and older children. *J Aapos.* 2002;6:9-14.
- Rabiah PK. Frequency and predictors of glaucoma after pediatric cataract surgery. *Am J Ophthalmol.* 2004;137:30-37.
- Ram J, Brar GS, Kaushik S, Gupta A. Role of posterior capsulotomy with vitrectomy and intraocular lens design and material in reducing posterior capsule opacification after pediatric cataract surgery. *J Cataract Refract Surg.* 2003;29:1579-1584.
- Rosenblum C, Dengler RE, Jr., Geoffroy RF. Ocular absorption of dexamethasone phosphate disodium by the rabbit. *Arch Ophthalmol.* 1967;77:234-237.
- Schweitzer I, Maguire K, Tuckwell V. Antiglaucoma medication and clinical depression. *Aust N Z J Psychiatry.* 2001;35:569-571.

- Skoner DP, Rachelefsky GS, Meltzer EO, Chervinsky P, Morris RM, Seltzer JM, Storms WW, Wood RA. Detection of growth suppression in children during treatment with intranasal beclomethasone dipropionate. *Pediatrics*. 2000;105:E23.
- Spalton DJ. Posterior capsular opacification after cataract surgery. *Eye*. 1999;13 (Pt 3b):489-492.
- Spiess BM, Nyikos S, Stummer E, Sahin A, Naegeli H. Systemic dexamethasone concentration in horses after continued topical treatment with an ophthalmic preparation of dexamethasone. *Am J Vet Res*. 1999;60:571-576.
- Strauss AJ, Su JT, Dalton VM, Gelber RD, Sallan SE, Silverman LB. Bony morbidity in children treated for acute lymphoblastic leukemia. *J Clin Oncol*. 2001;19:3066-3072.
- Szeffler SJ. Pharmacokinetics of intranasal corticosteroids. *J Allergy Clin Immunol*. 2001;108:S26-31.
- Tan AY, LeVatte TL, Archibald ML, Tremblay F, Kelly ME, Chauhan BC. Timolol concentrations in rat ocular tissues and plasma after topical and intraperitoneal dosing. *J Glaucoma*. 2002;11:134-142.
- Taylor D, Vaegan, Morris JA, Rodgers JE, Warland J. Amblyopia in bilateral infantile and juvenile cataract. Relationship to timing of treatment. *Trans Ophthalmol Soc U K*. 1979;99:170-175.
- Tetz MR, Auffarth GU, Sperker M, Blum M, Volcker HE. Photographic image analysis system of posterior capsule opacification. *J Cataract Refract Surg*. 1997;23:1515-1520.
- Tonshoff B, Mehls O. Interaction between glucocorticoids and the somatotrophic axis.[see comment]. *Acta Paediatr Suppl*. 1996;417:72-75.
- Touati G, Prieur AM, Ruiz JC, Noel M, Czernichow P. Beneficial effects of one-year growth hormone administration to children with juvenile chronic arthritis on chronic steroid therapy. I. Effects on growth velocity and body composition. *J Clin Endocrinol Metab*. 1998;83:403-409.
- Vaegan, Taylor D. Critical period for deprivation amblyopia in children. *Trans Ophthalmol Soc U K*. 1979;99:432-439.
- Van Staa TP, Laan RF, Barton IP, Cohen S, Reid DM, Cooper C. Bone density threshold and other predictors of vertebral fracture in patients receiving oral glucocorticoid therapy. *Arthritis Rheum*. 2003;48:3224-3229.

- Vasavada A, Desai J. Primary posterior capsulorhexis with and without anterior vitrectomy in congenital cataracts. *J Cataract Refract Surg.* 1997;23 Suppl 1:645-651.
- Vasavada AR, Trivedi RH, Singh R. Necessity of vitrectomy when optic capture is performed in children older than 5 years. *J Cataract Refract Surg.* 2001;27:1185-1193.
- Watts P, Abdolell M, Levin AV. Complications in infants undergoing surgery for congenital cataract in the first 12 weeks of life: is early surgery better? *J Aapos.* 2003;7:81-85.
- Weakley DR, Birch E, McClatchey SK, Felius J, Parks MM, Stager D, Jr. The association between myopic shift and visual acuity outcome in pediatric aphakia. *J Aapos.* 2003;7:86-90.
- Wejde G, Kugelberg M, Zetterstrom C. Position of anterior capsulorhexis and posterior capsule opacification. *Acta Ophthalmol Scand.* 2004;82:531-534.
- Vidal O, Lindberg MK, Hollberg K, Baylink DJ, Andersson G, Lubahn DB, Mohan S, Gustafsson JA, Ohlsson C. Estrogen receptor specificity in the regulation of skeletal growth and maturation in male mice. *Proc Natl Acad Sci U S A.* 2000;97:5474-5479.
- Wilson JR, Fernandes A, Chandler CV, Tigges M, Boothe RG, Gammon JA. Abnormal development of the axial length of aphakic monkey eyes. *Invest Ophthalmol Vis Sci.* 1987;28:2096-2099.
- Wilson ME, Bluestein EC, Wang X-H. Current trends in the use of intraocular lenses in children. *J Cataract Refract Surg.* 1994;20:579-583.
- Windahl SH, Vidal O, Andersson G, Gustafsson JA, Ohlsson C. Increased cortical bone mineral content but unchanged trabecular bone mineral density in female ERbeta(-/-) mice. *J Clin Invest.* 1999;104:895-901.
- Wood C, Sweet D, Contaxis I, Van Dolah J. Response of rabbits to corticosteroids. II. Influence of topical therapy on lens, aqueous humor, serum and urine composition. *Am J Ophthalmol.* 1967;63:849-856.
- Wood DC, Contaxis I, Sweet D, Smith JC, Van Dolah J. Response of rabbits to corticosteroids. I. Influence on growth, intraocular pressure and lens transparency. *Am J Ophthalmol.* 1967;63:841-849.
- Yamada Y, Takayanagi R, Tsuchiya K, Ito K, Ohtani H, Sawada Y, Iga T. Assessment of systemic adverse reactions induced by ophthalmic beta- adrenergic receptor antagonists. *J Ocul Pharmacol Ther.* 2001;17:235-248.
- Zetterstrom C. Intraocular lens implantation in the pediatric eye. *J Cataract Refract Surg.* 1997;23:599-600.

- Zetterstrom C. Cataract surgery in the pediatric eye. In: Cataract surgery in complicated cases, L. Buratto, R. H. Osher and S. Masket, Editors. Milano, SLACK Inc., Thorofare, NJ, USA, 2000; 1-14
- Zetterstrom C, Kugelberg U. Influence of lens implantation on lens and ocular growth. *Op Tech in Cat Refr Surg.* 1998;1:165-168.
- Zetterstrom C, Kugelberg U, Lundgren B, Syren-Nordqvist S. After-cataract formation in newborn rabbits implanted with intraocular lenses. *J Cataract Refract Surg.* 1996;22:85-88.
- Zetterstrom C, Kugelberg U, Oscarson C. Cataract surgery in children with capsulorhexis of anterior and posterior capsules and heparin-surface-modified intraocular lenses. *J Cataract Refract Surg.* 1994;20:599-601.
- Zwaan J, Mullaney PB, Awad A, Al-Mesfer S, Wheeler DT. Pediatric intraocular lens implantation. *Ophthalmology.* 1998;105:112-119.

14 Papers I-V