

From the Department of Clinical Neuroscience
Division of Ophthalmology and Vision
Karolinska Institutet, St Erik's Eye Hospital, Stockholm, Sweden

**POSTERIOR CAPSULE OPACIFICATION
AND
POSTOPERATIVE ENDOPHTHALMITIS
FOLLOWING CATARACT SURGERY**

Predictive and Protective Factors

Gisela Wejde



Stockholm 2005

All previously published papers were reproduced with permission from the publisher.

Printed by Repro Print AB
Box 21085, SE-100 31 Stockholm, Sweden
© Gisela Wejde, 2005
ISBN 91-7140-291-8

To Johan, Ellen and Björn

POSTERIOR CAPSULE OPACIFICATION AND ENDOPHTHALMITIS FOLLOWING CATARACT SURGERY

Predictive and Protective factors

Gisela Wejde

Department of Clinical Neuroscience

Division of Ophthalmology and Vision

Karolinska Institutet, St Erik's Eye Hospital, Stockholm, Sweden

ABSTRACT

Modern cataract surgery with implantation of an intraocular lens (IOL) is an increasingly safe and successful procedure, though complications still occur. This thesis addresses the most common complication, posterior capsule opacification (PCO) and the rare but serious complication postoperative endophthalmitis (POE).

The pathogenesis of PCO is multifactorial and several surgical and IOL-related factors appear to play an important role in PCO formation. In this project the relation of PCO to IOLs of different materials and design was investigated and, furthermore, the association between PCO and the anterior capsulorhexis position. In a prospective study, patients were randomized to have implantation of a heparin-surface-modified (HSM) poly(methyl methacrylate) (PMMA) IOL, a silicone IOL or a hydrophobic acrylic IOL after phacoemulsification (phaco). The HSM PMMA and the silicone IOL have rounded optic edges and the acrylic IOL has a sharp-edged optic. The PCO was assessed using the Evaluation of Posterior Capsule Opacification (EPCO) analysis system. After 2 years, patients with a hydrophobic acrylic IOL had significantly less PCO compared to those with a silicone or a HSM PMMA IOL. Three years postoperatively, the position of capsulorhexis in the silicone group and the acrylic group, were retrospectively analysed. Patients with the rhexis completely on the IOL optic had significantly less PCO than those with a decentred rhexis.

Because of the potentially serious outcome after POE, various prophylactic regimes are used and putative risk factors are analysed. The object of this project was the investigation of the efficacy and safety of a previous undescribed prophylactic mode against POE, an intracameral injection of cefuroxime. Pharmacokinetic data on intraocular cefuroxime was analysed. Visual acuity, endothelial cell loss, laser flare intensity and IgE-mediated hypersensitivity were assessed. Furthermore, the project included a single-centre, retrospective clinical observation study of POE in association with prophylactic intracameral cefuroxime. National data on POE were investigated in a multi-centre prospective observational study and risk factors for POE were analysed in a single-centre case-control study. The studies showed that intracameral prophylactic cefuroxime appears safe and confers protection against POE, the latter in the sense that traditionally common species causing POE, such as staphylococci no longer are main aetiologies. Also, the general incidence of POE was very low.

Key words: posterior capsule opacification, postoperative endophthalmitis, cataract surgery, capsulorhexis, intraocular lens, acrylic hydrophobic IOL, HSM PMMA IOL, silicone IOL, round edge, sharp edge, prophylaxis, cefuroxime

ISBN 91-7140-291-8

LIST OF PAPERS

This thesis is based on the following original articles, which are referred to by their Roman numerals:

- I. Wejde G, Kugelberg M, Zetterström C. Posterior capsule opacification: Comparison of 3 intraocular lenses of different materials and design. *J Cataract Refract Surg* 2003; 29: 1556-1559.
- II. Wejde G, Kugelberg M, Zetterström C. Position of anterior capsulorhexis and posterior capsule opacification. *Acta Ophthalmol Scand* 2004; 82: 531-534.
- III. Montan PG, Wejde G, Koranyi G, Rylander M. Prophylactic intracameral cefuroxime. Efficacy in preventing endophthalmitis after cataract surgery. *J Cataract Refract Surg* 2002; 28: 977-981.
- IV. Montan PG, Wejde G, Setterquist H, Rylander M, Zetterström C. Prophylactic intracameral cefuroxime. Evaluation of safety and kinetics in cataract surgery. *J Cataract Refract Surg* 2002; 28: 982-987.
- V. Wejde G, Montan PG, Lundström M, Stenevi U, Thorburn W. Endophthalmitis following cataract surgery in Sweden: national prospective survey 1999-2001. *Acta Ophthalmol Scand* 2005; 83: 7-10.
- VI. Wejde G, Samolov B, Seregard S, Koranyi G, Montan PG. Risk factors for endophthalmitis following cataract surgery. A retrospective case-control study. Submitted.

CONTENTS

ABBREVIATIONS	9
INTRODUCTION	11
Background	11
Posterior capsule opacification	12
Postoperative endophthalmitis	15
AIMS OF THE STUDY	17
MATERIALS AND METHODS	18
Posterior capsule opacification, papers I and II	18
PCO in association with IOL materials and design and in relation to the position of anterior capsulorhexis (I, II)	18
Intraocular lenses (I, II)	18
Ethics (I, II)	18
Surgery (I, II)	19
Follow-up (I, II)	19
Evaluation of Posterior Capsule Opacification (I, II)	19
Position of anterior capsulorhexis (II)	19
Statistics (I, II)	20
Postoperative endophthalmitis, papers III-VI	20
Single-centre epidemiology of POE in association with prophylactic intracameral cefuroxime (III)	21
Clinical definitions of POE	21
Cultures and medical treatment	21
Prophylactic protocol	21
Statistics	22
Safety and kinetics of intracameral cefuroxime in cataract surgery (IV)	22
Evaluation of visual acuity, endothelial counts and laser flare in association with intracameral cefuroxime	22
Immunoglobulin E-mediated hypersensitivity to cefuroxime	23
Intraocular concentrations of cefuroxime	23
Statistics	23

Multi-centre prospective observational study on POE frequency after cataract surgery (V)	24
Prophylaxis regimen survey	24
Diagnosis and therapy	24
Statistics	24
Single-centre retrospective case-control study of risk factors for POE following cataract surgery (VI)	25
Investigated variables	25
Prophylaxis Regimen	25
Statistics	26
RESULTS AND DISCUSSION	27
Posterior capsule opacification	27
Two years follow-up of 3 IOLs with different materials and design (I)	27
Position of anterior capsulorhexis and influence on PCO (II)	29
Postoperative endophthalmitis	32
Single-centre epidemiology of POE and prophylactic cefuroxime (III)	32
Safety and kinetics of intracameral cefuroxime (IV)	34
Visual acuity, endothelial cell loss and laser flare intensity in association with cefuroxime	34
IgE-mediated hypersensitivity to cefuroxime	35
Pharmacokinetic data on intraocular cefuroxime	35
National data on POE frequency (V)	36
Risk factors for POE (VI)	37
SUMMARY AND PERSPECTIVES	40
ACKNOWLEDGEMENTS	42
REFERENCES	44

ABBREVIATIONS

AQUA	Automated Quantification of After-cataract
BAB	blood aqueous barrier
BCVA	best-corrected visual acuity
BRB	blood retina barrier
CCC	continuous curvilinear capsulorhexis
CF	counting fingers
CI	confidence interval
CME	cystoid macular edema
ECCE	extracapsular cataract extraction
EPCO	Evaluation of Posterior Capsule Opacification
EVS	European Vitrectomy Study Group
HSM	heparin surface modified
ICCE	intracapsular cataract extraction
IgE	immunoglobulin E
IOL	intraocular lens
LEC	lens epithelial cell
MIC	minimal inhibitory concentration
NCR	National Cataract Register
Nd:YAG	neodymium: yttrium aluminium garnet
NLP	no light perception
OVD	ophthalmic viscoelastic device
PC	posterior chamber
PCO	posterior capsule opacification
Phaco	phacoemulsification
POCOman	Posterior Capsule Opacification manual
POE	postoperative endophthalmitis
PMMA	poly(methyl methacrylate)
SPSS	Statistical Package for the Social Sciences

INTRODUCTION

Background

Cataract is the most common cause of visual impairment and there are approximately 20 million people blind from this condition in the world (Foster 1999). The prevalence of cataract increases with age and is slightly higher among women (Kahn et al. 1977; Klein et al. 1992). Lens opacities are found in more than 70% of all people over 75 years of age (Kahn et al. 1977; Klein et al. 1998) and according to one investigation, approximately 30% of the population over 70 years of age will eventually undergo cataract surgery (Hirvela et al. 1995).

Cataract operation is the most common surgical procedure in Sweden today. According to the Swedish National Cataract Register, the number of extractions increased from approximately 7000 to 77 500 during 1980 – 2004 (Figure 1). There was a large increase in the 1980s, when the implantation of an intraocular lens (IOL) and the use of ophthalmic viscoelastic device (OVD) became the standard procedures. Also in the 1990s, the increase was large because of modification of the surgical technique with phacoemulsification (phaco). The procedure has become increasingly safe (Apple et al. 1992), but complications still occur. This thesis addresses the most common complication, posterior capsule opacification (PCO) (Apple et al. 1992; Schaumberg et al. 1998; Schmidbauer et al. 2001) and the rare but serious complication, postoperative endophthalmitis (POE) (Javitt et al. 1991; Norregaard et al. 1997; Aaberg et al. 1998).

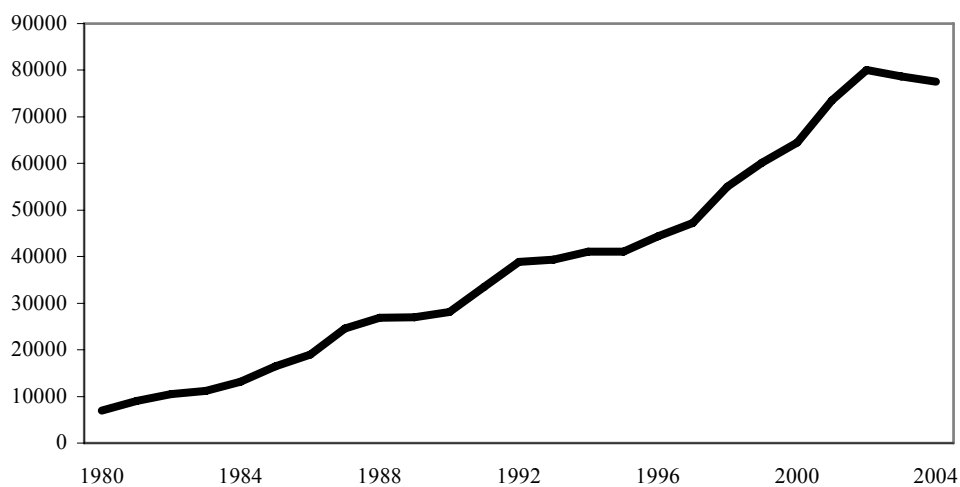


Figure 1. Cataract extractions in Sweden, annual volume.

Posterior capsule opacification

Posterior capsule opacification in the centre usually causes a decrease in visual acuity by direct blockage of the visual axis (Figure 2).

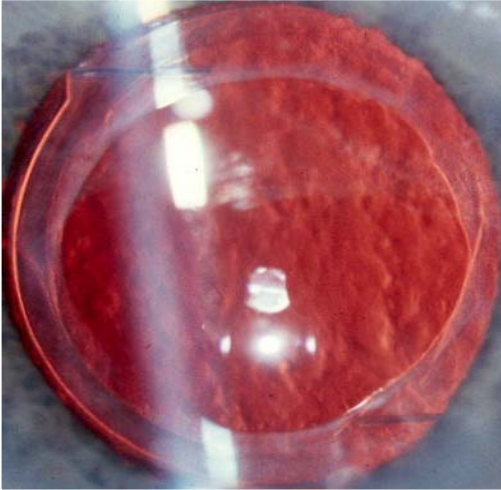


Figure 2. Dense posterior capsule opacification.

PCO formation is related to age and, in general, there is a lower incidence of PCO among older patients (Apple et al. 1992).

The treatment of PCO is capsulotomy of the posterior capsule and is usually performed with neodymium: yttrium-aluminium-garnet (Nd:YAG) laser (Figure 3).

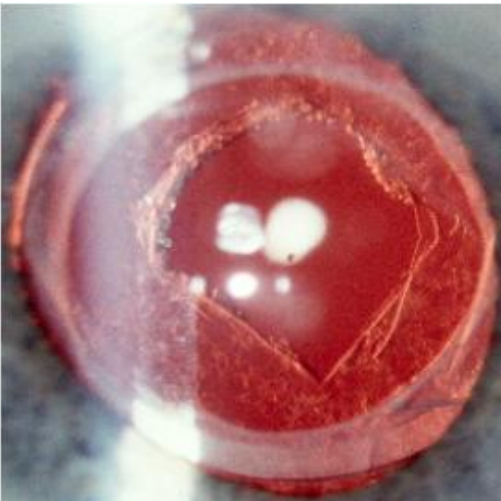


Figure 3. Capsulotomy of the posterior capsule.

Only in children and in cases with very dense membranes, a secondary invasive posterior capsulotomy is performed (Apple et al. 1992). In small children the prevention and treatment of PCO also includes primary posterior capsulorhexis and anterior vitrectomy (Vasavada & Desai 1997; Kugelberg & Zetterström 2002). Clinical studies have reported varying incidences of Nd:YAG treatment of PCO, decreasing from 50% in the 1980s (Apple et al. 1992) to less than 10% currently (Apple et al. 2001; Pandey et al. 2004). There are some disadvantages with ND:YAG laser therapy. Vision threatening complications may occur such as cystoid macular edema, postoperative intraocular pressure elevation, retinal detachment, damage to the intraocular lens and IOL luxation (Steinert et al. 1991; Apple et al. 1992; Javitt et al. 1992; Holweger & Marefat 1997; Newland et al. 1999; Ge et al. 2000). With the relatively high incidence of PCO, a Nd:YAG capsulotomy has become a commonly performed ophthalmic surgical procedure and therefore significantly raises the overall cost of cataract treatment (Steinberg et al. 1993).

Posterior capsule opacification is also referred to as after-cataract and the mechanism is still not completely understood. In fact the posterior capsule itself is not primarily involved, but the opacification process adjacent to the posterior capsule is caused by proliferation and migration of residual lens epithelial cells (LECs) and their derivatives after surgery (Apple et al. 1992). The LECs, having the potential to produce significant opacification, are remaining cuboidal cells from the anterior capsule and epithelial cells at the equatorial lens bow (Marcantonio & Vrensen 1999). These cells form membranes and/or clusters of swollen, opacified epithelial pearls, Elschnig pearls, and it is suggested that anterior epithelial cells mainly cause the fibrosis form and the equatorial cells cause the pearl form of PCO (McDonnell et al. 1983). Clinically, the fibrosis-type of PCO tends to appear sooner (within 6 months) than epithelial pearls which often appear after several months or years (Apple et al. 1992). Furthermore, development of PCO appears to be a dynamic process and tendency to regression of LECs with polyacrylic IOLs over a 2-year period has been described (Hollick et al. 1998). Recently, re-organization and even disappearance of Elschnig pearls was reported (Findl et al. 2004). Besides decreased visual acuity, the fibrosis may cause wrinkling of the posterior capsule (McDonnell et al. 1983) and may give rise to visual distortions including glare (Holladay et al. 1985).

Several authors have performed meta-analyses of published articles on PCO and they conclude that no single causative mechanism has been recognized but several surgical and

IOL related factors appear to play a major role in PCO formation (Schaumberg et al. 1998; Schmidbauer et al. 2001). Thorough removal of LECs and cortical remnants is important in the prevention of PCO (Peng et al. 2000). Pseudophakia lessens PCO compared to aphakia (Zetterström et al. 1996). It is suggested that in the bag-fixation of the IOL may help in reducing PCO (Ram et al. 1999). For instance, the IOL can act as a barrier against the migration of residual LECs (Hansen et al. 1988; Peng et al. 2000a) and the IOL material appears to be a major determinant for this effect (Hollick et al. 1998; Ursell et al. 1998; Hollick et al. 1999; Ram et al. 2001). Also the design of the IOL appear to be important in prevention of PCO and less PCO was reported with a sharp-edged IOL than with a round-edged IOL (Nishi et al. 1998; Kruger et al. 2000; Nishi et al. 2000; Nishi et al. 2001). Furthermore, the size and position of the continuous curvilinear capsulorhexis (CCC) has been suggested to influence PCO (Ravalico et al. 1996; Hollick et al. 1998). It is hypothesized that LECs more easily migrate from the anterior capsule on to the posterior capsule if the capsulorhexis margins are partially or totally outside the IOL optics (Meacock et al. 2001).

Postoperative endophthalmitis

Any surgical procedure may be complicated by infection. In open globe surgery, invasion of bacteria into the anterior chamber and the vitreous may occur resulting in postoperative endophthalmitis. Patients typically present with sudden onset of ocular pain, reduced vision, conjunctival hyperaemia, lid swelling and hypopyon (Endophthalmitis Vitrectomy Study Group 1995; Mamalis et al. 2002) (Figure 4). Most cases, approximately 75%, appear within 10 days postoperatively and another 20% within 11 to 30 days after surgery (Montan et al. 1998). Late onset infections, i.e. later than four weeks, are often caused by less virulent bacteria and those cases can be difficult to differ from sterile postoperative inflammation.

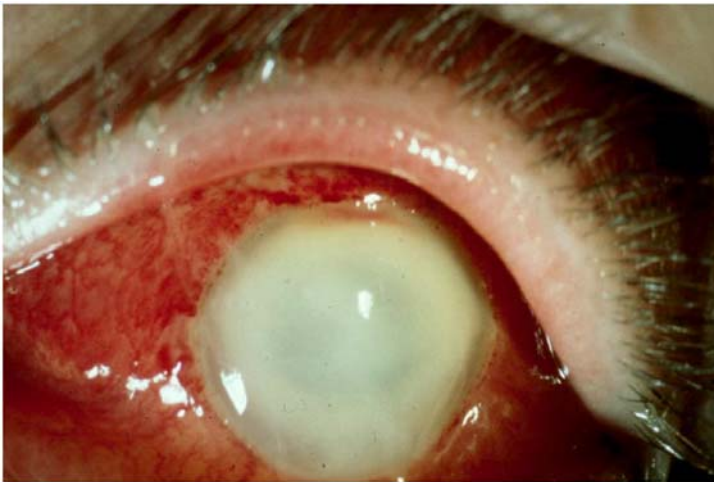

Figure 4. Acute postoperative endophthalmitis.

Consequences for the eye may be devastating since the avascular state of the vitreous and the sparse vasculature of the retina provide poor immediate defence against bacteria. The toxins produced by Gram-negative organisms and *Staphylococcus aureus* have proved to be particularly deleterious to the retina (Meyers-Elliott & Dethlefs 1982; Booth et al. 1995). Also streptococci and enterococci are associated with a poor visual outcome (Mao et al. 1992; Endophthalmitis Vitrectomy Study Group 1996; Mamalis et al. 2002). It is assumed that pH-changes and consumption of oxygen induced by the infection have an influence on the inflammatory response. In a rabbit-model, an altered permeability of the vessels, mainly in the anterior segment of the eye, was reported as early as three hours after intravitreal injection of an endotoxin (Howes et al. 1994). An early breakdown of the blood-retinal barrier (BRB) has also been described (Metrikin et al. 1995).

Complications of POE result in severe visual loss with visual acuity of less than 20/200 in at least 30 -50% of all patients (Aaberg et al. 1998; Montan et al. 1998; Doft et al. 2000). It is hypothesized that the most common source of POE is the patients' external flora (Sherwood et al. 1989; Speaker et al. 1991). Gram-positive organisms, mostly coagulase-negative staphylococci, are the dominant causes of culture-proven POE (Endophthalmitis Vitrectomy Study Group 1996; Montan et al. 1998; Montan et al. 2002).

Because of the potentially serious outcome after POE, various prophylactic regimes are used. The frequency of POE has decreased over the last two decades and incidence averages of 0.1% or even less have been reported in multi-centre studies (Javitt et al. 1994; Aaberg et al. 1998; Montan et al. 2002) It is suggested that this improvement could in part be explained by the use of prophylactic intracameral antibiotics (Gills 1987; Gimbel et al. 1994; Schmitz et al. 1999), but there are no prospective randomized double-masked controlled studies within this area to provide evidence of efficacy of any regime as stated in an evidence-based meta-analysis (Ciulla et al. 2002). The authors state that current literature indicates a relative support of the use of povidone-iodine as a preoperative disinfectant but in the referred to prospective study, povidone-iodine was used in combination with a variety of anti-infective compounds (Speaker & Menikoff 1991).

Cefuroxime, the studied drug in this thesis, is a 2nd generation cephalosporin, with a fair antibacterial coverage against Gram-positive species. It has a bactericidal effect and interferes with bacterial cell wall synthesis. The killing action is time-dependent.

A number of investigations have been conducted with the aim of identifying risk factors for the development of POE. With such information, various preventive measures could be implemented to lessen the incidence of POE. General health conditions of the cataract patient and various features of the operation technique have been pinpointed as risk factors, but the results have not been consistent (Kattan et al. 1991; Menikoff et al. 1991; Javitt et al. 1994; Montan et al. 1998; Nagaki et al. 2003; Wong & Chee 2004). It is also reasonable to believe that intraoperative complications increase the risk of POE, but the results from several studies are not conclusive (Javitt et al. 1991; Menikoff et al. 1991; Norregaard et al. 1997; Wong & Chee 2004).

AIMS OF THE STUDY

- To study posterior capsule opacification after cataract surgery in relation to different intraocular lenses (I, II).
- To study the effect of the position of anterior capsulorhexis on posterior capsule opacification (II).
- To evaluate the efficacy and the safety of a hitherto undescribed prophylactic mode against postoperative endophthalmitis using an intracameral injection of cefuroxime (III, IV).
- To identify risk factors and protective factors for postoperative endophthalmitis in a large surgical unit and in a nation-wide survey (III, V, VI).

MATERIALS AND METHODS

Posterior capsule opacification, papers I and II

With the aim of determining the extent of PCO and its possible dependence on different lens materials and design, a prospective randomized trial was performed (I). Two thirds of the participating cohort in paper I was retrospectively reviewed for an association between PCO and the position of the anterior capsulorhexis (II).

PCO in association with IOL materials and design and in relation to the position of anterior capsulorhexis (I, II)

The prospective study (I) included 180 eyes of 180 patients who had uneventful, standardized cataract surgery with phacoemulsification. Patients were between 61 and 86 years old and had no ocular pathology except cataract and non-serious macular degeneration. Patients with diabetes mellitus or on current steroid therapy were not included. In the retrospective study (II), the same cohort with the exception of those implanted with a poly(methyl methacrylate) (PMMA) lens with a different optic size was studied.

Intraocular lenses (I, II)

The patients were randomized to have implantation of 1 of 3 types of IOLs. A single-piece heparin-surface-modified (HSM) PMMA IOL (809C, Pharmacia & Upjohn) with an optic diameter of 5.0 mm was implanted in 61 patients. Sixty patients received a foldable 3-piece silicone IOL (SI-40NB, Allergan) with an optic diameter of 6.0 mm and 59 patients received a foldable, hydrophobic acrylic IOL (AcrySof[®] MA60BM, Alcon) with an optic diameter of 6.0 mm. The MA60BM has a sharp-edged optic and the 809C and SI-40NB have rounded-edged optics.

Ethics (I, II)

Approval from the local ethics committee was given for the studies and informed consent was obtained before surgery from all patients participating in the study.

Surgery (I, II)

Cataract surgery was performed by the same surgeon (C.Z.) at St Erik's Eye Hospital between 1995 and 1998 using a standardized procedure. The surgery was performed through a corneoscleral incision and a CCC approximately 4.5 to 5.5 mm wide was created under the protection of Healon[®]. Hydrodissection and hydrodelineation were performed using balanced salt solution (BSS[®]). Phacoemulsification was performed and cortical lens material was aspirated. An IOL was implanted in the bag and the wound closure was left unsutured in all cases. Postoperatively, topical 0.1% dexamethasone (Isopto-Maxidex[®]) was prescribed 3 times a day for 1 week and 2 times a day for 2 weeks.

Follow-up (I, II)

Postoperative examinations were performed with visual acuity assessment and retroillumination photographing after 2 and 3 years to evaluate potential PCO.

The Nd:YAG rate was recorded and analysed at the 2-year visit.

Evaluation of Posterior Capsule Opacification (EPCO) (I, II)

To evaluate PCO, a retroillumination photograph was taken through a dilated pupil using slitlamp and photographic set-up. The images were digitized and imported into the EPCO computer-analysis system (Tetz et al. 1997). With EPCO, the PCO density is interactively scored on a scale from 0 to 4 and then multiplied by the fractional area involved. The EPCO classification is as follows: 0 = none; 1 = minimal (mild capsule wrinkling, mild homogeneous layers or sheets of LECs); 2 = mild (honeycomb pattern of PCO, thicker homogeneous layers, denser fibrosis); 3 = moderate (classic Elschnig pearls, very thick homogeneous layer); 4 = severe (very thick Elschnig pearls with "darkening effect" and severe opacification).

Position of anterior capsulorhexis (II)

Images from patients with MA60BM and SI-40NB IOLs were analysed 3 years postoperatively. The relationship of the anterior capsulorhexis margin to the optic edge of the IOL was assessed on the retroillumination images by an independent not surgically trained co-worker, on a separate occasion from the PCO assessment to avoid bias. The position of the rhexis was graded as either completely on the optic (rhexis group 1) or at least partly off the optic (rhexis group 2).

Statistics (I, II)

The PCO density scores of each patient in the different IOL groups were ranked from the lowest to the highest. After Nd:YAG capsulotomy, patients were discontinued from further image analyses and their score imputed as the highest rank was carried forward throughout the study.

In paper I, the PCO data were computed with Kruskal-Wallis 1-way analysis of variance by ranks with additional multiple comparisons. The Nd:YAG rate in relation to the three lens types was analysed using Pearson chi-squared test (paper I). In paper II, the PCO density score data were analysed using Wilcoxon's two-sample rank test. A p-value of <0.05 was defined as significant.

Postoperative endophthalmitis, papers III-VI

The aims of these studies were to evaluate a previously not used prophylactic program to prevent postoperative endophthalmitis and to investigate the epidemiology and potential risk factors for POE. In our clinic, St Erik's Eye Hospital, prophylactic programs with either subconjunctival gentamicin or with topical gentamicin had proved to be insufficient against the targeted strains of bacteria (Montan et al. 1998; Montan et al. 2000). In January 1996 the prophylactic program was changed and a postoperative intracameral injection of 1 mg of cefuroxime was added to the prophylactic protocol. The efficacy (paper III) and the safety (paper IV) of this new regime were evaluated in non-controlled observational studies.

In Sweden, a national database, the Swedish National Cataract Register (NCR), was established in January 1992 (Stenevi et al. 1995) to gather nation-wide data on cataract extractions. From 1998 and onward, the participating clinics have committed to supply data on all cases of POE. Within the framework of NCR, the epidemiology of POE and potential risk factors were investigated during a 3-year period in a prospective observational study (paper V). Furthermore, a single-centre retrospective case-control study was conducted at St Erik's, to relate incidents of POE to various parameters of patient history, operation techniques and the use of different prophylactic regimes.

Single-centre epidemiology of POE in association with prophylactic intracameral cefuroxime (III)

In paper III, a retrospective clinical observational study was performed on cases of POE occurring after all uncombined cataract operations at St. Erik's Eye Hospital from January 1996 through December 2000. All patient charts in the hospital are computerized and all patients with presumed postsurgical infections are registered since 1990. The POE rate associated with the use of intracameral injection of cefuroxime was calculated and compared with historical data on POE rates from 1990 to 1995 (Montan et al. 1998; Montan et al. 2000).

Clinical definitions of POE

A presumed postoperative endophthalmitis case was defined as any patient experiencing unexpectedly intense postoperative inflammation warranting intraocular fluid sampling for microbiological analyses. Culture negative cases were deemed as probably infected unless an alternative cause of inflammation was unveiled.

Cultures and medical treatment

Cultures were evaluated according to current standard methods (Murray 1995). Medical treatment of POE included intravitreal injections of ceftazidime 2.27 mg and vancomycin 1 mg, subconjunctival injections of ceftazidime 100 mg and vancomycin 25 mg and systemic steroids. Eyes with light perception visual acuity were immediately vitrectomized in accordance with evidence presented by the Endophthalmitis Vitrectomy Study Group (EVS) (Endophthalmitis Vitrectomy Study Group 1995).

Prophylactic protocol

The antibiotic solution, which was instilled in the capsular bag at the completion of the surgery, consisted of 1 mg cefuroxime in 0.1 mL 0.9% saline (Zinacef[®], Pharmacia & Upjohn). The antimicrobial prophylactic protocol further included a topical preparation with 2 drops of 0.3% gentamicin (Gentamicin Sulfate[®]), which were omitted in June 1998, and rinsing of the conjunctiva with 0.05% chlorhexidine solution 5 minutes before surgery. The lid margins were draped with sterile plastic cover and the periocular zone was disinfected with 0.5% chlorhexidine alcohol.

No other preoperative or postoperative antibiotics were routinely used during the study period.

Statistics

Pearson chi-squared test was used for categorical data. A p-value < 0.05 was defined as significant.

Safety and kinetics of intracameral cefuroxime in cataract surgery (IV)

Evaluation of visual acuity, endothelial cell counts and laser flare intensity in association with intracameral cefuroxime

This study investigates the safety of the prophylactic protocol, previously described in paper III, page 21. The solution pH and osmolality were determined. Analyses were made to identify potential side effects of the antibiotic on the corneal endothelium, blood-aqueous barrier (BAB), and visual recovery. This observer-masked study used safety and functional data generated from the cataract patients participating in the prospective clinical trial described in paper I, see page 18 for enrolment criteria of study population and page 19 for description of the surgery. When that study had completed two thirds of the total enrolment, intracameral cefuroxime was added to the prophylactic regimen, which until then had consisted of preoperative topical antibiotics and disinfectant only. Thus, safety data from cases that had received the intracameral prophylaxis and from those that had been treated with topical anti-infectants only could be compared. Ninety participants were selected at random, but the study group was stratified according to the lens material, yielding 15 patients receiving intraocular antibiotics and 15 controls per lens type.

The best-corrected visual acuity was recorded 3 months after surgery.

Corneal endothelial cell counts, expressed as cells/mm², were assessed immediately before and 3 months after surgery with a Topcon SP-1000 noncontact specular microscope. The cells were counted with the IMAGENet-640 (Topcon Corp.) cell-analysis program.

The aqueous protein concentration, expressed as photons/millisecond, was measured with the Kowa 500 laser flare photometer. Readings were done 30 minutes after pupil dilation with a topical mixture of 0.75% cyclopentolate and 2.5% phenylephrine. This examination was done before surgery as well as 1 and 3 days and 3 months postoperatively.

Immunoglobulin E-mediated hypersensitivity to cefuroxime

In 1997 the frequency of immunoglobulin E (IgE) mediated hypersensitivity to cefuroxime was recorded. In patients who reported probable systemic anaphylaxis related to the use of penicillins and cephalosporins, a skin prick test was performed. The skin prick test was done with cefuroxime in 250 mg/mL solution. A weal larger than 3.0 mm that developed within 15 minutes was deemed positive.

Intraocular concentrations of cefuroxime

The pharmacokinetics of intracameral administration was analysed in a prospective observer-masked investigation including 20 cataract patients. Patients were enrolled if they met the same entry criteria as in the safety study assessing visual acuity, endothelial cell counts and effects on BAB. The local ethics committee approved the investigation and informed consent was obtained from each participant.

The 20 patients had uneventful phacoemulsification performed by one of two surgeons (H.S., P.G.M.) with implantation of a foldable 5.5 mm silicone IOL (SI-55NB, Allergan Optics) through a 3.2 mm scleral incision at the 12 o'clock position. Thirty seconds after the instillation of cefuroxime, 0.1 mL of aqueous humor was collected in 10 patients via the side port with a blunt 27-gauge cannula attached to a syringe. In another 10 patients, the collection was done 60 minutes after the operation.

The samples were kept at -70°C until further analysis. An agar diffusion method was used for concentration assays. The samples were tested together with 2-fold standard serial dilutions of cefuroxime prepared in PBS and an independent internal control in duplicate.

Statistics

Pearson chi-squared test was used for categorical data. As the continuous variables were not normally distributed, the Mann-Whitney test was used for independent variable comparisons between groups. A p-value < 0.05 was considered significant.

Multi-centre prospective observational study on POE frequency after cataract surgery (V)

The data were collected within the framework of the Swedish National Cataract Register (NCR). During the study period, all surgical units in Sweden except one participated. The clinics report all POE cases, including culture-proven cases and presumed cases with a negative culture. The case report consist of two forms, the first of which requires the date of suspected diagnosis and intraocular culture samples, while the second, to be completed about 3 months later, asks for information on the type of isolated organism, the prophylactic regime and present visual acuity. At the end of every year, all clinics are asked to verify the reported cases of POE. Reminders are issued also to clinics that have not reported any cases primarily. Parameters as patient gender and age, operation technique and lens material are also reported to the database.

Prophylaxis Regimen Survey

Every clinic reports their current use of prophylactic method in the month of December and whether this practice has been subject to change in the previous year. The material was dichotomized into intracameral antibiotics administered as bolus injections or in infusion fluid (regardless of additional topical anti-infectives) and ocular surface antibiotics only, given either as topical antibiotics or as subconjunctival injections, or both.

Diagnosis and Therapy

Guidelines concerning diagnostic and therapeutic management of POE in line with the presented evidence from the EVS (Endophthalmitis Vitrectomy Study Group 1995; Barza et al. 1997), are accessible to the ophthalmic community in an extensive document available on the internet. Gold standard methods including solid media and enrichment broths for both aerobic and anaerobic cultures of intraocular samples from endophthalmitis cases are described in a document published in 1994 by the Swedish institute for infectious disease control.

Statistics

All statistical evaluations were done with the Statistical Package for the Social Sciences (SPSS) for MS Windows (10.0 version). Pearson chi-squared test was employed in univariate analyses to explore the association between categorical variables and the development of POE

and confidence intervals for odds ratios were calculated. A logistic regression model was subsequently used. A p-value of < 0.05 was defined as significant.

Single-centre retrospective case-control study of risk factors for POE following cataract surgery (VI)

This case-control study was performed at St. Erik's Eye Hospital. All presumed POE cases among patients who underwent uncombined cataract operation or cataract operation combined with trabeculectomy from January 1994 through December 2000 were retrospectively reviewed. For this investigation, four control cases were randomly selected for every POE case reflecting the operation volume for each year. All information was retrieved from the computerized patient charts and from the register of all presumed postsurgical infections at the hospital. The local ethics committee approved the investigation.

Investigated variables

Parameters pertaining to patient history and to peroperative technique and complications were analysed. The analysed variables were: (1) age, (2) gender, (3) diabetes defined as use of oral antidiabetic medication and/or insulin 4) immunosuppressive treatment (systemic treatment with steroids, antimetabolites, alkylating agents, cyclosporine A or topical steroids), (5) use of prophylactic cefuroxime in the capsular bag or no such use, (6) operation technique (phacoemulsification, extra- or intracapsular cataract extraction or combined cataract extraction with trabeculectomy), (7) lens material (HSM PMMA, silicone, acrylic, hydrogel or no intraocular lens), (8) lens position (in the posterior chamber or anterior chamber or no lens used), (9) communication with vitreous, (10) loss of vitreous, (11) wound dehiscence.

Prophylaxis Regimen

During the study period the infection prophylaxis in our clinic was changed, illustrated in Figure 5. The preoperative preparation in 1994 and 1995 consisted of 0.3% gentamicin eye-drops given 4 times in 45 minutes and chlorhexidine solution 0.05% 10 ml irrigation of the conjunctiva 5 minutes before the start of the operation. In January 1996 1 mg cefuroxime in 0.1 mL saline 0.9% (Pharmacia & Upjohn) instilled in the capsular bag at the completion of surgery was added to the topical regime. At the same time the administration of gentamicin eye drops were decreased to 2 times preoperatively.

For two months in 1997 ceftazidime 0.5 mg was combined with 0.5 mg cefuroxime as the intraocular regime, following an epidemic with ceftazidime sensitive bacteria. In terms of skin preparation, the lid margins were draped with sterile plastic cover and the periocular zone was disinfected with chlorhexidine alcohol 0.5% in the entire study period. No other anti-infective drugs were given. All surgeons at the clinic adhere to the prophylactic principles.

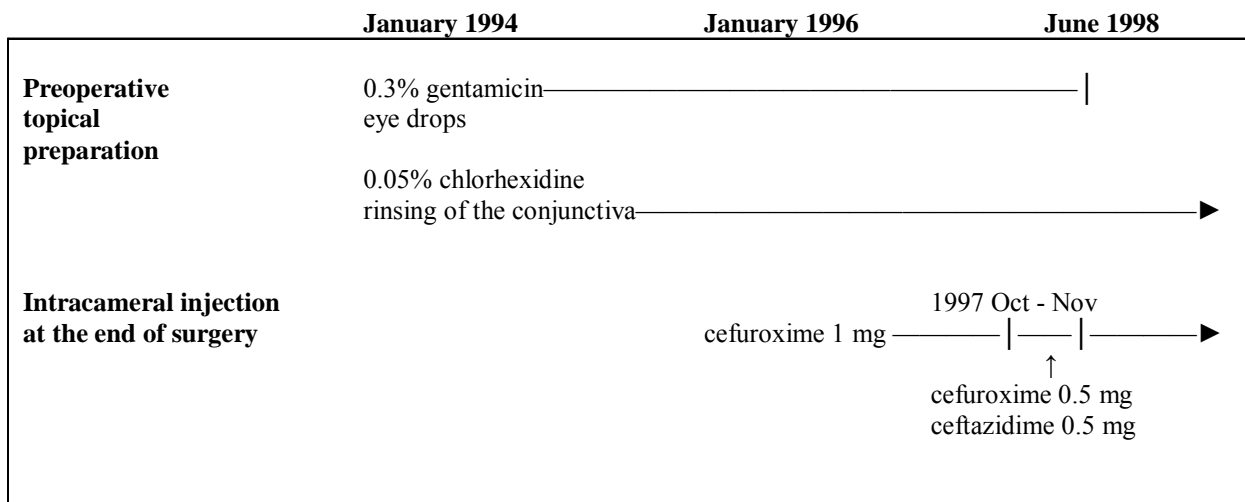


Figure 5. Prophylactic program.

Statistics

The relative risk of POE associated with the different parameters was calculated using Pearson Chi-Squared test. A subsequent forward stepwise logistic regression was employed with variables that were found to be statistically significant in the univariate analyses. All statistical evaluations were done with the Statistical Package for the Social Sciences (SPSS) for MS Windows (12.01 version). Since the parameters hydrogel lens material and no lens used were highly unusual, it was decided to omit them from both univariate and multivariate analyses. A p-value < 0.05% was considered significant.

RESULTS AND DISCUSSION

Posterior capsule opacification

Two years follow-up of 3 IOLs with different materials and design (I)

Two years postoperatively, 17 of the 180 patients did not come to the examination and 30 patients were excluded because the images were of poor quality. The analyses showed that the HSM PMMA IOL group had significantly more PCO than the silicone and the AcrySof groups. The silicone group had significantly more PCO than the AcrySof group ($p < 0.05$) (Table 1).

Parameter	IOL Group		
	HSM PMMA 809C	Silicone SI-40NB	AcrySof MA60BM
Number of patients	49	46	38
Average of ranks ⁽¹⁾	87	67	43
YAG frequency (%) ⁽²⁾	20	22	8

(1) $p < 0,05$ (Kruskal-Wallis analysis by ranks)

(2) $p > 0,05$ (χ^2 -test)

Table 1. Average of ranks of the individual EPCO scores and YAG frequency.

A variety of methods are used in the literature to evaluate PCO. Worsening of visual acuity or Nd:YAG rates are poor guidelines for estimating PCO, because the decision to treat a patient is influenced both by decreased vision and by the patients' subjective complaints. Visual acuity could also be reduced by other factors than PCO. Thus, morphological evaluation of PCO is crucial to an objective comparison of IOLs and surgical techniques.

Several quantitative methods have been developed, for example EPCO, POComan system and the Automated Quantification of After-Cataract (AQUA) system (Findl et al. 2003; Bender et al. 2004). In the current study, where the EPCO system was used, some patients required treatment earlier than two years after surgery and some of the patients were treated at other clinics. Those patients were excluded from the analyses of best-corrected visual acuity (BCVA), because we could not obtain EPCO scores from them.

Several factors may influence PCO formation, including age at surgery, other ocular pathology, systemic disorders and surgical technique. However, anti-inflammatory topical treatment in the immediate period after surgery, does not appear to influence PCO formation (Zaczeck et al. 2004). Nor does an enhanced inflammatory response cause increased PCO formation in a rabbit model (Wallentin et al. 2000). The prospective randomized single-surgeon design of this study, and the inclusion of normal eyes, save for cataract, largely excludes the effect of host factors and surgical technique on the observations. Our finding that the HSM PMMA IOL group developed more PCO than the silicone and acrylic groups, largely corresponds to another study (Hayashi et al. 1998). The current study indicates that a hydrophobic, acrylic IOL with sharp edge lessens the PCO formation. The AcrySof IOL has indeed been associated with low PCO formation in other studies (Ursell et al. 1998; Hollick et al. 1999; Ram et al. 2001; Ernest 2003), but surgery was performed with ECCE-technique and PCO was measured as Nd:YAG rate.

The barrier effect of the IOL, resulting in inhibition of PCO, has been discussed and studied and it is shown that the ingrowth of LECs from the equator along the posterior capsule can be retarded by an IOL (Apple et al. 1992; Zetterström et al. 1996; Peng et al. 2000a; Schmidbauer et al. 2001). Most IOLs now have a biconvex shape, so that the posterior capsule and optic surface are in apposition – the no space, no cells concept (Spalton 1999). The influence on PCO by the IOL material and its adhesion to the lens capsule is not entirely understood. Investigators have found different capsule-adhesion properties among PMMA, silicone and acrylic IOLs and it has been shown that the hydrophobic AcrySof IOL has a strong tendency to adhere to the lens capsule, contributing to capsule clarity (Nagata et al. 1998; Oshika et al. 1998). The best barrier effect appears to be created by an IOL with a square optic edge (Peng et al. 2000a; Schmidbauer et al. 2001; Abela-Formanek et al. 2002). *In vitro* models have shown that, during culture, LECs cease to proliferate because of contact inhibition when the cells reach the rectangular well wall, but along the wall of a U-shaped well, LECs grow and ascend (Nishi 1999). According to those findings it has been suggested that a square edge of the optic creates a sharp bend in the posterior capsule, preventing LEC migration by contact inhibition (Nishi et al. 1998; Nishi 1999; Nishi & Nishi 1999a).

It has also been argued that the preventive effect of a sharp optic edge can be obtained regardless of IOL material, although the adhesiveness of the material to the lens capsule could contribute to this effect. The AcrySof IOL has been reported to lose its preventive effect on

PCO when the optic was rounded (Nishi et al. 2001). Several authors have demonstrated that the preventive effect on PCO is similar with an AcrySof IOL and with a sharp edged silicone IOL (Nishi et al. 2000; Schauersberger et al. 2001; Auffarth et al. 2003; Mester et al. 2004). It has further been suggested that the hydrophobic acrylic IOLs are associated with a lower incidence of PCO than hydrophilic acrylic IOLs (Abela-Formanek et al. 2002; Auffarth et al. 2004).

Our results are in accordance with the reported experience that patients implanted with the sharp-edged, hydrophobic AcrySof IOL develop significantly less PCO than those with a silicone or HSM PMMA IOL with round-edged design.

Position of anterior capsulorhexis and influence on PCO (II)

The retrospective investigation three years postoperatively included two lens types, the silicone and the AcrySof, with the same optic diameter. Images from 92 patients out of the original 119 were analysed. Twenty-seven patients were excluded because they did not come to the examination or because the images did not visualize the entire anterior capsulorhexis margin. Patients with the capsulorhexis completely on the IOL optic had significantly less PCO than those with a decentred rhexis ($p=0.0014$). These results were reproduced within the AcrySof lens group ($p=0.0048$) and within the silicone lens group ($p=0.041$) (Table 2).

	Rhexis group 1 Completely on the IOL	Rhexis group 2 Decentred	p-value
Silicone SI40NB			
Number	32	15	
EPCO median	0.151	0.283	0.041
AcrySof MA60BM			
Number	28	17	
EPCO median	0.025	0.178	0.0048
Total			
Number	60	32	
EPCO median	0.050	0.269	0.0014

Table 2. EPCO medians and statistical comparisons for each IOL type when the capsulorhexis margin is decentred or completely on the IOL optic.

In addition, patients with AcrySof IOLs had significantly less PCO than those with silicone lenses 3 years after surgery ($p=0.026$) (Table 3), confirming the results of the 2-year examination (paper I).

	IOL Group		p-value
	Silicone SI40NB	AcrySof MA60BM	
Number	47	45	
EPCO median	0.223	0.054	0.026

Table 3. EPCO medians for the two different IOL groups.

The size and position of the anterior capsulorhexis has been investigated in previous studies with inconsistent results. Some investigators suggest that an anterior capsulorhexis slightly larger than the optic allow an adhesion between the anterior capsular flap and the posterior capsule, which would prevent migration of LECs into the visual axis (Hansen et al. 1988; Tetz et al. 1988). Other authors have found an increased incidence of PCO in cases of ciliary sulcus fixation of the IOL (Tan & Chee 1993). In one study it was demonstrated that an overlapping of the capsulorhexis of less than 20% resulted in significantly more PCO (Auffarth et al. 2003), but our results indicate that the rhexis edge should be completely on the IOL to reduce the incidence of PCO. The results of the current study agree with a study of rabbit eyes, where it was found that a well-centred anterior capsulorhexis, smaller than the IOL optic and with the entire circumference of the capsular edge in apposition to the optic lessens the PCO (Nishi et al. 2000). The same conclusion was made in a study on human eyes with AcrySof IOLs obtained postmortem (Schmidbauer et al. 2002). In contrast, a recently published investigation of the relation of the anterior capsule and the AcrySof MA30BA (5.5 mm optic) and its impact on PCO formation, no relationship between rhexis position and PCO was shown (Vasavada & Raj 2004). However, in that study only the presence or absence of PCO was measured, not the severity of PCO. Our results, in contrary, indicate that the rhexis position is particularly important when an AcrySof IOL is implanted.

If the rhexis is outside the optic in some part, there is incomplete adhesion between the capsule and the IOL. This creates a possible space for LECs to migrate on to the posterior capsule, illustrated in Figure 6.

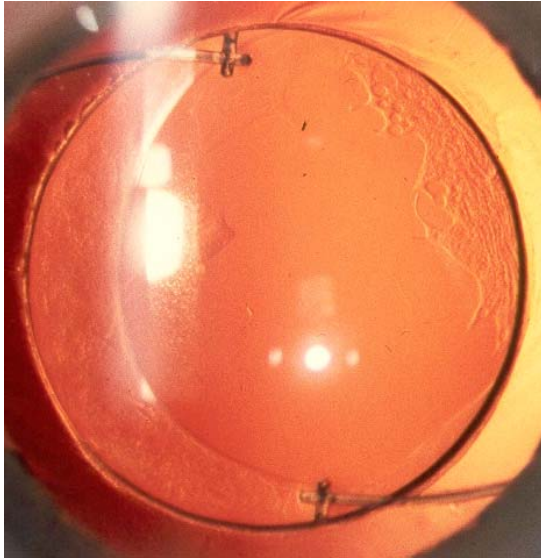

Figure 6. AcrySof IOL with decentred capsulorhexis and incipient PCO.

Regardless of the rhexis position, our results show that patients with an AcrySof IOL had less PCO than those with a silicone IOL. This may be explained by the difference in IOL design and the adherence of the hydrophobic acrylic material as is discussed in paper I. Our results indicate that the position of the anterior capsulorhexis as well as the square-edged design of the IOL are important prophylactic factors against PCO.

Postoperative endophthalmitis

Single-centre epidemiology of POE and prophylactic cefuroxime (III)

As St Erik's Eye Hospital is the only ophthalmic surgical centre in Stockholm with in-patient care and retina service, we believe that all cases of intraocular infections warranting sampling were admitted to the hospital.

During the study period 1996 – 2000, a total of 20 POE cases, 13 of which were culture positive, were found in 32 180 cataract operations, corresponding to a rate of 0.06%. The result was significantly lower compared to the POE rate between 1990 and 1995, which was 0.26% ($p < 0.001$) (Montan et al. 1998; Montan et al. 2000) Figure 7 demonstrates shifts in aetiology between the periods.

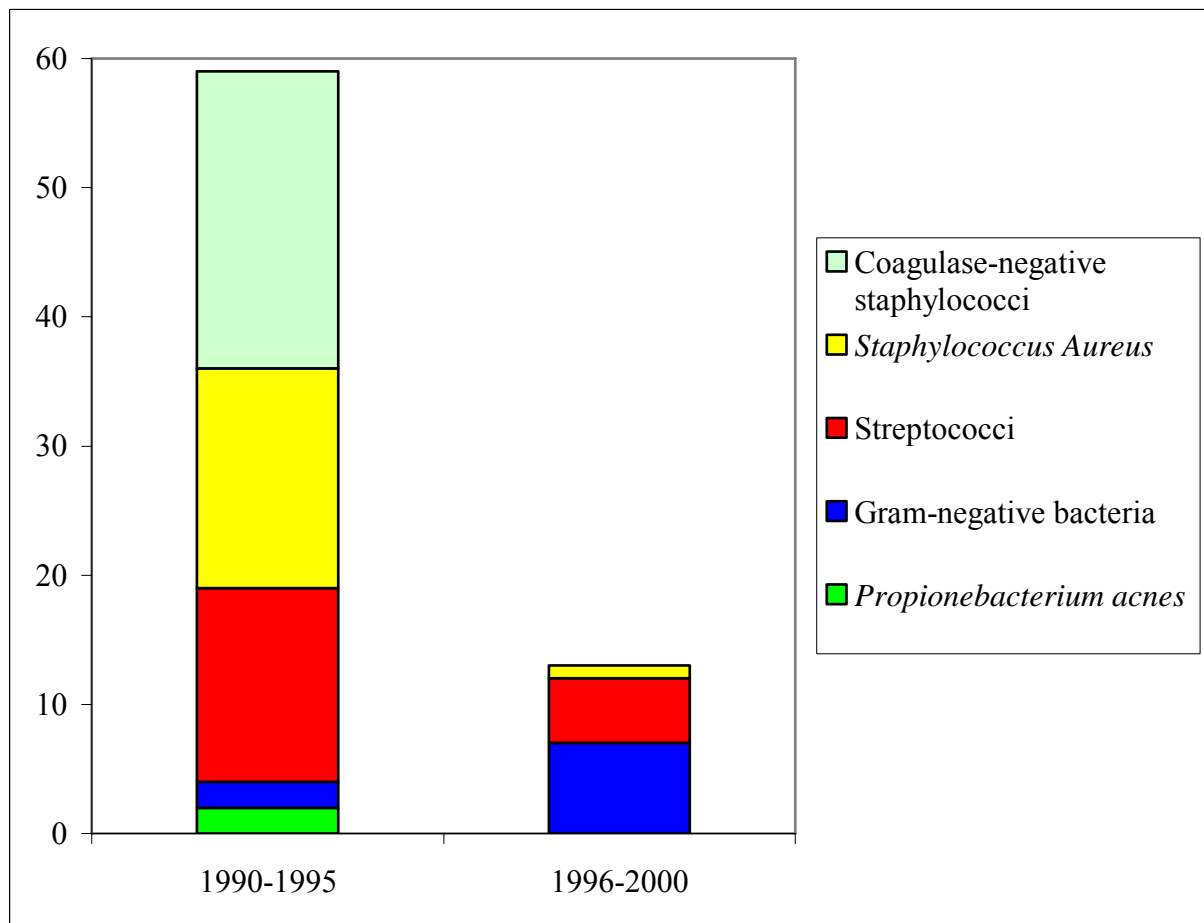


Figure 7. Bacterial aetiology of culture proven POE 1990-2000.

From 1990 to 1995 the prophylactic program included gentamicin, either as subconjunctival injection (1990-1993) or as eye drops (1994-1995). The overall frequency of POE was

practically identical for both periods, i.e. 0.26% and 0.25% respectively (Montan et al. 1998; Montan et al. 2000).

It could be argued that the decreasing incidence of POE was due to the technical improvement of cataract surgery in the 1990s. To reduce the possible bias by technical development, only phacoemulsification procedures with implantation of silicone IOLs were investigated in a subanalysis. From 1990 to 1995, there were 18 cases of POE in 3742 procedures and from 1996 to 2000, 11 cases in 12 245 procedures ($p < 0.001$), thus reproducing the overall results. In the study group, 7 cases had severe visual loss with a final visual acuity worse than 2/20, compared to 33 cases from 1990 to 1995 ($p < 0.001$).

Out of 13 culture proven cases, cefuroxime-resistant organisms caused 12. The selection of cefuroxime was based on the aetiological spectrum of previous endophthalmitis cases after cataract surgery in St Erik's Eye Hospital. Of 59 causative strains, only 4 were resistant to cefuroxime and it was assumed that the risk of an infection caused by a cefuroxime-resistant organism would be approximately 1 in 8500 operations. However, an unexpectedly high number of gram-negative infections occurred during the study period. Two epidemic outbreaks occurred in the clinic, and exogenous contamination was suspected in the first incident concerning 2 patients and was proved in the second concerning 4 patients. In the first epidemic, caused by *Alcaligenes xylosoxidans*, the source was not possible to identify but is known to contaminate solutions used in hospitals (Duggan et al. 1996). This pathogen has also been reported as a cause of low-grade POE in other studies (Aaberg et al. 1997; Swart et al. 1999). In the second epidemic, 3 of the cases were infected by the same strain of *Agrobacterium* species, traced to a tank containing deionised water used for rinsing the phacoemulsification hand pieces. This species has not been described as an ocular pathogen. One patient was infected with *Staphylococcus aureus* and the relation to the epidemic is uncertain. This was the only case in the study in which cefuroxime failed to eradicate a susceptible strain. Five additional cases were caused by the multiresistant enterococci and they constitute a serious gap in the of cefuroxime coverage of Gram-positive bacteria. Those patients achieved a final visual acuity from no light perception (NLP) to counting fingers (CF) 1 m only. From 1990 to 1995 there were 2 cases of POE caused by enterococci and there seems to have been a slight rise in number to 5 cases from 1996 to 2000, however, the increase was not significant ($p = 0.22$).

Vancomycin is effective against enterococci and has shown prophylactic evident efficacy against POE (Gimbel et al. 1994). However, we believe that vancomycin should be reserved for treatment only as it is a last-resort antibiotic with the exclusive capacity to combat infections caused by multiresistant Gram-positive bacteria. As regards the mode of administration, irrigation fluid antibiotics appear to be widely used in the Western world (Gills 1987; Gimbel et al. 1994; Schmitz et al. 1999), but we suggest that intracameral injection at the end of the procedure is a better alternative for environmental reasons.

Safety and kinetics of intracameral cefuroxime (IV)

Visual acuity, endothelial cell loss and laser flare intensity in association with cefuroxime

Quality analyses of the cefuroxime solution showed a pH of 7.42 and osmolality of 311 mOsm/kg, values within the tolerance range for corneal endothelium, which are 6.5 to 8.5 and 200 to 400 mOsm/kg respectively (Gonnering et al. 1979; Edelhauser et al. 1981). There was no statistically significant difference in endothelial cell loss between patients who received cefuroxime and those who did not, in line with previous reported observations on intracameral instillation of vancomycin and cefotaxime (Gimbel et al. 1994; Kramann et al. 2001). Nor was there any significant difference in induced laser flare changes between the groups.

We did not find any difference in visual acuity between the groups ($p=0.6$). One patient in the cefuroxime group and two in the topical disinfectant group developed cystoid macular edema (CME). Others have reported significantly higher numbers of CME after extracapsular cataract surgery when vancomycin was added in the irrigation fluid (Axer-Siegel et al. 1999). One deficiency in the current package of safety analyses is the lack of investigation of retinal toxicity. We are confident, however, that the cefuroxime solution is safe from a retinal perspective. An animal study on intraocular cefuroxime did not show any retinal damage on the ultrastructural level (Koul et al. 1990) and our results showed no significant differences in visual acuity or clinically diagnosed CME between patients receiving cefuroxime and control patients. Also, there were no induced changes in laser flare.

IgE-mediated hypersensitivity to cefuroxime

In the investigation of IgE-dependent allergy to cefuroxime, 5813 patients were screened. A skin prick test was performed in 233 patients on the basis of a reported skin or systemic reaction to the use of penicillins and cephalosporins. Only three tests were positive. These patients had cefuroxime instilled in the anterior chamber after being pretreated with an oral antihistamine and no adverse effects were observed.

Pharmacokinetic data on intraocular cefuroxime

Concerning the pharmacokinetic data, the median intracameral level of cefuroxime declined by a factor of 4 in 1 hour, i.e. from 2742 mg/L at 30 seconds to 756 mg/L at 60 minutes after drug instillation. The fast decrease found in the 60 minutes may not reflect the true elimination rate beyond the first hour. It could be slower because the dilution of the cefuroxime with aqueous flow probably is larger initially after the operation. The actual half-life of cefuroxime may be approximately 1 to 2 hours or similar to that reported for irrigation fluid antibiotics (Ferro et al. 1997; Lehmann et al. 1997; Mendivil Soto & Mendivil 2001). With a presumed constant elimination rate, cefuroxime levels in the aqueous exceeding minimal inhibitory concentrations (MIC) for several relevant species will persist for 4 to 5 hours (Donowitz & Mandell 1990).

This assumption is supported by the results of the efficacy study of intracameral cefuroxime (III) in which there was only one case of POE caused by a cefuroxime-sensitive strain in more than 32 000 operations.

In conclusion, intracameral prophylactic cefuroxime in cataract surgery appears safe and effective.

National data on POE frequency (V)

In the national prospective survey 1999-2001, 112 cases of POE in 188 151 cataract operations were identified, yielding an incidence of 0.0595%, which is at the lower end of the range reported in recent publications (Javitt et al. 1994; Aaberg et al. 1998; Schmitz et al. 1999; Versteegh & Van Rij 2000; Morlet et al. 2003; Sandvig & Dannevig 2003). The incidence is further the same as was found in the efficacy study from St. Erik's Eye Hospital 1996 to 2000 (III).

Gram-positive bacteria were the dominating aetiology, comprising 84.6% of culture-proven cases. The share of enterococci among causative bacteria was 25.3%, which is in line with the results in our single-centre study (III) where it was 38.5%. Also in this study the proportion of enterococci in culture-proven cases grew compared to previous reports from NCR (Montan et al. 1998). However, the frequency of POE due to enterococci did not change in the general cataract population (0.009% versus 0.012%). These shifts in aetiology are believed to have influenced visual outcomes following POE in the current study. A 20/40 acuity or better was reached by 28%. Roughly, half of the study group, 52.5%, had a final outcome of less than 20/200, implying that the overall risk of sustaining severe visual impairment due to POE was 3 in 10 000 cataract operations. In the multi-centre project conducted by the EVS (Endophthalmitis Vitrectomy Study Group 1995), about 50% of the patients reached 20/40 acuity and that is most likely explained by the difference in proportions of culture-negative cases and cases infected by coagulase negative staphylococci. Such patients accounted for 80% in the EVS and for 40% in the present material and those subjects almost invariably recover good visual acuity.

The data on the use of prophylactic antibiotics were analysed only from those clinics where the same regime had been in use during the entire previous year. The frequency of POE in patients who had received intracameral antibiotics was significantly lower (0.053%) than it was in patients who had been given topical antibiotics only (0.22%) ($p < 0.001$). This difference was also found to be statistically significant in a logistic regression analyses ($p < 0.001$) (Table 4).

	POE cases/ total number (%)	Odds ratio (95% CI)	P-value
Intra-cameral antibiotics**	81/151 874 (0.053)	1.0	
No intra-cameral*** antibiotics	15/6 805 (0.220)	3.649 (2.291 – 5.812)	<0.001

Table 4. Use of prophylactic antibiotics in clinics with unchanged regimes during an entire year*.

* Number of procedures in clinics where the prophylactic regime was changed during the year were 29 472. These cases were consequently not included in this analysis.

** 98.5% of cases received intracameral cefuroxime as a bolus intracameral injection, 1.5% were treated with infusion fluid antibiotics (gentamicin and vancomycin).

*** 72.5% received topical antibiotic eye drops such as chloramphenicol or fusidic acid only, 27.5% were treated with a subconjunctival injection of gentamicin.

No significant risk factors among the tested variables of age, gender or type of surgery were identified in the logistic regression model.

This is the largest prospective epidemiological study on POE following cataract surgery presented in the last decade. Consistent and continuous reporting by Swedish ophthalmological surgical units for almost 10 years makes us believe that the validity of the data is high (Håkansson et al. 2001). The present results suggest that the use of intraocular antibiotics is a promising option in prevention of POE.

Risk factors for POE (VI)

This was a case-control study performed at St Erik's to identify potential risk factors for POE after cataract surgery comprising all cataract operations performed from 1994 to 2000. During the study period phacoemulsification had become the standard procedure in our clinic, new lens materials were introduced and a new prophylactic regime was tried.

A total number of 46 292 cataract procedures were performed and the share of combined procedures with trabeculectomy was 2.8% (n = 1306). Sixty patients were diagnosed with POE, corresponding to a rate of 0.13%. The aetiologies and visual outcome have been reported by Montan and co-authors (Montan et al. 2000) and in paper III.

In the univariate analyses, 5 investigated variables were significantly associated with a changed risk for POE. The results from paper III and V were confirmed, as it was shown that

a significantly lower risk of POE is associated with the use of an intracameral prophylaxis with cefuroxime ($p < 0.001$).

In the present study the risk of POE was significantly lower when phaco was performed instead of ECCE/ICCE, although many previous reports have failed to demonstrate that phaco confers a lower risk of POE (Somani et al. 1997; Montan et al. 1998; Versteegh & Van Rij 2000). However, the number of patients operated with ECCE/ICCE technique was very small and a selection bias for this technique in particularly difficult cases or complications may have influenced the results. There was no observed increased risk for POE associated with combined procedures with trabeculectomy compared to phaco alone.

In the logistic regression analyses, the use of topical prophylactic methods only, performing ECCE/ICCE and implanting a silicone lens instead of an HSM PMMA IOL proved to be independent risk factors (Table 5).

Variable	Odds Ratio	95% Confidence Interval	P
Topical prophylaxis only vs. intracameral cefuroxime	5.7	2.8-11.9	<0.001
ECCE/ICCE vs. phaco	2.1	1.0-4.1	0.04
Silicone lens vs. HSM PMMA	3.4	1.6-7.1	0.001

Table 5. Multiple logistic regression analyses of independent predictors for endophthalmitis

A lower risk of POE was shown when the IOL was implanted in the posterior chamber as opposed to the anterior chamber and when the wound was tight compared to a leaking incision. These variables, however, did not converge in the multivariate model due to the small numbers.

Concerning IOL materials, a lower risk of POE was associated with acrylic compared to HSM PMMA IOLs in the univariate analyses. The result was driven, however, by the simultaneous introduction of the acrylic lens and of the prophylactic protocol based on an intracameral injection of cefuroxime and was therefore not reproduced in the logistic regression model.

In the latter model, silicone implants as opposed to HSM PMMA lenses carried a higher risk of infection (Table 5). This is in line with previous reports from our institution and also seems to corroborate experimental studies and some clinical data, reporting an increased bacterial adhesion to silicone lenses compared to IOLs with a heparinized surface (Bainbridge et al. 1998; Montan et al. 1998; Wong & Chee 2004). The result is, however, not in line with those

from the national survey (V), where no significantly changed risk for POE could be associated with any lens type. In all likelihood, the deposition of a prophylaxis in the anterior chamber exerting effects against gram-positive adhesive bacteria such as coagulase negative staphylococci and *S. Aureus*, is a strong factor in preventing the lens from becoming a vector for bacterial invasion. The present finding that the HSM IOL material may be protective even when an antibiotic is instilled in the proper compartment indicates that the biomaterial issue is not entirely unimportant in POE development after cataract surgery.

In summary, also this study (VI) shows an impressively protective effect against POE by prophylactic intracameral cefuroxime.

SUMMARY AND PERSPECTIVES

Cataract operation is one of the most common surgical procedures in the world and to minimize postoperative complications is therefore a major goal. Although the incidence of the most common complication, posterior capsule opacification, is decreasing rapidly, the disadvantages of the treatment must be taken into account. Many people in developing countries are blind from cataract and there is a great demand for cataract surgery in those countries. The Nd:YAG laser is too expensive for widespread use in the developing world. Thus, surgical modifications and IOL-related factors are important in the prevention of PCO.

- Implantation of a hydrophobic, acrylic IOL with sharp optic edge appears to decrease the amount of PCO.
- Positioning of the anterior capsulorhexis, ensuring that the edge is completely on the IOL optic, seems to reduce or delay the incidence of PCO.

The duration of the implant in the eye plays an important role in the formation of PCO and short-time studies do not always show any difference in PCO related to the type of IOL (Mester et al. 2004). Therefore, long-term studies are required to assess how different IOLs perform in relation to PCO. The patients in papers I and II were also examined five years postoperatively and long-term data on PCO analysed with EPCO remain to be evaluated.

Postoperative endophthalmitis is an infrequent complication to cataract surgery, but the potentially serious outcome demands the development of prophylactic regimes.

- Intracameral injection of cefuroxime appears to be a protective factor against POE.
- Intracameral cefuroxime appears safe in terms of local toxicity and IgE-mediated allergy is rare.
- There are important gaps in the antibacterial spectrum of cefuroxime, illustrated by our finding of an increased share of infections due to cefuroxime-resistant enterococci.
- Distinct risk factors for POE are difficult to prove.

Future supplementations with other antibiotics delivered in the same way may be considered, but such changes in the prophylactic protocol will have to be preceded by safety investigations of putative adverse effects. The protective effect against POE produced by the prophylactic use of intracameral cefuroxime in comparison to topical disinfections only, has justified the inclusion of intracameral cefuroxime in a large on-going prospective multi-centre European study on prophylaxis for cataract surgery.

In recent investigations, it has been suggested that clear corneal incision and especially a temporal corneal incision have been associated with an increased risk for POE (Schmitz et al. 1999; Cooper et al. 2003; Nagaki et al. 2003). It is also reported that an injected IOL may decrease the risk for POE (Mayer et al. 2003). These parameters were not investigated in our present studies and further multivariate analysis of operating technique variables need to be performed. Since 2002, registration on the Swedish National Cataract Register has incorporated additional variables, such as incision site, the use of injectors and the presence of intraoperative complications. The accumulated data of a 3-year period may allow for analyses of these parameters in relation to the development of POE.

ACKNOWLEDGEMENTS

I wish to express my sincere gratitude to all persons who have helped me and supported me during these years. Especially I want to thank:

Associate professor Charlotta Zetterström, my supervisor, for introducing me to the scientific world, for excellent working conditions, guidance, encouragement and patience throughout all these years. You have made me believe that I can manage and never give up.

Per Montan, my supervisor, for introducing me to the world of bacteria, statistics and diction. For your excellent guidance, concern and encouragement. Your knowledge and never-ending enthusiasm has carried me all the way.

Professor Jan Ygge, present chairman and professor Gunnar Lennerstrand, former chairman of the Division of Ophthalmology at the Institution of Clinical Neuroscience, for providing excellent research conditions and support during these years.

Mikaela Taube and Sinikka Syrén-Nordqvist, for your skilfulness in all examinations, for taking excellent care of all patients, for organizing my work and me, and for all nice chats.

Maria Kugelberg, my co-author, for all your help and fantastic support at any time and for cheering me up.

Professor Mats Lundström, my co-author, for introducing me to the Swedish National Cataract Register, for your help and for your quick answers to all my questions. Professor Ulf Stenevi and associate professor William Thorburn, my co-authors, for allowing me to participate in the work with the endophthalmitis register and for all help.

Professor Stefan Seregard, my co-author, for your help with the statistics and for your support.

Gabor Koranyi, my co-author, for all help with databases and Excel-files and your good advice.

Hans Setterquist, my co-author, for your help. I miss your bags of sweets and cheerful temperament.

Branka Samolov and Margareta Rylander, my co-authors, for your help.

Bo Nilsson, for statistical calculations and your patience with my questions.

All colleagues and the staff at the Department of Anterior segment surgery, St Erik's Eye Hospital, for supporting me, making me happy at work and for taking care of everything when I completed these studies.

Göran Olivestedt, for being my friend, for listening, for your encouragement and your skilfulness. You are always there to help and support.

Christina Persson and Annemari Koivula for your friendship.

My parents, Birgitta and Bo, for your love and for always encouraging and supporting me.

Finally, I would like to thank my wonderful beloved family. My husband Johan, for your love, support and understanding and for your knowledge and sensible advice in the work with this thesis. My children, Ellen and Björn, for your love, support and patience.

REFERENCES

- Aaberg TM, Jr., Flynn HW, Jr., Schiffman J & Newton J (1998): Nosocomial acute-onset postoperative endophthalmitis survey. A 10-year review of incidence and outcomes. *Ophthalmology* 105: 1004-1010.
- Aaberg TM, Jr., Rubsamens PE, Joondeph BC & Flynn HW, Jr. (1997): Chronic postoperative gram-negative endophthalmitis. *Retina* 17: 260-262.
- Abela-Formanek C, Amon M, Schild G, Schauersberger J, Heinze G & Kruger A (2002): Uveal and capsular biocompatibility of hydrophilic acrylic, hydrophobic acrylic, and silicone intraocular lenses. *J Cataract Refract Surg* 28: 50-61.
- Apple DJ, Peng Q, Visessook N, Werner L, Pandey SK, Escobar-Gomez M, Ram J & Auffarth GU (2001): Eradication of posterior capsule opacification: documentation of a marked decrease in Nd:YAG laser posterior capsulotomy rates noted in an analysis of 5416 pseudophakic human eyes obtained postmortem. *Ophthalmology* 108: 505-518.
- Apple DJ, Solomon KD, Tetz MR, Assia EI, Holland EY, Legler UF, Tsai JC, Castaneda VE, Hoggatt JP & Kostick AM (1992): Posterior capsule opacification. *Surv Ophthalmol* 37: 73-116.
- Auffarth GU, Brezin A, Caporossi A, Lafuma A, Mendicute J, Berdeaux G & Smith AF (2004): Comparison of Nd : YAG capsulotomy rates following phacoemulsification with implantation of PMMA, silicone, or acrylic intra-ocular lenses in four European countries. *Ophthalmic Epidemiol* 11: 319-329.
- Auffarth GU, Golescu A, Becker KA & Volcker HE (2003): Quantification of posterior capsule opacification with round and sharp edge intraocular lenses. *Ophthalmology* 110: 772-780.
- Axer-Siegel R, Stiebel-Kalish H, Rosenblatt I, Strassmann E, Yassur Y & Weinberger D (1999): Cystoid macular edema after cataract surgery with intraocular vancomycin. *Ophthalmology* 106: 1660-1664.
- Bainbridge JW, Teimory M, Tabandeh H, Kirwan JF, Dalton R, Reid F & Rostron CK (1998): Intraocular lens implants and risk of endophthalmitis. *Br J Ophthalmol* 82: 1312-1315.
- Barza M, Pavan PR, Doft BH, Wisniewski SR, Wilson LA, Han DP & Kelsey SF (1997): Evaluation of microbiological diagnostic techniques in postoperative endophthalmitis in the Endophthalmitis Vitrectomy Study. *Arch Ophthalmol* 115: 1142-1150.

- Bender L, Spalton DJ, Uyanonvara B, Boyce J, Heatley C, Jose R & Khan J (2004): POComan: new system for quantifying posterior capsule opacification. *J Cataract Refract Surg* 30: 2058-2063.
- Booth MC, Atkuri RV, Nanda SK, Iandolo JJ & Gilmore MS (1995): Accessory gene regulator controls *Staphylococcus aureus* virulence in endophthalmitis. *Invest Ophthalmol Vis Sci* 36: 1828-1836.
- Ciulla TA, Starr MB & Masket S (2002): Bacterial endophthalmitis prophylaxis for cataract surgery: an evidence-based update. *Ophthalmology* 109: 13-24.
- Cooper BA, Holekamp NM, Bohigian G & Thompson PA (2003): Case-control study of endophthalmitis after cataract surgery comparing scleral tunnel and clear corneal wounds. *Am J Ophthalmol* 136: 300-305.
- Doft BM, Kelsey SF & Wisniewski SR (2000): Retinal detachment in the endophthalmitis vitrectomy study. *Arch Ophthalmol* 118: 1661-1665.
- Donowitz G & Mandell G, *Cephalosporins. In: Principles and practice of infectious diseases.* 1990, Churchill Livingstone: New York, NY. p. 246-254.
- Duggan JM, Goldstein SJ, Chenoweth CE, Kauffman CA & Bradley SF (1996): *Achromobacter xylosoxidans* bacteremia: report of four cases and review of the literature. *Clin Infect Dis* 23: 569-576.
- Edelhauser HF, Hanneken AM, Pederson HJ & Van Horn DL (1981): Osmotic tolerance of rabbit and human corneal endothelium. *Arch Ophthalmol* 99: 1281-1287.
- Endophthalmitis Vitrectomy Study Group (1995): Results of the Endophthalmitis Vitrectomy Study. A randomized trial of immediate vitrectomy and of intravenous antibiotics for the treatment of postoperative bacterial endophthalmitis. Endophthalmitis Vitrectomy Study Group. *Arch Ophthalmol* 113: 1479-1496.
- Endophthalmitis Vitrectomy Study Group (1996): Endophthalmitis Vitrectomy Study Group: Microbiological factors and visual outcomes in the endophthalmitis vitrectomy study. *Am J Ophthalmol* 122: 830-846.
- Ernest PH (2003): Posterior capsule opacification and neodymium: YAG capsulotomy rates with AcrySof acrylic and PhacoFlex II silicone intraocular lenses. *J Cataract Refract Surg* 29: 1546-1550.
- Ferro JF, de-Pablos M, Logrono MJ, Guisasola L & Aizpuru F (1997): Postoperative contamination after using vancomycin and gentamicin during phacoemulsification. *Arch Ophthalmol* 115: 165-170.

- Findl O, Buehl W, Menapace R, Georgopoulos M, Rainer G, Siegl H, Kaider A & Pinz A (2003): Comparison of 4 methods for quantifying posterior capsule opacification. *J Cataract Refract Surg* 29: 106-111.
- Findl O, Neumayer T, Buehl W & Sacu S, *Short-term changes in the morphology of posterior capsule opacification.*, in *XXII Congress of the ESCRS*. 2004: Paris.
- Foster A (1999): Cataract--a global perspective: output, outcome and outlay. *Eye* 13 (Pt 3b): 449-453.
- Ge J, Wand M, Chiang R, Paranhos A & Shields MB (2000): Long-term effect of Nd:YAG laser posterior capsulotomy on intraocular pressure. *Arch Ophthalmol* 118: 1334-1337.
- Gills JP (1987): Antibiotics in irrigating solutions. *J Cataract Refract Surg* 13: 344.
- Gimbel HV, Sun R & DeBrof BM (1994): Prophylactic intracameral antibiotics during cataract surgery: The incidence of endophthalmitis and corneal endothelial cell loss. *Eur J Implant Ref Surg* 6: 280-285.
- Gonnering R, Edelhauser HF, Van Horn DL & Durant W (1979): The pH tolerance of rabbit and human corneal endothelium. *Invest Ophthalmol Vis Sci* 18: 373-390.
- Hansen SO, Solomon KD, McKnight GT, Wilbrandt TH, Gwin TD, O'Morchoe DJ, Tetz MR & Apple DJ (1988): Posterior capsular opacification and intraocular lens decentration. Part I: Comparison of various posterior chamber lens designs implanted in the rabbit model. *J Cataract Refract Surg* 14: 605-613.
- Hayashi H, Hayashi K, Nakao F & Hayashi F (1998): Quantitative comparison of posterior capsule opacification after polymethylmethacrylate, silicone, and soft acrylic intraocular lens implantation. *Arch Ophthalmol* 116: 1579-1582.
- Hirvela H, Luukinen H & Laatikainen L (1995): Prevalence and risk factors of lens opacities in the elderly in Finland. A population-based study. *Ophthalmology* 102: 108-117.
- Holladay JT, Bishop JE & Lewis JW (1985): Diagnosis and treatment of mysterious light streaks seen by patients following extracapsular cataract extraction. *J Am Intraocul Implant Soc* 11: 21-23.
- Hollick EJ, Spalton DJ, Ursell PG & Pande MV (1998): Lens epithelial cell regression on the posterior capsule with different intraocular lens materials. *Br J Ophthalmol* 82: 1182-1188.
- Hollick EJ, Spalton DJ, Ursell PG, Pande MV, Barman SA, Boyce JF & Tilling K (1999): The effect of polymethylmethacrylate, silicone, and polyacrylic intraocular lenses on

- posterior capsular opacification 3 years after cataract surgery. *Ophthalmology* 106: 49-54.
- Holweger RR & Marefat B (1997): Intraocular pressure change after neodymium:YAG capsulotomy. *J Cataract Refract Surg* 23: 115-121.
- Howes EL, Jr., Cole PW, Adair TM, Cruse VK & Pollycove M (1994): Cellular and vascular responses in acute experimental ocular inflammation. *Invest Ophthalmol Vis Sci* 35: 4031-4038.
- Håkansson I, Lundstrom M, Stenevi U & Ehinger B (2001): Data reliability and structure in the Swedish National Cataract Register. *Acta Ophthalmol Scand* 79: 518-523.
- Javitt JC, Street DA, Tielsch JM, Wang Q, Kolb MM, Schien O, Sommer A, Bergner M & Steinberg EP (1994): National outcomes of cataract extraction. Retinal detachment and endophthalmitis after outpatient cataract surgery. Cataract Patient Outcomes Research Team. *Ophthalmology* 101: 100-105; discussion 106.
- Javitt JC, Tielsch JM, Canner JK, Kolb MM, Sommer A & Steinberg EP (1992): National outcomes of cataract extraction. Increased risk of retinal complications associated with Nd:YAG laser capsulotomy. The Cataract Patient Outcomes Research Team. *Ophthalmology* 99: 1487-1497; discussion 1497-1488.
- Javitt JC, Vitale S, Canner JK, Street DA, Krakauer H, McBean AM & Sommer A (1991): National outcomes of cataract extraction. Endophthalmitis following inpatient surgery. *Arch Ophthalmol* 109: 1085-1089.
- Kahn HA, Leibowitz HM, Ganley JP, Kini MM, Colton T, Nickerson RS & Dawber TR (1977): The Framingham Eye Study. I. Outline and major prevalence findings. *Am J Epidemiol* 106: 17-32.
- Kattan HM, Flynn HW, Jr., Pflugfelder SC, Robertson C & Forster RK (1991): Nosocomial endophthalmitis survey. Current incidence of infection after intraocular surgery. *Ophthalmology* 98: 227-238.
- Klein BE, Klein R & Lee KE (1998): Incidence of age-related cataract: the Beaver Dam Eye Study. *Arch Ophthalmol* 116: 219-225.
- Klein BE, Klein R & Linton KL (1992): Prevalence of age-related lens opacities in a population. The Beaver Dam Eye Study. *Ophthalmology* 99: 546-552.
- Koul S, Philipson A, Philipson BT, Kock E & Nylen P (1990): Intraocular levels of cefuroxime in uninflamed rabbit eyes. *Acta Ophthalmol (Copenh)* 68: 455-465.

- Kramann C, Pitz S, Schwenn O, Haber M, Hommel G & Pfeiffer N (2001): Effects of intraocular cefotaxime on the human corneal endothelium. *J Cataract Refract Surg* 27: 250-255.
- Kruger AJ, Schauersberger J, Abela C, Schild G & Amon M (2000): Two year results: sharp versus rounded optic edges on silicone lenses. *J Cataract Refract Surg* 26: 566-570.
- Kugelberg M & Zetterström C (2002): Pediatric cataract surgery with or without anterior vitrectomy. *J Cataract Refract Surg* 28: 1770-1773.
- Lehmann OJ, Thompson JP, White LO, Keys MF & Campbell MJ (1997): Half-life of intracameral gentamicin after phacoemulsification. *J Cataract Refract Surg* 23: 883-888.
- Mamalis N, Kearsley L & Brinton E (2002): Postoperative endophthalmitis. *Curr Opin Ophthalmol* 13: 14-18.
- Mao LK, Flynn HW, Jr., Miller D & Pflugfelder SC (1992): Endophthalmitis caused by streptococcal species. *Arch Ophthalmol* 110: 798-801.
- Marcantonio JM & Vrensen GF (1999): Cell biology of posterior capsular opacification. *Eye* 13: 484-488.
- Mayer E, Cadman D, Ewings P, Twomey JM, Gray RH, Claridge KG, Hakin KN & Bates AK (2003): A 10 year retrospective survey of cataract surgery and endophthalmitis in a single eye unit: injectable lenses lower the incidence of endophthalmitis. *Br J Ophthalmol* 87: 867-869.
- McDonnell PJ, Zarbin MA & Green WR (1983): Posterior capsule opacification in pseudophakic eyes. *Ophthalmology* 90: 1548-1553.
- Meacock WR, Spalton DJ, Hollick EJ, Barman S & Boyce JF (2001): The effect of polymethylmethacrylate and acrysof intraocular lenses on the posterior capsule in patients with a large capsulorrhexis. *Jpn J Ophthalmol* 45: 348-354.
- Mendivil Soto A & Mendivil MP (2001): The effect of topical povidone-iodine, intraocular vancomycin, or both on aqueous humor cultures at the time of cataract surgery. *Am J Ophthalmol* 131: 293-300.
- Menikoff JA, Speaker MG, Marmor M & Raskin EM (1991): A case-control study of risk factors for postoperative endophthalmitis. *Ophthalmology* 98: 1761-1768.
- Mester U, Fabian E, Gerl R, Hunold W, Hutz W, Strobel J, Hoyer H & Kohnen T (2004): Posterior capsule opacification after implantation of CeeOn Edge 911A, PhacoFlex SI-40NB, and AcrySof MA60BM lenses: one-year results of an intraindividual comparison multicenter study. *J Cataract Refract Surg* 30: 978-985.

- Metrikin DC, Wilson CA, Berkowitz BA, Lam MK, Wood GK & Peshock RM (1995): Measurement of blood-retinal barrier breakdown in endotoxin-induced endophthalmitis. *Invest Ophthalmol Vis Sci* 36: 1361-1370.
- Meyers-Elliott RH & Dethlefs BA (1982): Experimental Klebsiella-induced endophthalmitis in the rabbit. *Arch Ophthalmol* 100: 1959-1963.
- Montan P, Lundström M, Stenevi U & Thorburn W (2002): Endophthalmitis following cataract surgery in Sweden. The 1998 national prospective survey. *Acta Ophthalmol Scand* 80: 258-261.
- Montan PG, Koranyi G, Setterquist HE, Stridh A, Philipson BT & Wiklund K (1998): Endophthalmitis after cataract surgery: risk factors relating to technique and events of the operation and patient history: a retrospective case-control study. *Ophthalmology* 105: 2171-2177.
- Montan PG, Setterquist H, Marcusson E, Rylander M & Ransjo U (2000): Preoperative gentamicin eye drops and chlorhexidine solution in cataract surgery. Experimental and clinical results. *Eur J Ophthalmol* 10: 286-292.
- Morlet N, Li J, Semmens J & Ng J (2003): The Endophthalmitis Population Study of Western Australia (EPSWA): first report. *Br J Ophthalmol* 87: 574-576.
- Murray PR (1995): *Manual of Clinical Microbiology*, 6th ed. Washington, DC, ASM Press,
- Nagaki Y, Hayasaka S, Kadoi C, Matsumoto M, Yanagisawa S, Watanabe K, Hayasaka Y, Ikeda N, Sato S, Kataoka Y, Togashi M & Abe T (2003): Bacterial endophthalmitis after small-incision cataract surgery. effect of incision placement and intraocular lens type. *J Cataract Refract Surg* 29: 20-26.
- Nagata T, Minakata A & Watanabe I (1998): Adhesiveness of AcrySof to a collagen film. *J Cataract Refract Surg* 24: 367-370.
- Newland TJ, McDermott ML, Elliott D, Hazlett LD, Apple DJ, Lambert RJ & Barrett RP (1999): Experimental neodymium:YAG laser damage to acrylic, poly(methyl methacrylate), and silicone intraocular lens materials. *J Cataract Refract Surg* 25: 72-76.
- Nishi O (1999): Posterior capsule opacification. Part 1: Experimental investigations. *J Cataract Refract Surg* 25: 106-117.
- Nishi O & Nishi K (1999a): Preventing posterior capsule opacification by creating a discontinuous sharp bend in the capsule. *J Cataract Refract Surg* 25: 521-526.

- Nishi O, Nishi K, Akura J & Nagata T (2001): Effect of round-edged acrylic intraocular lenses on preventing posterior capsule opacification. *J Cataract Refract Surg* 27: 608-613.
- Nishi O, Nishi K & Sakanishi K (1998): Inhibition of migrating lens epithelial cells at the capsular bend created by the rectangular optic edge of a posterior chamber intraocular lens. *Ophthalmic Surg Lasers* 29: 587-594.
- Nishi O, Nishi K & Wickstrom K (2000): Preventing lens epithelial cell migration using intraocular lenses with sharp rectangular edges. *J Cataract Refract Surg* 26: 1543-1549.
- Norregaard JC, Thoning H, Bernth-Petersen P, Andersen TF, Javitt JC & Anderson GF (1997): Risk of endophthalmitis after cataract extraction: results from the International Cataract Surgery Outcomes study. *Br J Ophthalmol* 81: 102-106.
- Oshika T, Nagata T & Ishii Y (1998): Adhesion of lens capsule to intraocular lenses of polymethylmethacrylate, silicone, and acrylic foldable materials: an experimental study. *Br J Ophthalmol* 82: 549-553.
- Pandey SK, Apple DJ, Werner L, Maloof AJ & Milverton EJ (2004): Posterior capsule opacification: a review of the aetiopathogenesis, experimental and clinical studies and factors for prevention. *Indian J Ophthalmol* 52: 99-112.
- Peng Q, Apple DJ, Visessook N, Werner L, Pandey SK, Escobar-Gomez M, Schoderbek R & Guindi A (2000): Surgical prevention of posterior capsule opacification. Part 2: Enhancement of cortical cleanup by focusing on hydrodissection. *J Cataract Refract Surg* 26: 188-197.
- Peng Q, Visessook N, Apple DJ, Pandey SK, Werner L, Escobar-Gomez M, Schoderbek R, Solomon KD & Guindi A (2000a): Surgical prevention of posterior capsule opacification. Part 3: Intraocular lens optic barrier effect as a second line of defense. *J Cataract Refract Surg* 26: 198-213.
- Ram J, Apple DJ, Peng Q, Visessook N, Auffarth GU, Schoderbek RJ, Jr. & Ready EL (1999): Update on fixation of rigid and foldable posterior chamber intraocular lenses. Part II: Choosing the correct haptic fixation and intraocular lens design to help eradicate posterior capsule opacification. *Ophthalmology* 106: 891-900.
- Ram J, Kaushik S, Brar GS & Gupta A (2001): Neodymium:YAG capsulotomy rates following phacoemulsification with implantation of PMMA, silicone, and acrylic intraocular lenses. *Ophthalmic Surg Lasers* 32: 375-382.

- Ravalico G, Tognetto D, Palomba M, Busatto P & Baccara F (1996): Capsulorhexis size and posterior capsule opacification. *J Cataract Refract Surg* 22: 98-103.
- Sandvig KU & Dannevig L (2003): Postoperative endophthalmitis: establishment and results of a national registry. *J Cataract Refract Surg* 29: 1273-1280.
- Schauersberger J, Amon M, Kruger A, Abela C, Schild G & Kolodjaschna J (2001): Comparison of the biocompatibility of 2 foldable intraocular lenses with sharp optic edges. *J Cataract Refract Surg* 27: 1579-1585.
- Schaumberg DA, Dana MR, Christen WG & Glynn RJ (1998): A systematic overview of the incidence of posterior capsule opacification. *Ophthalmology* 105: 1213-1221.
- Schmidbauer JM, Vargas LG, Apple DJ, Escobar-Gomez M, Izak A, Arthur SN, Golescu A & Peng Q (2002): Evaluation of neodymium:yttrium-aluminum-garnet capsulotomies in eyes implanted with AcrySof intraocular lenses. *Ophthalmology* 109: 1421-1426.
- Schmidbauer JM, Vargas LG, Peng Q, Escobar-Gomez M, Werner L, Arthur SN & Apple DJ (2001): Posterior capsule opacification. *Int Ophthalmol Clin* 41: 109-131.
- Schmitz S, Dick HB, Krummenauer F & Pfeiffer N (1999): Endophthalmitis in cataract surgery: results of a German survey. *Ophthalmology* 106: 1869-1877.
- Sherwood DR, Rich WJ, Jacob JS, Hart RJ & Fairchild YL (1989): Bacterial contamination of intraocular and extraocular fluids during extracapsular cataract extraction. *Eye* 3 (Pt 3): 308-312.
- Somani S, Grinbaum A & Slomovic AR (1997): Postoperative endophthalmitis: incidence, predisposing surgery, clinical course and outcome. *Can J Ophthalmol* 32: 303-310.
- Spalton DJ (1999): Posterior capsular opacification after cataract surgery. *Eye* 13 (Pt 3b): 489-492.
- Speaker MG & Menikoff JA (1991): Prophylaxis of endophthalmitis with topical povidone-iodine. *Ophthalmology* 98: 1769-1775.
- Speaker MG, Milch FA, Shah MK, Eisner W & Kreiswirth BN (1991): Role of external bacterial flora in the pathogenesis of acute postoperative endophthalmitis. *Ophthalmology* 98: 639-649; discussion 650.
- Steinberg EP, Javitt JC, Sharkey PD, Zuckerman A, Legro MW, Anderson GF, Bass EB & O'Day D (1993): The content and cost of cataract surgery. *Arch Ophthalmol* 111: 1041-1049.
- Steinert RF, Puliafito CA, Kumar SR, Dudak SD & Patel S (1991): Cystoid macular edema, retinal detachment, and glaucoma after Nd:YAG laser posterior capsulotomy. *Am J Ophthalmol* 112: 373-380.

- Stenevi U, Lundström M & Thorburn W (1995): A national Cataract Register. I. Description and epidemiology. *Acta Ophthalmol Scand* 73: 41-44.
- Swart J, Volker-Dieben HJ & Reichert-Thoen JW (1999): *Alcaligenes xylosoxidans* endophthalmitis 8 months after cataract extraction. *Am J Ophthalmol* 127: 345-346.
- Tan DT & Chee SP (1993): Early central posterior capsular fibrosis in sulcus-fixated biconvex intraocular lenses. *J Cataract Refract Surg* 19: 471-480.
- Tetz MR, Auffarth GU, Sperker M, Blum M & Volcker HE (1997): Photographic image analysis system of posterior capsule opacification. *J Cataract Refract Surg* 23: 1515-1520.
- Tetz MR, O'Morchoe DJ, Gwin TD, Wilbrandt TH, Solomon KD, Hansen SO & Apple DJ (1988): Posterior capsular opacification and intraocular lens decentration. Part II: Experimental findings on a prototype circular intraocular lens design. *J Cataract Refract Surg* 14: 614-623.
- Ursell PG, Spalton DJ, Pande MV, Hollick EJ, Barman S, Boyce J & Tilling K (1998): Relationship between intraocular lens biomaterials and posterior capsule opacification. *J Cataract Refract Surg* 24: 352-360.
- Wallentin N, Lundgren B & Lundberg C (2000): Lack of correlation between intraocular inflammation and after-cataract formation in the rabbit eye. *J Cataract Refract Surg* 26: 1389-1397.
- Vasavada A & Desai J (1997): Primary posterior capsulorhexis with and without anterior vitrectomy in congenital cataracts. *J Cataract Refract Surg* 23 Suppl 1: 645-651.
- Vasavada AR & Raj SM (2004): Anterior capsule relationship of the AcrySof intraocular lens optic and posterior capsule opacification: a prospective randomized clinical trial. *Ophthalmology* 111: 886-894.
- Versteegh MF & Van Rij G (2000): Incidence of endophthalmitis after cataract surgery in the Netherlands: several surgical techniques compared. *Doc Ophthalmol* 100: 1-6.
- Wong TY & Chee SP (2004): Risk factors of acute endophthalmitis after cataract extraction: a case-control study in Asian eyes. *Br J Ophthalmol* 88: 29-31.
- Zaczeck A, Laurell CG & Zetterström C (2004): Posterior capsule opacification after phacoemulsification in patients with postoperative steroidal and nonsteroidal treatment. *J Cataract Refract Surg* 30: 316-320.
- Zetterström C, Kugelberg U, Lundgren B & Syren-Nordqvist S (1996): After-cataract formation in newborn rabbits implanted with intraocular lenses. *J Cataract Refract Surg* 22: 85-88.