

From the Department of Clinical Science, Intervention and Technology,
Division of ENT Diseases
Karolinska Institutet, Stockholm, Sweden

CLINICAL IMPLICATIONS OF HPV IN OROPHARYNGEAL CANCER

Per Attner



**Karolinska
Institutet**

Stockholm 2012

All previously published papers were reproduced with permission from the publisher.

Front cover: Electron micrograph of a negatively stained human papilloma virus
(Source: Wikimedia Commons-public domain)

Published by Karolinska Institutet.

© Per Attner, 2012

ISBN 978-91-7457-692-4

Printed by



www.reproprint.se

Gårdsvägen 4, 169 70 Solna

I am so smart, I am so smart,

S-M-R-T..... I mean S-M-A-R-T

Homer Simpson

To Caroline and Calle

ABSTRACT

Tonsillar cancer incidence has been increasing in Sweden and many other western countries in the last decades despite that other head and neck cancers are decreasing. It is now established that Human Papillomavirus (HPV) can be accredited part of that increase.

The aims of this thesis were to investigate any change in incidence of base of tongue cancer, any further increase of tonsillar cancer incidence, what role HPV may have, the prognostic value of HPV as well as the outcome of different treatment regimes on tonsillar cancer.

Using the Swedish Cancer Registry, we found that the incidence for both tonsillar and base of tongue cancer has increased from 1970 to 2006-2007, for tonsillar cancer from 0.74/100000 person-years 1970-1979 to 1.65/100000 person-years 2000-2006 in Stockholm County and for base of tongue cancer from 0.15/100000 person-years 1970-1974 to 0.47/100000 person-years 2005-2007 in Sweden. We analyzed pre-treatment, paraffin-embedded diagnostic tumor biopsies for HPV using PCR technique and found that the proportion of HPV in both tonsillar and base of tongue cancer has increased during the last decade, reaching 93% positivity in tonsillar cancer and 83% positivity in base of tongue cancer in 2006-2007. To evaluate if HPV was transcriptionally active in these biopsies, we also tested for HPV E6 and E7 mRNA, which was positive in the vast majority of cases. For base of tongue cancer, HPV was found to be a significant prognostic factor, with improved overall as well as disease free survival compared to patients with HPV-negative tumors, irrespective of patient age, sex and tumor stage. It has been suggested that patients with HPV positive tumors possibly could be cured by less intense treatment and thus reducing side effects. When analyzing all HPV positive tonsillar cancer patients in Stockholm County, Sweden between 2000 and 2007, we compared survival and development of distant metastasis between groups that had received three different treatment regimes. No significant difference in overall or disease free survival was found between the treatment groups, but a trend of improved survival for intensified treatment was seen that needs to be studied further.

The vast majority of HPV positive tonsillar- and base of tongue cancers are HPV16, which means that the commercially available vaccines would protect against it. This highlights the discussion if boys/men should be included in the HPV vaccination program.

LIST OF PUBLICATIONS

- I. Näsman A, **Attner P**, Hammarstedt L, Du J, Eriksson M, Giraud G, Ahrlund-Richter S, Marklund L, Romanitan M, Lindquist D, Ramqvist T, Lindholm J, Sparén P, Ye W, Dahlstrand H, Munck-Wikland E, Dalianis T. Incidence of human papillomavirus (HPV) positive tonsillar carcinoma in Stockholm, Sweden: an epidemic of viral-induced carcinoma? *Int J Cancer*. 2009 Jul 15;125(2):362-6.
- II. **Attner P***, Du J*, Näsman A, Hammarstedt L, Ramqvist T, Lindholm J, Marklund L, Dalianis T, Munck-Wikland E. The role of human papillomavirus in the increased incidence of base of tongue cancer. *Int J Cancer*. 2010 Jun 15;126(12):2879-84.
- III. **Attner P**, Du J, Näsman A, Hammarstedt L, Ramqvist T, Lindholm J, Marklund L, Dalianis T, Munck-Wikland E. Human papillomavirus and survival in patients with base of tongue cancer. *Int J Cancer*. 2011 Jun 15;128(12):2892-7.
- IV. **Attner P**, Näsman A, Du J, Hammarstedt L, Ramqvist T, Lindholm J, Munck-Wikland E, Dalianis T, Marklund L. Survival in patients with human papillomavirus positive tonsillar cancer in relation to treatment. *Int J Cancer*. 2011 Oct 31. doi: 10.1002/ijc.26490. [Epub ahead of print]

*Authors contributed equally

CONTENTS

1	Introduction.....	1
1.1	Oropharyngeal cancer	2
1.1.1	The oropharynx.....	2
1.1.2	Oropharyngeal cancer.....	3
1.1.3	Epidemiology.....	4
1.1.4	Classification	5
1.1.5	Treatment.....	7
1.2	Human Papilloma Virus (HPV)	9
1.2.1	History	9
1.2.2	Virus anatomy.....	10
1.2.3	HPV and cancer development	11
1.2.4	HPV and oropharyngeal cancer	12
1.2.5	HPV vaccines	13
2	Aims of the thesis.....	14
3	Materials and methods	15
3.1	Materials.....	15
3.1.1	Swedish Cancer Registry.....	15
3.1.2	International Classification of Diseases (ICD).....	16
3.1.3	Study populations	17
3.2	Methods.....	19
3.2.1	DNA detection.....	19
3.2.2	RNA detection	20
3.2.3	P16 analysis	21
3.3	Statistical analysis	23
3.3.1	Paper I.....	23
3.3.2	Paper II	23
3.3.3	Paper III	23
3.3.4	Paper IV.....	24
4	Results.....	25
4.1	Paper I	25
4.2	Paper II	27
4.3	Paper III.....	28
4.4	Paper IV	30
5	Discussion	34
6	Future perspectives.....	38
7	Acknowledgements.....	40
8	References	42

LIST OF ABBREVIATIONS

HPV	human papillomavirus
HNC	head and neck cancer
SCC	squamous cell carcinoma
SEER	Surveillance, Epidemiology and End Results
UICC	International Union Against Cancer
WHO	World Health Organization
DNA	deoxyribonucleic acid
mRNA	messenger-ribonucleic acid
LCR	long control region
Rb	retinoblastoma
CDC	Centre for Disease Control
VLP	virus-like particles
ICD	International Classification of Diseases
IHC	immunohistochemistry
PCR	polymerase chain reaction
IARC	International Agency for Research on Cancer
ISH	in situ hybridization
EGFR	epidermal growth factor receptor

1 INTRODUCTION

Head and neck cancer (HNC) is the sixth most common cancer worldwide[1]. The incidence of HNC varies greatly worldwide. Oral and oropharyngeal cancer represent 3-5% of the malignancies in the western world, but in Asia (India), this figure reaches up to 40-50%[2]. The vast majority of HNC is considered to be associated with traditional risk factors; smoking and alcohol abuse[3]. In later years a decreased incidence of HNC overall, possibly associated with less smoking[4], but an increase in oropharyngeal cancer has been seen [5, 6]. Accumulating epidemiological and molecular data show that high risk Human Papillomavirus (HPV) is partly responsible for this increase and in many countries in the western world, HPV-positive oropharyngeal cancer is now in majority[7, 8].

Treatment for oropharyngeal cancer frequently carries severe side effects, such as dryness of the mouth, difficulties with swallowing, esophageal strictures and osteoradionecrosis. TNM and tumor stage are the only well established prognostic factors and the basis for choice of treatment. Since outcome for patients with HNC in general is poor, treatment for this group has gradually become more intensified in an attempt to cure more patients. The flip side of the coin is that more treatment also carries more side effects. The identification of clinically usable predictive markers is vital to enable optimization of treatment and reduction of sequelae.

In the oropharynx, patients with tumors of different subsites have different prognosis[9] and may get diverse treatment. Despite that, few studies on oropharyngeal cancer distinguish between the subsites, i.e. tonsillar fossa, base of tongue, soft palate, uvula and posterior pharynx. Our research group has earlier described a large increase in tonsillar cancer incidence and a parallel increase in HPV prevalence from 1970 to 2002. We now wanted to study the continuous development of tonsillar cancer incidence. Little is known about the incidence of base of tongue cancer over time, the HPV prevalence in base of tongue cancer and HPV's effect on survival. Due to the better outcome, several authors have advocated that treatment for HPV-positive oropharyngeal cancer should be de-escalated, but few studies have investigated outcome of different treatments for patients with HPV positive tumors.

1.1 OROPHARYNGEAL CANCER

1.1.1 The oropharynx

The oropharynx or mesopharynx lies behind the oral cavity, extending from the uvula to the level of the hyoid bone. It opens anteriorly, through the isthmus faucium, into the mouth. The anterior wall consists of the base of the tongue and the epiglottic vallecula; the lateral wall is made up of the tonsil, tonsillar fossa, and tonsillar (faucial) pillars; the superior wall consists of the inferior surface of the soft palate and the uvula and the posterior wall consists of the posterior pharyngeal wall. The oropharynx is lined by non keratinized squamous stratified epithelium.

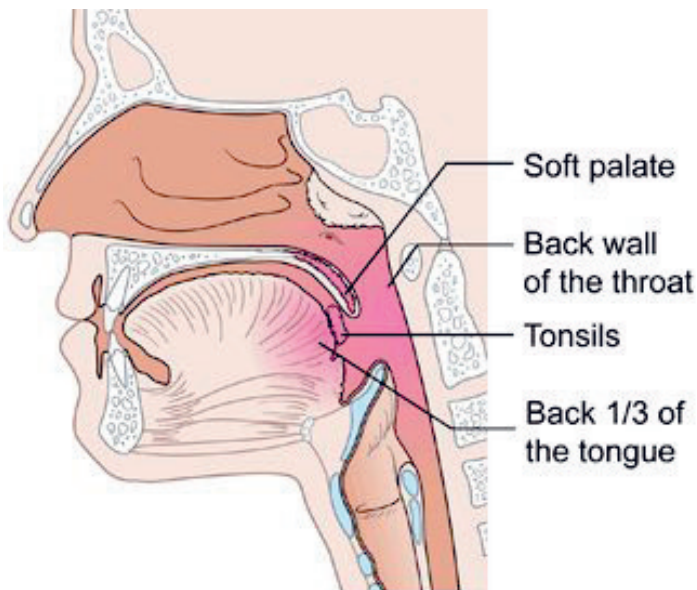


Figure 1: The parts of the orofarynx. From CancerHelp UK
(<http://cancerhelp.cancerresearchuk.org/>)

1.1.2 Oropharyngeal cancer

The vast majority of oropharyngeal cancer is squamous cell carcinoma (SCC)[10]. In Sweden, as well as in other western countries, tonsillar cancer is the most common oropharyngeal cancer[3] with base of tongue cancer being the second most common[10]. The other sub-sites of the oropharynx (non-tonsill and non-base of tongue) i.e. soft palate, uvula and posterior pharynx wall, are a distant third.

Tonsills and base of tongue are both part of Waldeyers ring and share morphological and histological similarities with underlying lymphoid tissue. There are both similarities and differences in tonsillar and base of tongue cancer patients: Clinical presentation, treatment and prognosis differ somewhat between the two groups while both carry a strong relationship with HPV[11, 12]. Patients with tonsillar cancer often present with unilateral sore throat or ear ache but it is not unusual that patients first demonstrate a neck mass which turns out to be a nodal metastasis. Patients with base of tongue cancer may have no or very little symptoms from the primary site, but commonly seek medical help due to discomfort when swallowing. Non-tonsill and non-base of tongue parts of the oropharynx does not share the same features and these cancer patients do more resemble oral cancer or hypopharyngeal cancer patients.

Risk factors for oropharyngeal cancer are similar to many head and neck cancers: smoking and alcohol abuse, but also HPV is now recognized as one of the primary causes of oropharyngeal SCC[13].

Oropharyngeal cancer has attracted a lot of attention in the last years, partly because of an international trend of increased incidence[5, 6, 14, 15], but also because HPV has been identified as playing an important role for that increase[8, 16-20].

Previous studies have shown a strong relationship with HPV and tonsillar as well as base of tongue cancer while non-tonsil, non-base of tongue cancer have not been shown to be as closely linked to HPV[21, 22].

1.1.3 Epidemiology

One reason for the varied incidence of Head and Neck Cancer (HNC) over the world is the different use of tobacco, both smoking and smokeless/chewing tobacco. In countries/areas with high tobacco use there are also higher incidences of HNC. In parts of India, oral tobacco chewing (betel/areca nut chewing) is one explanation to the very high incidence of HNC[23]. It has been shown that in countries with a decrease in tobacco use, incidence of HNC also decreases[5, 24].

In general, men have higher incidence rates of oropharyngeal cancer than women (two to five times) but in Vietnam and in the Philippines, women have higher incidence than men. In China, the incidence of oropharyngeal cancer is comparably low, but higher in parts of the country with large western influence, like Hong Kong[2].

An increase in oropharyngeal cancer incidence has been seen in several countries in the developed world; Sweden[6], Finland[25], Australia[15], USA[5, 24], Denmark[26], Norway[27] and the Netherlands[14]. In all these countries, HPV is believed to be responsible for this increase. In the US, SEER (Surveillance, Epidemiology and End Results) data show that base of tongue cancer incidence rose by 1.3% and tonsillar cancer incidence by 0.6% annually between 1973 and 2004. In 1973, SEER data suggests that 18% of HNC was oropharyngeal cancer, but in 2004, that proportion had risen to 31%[5].

1.1.4 Classification

Classification of oropharyngeal cancer is done at diagnosis according to the TNM-system by International Union Against Cancer, UICC. The TNM-system is based on size of the primary tumor (T), presence, size, number and localization of regional metastasis (N) and presence of distant metastasis (M). The latest classification scheme is from 2002:

TNM staging-Oropharynx

Primary tumor (T) – oropharynx

TX:	Primary tumor cannot be assessed
T0:	No evidence of primary tumor
Tis:	Carcinoma in situ
T1:	Tumor 2 cm or less in greatest dimension
T2:	Tumor more than 2 cm but not more than 4 cm in greatest dimension
T3:	Tumor more than 4 cm in greatest dimension or extension to lingual surface of epiglottis
T4a:	Moderately advanced local disease – tumor invades the larynx, extrinsic muscle of tongue, medial pterygoid, hard palate or mandible
T4b:	Very advanced local disease - tumor invades lateral pterygoid muscle, pterygoid plates, lateral nasopharynx or skull base or encases carotid artery

Note: mucosal extension to lingual surface of epiglottis from primary tumors of the base of the tongue and vallecula does not constitute invasion of larynx

Regional lymph nodes (N) – oropharynx

NX:	Regional lymph nodes cannot be assessed
N0:	No regional lymph node metastasis
N1:	Metastasis in a single ipsilateral lymph node, 3 cm or less in greatest dimension
N2:	Metastasis in a single ipsilateral lymph node, more than 3 cm but not more than 6 cm in greatest dimension; or in multiple ipsilateral lymph nodes, none more than 6 cm in greatest dimension; or in bilateral or contralateral lymph nodes, none more than 6 cm in greatest dimension
N2a:	Metastasis in a single ipsilateral lymph node more than 3 cm but not more than 6 cm in greatest dimension
N2b:	Metastasis in multiple ipsilateral lymph nodes, none more than 6 cm in greatest dimension
N2c:	Metastasis in bilateral or contralateral lymph nodes, none more than 6 cm in greatest dimension
N3:	Metastasis in a lymph node more than 6 cm in greatest dimension

Distant metastasis (M) – oropharynx

M0:	No distant metastasis
M1:	Distant metastasis

Using the TNM-stage, patients are grouped in stage/prognostic groups:

Stage / prognostic groups – oropharynx

Stage 0:	Tis N0 M0
Stage I:	T1 N0 M0
Stage II:	T2 N0 M0
Stage III:	T3 N0 M0 or T1-3 N1 M0
Stage IVA:	T4a N0-1 M0 or T1-4a N2 M0
Stage IVB:	T4b Any N M0 or Any T N3 M0
Stage IVC:	Any T Any N M1

1.1.5 Treatment

Today, most centers treat base of tongue and tonsillar cancer primarily with oncological treatment, i.e. radiotherapy with/without chemotherapy.

External radiotherapy can be administered as conventionally fractionated (once/day for 5 days/week, usually delivering 2 Gy/day until reaching 68-72 Gy) or altered (hyperfractionated/ accelerated) fractionation. Hyperfractionated radiotherapy usually consists of a 10–15% total dose increase, using several daily sessions. There are several protocols for hyperfractionated radiotherapy, for example the EORTC trial 22791 which used two daily sessions of 1.15 Gy, up to 80.5 Gy given over 7 weeks. In accelerated radiotherapy the conventional schedule is accelerated thus reducing the overall treatment time as exemplified in the EORTC 22851 study where three daily sessions, each of 1.60 Gy, up to 72 Gy over 5 weeks was administered. For accelerated radiotherapy the objective is to limit tumor repopulation and counterbalance fast tumor growth. Other examples of accelerated radiotherapy are accelerated fractionation with concomitant boost, where 1.8 Gy/fraction/day, 5 days/week to large field is administered and 1.5 Gy/fraction/day is administered to a boost field. The Danish DAHANCA trial has been using moderate accelerated radiotherapy at 2 Gy/fraction, once daily for 6 days/week. To complicate matters even more, radiotherapy treatment protocols can be both hyperfractionated and accelerated at the same time. In altered fractionation regimes delivering two daily sessions, the time interval between the fractions is of critical importance and should respect a window of at least 6–7h to allow repair of sub-lethal damage in normal tissues[28]. Some studies show benefit of altered fractionation[29], but a recent Swedish study show no significant advantage for tonsillar or base of tongue cancer[30].

Interstitial radiotherapy (brachytherapy) is sometimes used to treat oropharyngeal cancer. It can be used as the sole treatment, but typically it is combined with external radiotherapy and/or chemotherapy. Administering brachytherapy in oropharyngeal cancer means plastic tubes are inserted in the tumor in a pre-defined pattern. This is normally done under general anesthesia. Concomitant chemotherapy during brachytherapy is not recommended outside clinical trials[31].

Chemotherapy can be administered as induction, concomitant or adjuvant. Induction chemotherapy is given prior to radiotherapy start and often consists of two cycles of

Cisplatin, 5- fluorouracil and sometimes docetaxel. Concomitant chemotherapy is administered during radiotherapy, for example using cetuximab weekly[32]. Adjuvant chemotherapy is normally administered after surgery where some tumor features suggest residual tumor. Adjuvant chemotherapy is sometimes combined with radiotherapy and may consist of cispatin or cetuximab.

Historically, surgical treatment was more common 20-30 years ago with radical excision and free flap coverage of the primary site. Today, surgery toward the primary site is often reserved for salvage surgery, i.e. recidual or recurrent tumor after oncological treatment. Some centers, however, use transoral laser microsurgery as a primary treatment modality for oropharyngeal cancer[33]. Neck dissection is performed when extensive neck metastases are present, or if patients do not have complete response after radiotherapy. Combined treatment is common, but no consensus is adopted worldwide or even nationally.

At the Department of Otorhinolaryngology, Head and Neck Surgery, Karolinska University Hospital, patients with base of tongue cancer are treated with external radiotherapy combined with interstitial radiotherapy (brachytherapy) and in some cases also with chemotherapy. Patients with tonsillar cancer are also treated with external radiotherapy, sometimes combined with chemotherapy either as induction or concomitant. In advanced cases, tonsillar cancer patients also receive interstitial radiotherapy. Neck dissection for these two tumor types is performed when the patient is staged in N3 at diagnosis or if palpable neck mass is present after the oncological treatment.

1.2 HPV

1.2.1 History

In 1842, the Italian physician Rigoni-Stern noted a high frequency of cervical cancer in married women, widows and prostitutes, but a rare occurrence in virgins and nuns. He concluded that the development of this disease was related to sexual contacts. In the second part of the 19th century the rapid development of bacteriology and virology resulted in theories linking cervical cancer to sexually transmitted infections. When analytical and epidemiological methods improved, a herpes virus, Herpes simplex type 2, was proposed as a candidate for cervical cancer etiology[34-36]. Initially, a number of studies supporting this theory was published, but a large scale prospective study performed in former Czechoslovakia failed to confirm these results[37, 38].

Human Papilloma Virus (HPV) was first identified in 1949, using electron microscopy[39]. In the nineteen-seventies, it was understood that HPV is a family of viruses, causing different diseases. Today, more than 120 HPV types have been identified[40] and among those, around 15 HPV types are so called “high risk”, due to their role in cancer development.

In 1976, Harald zur Hausen published the hypothesis that HPV may play an important role in the development of cervical cancer[41]. In 1983, zur Hausen and associates isolated HPV-16 and the following year HPV-18, which we today know cause a large proportion of cervical cancer. These findings, which eventually led to the development of HPV vaccines, were the reason why Harald zur Hausen received the 2008 Nobel Prize in Physiology / Medicine.

Syrjänen and associates demonstrated HPV antigen using immunoperoxidase staining with anti-HPV serum in premalignant lesions of the oral cavity in 1983[42]. Since then, a large number of reports have confirmed these data[43-45] and HPV is now recognized by IARC as a risk factor for oropharyngeal cancer.

1.2.2 Virus anatomy

HPV is an 8-kb, double-stranded, circular DNA virus. The virus is enclosed in a 52-55 nm viral capsid and is organized in three different regions: the long control region (LCR, a non-coding region where the regulation of viral gene expression is regulated), the early region (E, which codes for the E1-E2 and E4-E7 proteins) and the late region (L, which codes for the capsid proteins L1-L2). The proteins produced in the early region (E1-2, E4-E7) play a major role in gene regulation, replication, carcinogenesis and transformation. The molecular basis of the difference in malignant potential between low- and high-risk HPV infections is not completely understood. Most likely this is caused by differences in the ability of oncoproteins E6 and E7 to induce transformation of cells[46]. In cervical cancer, the HPV genome is mainly integrated with the host cells genome[47] which can lead to disruption of the E2 gene. This is believed to be one explanation to tumor development as E2 regulates the expression of E6/E7. In oropharyngeal cancer, there are reports of HPV being either episomal[48] or integrated [49] while others report a mix of episomal and integrated[50].

Disease	HPV type
Common warts	2, 7
Plantar warts	1, 2, 4, 63
Flat warts	3, 10
Anogenital warts	6, 11, 42, 44 and others
Genital cancers	Highest risk: 16, 18, 31, 45 Other high-risk: 33, 35, 39, 51, 52, 56, 58, 59 Probably high-risk: 26, 53, 66, 68, 73, 82
Epidermodysplasia verruciformis	Over 15 types
Focal epithelial hyperplasia (oral)	13, 32
Oral papillomas	6, 7, 11, 16, 32
Oropharyngeal cancer	16
Laryngeal papillomatosis	6, 11

Figure 2: HPV types and associated diseases

1.2.3 HPV and cancer development

HPV infection is restricted to the basal cells in the epithelial layers of the mucosa. The virus prefer to target the highly specialized epithelium that lines tonsillar crypts[49]. Replication takes place within the infected cell nucleus and is dependent on S-phase entry[51]. Once the virus integrates its DNA genome within the host cell nucleus, expression of the oncoproteins E6 and E7 takes place. These oncoproteins are necessary through their proliferation stimulating activity and play a key role in malignant transformation and maintenance[52].

The E6 protein degrades P53 through ubiquitin-mediated proteolysis, leading to substantial loss of P53 activity. P53 usually functions to arrest cells in G1 or induce apoptosis to allow host DNA to be repaired. E6-expressing cells are not capable of this P53-mediated response to DNA damage and are therefore susceptible to genomic instability[53].

The HPV E7 protein binds and degrades the retinoblastoma protein (pRb), preventing it from inhibiting the transcription factor E2F resulting in cell-cycle disruption, proliferation, and malignant transformation[52]. The functional inactivation of Rb results in the overexpression of the protein p16. HPV-positive tumors are consequently characterized by high levels of p16[54]. Several studies have shown a very high correlation (>90%) between high levels of p16 and HPV-positivity in oropharyngeal tumors and it has been suggested as a clinically useful surrogate marker for HPV[55, 56].

In head and neck cancer related to the traditional risk factors (tobacco and alcohol), p53 is often mutated[57, 58] and on chromosome 9, p21-22 is lost early in carcinogenesis, resulting in loss of the tumor suppressing gene p16[49]. HPV-positive head and neck tumors have a lower expression of wild-type p53 due to its inactivation and degradation by the E6 oncoprotein. An inverse relationship between HPV-16 infection and disruptive p53 gene mutations in head and neck carcinoma has been suggested[59], leading to the conclusion that HPV positive head and neck tumors represent a distinct molecular phenotype with a unique mechanism of tumorigenesis independent of the carcinogenic effects of tobacco and alcohol.

1.2.4 HPV and oropharyngeal cancer

In several western countries, the majority of patients with oropharyngeal cancer harbor HPV-positive tumors. The natural history and tumor development of HPV-infection are not yet fully understood. When characterizing HPV-positive oropharyngeal cancer, HPV-16 is highly prevalent in all studies, in contrast to cervical cancer, where the prevalence of different HPV types varies worldwide. Other high-risk HPVs (HPV-31, -33, -58, -59, -62, -72) are less common and HPV-18, which is the second most common HPV type in cervical cancer, is very rare in oropharyngeal cancer[60, 61].

HPV-positive oropharyngeal cancer has been recognized as a separate entity with different clinical features compared to HPV-negative oropharyngeal cancer: patients with HPV-positive tonsillar cancer are younger than patients with HPV-negative tonsillar cancer[12, 19]. Many of these patients have no history of tobacco and/or high alcohol consumption and generally have a better performance status[24, 43]. At diagnose, patients with HPV-positive oropharyngeal cancer often have a small T-stage (T1-T2) but quite often advanced nodal involvement (N+), resulting in a clinically advanced stage (Stage III-IV)[7, 62-64]. HPV-positive tumors also have different histopathological features; the tumors have a basoloid appearance, do not undergo significant keratinization and are usually poorly differentiated[65].

The most striking clinical difference between patients with HPV-positive and HPV-negative tonsillar and base of tongue cancer is the favorable prognosis for patients with HPV-positive cancer. This advantage is independent of nodal status, age, stage, tumor differentiation and sex[7, 22, 66, 67].

Risk factors for HPV positive oropharyngeal cancer are mostly associated with sexual behavior, i.e. early sexual debut and increasing numbers of sexual partners. It is suggested that these cancers are sexually transmitted[43, 68].

1.2.5 HPV Vaccines

In the HPV genome, the late region (L) codes for the capsid protein L1. L1 can self-assemble into virus-like particles (VLPs). Preventive HPV vaccines contain VLPs from HPV-16 and HPV-18 L1[69].

Today there are two HPV vaccines on the market: Gardasil© (Merck & Co.) and Cervarix© (GlaxoSmithKline). Both vaccines protect against the two HPV types (HPV-16 and HPV-18) that cause the majority of cervical cancer. These types also cause most HPV-induced genital and head and neck cancer. Gardasil© also protects against HPV-6 and HPV-11 that cause 90% of genital warts and has been shown to also be effective in preventing genital warts in males.

In a recent study, a follow-up comparing the two vaccines showed 2-9 times higher titers of HPV-16 and HPV-18 antibodies after vaccination with Cervarix© compared to those vaccinated with Gardasil©. The authors state that although an immunological correlate of protection has not been defined, differences in the magnitude of immune response between vaccines may represent duration of protection[69].

In the US, the Center for Disease Control and Prevention (CDC) recommend that the vaccine should be given to boys ages 11-12. CDC's recommendation is intended to prevent genital warts and anal cancers in males, and possibly prevent head and neck cancer although the vaccine's effectiveness against head and neck cancers has not yet been proven.

For those already infected with high-risk HPV, preventive vaccines are not effective but lately an interesting approach to battle HPV-caused cancer has emerged[70]. Using DNA-vaccines targeting the HPV-specific E6/E7 proteins, the vaccine will be delivered into the skin where many immature dendritic cells, Langerhans cells, are located. It is now clear that dendritic cells are key players by initiating an immune response. The HPV antigens E6 and E7 represent ideal targets for the control of head and neck cancer since they are constantly expressed, essential for tumor phenotype, not expressed on normal cells and contribute to tumor progression. Experimental studies also show, that the effect of therapeutic vaccines is improved when combined with radiotherapy and cisplatin[71].

2 AIMS OF THESIS

The aims of this thesis were to investigate any change in incidence of tonsillar and base of tongue cancer in Sweden, the role that HPV may have had in this change and the prognostic value of HPV as well as the outcome of different treatment regimes on HPV positive tonsillar cancer.

Specific aims:

- To investigate if the incidence of tonsillar cancer has continued to increase and if the proportion of HPV-positive tonsillar cancer patients continues to increase.
- To investigate any change in the incidence of base of tongue cancer and the proportion of HPV positive base of tongue cancer over time.
- To investigate if the prevalence of HPV in base of tongue cancer has any impact on prognosis of the disease.
- To investigate if different treatment regimes given to patients with HPV-positive tonsillar cancer affect prognosis.

3 MATERIALS AND METHODS

3.1 MATERIALS

3.1.1 Swedish Cancer Registry

The Swedish Cancer Registry was founded in 1958 and covers the whole population. Since 1960 the registry is considered reliable and covers more than 98% of cancer cases[72]. Approximately 50 000 cases of cancer are registered every year in Sweden.

It is compulsory for every health care provider in Sweden to report newly detected cancer cases to the registry. A report has to be sent for every cancer case diagnosed at clinical-, morphological -, other laboratory examinations as well as cases diagnosed at autopsy.

There are three different types of information available in the Swedish Cancer Register:

- 1) Data on the patient: personal identification number, sex, age and place of residence.
- 2) Medical data: site of tumor (coded according to ICD-7), histological type, basis of diagnosis, date of diagnosis, reporting hospital and department, reporting pathology/cytology department and identification number for the tissue specimen.
- 3) Follow-up data: date of death, cause of death and date of migration.

A quality study of the cancer register was published in *Acta Oncologica* in 2009 where the coverage rate was evaluated in comparison to the inpatient registry. The rate of underreporting was estimated to approximately 4 percent[73].

The amount of underreported cancer cases can also be estimated by comparing the Cancer Register data with the Cause of Death Register, since the Swedish Cancer Register does not accept notifications from death certificates. This shows that the underreporting is highly dependent on the cancer site; for example breast cancer has very low underreporting while there are a larger amount of pancreatic and lung cancer not reported to the cancer registry.

3.1.2 International Classification of Diseases (ICD)

International Classification of Diseases (ICD) is the international standard diagnostic classification used to classify diseases and other health problems recorded on many types of health and vital records including death certificates and health records.

In addition to enabling the storage and retrieval of diagnostic information for clinical, epidemiological and quality purposes, these records also provide the basis for the compilation of national mortality and morbidity statistics by World Health Organization (WHO) member States.

In clinical practice use today is the tenth revision, ICD-10, the latest in a series which has its origin in the 1850s. ICD-10 was endorsed by the Forty-third World Health Assembly in May 1990 and came into use in WHO Member States as from 1994.

The first edition, known as the International List of Causes of Death, was adopted by the International Statistical Institute in 1893. WHO took over the responsibility for the ICD at its creation in 1948 when the Sixth Revision, which included causes of morbidity for the first time, was published.

The Seventh Revision of ICD, the version used by the Swedish Cancer Registry, was endorsed in Paris under the auspices of WHO in February 1955.

3.1.3 Study populations

When retrieving patients for the articles, both the Swedish Cancer Registry and the local registry at the Department of Otorhinolaryngology, Head and Neck Surgery, Karolinska University Hospital were used.

Patients retrieved from the Swedish Cancer Registry had their diagnose coded according to ICD-7 while the patients retrieved from the local registry at the ENT-department, Karolinska University Hospital were coded using ICD-10.

For patients with base of tongue cancer, there is no difference, ICD-10 code C01.9 is the same as ICD-7 code 141.0. For tonsillar cancer, however, ICD-7 code 145.0 is translated to ICD-10 code C09.0 (tonsillar fossa) while the also used C09.8 (overlapping lesion of tonsil) and C09.9 (tonsil, unspecified) are not included, leaving some patients with tonsillar cancer out from the Cancer Registry cohort.

The studies were conducted according to ethical permissions 2005/431-31/4, 2005/1330-32 and 2009/1278-31/4 from the Ethical Committee at Karolinska Institutet, Stockholm, Sweden.

Paper I

For Paper 1, all patients in Stockholm County, Sweden diagnosed with tonsillar squamous cell carcinoma (ICD-7 code 145.0, histology code 146) between 1970 and 2006 were retrieved from the Swedish Cancer Registry. A total of 659 cases of tonsillar cancer were diagnosed during this period.

For HPV prevalence, all patients diagnosed with tonsillar squamous cell carcinoma (ICD-7 code 145.0) between 2003 and 2007 in Stockholm County were identified using the Swedish Cancer Registry. Pre-treatment biopsies were obtained for HPV PCR analyses and clinical data on all patients and tumor characteristics were obtained from the medical records at the Department of Otorhinolaryngology, Head and Neck Surgery, Karolinska University Hospital.

Paper II and III

All patients in Sweden diagnosed with base of tongue squamous cell carcinoma (ICD-7 code 141.0, histology code 146) between 1970 and 2007 were retrieved from the Swedish Cancer Registry. All together there were 931 cases.

For HPV prevalence, all patients diagnosed with base of tongue cancer in Stockholm County between 1998 and 2007 were identified using the local registry at the Department of Otorhinolaryngology, Head and Neck Surgery, Karolinska University Hospital (ICD-10 code C01.9). Clinical data and tumor characteristics were obtained from the medical records (at the Department of Otorhinolaryngology, Head and Neck Surgery, Karolinska University Hospital).

These patients were also the study base for survival analysis in Paper 3.

Paper IV

In Paper 4 all 290 patients diagnosed with tonsillar squamous cell carcinoma (ICD-10 codes C09.0-C09.9 in the County of Stockholm, Sweden, between 2000 and 2007 were identified using the local cancer registry. Of these, patients treated with the intention to cure and who were positive for HPV by PCR and for p16 by immunohistochemistry were included in the study. Clinical data and tumor characteristics were obtained from the medical records (at the Department of Otorhinolaryngology, Head and Neck Surgery, Karolinska University Hospital).

3.2 METHODS

In paper I-IV we used PCR analysis to identify HPV-DNA in cancer tissue samples. We also analyzed HPV-16 E6 and E7 RNA. These oncogenes are known to be necessary for carcinogenesis in cervical carcinoma and supports HPV as an etiological factor for tonsillar and base of tongue cancer.

For Paper IV, one reviewer recommended that HPV-DNA should be combined with p16 immunohistochemistry analysis to minimize the risk of over-diagnosing HPV-positive samples which is why p16 analysis was added.

3.2.1 DNA detection

Formalin fixed, paraffin embedded tumors were macro-dissected from 2x15 um slides and de-paraffinized in Xylene and rehydrated in ethanol. DNA was extracted according to the manufacturer's instruction for the High Pure RNA Paraffin Kit (Roche Molecular Biochemicals, Mannheim, Germany) with exclusion of the DNase treatment. For each patient sample, 1 blank paraffin control sample without any tissue was taken and treated in the same way to exclude cross-contamination between samples.

Presence of HPV DNA was analyzed by polymerase chain reaction (PCR) using general primer pairs GP5+/6+ (located in the L1 region) and CPl/IIG (located in the E1 region). In addition, all samples were tested using HPV-16 and HPV-33 type specific primers to minimize the risk of false-negative samples due to loss of L1 and E1 regions.

Conditions for the GP5+/6+ were the following; the 50 µl PCR mixture contained 5µl 10 X PCR buffer II (Applied Biosystems, Foster City, CA), 200 µM of each dNTP, 3.5 mM MgCl₂, 25 pmol of each primer and 1U of Taq DNA polymerase (AmpliTaq Gold DNA polymerase, Applied Biosystems) and 5 µl of extracted DNA. Amplification was run in an automated thermocycler (GeneAmp PCR system 9700, Applied Biosystems). The cycles consisted of an initial denaturation of 5 min at 94°C followed by 40 cycles of 95°C for 30 sec, 44°C for 60 sec, 72°C for 90 sec and finally 72°C for 10 min.

The Cpl/IIG PCR were run under the same conditions with the exception of that 3 mM MgCl₂, 0.05% BSA, 17 pmol of Cpl and 26 pmol of CplIIG, and 2.5 U of Taq DNA polymerase were used, and that the PCR program consisted of 5 min at 94°C, 35 cycles of 95°C for 60 sec, 55°C for 60 sec, 72°C for 120 sec and then 72°C for 10 min.

HPV16 protocol consisted of 5 µl 10 X PCR buffer II (Applied Biosystems, Foster City, CA), 200 µM of each dNTP, 3.5 mM MgCl₂, 20 pmol of each primer and 1U of Taq DNA polymerase (AmpliTaQ Gold DNA polymerase, Applied Biosystems) and 5 µl of extracted DNA. PCR cycles consisted of an initial denaturation of 5 min at 94°C followed by 40 cycles of 95°C for 30 sec, 55°C for 30 sec, 72°C for 60 sec and finally 72°C for 4 min. Cloned plasmids of HPV-16 were used as positive controls and blanks without DNA were used as negative controls in all reactions described above.

Samples tested negative for general primers and HPV-16 and HPV-33, were tested by PCR for the human housekeeping gene S14 for verification of amplifiable DNA. The PCR mixture consisted of 5 µl 10 X PCR buffer (Applied Biosystems), 200 µM of each dNTP (Applied Biosystems), 1.5 mM MgCl₂, 4 µg/µl BSA, 15 pmol of each S14 primer, 10 U Taq polymerase (Applied Biosystems) and 100–200 ng sample DNA in a final volume of 50 µl. Water was used as the negative control, and human fibroblast DNA was used as the positive control. Amplification was run in an automated thermocycler (Perkin- Imer, Norwalk, CT) and initiated by a denaturation step at 94°C for 1 min, followed by 40 amplification cycles consisting of denaturation at 94°C for 30 sec, annealing at 50°C for 30 sec and elongation at 72°C for 45 sec. In the final cycle, the elongation step was extended to 5 min. All PCR products were visualized by UV-light on 2.5% agarose gels, stained with ethidium bromide, and only products with the appropriate size were considered as positive.

Samples positive for HPV with general primers and negative for HPV-16 and HPV-33 were sequenced for determination of HPV type on the amplicon generated from these primers. HPV typing was done by direct cycle sequencing of the purified PCR products from the consensus primers using the Big Dye Terminator Cycle Sequencing Kit, carried out in ABI PRISM 377 DNA Sequencer (Applied Biosystems). Both DNA strands were sequenced and aligned to those available at NCBI BLAST GenBank (<http://www.ncbi.nlm.nih.gov/BLAST/>).

3.2.2 mRNA detection

In paper I and II, E6 and E7 mRNA was analyzed to determine if HPV was transcriptionally active. Total RNA was extracted from 60 to 80 µm paraffin-embedded HPV-16 positive tonsillar tumors using a Roche High Pure RNA Isolation kit (Roche Diagnostics Scandinavia) according to the manufacturer's instructions. Blank paraffin

samples were treated the same way. cDNA was synthesized from 800 to 1,000 ng extracted RNA using SuperScript/ III First-Strand Synthesis SuperMix for qRT-PCR kit (Invitrogen). A qualitative real-time PCR with a SYBRgreen protocol was used to detect HPV-16 E6 and E7 cDNA with E6 primers 5'-GAGCGACCCAGAAAGTTACCA-3' and 5'-AAATCCCGAAAAGCAAAGTCA-3' and E7 primers 5'-ACCGGACAGAGCCCATTACAA-3' and 5'-GTGCCCCATTAACAGGTCTTCC-3'. Around 50 ng cDNA was run in a volume of 25 µl with 12.5 µl SYBR Green Supermix (iQ SYBR Green Supermix, Bio-Rad) and 10 pM of each HPV-16 E6 and E7 primers and the PCR program was run as follows: 50° C for 2min and 95° C for 10 min, followed by 40 cycles of denaturation at 95 ° C for 15 s, and annealing and elongation at 60° C for 1 min. Finally, a melting curve, starting at 40° C and increasing by 0.5° C every 10 s until 120° C was reached, was run to verify the specificity of the obtained amplicons. Samples were just considered as positive or negative for HPV-16 E6 and E7 RNA expression. Samples tested negative for presence of E6/E7 HPV RNA were further tested for amplifiable cDNA, using a SYBRgreen protocol with GUSB primers.

3.2.3 p16 analysis

In paper IV, p16 analysis was used instead of E6/E7 analysis to try to identify biologically active HPV. Immunohistochemistry was performed with the p16^{INK4a} primary monoclonal mouse anti-human p16^{INK4a} antibody (clone E6H4) (DakoCytomation A/S, Carpinteria, CA, USA). The staining was performed in an automated deparaffinization and staining machine (BenchMark® XT, Ventana Medical system, Tuscon, AZ, USA). Serial 5-µm sections of formalin-fixed and paraffin-embedded tissue were used with a final haematoxylin and eosin-stained section to confirm the histopathological diagnosis and the representativeness of the cut-off levels. The sections were processed in BenchMark® XT for deparaffinazitation (98°C, for 30 min) and then re-hydrated through graded alcohol. Epitope retrieval was performed by heating and then the sections were treated with peroxidase blocking reagent. The slides were incubated for 32 min (42°C) with 100µl of the monoclonal antibody p16^{INK4a}, followed by incubation with visualisation reagent. The reaction was developed using chromogen solution (DAB) and counterstained with haematoxylin. As a negative antibody control monoclonal mouse igA2 was used. Immunohistochemical staining was evaluated by light microscopy and was graded using a 4-tier scale where 0–1 (absent or weak staining) was regarded as negative and 2–3 (strong or very strong

staining) was regarded as positive. A positive control section from a cervical carcinoma in situ was included with all samples.

3.3 STATISTICAL ANALYSIS

3.3.1 Paper I

The Swedish population as of 2000 was used for age standardization of tonsillar SCC over time. The Pearson Chi-square test was used to compare proportions of HPV DNA-positive samples across time and for calculating differences in tumor stage. Fisher's exact test was used to calculate differences in tumor differentiation. Two-sided p values were reported. An independent, 2-sided t-test was performed to compare the mean age between HPV-positive and HPV-negative cases.

3.3.2 Paper II

We used direct standardization according to the age distribution of the Swedish population in 2000 over the different calendar periods for base of tongue SCC. Fisher's exact test (two-tailed) was used to compare the proportion of HPV DNA-positive samples between different time periods. An independent, two-sided t-test was used to compare the mean age for patients with HPV-positive and HPV-negative tumors, respectively. The associations of HPV status with TNM status, stage and differentiation were calculated using the Freeman-Halton extension of Fisher's exact test (two-tailed) utilizing VassarStats website for statistical calculations (<http://faculty.vassar.edu/lowry/VassarStats.html>).

3.3.3 Paper III

Kaplan-Meier curves were used to present survival data for patients with HPV-positive and HPV-negative tumors and the log-rank test was used in univariate analysis. In multivariable analyses, a Cox proportional hazards model was used to adjust for covariates. The proportional hazards assumption was evaluated with Schoenfeld residuals. An independent, two-sided t-test was used to compare the mean age between patients with HPV-positive and HPV-negative tumors. The association of HPV status with TNM status, stage and histopathological differentiation was calculated using the Freeman-Halton extension of Fisher's exact test (two-tailed) using VassarStats web site for statistical calculations (<http://faculty.vassar.edu/lowry/VassarStats.html>).

3.3.4 Paper IV

Survival analysis was performed using the log-rank test in univariate analysis and a Cox proportional hazards model in multivariable analyses. Kaplan-Meier curves were used to present survival data for patients categorized in the treatment groups. The proportional hazards assumption was evaluated with Schoenfeld residuals. The associations of treatment with sex or age were calculated using Chi-square test while the association between treatment and stage, histopathological differentiation or TNM-status was calculated using Fishers exact test.

4 RESULTS

4.1 PAPER I

A total of 659 cases of tonsillar cancer (ICD-7 code 145.0), was registered in Stockholm County, Sweden between 1970 and 2006 according to the Swedish Cancer Registry. The incidence rate (age-standardized to the population of 2000) of tonsillar cancer increased from 0.74/100 000 person-years in 1970-1974 to 1.65/100 000 person-years in 2000-2006. See table 1:

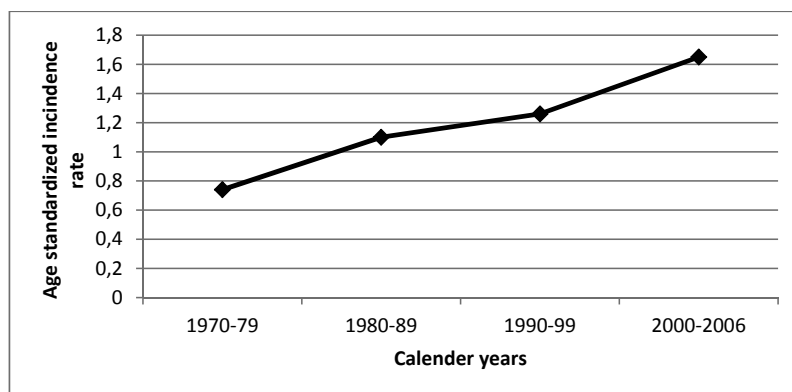


Table 1: Age standardized incidence rate of tonsillar cancer in the Country of Stockholm between 1970 and 2006.

Between 2003 and 2007, 120 patients were diagnosed with tonsillar SCC in Stockholm county. From 98 of these patients (76 males, 22 females), pre-treatment biopsies were available for HPV analysis using PCR. HPV DNA was detected in 83 of these biopsies (85%). 77 biopsies were HPV16 positive, 1 positive for HPV33, 1 positive for HPV35, 1 positive for HPV59 and 3 samples were not possible to type. HPV-16 E6 and/or E7 mRNA expression was demonstrated in 50/51 (98%) available samples.

Patients with HPV-positive tumors were younger with a mean age of 59 at diagnosis, compared to 68 years for patients with HPV-negative tumors ($p = 0.0088$).

Histopathologically, the HPV-positive tumors tended to be lesser differentiated than their HPV-negative counterparts ($p = 0.02$).

When comparing our new data to previous data from our group covering 2000-2002, the proportion of HPV-positive tonsillar cancer biopsies over time is demonstrated in Table 2:

Years	Biopsies retrieved	% HPV DNA* detected from the retrieved biopsies (95% CI)
2000 – 2002	47	68 % (53 – 81)
2003 – 2005	52	77% [†] (63 – 87)
2006 – 2007	46	93% [‡] (82 – 99)
Total	145	115 (79 %)

* Presence of HPV DNA by PCR.
[†] p = 0.3266 compared to the frequency of HPV in the 2000-2002.
[‡] p <0.01 compared to the frequency of HPV in 2000-2002 and p <0.05 compared to the frequency of HPV in 2003-2005.

Table 2: Presence of HPV in tonsillar cancer ICD-7 145.0 between 2000-2007 in the County of Stockholm.

The results for the whole period between 1970 and 2007 shows that the percentages of HPV-positive tonsillar cancer were: 23% in the 1970s, 29% in the 1980s, 57% in the 1990s and 79% for 2000–2007 ($p < 0.0001$). Using HPV prevalence in earlier decades from our earlier studies and incidence data from the Swedish Cancer Registry, we then estimated the trends for HPV-positive and HPV-negative tonsillar cancer in Stockholm County between 1970-1979 and 2000-2006. This is shown in Figure 3:

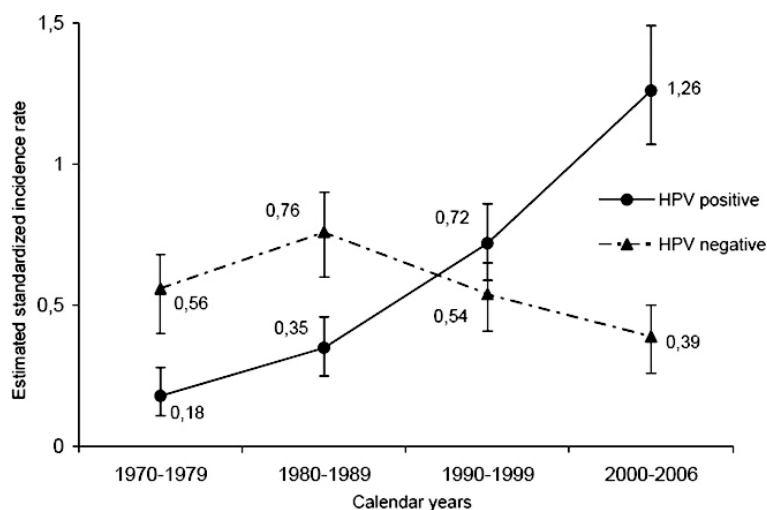


Figure 3: Estimated age standardized incidence rate of HPV-positive and HPV-negative tonsillar SCC in the County of Stockholm between 1970 and 2006.

4.2 PAPER II

During the study period (1970 – 2007) there were 931 cases of base of tongue cancer registered at the Swedish Cancer Registry. The age standardized incidence in Sweden increased from 0.15/100,000 person years during 1970-1974 to 0.47/100,000 person years during 2005-2007. See Figure 4:

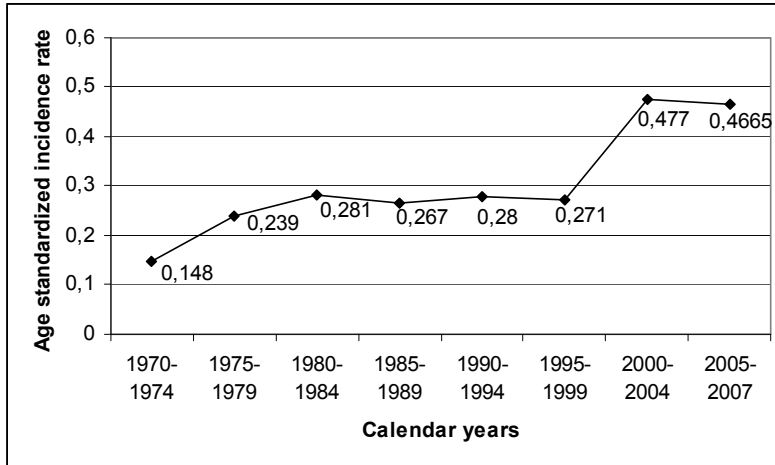


Figure 4: Age-standardized incidence rate of base of tongue SCC per 100000 person-years in Sweden between 1970 and 2007.

In the Stockholm area between 1998 and 2007, 109 patients were diagnosed with base of tongue SCC. From 95 patients (65 male and 30 female), diagnostic pre-treatment paraffin-embedded tumor biopsies could be obtained for HPV testing by PCR. HPV DNA was detected in 71/95 (75%) of all biopsies. Of the HPV-positive tumors, 61/71 (86%) were HPV-16 positive by HPV type-specific PCR and 7 were HPV-33 positive. Direct sequencing of the remaining three HPV-positive samples showed presence of HPV-35 in two and HPV-58 in one sample respectively. RNA from twenty randomly selected and available HPV-positive samples was extracted for analysis of E6 and E7 mRNA expression. Of these samples 17/20 (85%) were positive for both E6 and E7 mRNA.

No significant differences regarding mean age, sex or tumor differentiation were shown between the HPV-positive and HPV-negative group. Patients with HPV-positive tumors were more often in stage IV ($p<0.01$) and showed less advanced T-stage ($p<0.05$) (i.e. smaller tumors), but more advanced N-stage ($p<0.05$).

Stratified over time, there was a trend with increasing frequency of HPV-positive biopsies, see Table 3 below:

Years	Biopsies retrieved	% HPV DNA ¹ detected from the retrieved biopsies (95% CI)
1998-2001	26	58% ² (39 - 77)
2002-2003	24	75% (58 - 92)
2004-2005	26	85% (71 - 99)
2006-2007	19	84% (68 - 100)
Total	95	75%

¹ Presence of HPV DNA by PCR

² $p < 0.05$ compared with the frequency of HPV in 2004-2007

Table 3: Presence of HPV in base of tongue cancer ICD-10 C01.9 between 1998 and 2007 in Stockholm County

4.3 PAPER III

In paper II, 95 pre-treatment biopsies (65 male and 30 female patients) were obtained from the 109 patients diagnosed with base of tongue SCC in Stockholm County 1998-2007. Of these patients where pre-treatment biopsies were available, 87 were treated with curative intent and were included in Paper III. Of the 87 tumor biopsies from the included patients, 68 were identified as HPV DNA positive (78%); 58 were identified as HPV-16 (85%), 7 as HPV-33 (10%), 2 as HPV-35 (3%) and 1 as HPV-58 (2%).

Overall survival for patients with HPV-positive base of tongue cancer was significantly better ($p=0.0004$, log-rank test) compared to patients with HPV-negative cancer (Figure 5). Patients with HPV-positive tumors also had a significantly better disease-free survival ($p=0.0008$, log-rank test) than patients with HPV-negative cancer (Figure 6).

Univariate analyses were performed to evaluate factors potentially associated with overall and disease-free survival. HPV-status, age, sex, tumor stage and treatment were analyzed individually. HPV-status was associated with better both overall and disease-free survival. Chemoradiotherapy treatment was associated with favorable overall survival.

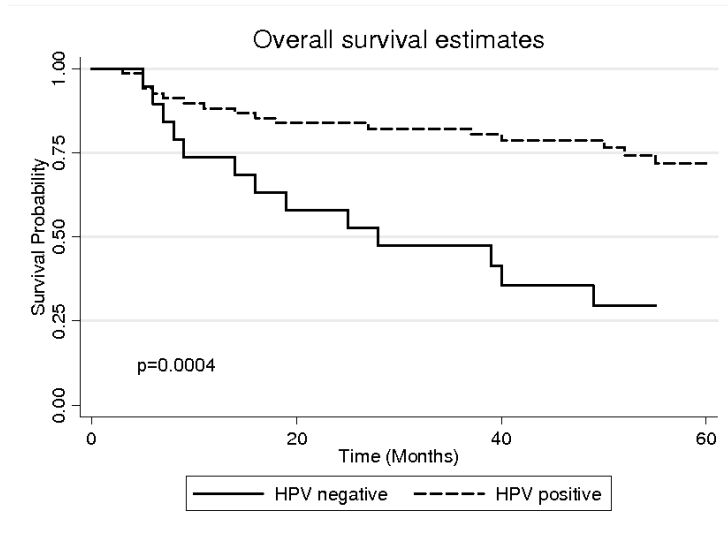


Figure 5: Overall survival illustrated with Kaplan-Meier curve stratified by HPV status.

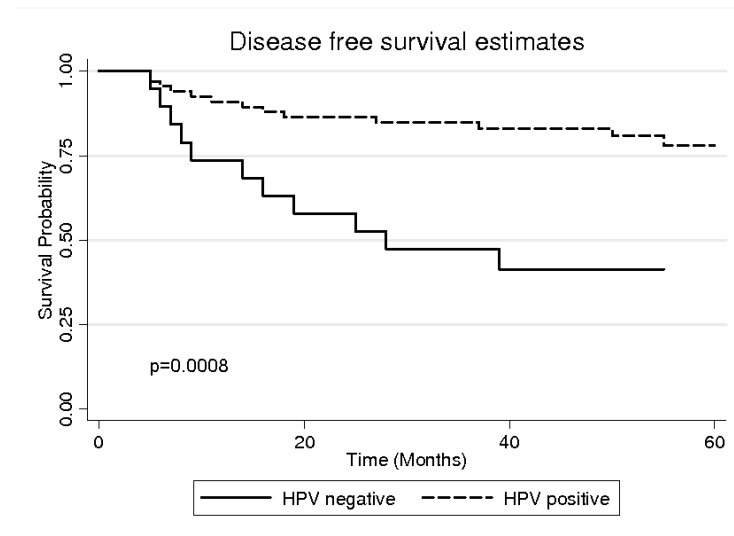


Figure 6: Disease-free survival illustrated with Kaplan-Meier curve stratified by HPV status.

In a multivariable analysis using the Cox proportional hazards model, HPV-status was found to be an independent and significant positive prognostic factor both for overall survival ($p=0.005$) and for disease-free survival ($p=0.004$). Other variables, including treatment, did not affect prognosis significantly.

4.4 PAPER IV

Between 2000 and 2007, 290 patients were diagnosed with tonsillar SCC in Stockholm County. 264 patients were treated with the intention to cure and from these patients 211 tumor pretreatment biopsies were available for HPV analysis. In total 153 patients had HPV-DNA positive and p16-positive tumors and were included in the comparison between the different treatment modalities. The three treatments that were compared were: conventional radiotherapy (86 patients); accelerated radiotherapy (40 patients) and chemoradiotherapy (27 patients). Patients in the three different treatment groups were similar, except for stage, where patients treated with chemoradiotherapy were significantly higher staged than patients in the other two groups ($p=0.002$). When analyzing chemoradiotherapy and radiotherapy groups, 153 patients were included but for the analysis between accelerated radiotherapy and conventional radiotherapy groups, 126 patients were included.

No significant difference in overall or disease-free survival was seen between the conventional or accelerated radiotherapy groups with regard to overall survival (log rank test $p=0.207$, Fig. 7) or disease specific survival (log rank test $p=0.569$, Fig. 7). A multivariable analysis using the Cox proportional hazards model was performed using the following variables: age, sex, treatment and tumor stage. Age above median and mean age was found to be an independent and significant negative prognostic factor for overall survival, but not for disease-free survival ($p=0.001$). For disease free survival patients categorized in Stage 4 had a significantly worse prognosis compared to patients categorized in Stages 1-3 ($p=0.025$). Other included variables were not significant.

When comparing the radiotherapy and the chemoradiotherapy groups, no significant difference in overall survival (log rank test $p=1.0$, Fig. 8), or disease-free survival (log rank test $p=0.357$, Fig. 8) was seen.

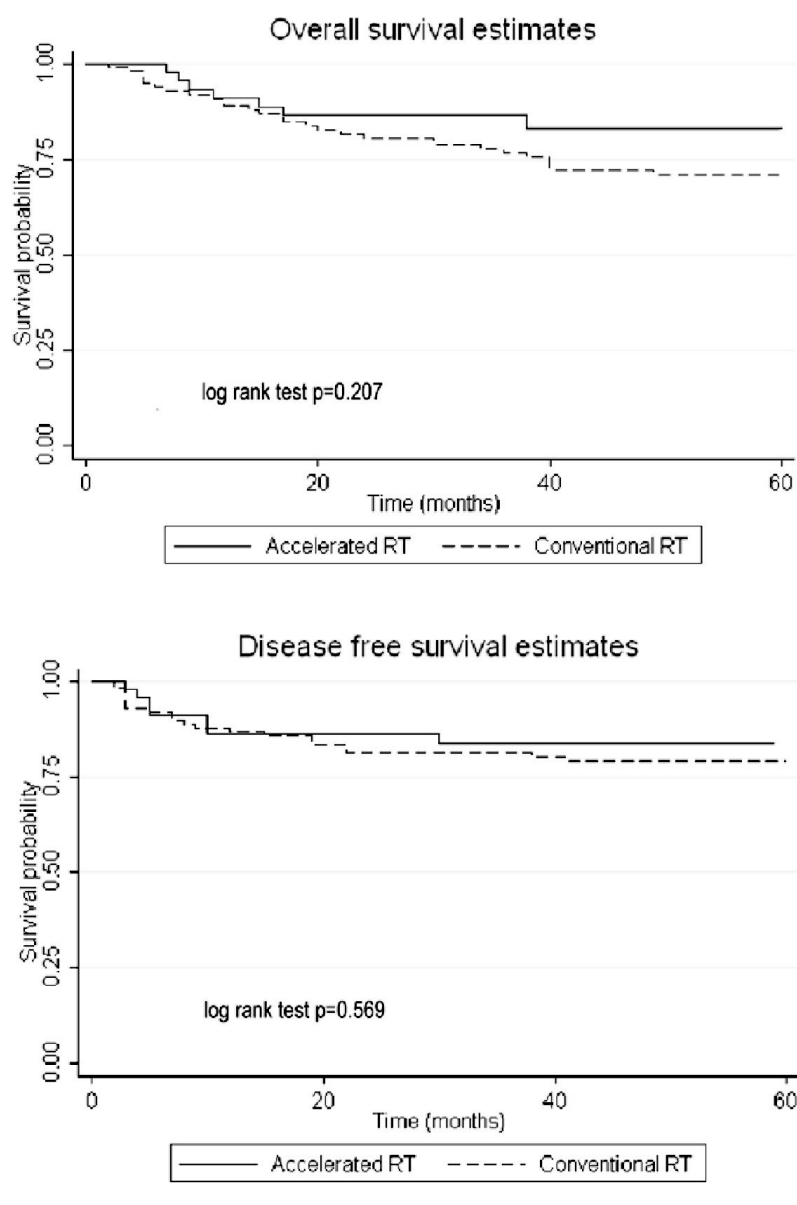


Figure 7: Overall- and Disease-free survival comparing the conventional radiotherapy and accelerated radiotherapy groups

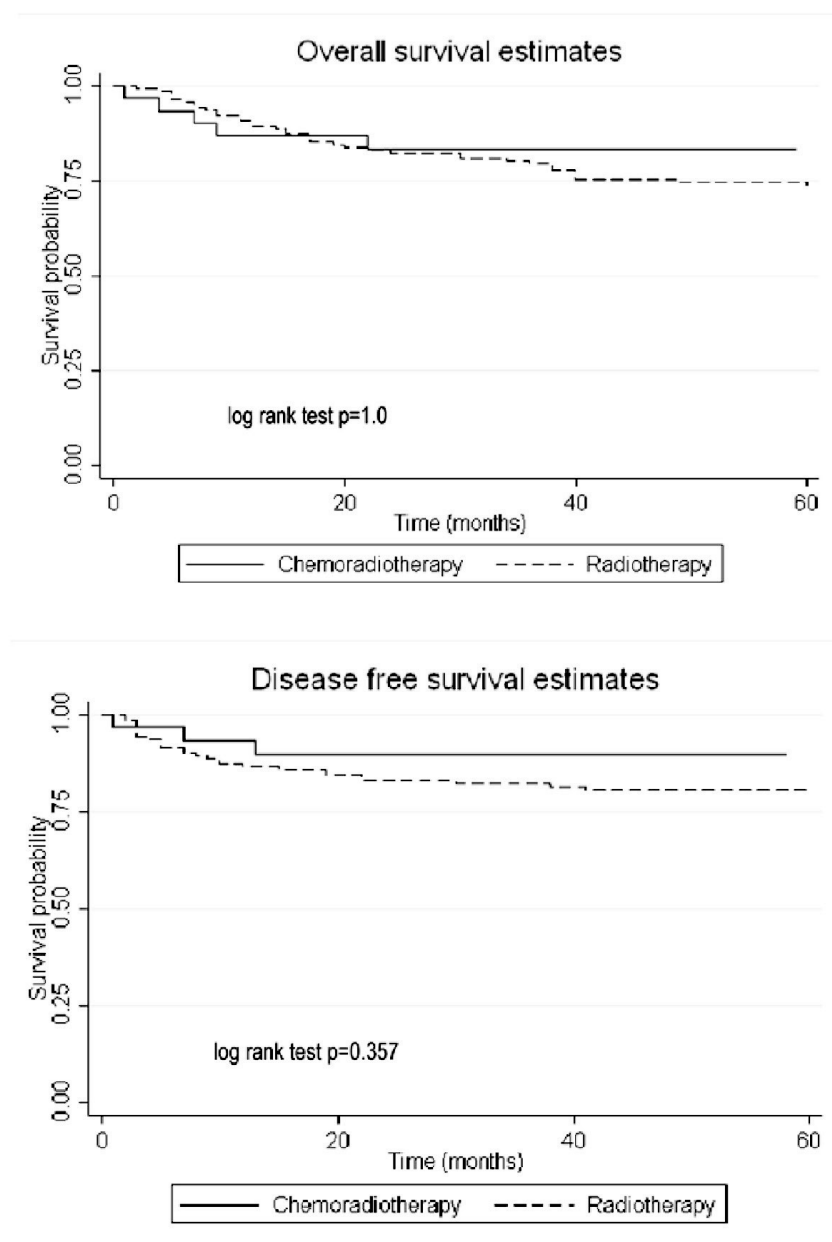


Figure 8: Overall- and Disease-free survival comparing the radiotherapy and chemoradiotherapy groups

To assess the independent predictive value of all factors for overall- and disease-free survival, a multivariable analysis using the Cox proportional hazards model was performed. The same variables: age, sex, treatment and tumor stage were included in the model. Age above median and mean age was found to be an independent and

significant negative prognostic factor for overall survival ($p=0.001$). For disease free survival patients categorized in Stage 4 had a significantly worse prognosis compared to patients categorized in Stages 1-3 ($p=0.025$). Other included variables were not significant.

We also analysed if patients treated with chemoradiotherapy developed fewer distant metastases compared to patients treated with radiotherapy. No significant difference was found comparing the two groups (log-rank test $p=0.450$, Fig. 9). In a uni- and multivariate analysis, no significant differences between the groups were found.

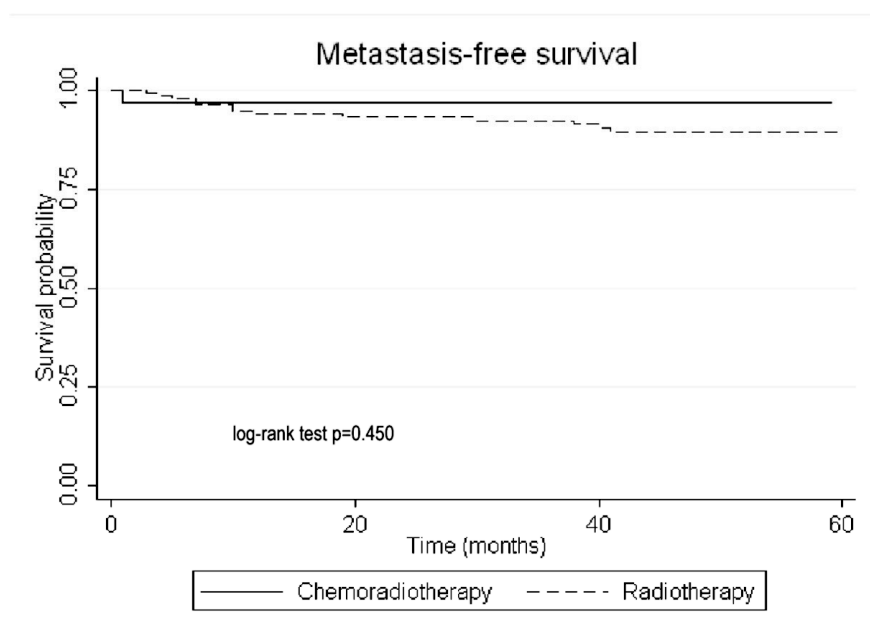


Figure 9: Distant-metastasis free survival comparing the radiotherapy and chemoradiotherapy groups.

5 DISCUSSION

The aim of this thesis was to investigate if the incidence of tonsillar and base of tongue cancer has increased in Sweden and if the proportion of HPV positive tumors has changed over time. We also wanted to see if HPV prevalence in base of tongue cancer has any impact on prognosis of the disease. Finally, we wanted to investigate if different treatment regimes given to patients with HPV-positive tonsillar cancer affect prognosis.

We found a continued increase of tonsillar cancer incidence between 2002-2006 in the Stockholm County as well as of base of tongue cancer in Sweden between 1970 and 2007. The proportion of HPV positive tumors in both tonsillar and base of tongue cancer has increased gradually and we are approaching a situation like in cervical cancer, where almost all tumors are HPV positive. These findings have later been confirmed by others[74]. We and others have earlier found a difference in age between patients with HPV positive and HPV negative tonsillar cancer[12, 75], but in base of tongue cancer, there was no age difference. This is one discrepancy between these sub-sites, but in many other aspects, there are similarities.

For base of tongue cancer, we demonstrated that HPV positivity is a significant prognostic factor both for overall and disease free survival, despite the fact that patients with HPV positive tumors were higher staged. This improved survival is well known for tonsillar cancer and since base of tongue cancer to some extent share pathophysiology with tonsillar cancer i.e both belong to the Waldeyer's ring; this was somewhat expected, but not earlier clearly demonstrated.

When analyzing outcome for patients with HPV positive tonsillar cancer related to three different treatments (conventionally fractionated radiotherapy, accelerated radiotherapy or chemoradiotherapy) we found no significant differences in overall or disease free survival. This might be due to a small study sample and there was a trend (non-significant) that more intensified treatment rendered better prognosis that needs to be investigated further. In another, similar study, Ang et al[76] found no significant difference in overall survival comparing standard fractionated radiotherapy with accelerated radiotherapy for patients with HPV positive tonsillar cancer. In their study, all patients received high-dose cisplatin.

There is no consensus about the best method for HPV analysis, although detection of HPV E6 oncogene expression in frozen biopsies has been considered gold standard[77]. GP5+/6+ PCR, HPV16 E6/E7 mRNA, HPV16 in situ hybridization (ISH) and p16 immunohistochemistry (IHC) are some of the methods favored by different authors[78]. Many authors favor a combination of two standardized methods to clinically evaluate HPV in oropharyngeal tumors[44]. Ultimately, which method to use will be influenced by concerns regarding sensitivity, specificity, reproducibility, cost, and feasibility. For the papers in this thesis, we analyzed tumor-biopsies with respect to HPV by using PCR methodology to detect the presence of HPV DNA.

Others have shown that only detecting HPV DNA is of little or no prognostic value, since it does not distinguish transcriptionally active (i.e. clinically relevant) from transcriptionally inactive (i.e. clinically irrelevant) HPV infection[79]. In HPV-positive oropharyngeal carcinomas, transcription of the viral oncoproteins E6 and E7 is necessary for tumor development, so presence of HPV-16 E6 and E7 mRNA in the biopsies suggests that the virus is transcriptionally active and thus possibly relevant for carcinogenesis. This method was thus used in paper I-III.

E7 inactivates the function of the Rb gene product and induces upregulation of p16 expression, which then can be detected by immunohistochemistry. p16 is sometimes advocated as a surrogate marker of HPV infection for oropharyngeal cancer[55] but p16 overexpression could also suggest Rb pathway disturbances unrelated to HPV[77, 80] (eg, mutational inactivation of retinoblastoma protein). Thus in paper IV, we analyzed HPV DNA presence by PCR and added p16 by immunohistochemistry in order to identify patient biopsies that were positive both for HPV DNA and p16 and included them in the study.

In formalin-fixed, paraffin-embedded tumors the DNA may become fragmented or degraded over time and it has been suggested that this could be one explanation for the increase in HPV prevalence over time. However, in a recent study of formalin-fixed cervical specimens dating back to 1931, high quality DNA was extracted and successfully used for PCR detection of HPV[81]. We also tested all samples negative for general primers and HPV-16 and HPV-33 primers by PCR for the human housekeeping gene S14 for verification of amplifiable DNA. All tested samples had amplifiable DNA which is why our results from HPV DNA analysis by PCR appear reliable.

In paper I, we used data from the Swedish Cancer Registry. Since this data uses the ICD-7 code 145.0 for tonsillar cancer, which translates into ICD-10 code C09.0, we did not include patients diagnosed with tonsillar cancer coded C09.8 (overlapping lesion of tonsil) and C09.9 (tonsil, unspecified). This could mean that, if more patients were classified with C09.8-9 during one or more years, this different coding could lead to misclassification. Since ICD-7, used by the Swedish Cancer Registry, is less specific, including only patients coded with 145.0 the risk of a larger misclassification when ICD-10 codes are translated into ICD-7 codes is eliminated.

When performing our studies, we included only patients with SCC. The reason for this is that other histopathological diagnoses are rare and have different carcinogenic mechanisms than SCC. These other histopathological tumors are only about 5 cases per year and have not increased since the start of the Swedish Cancer Registry, so the risk of these tumors influencing the results is very small.

The Swedish Cancer Registry used to obtain incidence data from and identify patients in papers I-III has been shown to be valid[73] and is comparable to other high quality registers in Northern Europe. For most uses in epidemiological or public health surveillance, potential underreporting has been shown to be minimal.

All four papers are retrospective studies which limit the amount of reliable data on patient performance status, smoking habits, loco-regional control and comorbidity. This highlights the need for prospective, controlled studies with large numbers of patients. Not in any of the studies were we able to include all tonsillar or base of tongue cancer patients, most often due to lack of available pre-treatment biopsies. This could indicate a selection bias if the non-included group differed greatly in HPV prevalence. However, there were no differences in clinical appearance between the included and non-included patient groups regarding age, sex, tumor stage, age period or histopathological stage (data not shown).

When analyzing the tumor biopsies for HPV, we primarily used the general HPV primers GP5+/6+ (targeting the L1 region) and CPI/IIG (targeting the E1 region). Both these regions can be lost, for example when /if the virus DNA is integrated in the host cells genome. To be able to find HPV DNA even in these cases, we also used HPV-16

and -33 specific primers. From earlier studies, it is known that HPV-16 is the most frequent HPV type in oropharyngeal cancer, with frequencies around 90%[12, 82].

It is established that HPV positive and HPV negative oropharyngeal cancer represent two different entities with distinct clinical and molecular-genetic features[43]. One difference between the groups is that HPV positive patients to a lesser extent use alcohol and tobacco. It seems, however, that smoking has a negative impact on survival even for the HPV-positive tumors[83]. This might indicate that the tumors biological behavior may be influenced by smoking. The improved survival for patients with HPV positive oropharyngeal cancer has been shown for surgery[84], radiotherapy[85] and chemotherapy[22]. The reason for the better response to treatment for patients with HPV positive tumors is unclear, but previous studies have found an inverse relationship between tumor HPV status and presence of p53 mutations in head and neck cancer[86]. One explanation to the improved response to oncological treatment for patients with HPV-positive tumors could therefore be explained by the presence of an intact p53-mediated apoptotic response in HPV-positive tumors. Another possibility that has been proposed is immunological factors related to HPV infection[87].

That patients with HPV-positive tonsillar cancer are younger at diagnosis also means that they will suffer the side-effects of the treatment for longer, and this will increase demand for follow-up of the side-effects and rehabilitation. When planning studies on treatment for oropharyngeal cancer, HPV-status needs to be taken into consideration. Studies to identify the curative but least morbid treatment for these patients are needed. The identification of additional biomarkers combined with HPV diagnostics is vital to individualize and optimize treatment for each patient.

6 FUTURE PERSPECTIVES

As vaccination with the two available HPV vaccines starts, it will be of great interest to see the impact on oropharyngeal cancer incidence. The vaccines are primarily developed against cervical cancer and in many countries, only females are vaccinated. Tonsillar and base of tongue cancer are more common in males and in the US, since oropharyngeal cancer has become more common than cervical cancer it is argued that males should be vaccinated as well. The current vaccines are not ideal; they are type specific to only HPV16 and HPV18, the most pathogenic, oncogenic types and one, additionally, targets HPV6 and HPV11, the cause of genital warts. These vaccines are expensive and require refrigeration, multiple doses and intramuscular injection. Second-generation vaccines are currently being developed to address these shortcomings. New expression systems, viral and bacterial vectors for HPV L1 capsid protein delivery, and use of the HPV L2 capsid protein will hopefully aid to decrease cost and increase ease of use and width of protection. These second-generation vaccines could allow affordable immunization of women in developing countries, where the incidence of cervical cancer is high.

Phase I/II trials with therapeutic vaccines with the approach of immunisation with oncogenic HPV E6 and/or E7 proteins and antigen specific cytotoxic T cells as an immunotherapy for HPV associated cancer and high grade precancerous lesions have been tested with a wide array of potential vaccine delivery systems with varying success[88].

Targeted treatment, using antibodies against the epidermal growth factor receptor (EGFR) has been proposed in the treatment against head and neck cancer. In patients with HPV positive oropharyngeal tumors, EGFR overexpression is rare and there are indications of an almost inverse relationship between HPV/p16 status and EGFR expression. The anti-EGFR antibody cetuximab has been shown to reduce mortality in advanced head and neck cancer[89], but while the majority of patients had oropharyngeal tumors, HPV status was not analysed in the study. It is believed that any effect of cetuximab in HPV positive tumors is most probably limited to the small subgroup of EGFR expressing tumors[90].

Antiviral treatment, directed primarily against HPV rather than the cancer, has been tried against HPV-induced cervical tumors. The nucleoside analogue cidofovir, which can be administered both topically and systemically, have shown some effect in clinical settings[91], but trials for its application in HNSCC are not yet initiated.

The question whether HPV-positive oropharyngeal cancer can be treated with less intense treatment compared to HPV-negative patients cannot be answered yet, further studies are needed as there is a lack of high-quality evidence to support this. This lack of evidence could be overcome by initiating high-quality, randomized control trials to identify the most effective treatments for the HPV positive and the HPV negative subgroups. The intensified treatment used to treat patients can lead to acute side effects, which can halt treatment (i.e. severe mucositis) as well as more long-lasting side effects, for example dysphagia/esophageal stricture. Accelerated fractionated radiotherapy and induction chemotherapy have been shown to increase the risk of these side effects[42, 92].

More research is also required to better define the most accurate and feasible diagnostic method for HPV diagnostics in the clinical setting.

7 ACKNOWLEDGEMENTS

To my own surprise, I have completed this thesis and it is time to give credit where it is due. My thanks go out to a lot of people; I would especially like to thank:

My supervisor, Professor **Eva Munck-Wikland**, always enthusiastic and always ready to give advice. I will always be grateful for you taking me in as your PhD-student. I will miss your hand-written suggestions scabbled on any little piece of paper.

My co-supervisor **Linda Marklund**, even if you keep a low profile, your brilliance shines through. Your support and effort will always be remembered.

Lalle Hammarstedt (Nordenvall), co-supervisor, for picking me up onto the HPV-track and for sharing all your epidemiological knowledge.

All my co-authors at CCK, especially **Tina Dalianis, Torbjörn Ramquist, Anders Näsman, Juan Du, Mircea Romanitan** and **Johan Lindholm**, thank you for all your expertise in the field of HPV and paper-writing and not to mention HPV-diagnostics.

Former and present Head of the **Department of Otorhinolaryngology** at Karolinska Universitetssjukhuset, **Richard Kuylenstierna** and **Mats Holmström**, for creating a wonderful workplace and allowing me to finish this thesis.

Department secretary **Agneta Wittlock**, for your invaluable help with the administrative part, keeping track on all forms and files when I didn't.

Former clinical supervisor and current boss, **Sushma Nordemar**, for your friendship and encouragement.

My first clinical supervisor and mentor, **Claes Hemlin**, for your friendship and for actually introducing me to clinical research.

All my colleagues and friends at the **Department of Otorhinolaryngology** at Karolinska Universitetssjukhuset, for making it fun to go to work.

Professors **Lars Olaf Cardell**, **Malou Hultcrantz** and **Dan Bagger-Sjöbäck**, for your continuous work for research and your encouragement.

My roommates **Mattias** and **Michael**, for preparing me for my mid-life crisis.

My wonderful family for support, encouragement and babysitting and most of all **Caroline** and **Calle**, my sweethearts, for keeping my priorities straight.

This thesis was supported by The Swedish Cancer Foundation, The Stockholm Cancer Society, The Swedish Research Council, The Laryngeal Foundation, Henning and Ida Perssons Foundation, The Stockholm City Council, Karolinska Institutet, The ACTA Otolaryngologica Foundation and the Serafimerlasarettet Foundation.

8 REFERENCES

1. Boyle P, L.B., *World Cancer Report 2008*. International Agency for Reasearch on Cancer (IARC), 2008.
2. Parkin, D.M., et al., *Global cancer statistics, 2002*. CA Cancer J Clin, 2005. **55**(2): p. 74-108.
3. Licitra, L., et al., *Cancer of the oropharynx*. Crit Rev Oncol Hematol, 2002. **41**(1): p. 107-22.
4. Sturgis, E.M. and P.M. Cinciripini, *Trends in head and neck cancer incidence in relation to smoking prevalence: an emerging epidemic of human papillomavirus-associated cancers?* Cancer, 2007. **110**(7): p. 1429-35.
5. Shiboski, C.H., B.L. Schmidt, and R.C. Jordan, *Tongue and tonsil carcinoma: increasing trends in the U.S. population ages 20-44 years*. Cancer, 2005. **103**(9): p. 1843-9.
6. Hammarstedt, L., et al., *The incidence of tonsillar cancer in Sweden is increasing*. Acta Otolaryngol, 2007. **127**(9): p. 988-92.
7. Lindquist, D., et al., *Human papillomavirus is a favourable prognostic factor in tonsillar cancer ant its oncogenic role is supported by the expression of E6 and E7*. Molecular Oncol, 2007. **1**: p. 350-355.
8. Mork, J., et al., *Human papillomavirus infection as a risk factor for squamous-cell carcinoma of the head and neck*. N Engl J Med, 2001. **344**(15): p. 1125-31.
9. Makitie, A.A., et al., *Oropharyngeal carcinoma and its treatment in Finland between 1995-1999: a nationwide study*. Eur Arch Otorhinolaryngol, 2006. **263**(2): p. 139-43.
10. The National Board of Health and Welfare, *Cancer incidence in Sweden 2007*, Swedish Cancer Registry, 2008.
11. Dahlgren, L., et al., *Human papillomavirus is more common in base of tongue than in mobile tongue cancer and is a favorable prognostic factor in base of tongue cancer patients*. Int J Cancer, 2004. **112**(6): p. 1015-9.
12. Hammarstedt, L., et al., *Human papillomavirus as a risk factor for the increase in incidence of tonsillar cancer*. Int J Cancer, 2006. **119**(11): p. 2620-3.
13. WHO, IARC *Monographs on the Evaluation of Carcinogenic Risks to Humans Volume 90 (2007) Human Papillomaviruses*. 2007.
14. Braakhuis, B.J., O. Visser, and C.R. Leemans, *Oral and oropharyngeal cancer in The Netherlands between 1989 and 2006: Increasing incidence, but not in young adults*. Oral Oncol, 2009. **45**(9): p. e85-9.
15. Hong, A., et al., *Oropharyngeal cancer. Australian data show increase*. BMJ, 2010. **340**: p. c2518.
16. Gillison, M.L. and K.V. Shah, *Human papillomavirus-associated head and neck squamous cell carcinoma: mounting evidence for an etiologic role for human papillomavirus in a subset of head and neck cancers*. Curr Opin Oncol, 2001. **13**(3): p. 183-8.
17. Alani, R.M. and K. Munger, *Human papillomaviruses and associated malignancies*. J Clin Oncol, 1998. **16**(1): p. 330-7.
18. D'Souza, G., et al., *Case-control study of human papillomavirus and oropharyngeal cancer*. N Engl J Med, 2007. **356**(19): p. 1944-56.
19. Smith, E.M., et al., *Age, sexual behavior and human papillomavirus infection in oral cavity and oropharyngeal cancers*. Int J Cancer, 2004. **108**(5): p. 766-72.

20. Snijders, P.J., et al., *Prevalence and expression of human papillomavirus in tonsillar carcinomas, indicating a possible viral etiology*. Int J Cancer, 1992. **51**(6): p. 845-50.
21. Hong, A.M., et al., *Human papillomavirus predicts outcome in oropharyngeal cancer in patients treated primarily with surgery or radiation therapy*. Br J Cancer, 2010. **103**(10): p. 1510-7.
22. Fakhry, C., et al., *Improved survival of patients with human papillomavirus-positive head and neck squamous cell carcinoma in a prospective clinical trial*. J Natl Cancer Inst, 2008. **100**(4): p. 261-9.
23. Gupta, P.C., et al., *Smokeless tobacco: a major public health problem in the SEA region: a review*. Indian J Public Health, 2011. **55**(3): p. 199-209.
24. Chaturvedi, A.K., et al., *Incidence trends for human papillomavirus-related and -unrelated oral squamous cell carcinomas in the United States*. J Clin Oncol, 2008. **26**(4): p. 612-9.
25. Syrjanen, S., *HPV infections and tonsillar carcinoma*. J Clin Pathol, 2004. **57**(5): p. 449-55.
26. Blomberg, M., et al., *Trends in head and neck cancer incidence in Denmark, 1978-2007: focus on human papillomavirus associated sites*. Int J Cancer, 2011. **129**(3): p. 733-41.
27. Mork, J., et al., *Time trends in pharyngeal cancer incidence in Norway 1981-2005: a subsite analysis based on a reabstraction and recoding of registered cases*. Cancer Causes Control, 2010. **21**(9): p. 1397-405.
28. Bernier, J. and J.C. Horiot, *Altered-fractionated radiotherapy in locally advanced head and neck cancer*. Curr Opin Oncol, 2011.
29. Bourhis, J., et al., *Hyperfractionated or accelerated radiotherapy in head and neck cancer: a meta-analysis*. Lancet, 2006. **368**(9538): p. 843-54.
30. Zackrisson, B., et al., *Two-year results from a Swedish study on conventional versus accelerated radiotherapy in head and neck squamous cell carcinoma - The ARTSCAN study*. Radiother Oncol, 2011.
31. Mazon, J.J., et al., *GEC-ESTRO recommendations for brachytherapy for head and neck squamous cell carcinomas*. Radiother Oncol, 2009. **91**(2): p. 150-6.
32. Rampino, M., et al., *Efficacy and feasibility of induction chemotherapy and radiotherapy plus cetuximab in head and neck cancer*. Anticancer Res. **32**(1): p. 195-9.
33. Sinha, P., et al., *Extracapsular spread and adjuvant therapy in human papillomavirus-related, p16-positive oropharyngeal carcinoma*. Cancer, 2011.
34. Rawls, W.E., et al., *Herpesvirus type 2: association with carcinoma of the cervix*. Science, 1968. **161**(847): p. 1255-6.
35. Nahmias, A.J., et al., *Genital infection with type 2 Herpes virus hominis. A commonly occurring venereal disease*. Br J Vener Dis, 1969. **45**(4): p. 294-8.
36. Naib, Z.M., et al., *Genital herpetic infection. Association with cervical dysplasia and carcinoma*. Cancer, 1969. **23**(4): p. 940-5.
37. Vonka, V., et al., *Prospective study on the relationship between cervical neoplasia and herpes simplex type-2 virus. I. Epidemiological characteristics*. Int J Cancer, 1984. **33**(1): p. 49-60.
38. Vonka, V., et al., *Prospective study on the relationship between cervical neoplasia and herpes simplex type-2 virus. II. Herpes simplex type-2 antibody presence in sera taken at enrollment*. Int J Cancer, 1984. **33**(1): p. 61-6.
39. Strauss, M.J., E.W. Shaw, and et al., *Crystalline virus-like particles from skin papillomas characterized by intranuclear inclusion bodies*. Proc Soc Exp Biol Med, 1949. **72**(1): p. 46-50.

40. Bernard, H.U., et al., *Classification of papillomaviruses (PVs) based on 189 PV types and proposal of taxonomic amendments*. Virology, 2010. **401**(1): p. 70-9.
41. zur Hausen, H., *Papillomaviruses in the causation of human cancers - a brief historical account*. Virology, 2009. **384**(2): p. 260-5.
42. Syrjanen, K.J., et al., *Immunohistochemical demonstration of human papilloma virus (HPV) antigens in oral squamous cell lesions*. Br J Oral Surg, 1983. **21**(2): p. 147-53.
43. Gillison, M.L., et al., *Distinct risk factor profiles for human papillomavirus type 16-positive and human papillomavirus type 16-negative head and neck cancers*. J Natl Cancer Inst, 2008. **100**(6): p. 407-20.
44. Weinberger, P.M., et al., *Molecular classification identifies a subset of human papillomavirus--associated oropharyngeal cancers with favorable prognosis*. J Clin Oncol, 2006. **24**(5): p. 736-47.
45. Psyrri, A. and D. DiMaio, *Human papillomavirus in cervical and head-and-neck cancer*. Nat Clin Pract Oncol, 2008. **5**(1): p. 24-31.
46. zur Hausen, H., *Papillomaviruses causing cancer: evasion from host-cell control in early events in carcinogenesis*. J Natl Cancer Inst, 2000. **92**(9): p. 690-8.
47. Pett, M. and N. Coleman, *Integration of high-risk human papillomavirus: a key event in cervical carcinogenesis?* J Pathol, 2007. **212**(4): p. 356-67.
48. Mellin, H., et al., *Human papillomavirus type 16 is episomal and a high viral load may be correlated to better prognosis in tonsillar cancer*. Int J Cancer, 2002. **102**(2): p. 152-8.
49. Kim, S.H., et al., *HPV integration begins in the tonsillar crypt and leads to the alteration of p16, EGFR and c-myc during tumor formation*. Int J Cancer, 2007. **120**(7): p. 1418-25.
50. Koskinen, W.J., et al., *Prevalence and physical status of human papillomavirus in squamous cell carcinomas of the head and neck*. Int J Cancer, 2003. **107**(3): p. 401-6.
51. Deng, W., et al., *Cyclin/CDK regulates the nucleocytoplasmic localization of the human papillomavirus E1 DNA helicase*. J Virol, 2004. **78**(24): p. 13954-65.
52. Wiest, T., et al., *Involvement of intact HPV16 E6/E7 gene expression in head and neck cancers with unaltered p53 status and perturbed pRb cell cycle control*. Oncogene, 2002. **21**(10): p. 1510-7.
53. Chung, C.H. and M.L. Gillison, *Human papillomavirus in head and neck cancer: its role in pathogenesis and clinical implications*. Clin Cancer Res, 2009. **15**(22): p. 6758-62.
54. Nevins, J.R., *The Rb/E2F pathway and cancer*. Hum Mol Genet, 2001. **10**(7): p. 699-703.
55. Klussmann, J.P., et al., *Expression of p16 protein identifies a distinct entity of tonsillar carcinomas associated with human papillomavirus*. Am J Pathol, 2003. **162**(3): p. 747-53.
56. Mellin Dahlstrand, H., et al., *P16(INK4a) correlates to human papillomavirus presence, response to radiotherapy and clinical outcome in tonsillar carcinoma*. Anticancer Res, 2005. **25**(6C): p. 4375-83.
57. Ahomadegbe, J.C., et al., *High incidence of p53 alterations (mutation, deletion, overexpression) in head and neck primary tumors and metastases; absence of correlation with clinical outcome. Frequent protein overexpression in normal epithelium and in early non-invasive lesions*. Oncogene, 1995. **10**(6): p. 1217-27.

58. Carlos de Vicente, J., et al., *Prognostic significance of p53 expression in oral squamous cell carcinoma without neck node metastases*. Head Neck, 2004. **26**(1): p. 22-30.
59. Westra, W.H., et al., *Inverse relationship between human papillomavirus-16 infection and disruptive p53 gene mutations in squamous cell carcinoma of the head and neck*. Clin Cancer Res, 2008. **14**(2): p. 366-9.
60. Herrero, R., et al., *Human papillomavirus and oral cancer: the International Agency for Research on Cancer multicenter study*. J Natl Cancer Inst, 2003. **95**(23): p. 1772-83.
61. Munoz, N., et al., *Epidemiologic classification of human papillomavirus types associated with cervical cancer*. N Engl J Med, 2003. **348**(6): p. 518-27.
62. Lassen, P., *The role of Human papillomavirus in head and neck cancer and the impact on radiotherapy outcome*. Radiother Oncol, 2010. **95**(3): p. 371-80.
63. Lassen, P., et al., *HPV-associated p16-expression and response to hypoxic modification of radiotherapy in head and neck cancer*. Radiother Oncol, 2010. **94**(1): p. 30-5.
64. Goldenberg, D., et al., *Cystic lymph node metastasis in patients with head and neck cancer: An HPV-associated phenomenon*. Head Neck, 2008. **30**(7): p. 898-903.
65. Begum, S. and W.H. Westra, *Basaloid squamous cell carcinoma of the head and neck is a mixed variant that can be further resolved by HPV status*. Am J Surg Pathol, 2008. **32**(7): p. 1044-50.
66. Gillison, M.L., *Human papillomavirus-associated head and neck cancer is a distinct epidemiologic, clinical, and molecular entity*. Semin Oncol, 2004. **31**(6): p. 744-54.
67. Mellin, H., et al., *Human papillomavirus (HPV) DNA in tonsillar cancer: clinical correlates, risk of relapse, and survival*. Int J Cancer, 2000. **89**(3): p. 300-4.
68. Heck, J.E., et al., *Sexual behaviours and the risk of head and neck cancers: a pooled analysis in the International Head and Neck Cancer Epidemiology (INHANCE) consortium*. Int J Epidemiol, 2009. **39**(1): p. 166-81.
69. Einstein, M.H., et al., *Comparative immunogenicity and safety of human papillomavirus (HPV)-16/18 vaccine and HPV-6/11/16/18 vaccine: Follow-up from Months 12-24 in a Phase III randomized study of healthy women aged 18-45 years*. Hum Vaccin, 2011. **7**(12): p. 166-81.
70. Wu, A., et al., *Innovative DNA vaccine for human papillomavirus (HPV)-associated head and neck cancer*. Gene Ther, 2011. **18**(3): p. 304-12.
71. Tseng, C.W., et al., *Low-dose radiation enhances therapeutic HPV DNA vaccination in tumor-bearing hosts*. Cancer Immunol Immunother, 2009. **58**(5): p. 737-48.
72. Mattsson, B. and A. Wallgren, *Completeness of the Swedish Cancer Register. Non-notified cancer cases recorded on death certificates in 1978*. Acta Radiol Oncol, 1984. **23**(5): p. 305-13.
73. Barlow, L., et al., *The completeness of the Swedish Cancer Register: a sample survey for year 1998*. Acta Oncol, 2009. **48**(1): p. 27-33.
74. Chaturvedi, A.K., et al., *Human papillomavirus and rising oropharyngeal cancer incidence in the United States*. J Clin Oncol, 2011. **29**(32): p. 4294-301.
75. Fakhry, C. and M.L. Gillison, *Clinical implications of human papillomavirus in head and neck cancers*. J Clin Oncol, 2006. **24**(17): p. 2606-11.
76. Ang, K.K., et al., *Human papillomavirus and survival of patients with oropharyngeal cancer*. N Engl J Med, 2010. **363**(1): p. 24-35.

77. Smeets, S.J., et al., *A novel algorithm for reliable detection of human papillomavirus in paraffin embedded head and neck cancer specimen*. Int J Cancer, 2007. **121**(11): p. 2465-72.
78. Shi, W., et al., *Comparative prognostic value of HPV16 E6 mRNA compared with in situ hybridization for human oropharyngeal squamous carcinoma*. J Clin Oncol, 2009. **27**(36): p. 6213-21.
79. Weinberger, P.M., et al., *Prognostic significance of p16 protein levels in oropharyngeal squamous cell cancer*. Clin Cancer Res, 2004. **10**(17): p. 5684-91.
80. El-Naggar, A.K. and W.H. Westra, *p16 expression as a surrogate marker for HPV-related oropharyngeal carcinoma: A guide for interpretative relevance and consistency*. Head Neck, 2011.
81. Bertelsen, B.I., et al., *HPV subtypes in cervical cancer biopsies between 1930 and 2004: detection using general primer pair PCR and sequencing*. Virchows Arch, 2006. **449**(2): p. 141-7.
82. Kreimer, A.R., et al., *Human papillomavirus types in head and neck squamous cell carcinomas worldwide: a systematic review*. Cancer Epidemiol Biomarkers Prev, 2005. **14**(2): p. 467-75.
83. Hafkamp, H.C., et al., *Marked differences in survival rate between smokers and nonsmokers with HPV 16-associated tonsillar carcinomas*. Int J Cancer, 2008. **122**(12): p. 2656-64.
84. Licitra, L., et al., *High-risk human papillomavirus affects prognosis in patients with surgically treated oropharyngeal squamous cell carcinoma*. J Clin Oncol, 2006. **24**(36): p. 5630-6.
85. Lassen, P., et al., *Effect of HPV-associated p16INK4A expression on response to radiotherapy and survival in squamous cell carcinoma of the head and neck*. J Clin Oncol, 2009. **27**(12): p. 1992-8.
86. Dai, M., et al., *Human papillomavirus type 16 and TP53 mutation in oral cancer: matched analysis of the IARC multicenter study*. Cancer Res, 2004. **64**(2): p. 468-71.
87. Spanos, W.C., et al., *Immune response during therapy with cisplatin or radiation for human papillomavirus-related head and neck cancer*. Arch Otolaryngol Head Neck Surg, 2009. **135**(11): p. 1137-46.
88. Gersch, E.D., L. Gissmann, and R.L. Garcea, *New approaches to prophylactic human papillomavirus vaccines for cervical cancer prevention*. Antivir Ther, 2012.
89. Bonner, J.A., et al., *Radiotherapy plus cetuximab for squamous-cell carcinoma of the head and neck*. N Engl J Med, 2006. **354**(6): p. 567-78.
90. Olthof, N.C., et al., *Next-generation treatment strategies for human papillomavirus-related head and neck squamous cell carcinoma: where do we go?* Rev Med Virol. **22**(2): p. 88-105.
91. Snoeck, R., et al., *Cidofovir, a new approach for the treatment of cervix intraepithelial neoplasia grade III (CIN III)*. J Med Virol, 2000. **60**(2): p. 205-9.
92. Trotti, A., et al., *Mucositis incidence, severity and associated outcomes in patients with head and neck cancer receiving radiotherapy with or without chemotherapy: a systematic literature review*. Radiother Oncol, 2003. **66**(3): p. 253-62.