

Department of Women's and Children's Health
Karolinska Institutet, Stockholm, Sweden

ETIOLOGICAL AND CLINICAL STUDIES OF LANGERHANS CELL HISTIOCYTOSIS (LCH)

SELMA OLSSON ÅKEFELDT



**Karolinska
Institutet**

Stockholm 2013

Front cover photo: Immunofluorescence staining of BCL2A1 (red) and CD1a (green) of a multinucleated giant cell and mononuclear cells in a bone lesion from a patient with LCH. Photo by Mohamad Bachar Ismail, Laboratoire CNRS UMR5239, Lyon.

All previously published papers were reproduced with permission from the publisher.

Published by Karolinska Institutet. Printed by Reproprint AB.

© Selma Olsson Åkefeldt, 2013
ISBN 978-91-7549-319-0

ABSTRACT

Langerhans cell histiocytosis (LCH) is a rare disease of unknown origin. LCH may occur at any age but affects mainly children and the most severe forms of the disease are seen in the youngest children. In LCH, granulomatous lesions are formed in various organs. These lesions always contain CD1a⁺ dendritic cells (LCH DCs), and multinucleated giant cells (MGCs) of unknown origin are also commonly seen in the lesions. The course of LCH is extremely variable ranging from self-healing, solitary lesions in the bone or the skin, to recurrent multiple lesions or progressive disseminated forms of the disease. Recently, a mutation in *BRAF*, a pivotal kinase in the RAS-RAF-MAPK signaling pathway, important for cell survival and proliferation, was identified in LCH DCs. Still it is, however, not known whether the disease has a neoplastic origin or whether it is triggered by inflammatory stimuli allowing for secondary pro-survival mutations to take place.

In terms of survival, the prognosis is usually good except for children with severe disseminated forms of the disease, but long term permanent consequences of LCH are common. One severe complication is a slowly developing neurodegeneration, linked to CNS inflammation, which may develop in around 10-25% of the children. In spite of improved therapies for LCH in general, the cause of the neurodegenerative process and how it can be halted is still unknown. Once MRI changes are evident, substantial neuronal loss has already occurred. Therefore, it would be valuable to detect signs of ongoing neurodegeneration earlier than with MRI. This would also provide an opportunity to more promptly evaluate treatment interventions.

In **paper I** in this thesis we evaluated the presence of three well-known biomarkers in the cerebrospinal fluid (CSF) of children with radiologically manifest neurodegeneration; NF-L, TAU and GFAP. The results indicate that patients with neurodegenerative LCH have elevated levels of at least one CSF biomarker and that NF-L, TAU and GFAP analyzed together may be useful to detect *ongoing* neurodegeneration in LCH. NF-L might be of special interest as a marker of progressive neurodegeneration. However, further studies are needed to evaluate this.

Previous register studies have indicated an overrepresentation of LCH among Swedish children born after *in vitro* fertilization (IVF) 1982-2005. By confirming the diagnoses and characterizing the disease in these children, in **paper II** we verified a, possibly temporary, overrepresentation of LCH in children born after IVF, which was not due to over-diagnosis of mild forms of the disease. The reasons for this finding, that might provide a clue to the origin of LCH, are however, still unknown. The possible correlation between IVF and LCH should also be confirmed in independent studies from other countries.

IL-17A is a pro-inflammatory cytokine involved in the pathogenesis of many chronic inflammatory disorders. In **papers III, IV and V** we investigated how IL-17A affects monocyte-derived immature dendritic cells (mo-DCs) and a possible role for IL-17A in LCH. We found that IL-17A modifies mo-DCs to cells with a mixed macrophage-DC phenotype, spontaneously resistant to apoptosis, associated with up-regulation of the pro-survival protein BCL2A1. IL-17A-treated DCs were prone to undergo cell fusion to form MGCs and expressed a variety of pro-inflammatory molecules, in many ways resembling LCH DCs. We also found that IL-17A was present in LCH lesions and that mo-DCs from LCH patients secreted IL-17A, in contrast to cells from healthy donors. Moreover, Mo-DCs from LCH patients also expressed BCL2A1 and underwent cell fusion spontaneously, a process that was dependent on IL-17A.

The significance of IL-17A in the pathogenesis of LCH is under debate. Yet, our findings indicate a role for this cytokine in LCH where IL-17A might contribute to the pro-inflammatory, tissue degrading environment, characteristic for LCH lesions, and an inefficient immune response resulting in the failure of the body to clear the LCH lesions. Moreover, IL-17A may contribute to an increased viability of LCH DCs allowing for formation of MGCs and pro-survival mutations to take place.

LIST OF PUBLICATIONS

- I. Gavhed D, **Åkefeldt SO**, Österlundh G, Laurencikas E, Hjorth L, Blennow K, Rosengren L, Henter JI. *Pediatr Blood Cancer* 2009; 53(7): 1264-1270.
- II. **Åkefeldt SO**, Finnström O, Gavhed D, Henter JI. Langerhans cell histiocytosis in children born 1982-2005 after *in vitro* fertilization. *Acta Paediatr* 2012; 101(11): 1151-1155.
- III. Coury F, Annels N, Rivollier A, **Olsson S**, Santoro A, Speziani C, Azocar O, Flacher M, Djebali S, Tebib J, Brytting M, Egeler RM, Rabourdin-Combe C, Henter JI, Arico M, Delprat C. Langerhans cell histiocytosis reveals a new IL-17A-dependent pathway of dendritic cell fusion. *Nat Med* 2008; 14(1): 81-87.
- IV. **Åkefeldt SO***, Maisse C*, Belot A, Mazzorana M, Salvatore G, Bissay N, Jurdic P, Aricò M, Rabourdin-Combe C, Henter JI, Delprat C. Chemoresistance of human monocyte-derived dendritic cells is regulated by IL-17A. *PLoS One* 2013; 8(2): e56865.
- V. **Åkefeldt SO**, Ismail MB, Belot A, Maisse C, Salvatore G, Bissay N, Aricò M, Henter JI, Delprat C. IL-17A induced BCL2A1/BFL1 mediates survival of monocyte derived dendritic cells from patients with Langerhans cell histiocytosis. *Manuscript*.

*Both authors contributed equally

TABLE OF CONTENTS

| | | |
|--------|---|----|
| 1 | INTRODUCTION | 1 |
| 1.1 | The immune system – a short overview | 1 |
| 1.1.1 | Innate versus adaptive immunity | 1 |
| 1.1.2 | Lymphocytes | 2 |
| 1.1.3 | Monocytes | 3 |
| 1.1.4 | Macrophages | 3 |
| 1.1.5 | Dendritic cells (DCs) | 3 |
| 1.1.6 | Langerhans cells (LCs) | 5 |
| 1.1.7 | Giant cells | 6 |
| 1.1.8 | Tumor-associated macrophages (TAMs) | 7 |
| 1.1.9 | Myeloid-derived suppressor cells (MDSCs) and tumoral DCs | 8 |
| 1.1.10 | Histiocytes | 8 |
| 1.1.11 | Granulomas | 9 |
| 1.2 | Dendritic cell homeostasis | 9 |
| 1.3 | IL-17A | 12 |
| 1.3.1 | Molecular characteristics | 12 |
| 1.3.2 | Receptor signaling | 12 |
| 1.3.3 | Sources of IL-17A | 13 |
| 1.3.4 | IL-17A in host defense | 13 |
| 1.3.5 | IL-17A in chronic inflammatory and autoimmune diseases | 14 |
| 1.3.6 | IL-17A in malignancies | 15 |
| 1.3.7 | IL-17A mediated cell survival | 17 |
| 1.4 | Historical background of LCH | 18 |
| 1.5 | Incidence and epidemiology of LCH | 19 |
| 1.5.1 | Incidence | 19 |
| 1.5.2 | Associated factors | 20 |
| 1.6 | Clinical presentation | 23 |
| 1.6.1 | Prognosis and sequelae | 24 |
| 1.6.2 | Characteristics of specific organ involvement in LCH | 25 |
| 1.6.3 | Central nervous system (CNS) involvement | 27 |
| 1.6.4 | LCH in adults | 33 |
| 1.7 | Diagnosis | 34 |
| 1.7.1 | Histopathology | 34 |
| 1.7.2 | Diagnostic evaluation | 35 |
| 1.8 | Treatment | 37 |
| 1.8.1 | Previous international treatment studies | 37 |
| 1.8.2 | LCH-IV | 38 |
| 1.8.3 | Alternative treatments | 39 |
| 1.8.4 | Treatment for adults | 39 |
| 1.9 | Pathogenesis of LCH | 40 |
| 1.9.1 | Characteristics of LCH DCs | 40 |
| 1.9.2 | Origin of LCH DCs | 41 |

| | | | |
|---|--------|--|----|
| | 1.9.3 | Characteristics of the LCH lesion | 43 |
| | 1.9.4 | Theories on the etiology of LCH | 44 |
| 2 | | AIMS OF THE THESIS | 51 |
| 3 | | PATIENTS, MATERIAL AND METHODS | 52 |
| | 3.1 | Patients | 52 |
| | 3.2 | Material and methods | 57 |
| | 3.2.1 | CSF sampling and MRI evaluation..... | 57 |
| | 3.2.2 | Blood samples and synovial fluid | 57 |
| | 3.2.3 | Tissue samples..... | 58 |
| | 3.2.4 | Cell cultures | 58 |
| | 3.2.5 | DC survival and fusion efficiency studied after TRAP and Hoechst staining | 59 |
| | 3.2.6 | Flow cytometry analyses (FACS)..... | 59 |
| | 3.2.7 | Methods to detect soluble molecules in serum and supernatants | 61 |
| | 3.2.8 | IL-17A/anti-IL-17A IgG autoimmune complex titration of serum | 62 |
| | 3.2.9 | Immunohistochemical techniques..... | 62 |
| | 3.2.10 | Affymetrix genechip study, microarray analysis | 64 |
| | 3.2.11 | Real-time quantitative PCR | 64 |
| | 3.2.12 | Western blot analysis | 65 |
| | 3.2.13 | Statistical analyses..... | 65 |
| | 3.2.14 | Chemotherapeutic compounds..... | 66 |
| 4 | | RESULTS AND DISCUSSION | 67 |
| | 4.1 | Biomarkers to detect ongoing neurodegeneration in LCH..... | 67 |
| | 4.2 | LCH in children conceived by IVF..... | 71 |
| | 4.3 | A possible role for IL-17A in LCH..... | 76 |
| | 4.3.1 | Initial findings of IL-17A in LCH (paper III)..... | 76 |
| | 4.3.2 | Effects of IL-17A on immature monocyte-derived DCs from healthy donors..... | 78 |
| | 4.3.3 | IL-17A increases viability of mo-DCs from healthy donors..... | 79 |
| | 4.3.4 | Increased survival of monocyte derived DCs from LCH patients is linked to up-regulation of BCL2A1 | 82 |
| | 4.3.5 | Is there really any IL-17A in LCH? | 83 |
| 5 | | CONCLUSIONS | 87 |
| 6 | | GENERAL REMARKS AND FUTURE PERSPECTIVES..... | 88 |
| 7 | | SVENSK SAMMANFATTNING..... | 89 |
| 8 | | ACKNOWLEDGMENTS | 91 |
| 9 | | REFERENCES | 94 |

LIST OF ABBREVIATIONS

| | |
|--------|---|
| ALL | Acute lymphoblastic leukemia |
| AML | Acute myeloid leukemia |
| APC | Antigen presenting cell |
| ARA-C | Cytosine arabinoside, cytarabine |
| BCL2 | B-cell lymphoma 2 |
| BCL2A1 | BCL2-related protein A1, BFL1 |
| CCL | Chemokine (C-C motif) ligand |
| CCR | Chemokine (C-C motif) receptor |
| CD | Cluster of differentiation |
| 2-CdA | 2-chlorodeoxyadenosine, cladribine |
| CSF | Cerebrospinal fluid |
| CTL | Cytotoxic T lymphocyte |
| CXCL | Chemokine (C-X-C motif) ligand |
| CXCR | Chemokine (C-X-C motif) receptor |
| DC | Dendritic cell |
| DI | Diabetes insipidus |
| EBV | Epstein-Barr virus |
| FLT3L | Fms-like tyrosine kinase receptor-3 ligand |
| GFAP | Glial acidic fibrillary protein |
| GM-CSF | Granulocyte-macrophage colony-stimulating factor |
| HCMV | Human cytomegalovirus |
| HLA | Human Leukocyte Antigen |
| HVS | Herpesvirus Saimiri |
| IBD | Inflammatory bowel disease |
| ICD | International Classification of Diseases |
| IVF | <i>In vitro</i> fertilization |
| IVIG | Intravenous Immunoglobulin |
| IFN | Interferon |
| IL | Interleukin |
| LC | Langerhans cell |
| LCH-IV | The international treatment study protocol for LCH started 2013 |
| LCH | Langerhans cell histiocytosis |
| LCH DC | Pathological dendritic cell in LCH |
| LPS | Lipopolysaccharide |
| MCL1 | Myeloid cell leukemia sequence 1 |
| MDSC | Myeloid derived suppressor cell |
| MHC | Major histocompatibility complex |
| M-CSF | Macrophage colony-stimulating factor |
| MGC | Multinucleated giant cell |
| MMP | Matrix metalloproteinase |
| Mo-DC | Monocyte-derived dendritic cell |

| | |
|----------------|--|
| MRI | Magnetic Resonance Imaging |
| MS LCH | Multisystem LCH |
| NF-L | Neurofilament protein light chain |
| NF- κ B | Nuclear factor kappa B |
| NK | Natural killer |
| PDN | Prednisolone |
| PET | Positron emission tomography |
| RA | Rheumatoid arthritis |
| RANKL | Receptor activator of nuclear factor κ B ligand |
| RO | Risk organ |
| SS LCH | Single system LCH |
| TAM | Tumor-associated macrophage |
| TAU | Total TAU protein |
| TCR | T cell receptor |
| TGF | Transforming growth factor |
| Th | Helper T cell |
| TLR | Toll-like receptor |
| TNF | Tumor necrosis factor |
| TRAIL | TNF-related apoptosis-inducing ligand |
| Treg | Regulatory T cell |
| VBL | Vinblastine |
| VEGF | Vascular endothelial growth factor |

FOREWORD

This thesis embraces studies of different aspects of Langerhans cell histiocytosis (LCH). The last three papers focus on a potential role for an inflammatory cytokine, interleukin IL-17A (IL-17A), in LCH, while the first two papers of the thesis deal with neurodegeneration in LCH and a possible correlation between *in vitro* fertilization (IVF) and LCH, respectively.

To readers outside the immunologic or histiocytosis research fields, the first part of the introduction aims to provide a general background of human immunology, of factors important for dendritic cell homeostasis and of IL-17A. This part is followed by an introduction to LCH and questions that are currently debated regarding the origin of the disease. Next, there is a presentation and a discussion of the results of the research underlying this thesis with concluding remarks and speculation on future perspectives. The final section includes the five papers comprising the thesis.

Stockholm, October 2013

Selma Olsson Åkefeldt

1 INTRODUCTION

1.1 THE IMMUNE SYSTEM – A SHORT OVERVIEW

1.1.1 Innate versus adaptive immunity

The immune system is traditionally divided into two parts; innate immunity and adaptive immunity. Innate immunity is responsible for the initial immune response to foreign invaders. The first hinder to overcome is provided by physical barriers, such as the skin and the mucosa, in combination with antimicrobial peptides (defensins) and other antimicrobial agents secreted from the epithelium (Gallo and Hooper, 2012). Cells of the innate immune response include monocytes, macrophages, mast cells, granulocytes (neutrophils, eosinophils and basophils), natural killer (NK) cells and dendritic cells (DCs). The innate immune system recognizes and reacts to molecular motifs that have been conserved throughout evolution, known as pathogen-associated molecular patterns (PAMPs), in contrast to the disease specific antigens recognized by the adaptive immune response. Lipopolysaccharide (LPS), from gram-negative bacteria, unmethylated repeats of the CpG dinucleotides present in bacterial DNA, or double stranded RNA in viruses are examples of ubiquitous microbial molecules recognized through pattern-recognition receptors (PRRs) including toll like receptors (TLRs) (Heine and Lien, 2003, Janeway and Medzhitov, 2002). Macrophages, neutrophils and dendritic cells engulf (phagocyte) invading pathogens and in response to the stimuli mentioned above they secrete biologically active molecules known as chemokines and cytokines with a capacity to attract (chemokines) and stimulate (cytokines) other cells of the immune system, such as T or B lymphocytes (T or B cells).

T and B cells are central for the adaptive immune response. These cells are characterized by an extreme variety of receptors, generated by a process called somatic recombination, recognizing specific antigens. While B cells mature in the bone marrow T cells mature in the thymus where they undergo a rigorous selection process in which self-reactive T cells are usually sorted out. DCs are in firm control over this process, which is important for “tolerance towards self”. Upon the encounter of a ”non-self” molecule DCs initiate cross-talk between the innate and the adaptive immune responses by migrating to a lymph node (or other secondary lymphoid organs) where T and B cells are activated, leading to a clonal expansion of lymphocytes and the establishment of specific immunological memory. Thus, the adaptive immune response is slower but highly specific and effective upon the re-encounter of a specific antigen (Delves and Roitt, 2000b, Delves and Roitt, 2000a)

1.1.2 Lymphocytes

T cells mediate cell-mediated immunity whereas B cells support humoral immunity, characterized by the formation of antibodies that bind to pathogens mediating their destruction by macrophages or the complement system. Cell-mediated immunity is important in fighting intracellular infections caused by viruses or intracellular bacteria but also in the control of cancer cells.

B and T lymphocytes are original in their highly variable expression of specific antigen receptors called BCR (for B cell receptor) and TCR (for T cell receptor), respectively. Circulating lymphocytes are naïve as long as their specific antigen receptors have not been engaged and they need an additional co-stimulatory signal to enter the cell cycle. Thus, two signals are required to activate naïve lymphocytes and to make them divide. Following antigen presentation by DCs to T cells, co-stimulation of TCR and CD28 leads to a double progeny of effector and memory T lymphocytes. In the CD4⁺ (or “helper T cell”) sub-population, the activated T lymphocytes express CD154 (or CD40-ligand), aiding B cell activation. Following the binding of (soluble native) antigen on the BCR and CD40 co-stimulation, B cells divide and give rise to a double progeny of effector (called plasmocytes) and memory B lymphocytes. In addition the quality and intensity of lymphocyte functions are fine-tuned by cytokines.

The transduction chain of TCR, responsible for intracellular TCR signaling, is called CD3. Thus all T cells express CD3. There are two major T cell subpopulations: the CD4⁺ or helper T cells, able to regulate the functions of other lymphocytes, and the CD8⁺ or cytotoxic T lymphocytes (CTLs), able to kill cells infected with intracellular pathogens. TCRs recognize antigens as short peptides bound to a major histocompatibility complex (MHC) molecule. There are two types of MHC molecules, MHC class I and MHC class II. In humans, MHC molecules are referred to as Human Leukocyte Antigens (HLA) and HLA-DR corresponds to MHC class II. MHC class II molecules are expressed by antigen presenting cells (APCs), including DCs but also macrophages and B cells, which capture and present extracellular antigens to helper T cells. The T cell co-receptor CD4 binds to a conserved site on the MHC class II molecule. In contrast, MHC class I molecules are expressed by almost all nucleated cells in the body and present antigens from intracellular pathogens. CTLs are activated as their TCRs bind antigens presented on MHC I molecules of infected cells. To initiate killing, the binding of their co-receptor CD8 to a specific site on the MHC class I molecule is necessary. (Murphy, 2011).

Before 2005, two subclasses of helper T cells had been described: Th1 and Th2, characterized by their cytokine profiles. Th1 cells stimulate phagocytosis by macrophages and neutrophils either by direct contact with macrophages or by secreting activating cytokines, mainly IFN- γ . They are also important in stimulating CTL responses. Likewise, B cells depend on stimulation from Th2 cells for their differentiation and production of antibodies by cytokines such as IL-4, IL-5 and IL-6.

(Delves and Roitt, 2000b, Delves and Roitt, 2000a). In 2005 a third group of helper T cells, Th17, was discovered majorly secreting IL-17A but also IL-17F, IL-21, IL-22, tumor necrosis factor- α (TNF- α) and IL-26 (Harrington et al., 2005, Park et al., 2005).

Regulatory T cells (Tregs) constitute another subset of T cells that have received much attention in the last decade. Tregs come in many forms but those best characterized are the naturally occurring CD4⁺CD25⁺ Foxp3⁺ natural regulatory T cells (nTreg cells). However there are also types of regulatory T cells (iTreg cells) that are Foxp3^{+/−} and that can be induced in the periphery (Toda and Piccirillo, 2006). Regulatory T cells are potent suppressors of T cell responses and can induce tolerance to antigens by several mechanisms, including secretion of IL-10 and transforming growth factor- β (TGF- β), modifying DC stimulation of T cells.

NK cells belong to the innate immune system. They are capable of killing target cells through secretion of perforin and other cytotoxic substances. Once activated, they also secrete large amounts of cytokines, such as IFN- γ . NK cells are important in tumor surveillance and in killing virus-infected cells but also in terminating an immune response (Moretta et al., 2002, Janka, 2012).

1.1.3 Monocytes

Monocytes are mononuclear cells that circulate the blood, spleen and bone marrow. They do not proliferate under steady state conditions. Upon inflammation they migrate to sites of inflammation where they have the potential to differentiate into macrophages (under the influence of macrophage colony-stimulating factor (M-CSF)) or into DCs (under the influence of granulocyte macrophage colony-stimulating factor (GM-CSF) and IL-4) (Auffray et al., 2009, Geissmann et al., 2010).

1.1.4 Macrophages

Macrophages are resident phagocytic cells in lymphoid and non-lymphoid tissues that are believed to be important in tissue homeostasis by the clearance of apoptotic cells and production of growth factors. Macrophages express a number of pattern-recognition receptors making them efficient in responding to foreign material and initiating an immune response by secreting inflammatory cytokines.

1.1.5 Dendritic cells (DCs)

DCs constitute a heterogeneous group of hematopoietic cells. Immature DCs are equipped with a strong phagocytic capacity. As they process antigens, DCs mature to potent antigen presenting cells, efficient in initiating adaptive immune responses. For naïve T cells to be activated by DCs two signals are required: TCR engagement by an antigen presented by MHC molecules on the surface of the DCs and CD28 binding by

co-stimulatory molecules expressed by DCs such as CD80 and CD86. Co-stimulatory molecules are up-regulated in DCs in response to danger signals downstream of PRR activation. Depending on the type of immune response needed, in addition to activating cell cycling in naïve T cells, DCs can direct T cell differentiation into different kinds of effector T cells through secretion of different cytokines. Furthermore, DCs are also critical in inducing tolerance, to protect us from unwanted immune responses. DCs initiate programmed cell death in self-reactive T cells that bind too hard to self-MHC molecules in the thymus but they can also render T cells in the periphery anergic, as occurs when a T cell recognizes an antigen bound to an MHC molecule in the absence of co-stimulatory molecules.

DCs are distributed throughout the body but are enriched in lymphoid organs and where environmental contact is high. Normally, however, they are quite rare cells, accounting for around 1 % of all cells in lymphoid organs and even lower numbers in non-lymphoid organs and in the blood (Steinman, 1991). As DCs have taken up antigens they move from sites of infection to lymphoid organs to interact with T cells.

DC subsets are characterized by their membrane markers, their localization *in vivo*, their migrating abilities, their cytokine production and their functions (Geissmann et al., 2010, Merad and Manz, 2009). Individual DC populations may share tissue markers with macrophages and may sometimes be difficult to ascribe to one population or another (Geissmann et al., 2010). Classical myeloid DCs are normally separated from plasmacytoid DCs. Plasmacytoid DCs are specialized in secreting type I interferons in response to viral infections and to prime T cells against viral antigens. They have a relatively long half-life (Liu, 2005). In the text below, the focus is on classical myeloid DCs.

In vivo, steady state DC half-life is not really known but studies on mice have indicated that it ranges from days to a few weeks depending on the localization (Kamath et al., 2002, Ruedl et al., 2000). With the exception of Langerhans cells (LCs), microglia and thymic DCs (as demonstrated in mice), DCs generally do not divide, and are thought to be replaced by blood-borne progenitor cells. (Merad and Manz, 2009, Ajami et al., 2007).

Mouse studies have shown that DCs can be obtained from a very early bone-marrow derived progenitor shared with the other cells of the mononuclear phagocyte system, monocytes and macrophages, called the “monocyte-macrophage-DC progenitor” (MDP). Downstream of this progenitor there is a common DC progenitor (CDP) that can give rise to classical myeloid DCs and plasmacytoid DCs but not to monocytes or macrophages, which thus normally develop independently of DCs (Hettinger et al., 2013, Liu et al., 2009). Under steady state conditions, *fms* related tyrosine kinase 3 ligand (FLT3L) has been shown to be the major cytokine of importance for DC differentiation and survival *in vivo* (Merad and Manz, 2009).

Even if monocytes are thought to contribute little to DC development under steady state conditions, in inflammatory conditions monocytes do differentiate into DCs and provide an important source of these cells, as has been shown in mice by Cheong *et al.* and in humans by Segura *et al.* (Cheong *et al.*, 2010, Segura *et al.*, 2013). Accordingly, during inflammation GM-CSF increases in serum (Merad and Manz, 2009).

In vitro, DCs can be generated either by differentiation of CD34⁺ progenitors, highly enriched in cord blood, with GM-CSF and TNF- α (Caux *et al.*, 1992) or by differentiation of monocytes in the presence of GM-CSF and IL-4 (Sallusto and Lanzavecchia, 1994). Similarly to LCs, all DCs generated from monocytes with GM-CSF and IL-4 express CD1a.

1.1.6 Langerhans cells (LCs)

LCs were actually the first dendritic cells to be described, named after Dr Paul Langerhans, who first characterized them as early as 1868 (Langherhans, 1868). LCs are mainly found in the epidermis of the skin where they constitute about 2-8% of the epidermal cells, providing a barrier against foreign invaders. In 1961, following the introduction of electron microscopy and the possibility to study LCs ultrastructurally, the discovery of the intracytoplasmic Birbeck granules was made (Birbeck *et al.*, 1961). Demonstration of Birbeck granules has since then been a method to identify LCs in other tissues than the skin.

However, it was not until the major advances of immunology following the discovery of the MHC molecules and the role of DCs in initiating immune responses (Steinman and Cohn, 1973) at the beginning of the 1970's that the role of LCs began to be revealed. LCs have then successively been shown to be antigen presenting cells constitutively expressing MHC class II and high levels of Langerin/CD 207 and CD1a (Rowden *et al.*, 1977, Silberberg, 1971, Valladeau *et al.*, 2000, Romani *et al.*, 2010).

While Langerin/CD207 is a transmembrane protein that binds microbial glycolipids, which induces the formation of intracellular Birbeck granules, CD1a is an MHC class I homolog that is important for the presentation of foreign glycolipids and lipid antigens to T cells (Porcelli and Modlin, 1999, Valladeau *et al.*, 2003). Langerin/CD207 is internalized by receptor-mediated endocytosis and accumulated in the Birbeck granules where antigens then are loaded onto CD1a and presented to T cells in the lymph nodes. Both CD1a and Langerin/CD207 are often used to identify human LCs. However, in humans, CD1a is also a marker of monocyte-derived DCs and lately it has been shown in mice that Langerin/CD207 is also expressed by CD8⁺ DCs in lymphoid organs and by a population of DCs present in the lung and dermis (Bursch *et al.*, 2007, Ginhoux *et al.*, 2007, Poulin *et al.*, 2007, Idozaga *et al.*, 2009). Thus, neither CD1a nor Langerin/CD207 are exclusive markers for LCs.

In their resting state LCs express adhesion molecules, such as E-cadherin and EpCAM (CD326, TACSTD1), anchoring the cells to neighboring keratinocytes (Tang et al., 1993, Merad et al., 2008). Upon stimulation by an antigen, E-cadherin and CCR6 are down-regulated, while CCR7, the receptor for the chemokines CCL19 and CCL21, is induced. This facilitates detachment from the epithelium and migration towards draining lymph nodes. As LCs leave the epidermis they undergo a maturation process demonstrated by up-regulation of MHC class II molecules and co-stimulatory factors such as CD80, CD86 and CD40 useful for T cell activation (Merad et al., 2008).

In contrast to other DCs, LCs have a remarkably long lifespan with a half-life of 53-78 days in the epidermis (Vishwanath et al., 2006). They also proliferate at a low rate, approximately 2-3% of the LCs are constantly cycling, but it has been shown that this number can increase upon inflammation in response to keratinocyte signaling (Chorro et al., 2009). LCs are also resistant to irradiation as has been shown by the presence of host LCs in transplanted patients up to 18 months post transplantation (Chorro et al., 2009, Merad et al., 2002). Under steady state conditions, and perhaps also inflammatory conditions, self-renewal of differentiated LCs is thus thought to sustain LC homeostasis independently of circulating precursors. This has raised the question of the origin of these cells and quite recently it was suggested that LCs develop from an embryonic precursor that populates the epidermis before birth, proliferating during the first week after birth to establish the LC network (Chorro et al., 2009, Chorro and Geissmann, 2010). However, in settings where LCs are depleted, such as pronounced inflammation, there might still be a role for replacement by bone-marrow derived precursor cells including monocytes (Ginhoux et al., 2006, Merad et al., 2008). This discussion is of importance to LCH research as there is currently a debate concerning the origin of the pathological DCs in Langerhans cell histiocytosis (LCH DCs). Gene expression in LCH DCs has been compared to gene expression in LCs, myeloid and plasmacytoid DCs, implicating that Langerhans cells are not the cells of origin for LCH DCs after all (Allen et al., 2010b, Hutter et al., 2012).

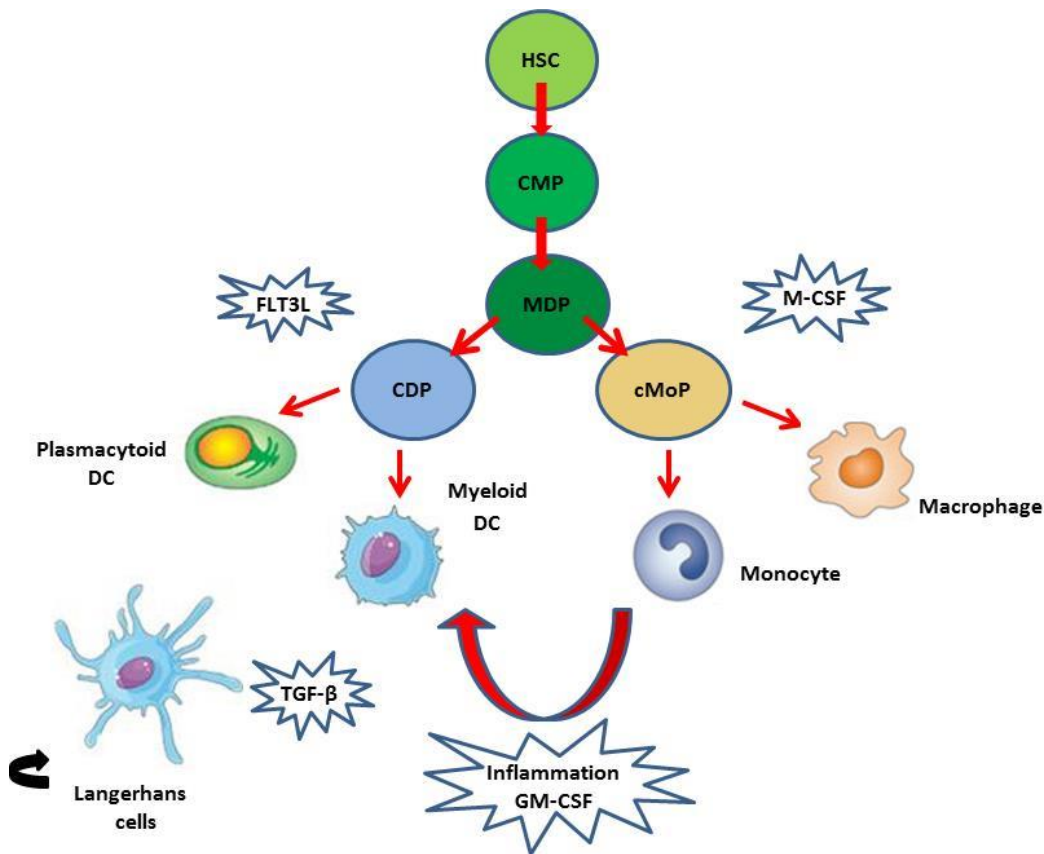
Studies on mice have shown that TGF- β is critical for LC development *in vivo* (Merad and Manz, 2009). Experimentally, LCs can be generated from monocytes by stimulation with IL-4, GM-CSF and TGF- β (Geissmann et al., 1998) and from CD34⁺ hematopoietic progenitors by stimulation with various cytokines including GM-CSF, TNF- α and TGF- β (Jaksits et al., 1999, Caux et al., 1992).

1.1.7 Giant cells

Multinucleated giant cells (MGCs) are seen in various infectious and non-infectious granulomatous disorders, including tuberculosis, schistosomiasis, Crohn's disease, sarcoidosis and LCH. They are thought to arise by the fusion of cells from the myeloid lineage in response to microbial or inflammatory stimuli as has already been demonstrated for another type of MGCs, osteoclasts, which are bone resorbing cells. The latter can be obtained *in vitro* by the fusion of either monocyte or dendritic cells in

the presence of M-CSF and receptor activator of nuclear factor κ B ligand (RANKL) (Fujikawa et al., 1996, Rivollier et al., 2004).

Figure 1. Schematic, simplified picture of the differentiation of DCs in relation to other cells of the mononuclear phagocyte system.



Under steady state DCs differentiate from DC progenitors under the influence of FLT3L. Under inflammatory conditions monocytes differentiate into DCs. GM-CSF is thought to be important for this way of DC differentiation. HSC Hematopoietic stem cell, CMP common myeloid progenitor, MDP monocyte/macrophage, CDP common DC progenitor, cMoP common monocyte progenitor. LC homeostasis is thought to be sustained independently of circulating precursors under steady state and perhaps also under inflammatory conditions.

1.1.8 Tumor-associated macrophages (TAMs)

In recent years there has been growing evidence for a role of so called tumor-associated macrophages (TAMs) in tumor development. As monocytes are attracted to tumor sites the microenvironment surrounding the tumor promotes differentiation of macrophages with different characteristics. Analogous to the classical Th1/Th2 distinction of T cells macrophages can be divided into M1 and M2 subtypes (Mantovani et al., 2002). “Classical”, or M1-type macrophage activation, occurs either in response to microbial

alarm signals or to IFN- γ and is of vital importance in the defense against microbes but also in eliminating tumor cells. M1 macrophages are potent APCs, promote Th1 responses, and generate high amounts of toxic compounds such as nitric oxide (NO) and reactive oxygen species. They are characterized by a high expression of MHC class II, inducible nitric oxide synthase (iNOS), TNF- α , IL-12 and IL-23 as well as a low expression of IL-10 (Sica et al., 2008, Mantovani et al., 2002). This type of macrophages is rarely found at a tumor site except in the early phases of tumor development (Sica et al., 2008). When the tumor is growing, TAMs are usually converted from an M1 to an M2, or “alternative”, phenotype by factors in the microenvironment, such as IL-4 or IL-13 (Sica et al., 2008, Biswas et al., 2013). M2 macrophages are thought to be of importance in the protection against parasites and in tissue remodeling but can also promote tumor growth in several ways. They are characterized by a low expression of IL-12, IL-23 and MHC class II but a high expression of IL-10, TGF- β , macrophage mannose receptor (MMR), arginase-1 (Arg-1) and scavenger receptors. Tumor growth and spread is facilitated by their secretion of matrix metalloproteinases (MMPs) and other tissue degrading enzymes, as well as secretion of proangiogenic and growth promoting substances (e.g. epidermal growth factor (EGF), vascular endothelial growth factor (VEGF) and TGF- β). Inhibition of adaptive anti-tumor responses is also achieved through induction and recruitment of Tregs, inhibition of DC maturation and inhibition of Th1 cell responses (Mantovani et al., 2013, Sica et al., 2008).

1.1.9 Myeloid-derived suppressor cells (MDSCs) and tumoral DCs

Myeloid-derived suppressor cells (MDSCs) constitute a heterogeneous population of immature myeloid progenitor cells including precursors of DCs, macrophages and granulocytes, recruited to tumoral sites that are also thought to be important in suppressing an anti-tumoral immune response (Gabrilovich and Nagaraj, 2009). Although mature DCs are potent initiators of immune responses against tumors, factors secreted by tumor cells or associated cells, such as IL-10 may retain DCs in an immature state (Gabrilovich, 2004). Since the expression of co-stimulatory molecules on immature DCs is low, interaction with T cells supports T cell anergy rather than activation, thus preventing an efficient anti-tumor response. DCs affected by a tumoral microenvironment have also been shown to be able to induce Tregs and to skew immune responses towards a Th2 type of immunity of little value in the fight against tumors (Ghiringhelli et al., 2005, Yang et al., 2010).

1.1.10 Histiocytes

“Histiocyte” is the traditional, historic name to describe a tissue resident cell of the mononuclear phagocytic system lineage, i.e. macrophages and dendritic cells, in contrast to circulating monocytes.

1.1.11 Granulomas

Granulomas are small nodules of inflammatory mononuclear cells accompanied by other infiltrating leukocytes, fibroblasts and MGCs. The mononuclear cells can be more or less organized and are often surrounded by fibrosis. Granulomas associated with tuberculosis often have a necrotic core which is usually not the case in non-infectious granulomas. Granulomas are thought to be a means to wall off foreign substances that are not possible to eliminate but are also associated with a high inflammatory activity and tissue destruction. As for Crohn's disease or sarcoidosis, exactly what triggers granuloma formation in LCH is unknown.

1.2 DENDRITIC CELL HOMEOSTASIS

Since DCs are normally not able to proliferate (LCs and microglia excepted) their homeostasis is dependent on their production from precursor cells and their ability to survive. Tight control of DC homeostasis is important to avoid overstimulation of immune responses, resulting in tissue damage and autoimmunity as has been shown in autoimmune lymphoproliferative syndrome type II (ALPS type II) (Wang et al., 1999b). DC half-life can be prolonged by inflammatory or infectious stimuli (Marsden and Strasser, 2003). Considering that the proliferation rate of LCH DCs is thought to be low (around 2%) (Senechal et al., 2007, Brabencova et al., 1998), an increased viability rather than proliferation of LCH DCs might contribute to the pathological accumulation of LCH DCs typically seen in this disease.

As for other cells, DC life is controlled through apoptosis. Apoptosis, or programmed cell death, is initiated through extrinsic or intrinsic pathways. Extrinsic apoptosis is mediated through death ligands such as CD95/FASL, tumor necrosis factor (TNF) or TNF-related apoptosis-inducing ligand (TRAIL). When these molecules stimulate their receptors (including FAS, TNFR1 and TRAIL-R) a death-inducing signaling complex (DISC) is activated. This activation in turn initiates caspase activation and mitochondria independent apoptosis (Kischkel et al., 1995). Death receptors are specifically important to terminate an immune response. DCs express several of these receptors, CD95/FAS, TNFR and TRAIL-R, and are sensitive to apoptosis mediated through FASL, TNF and TRAIL depending on the dose (Chen et al., 2006, Diehl et al., 2004, Funk et al., 2000). However, formation of the death-inducing signaling complex can be inhibited by a protein called CFLAR (CASP8 and FADD-like apoptosis regulator) formerly named FLIP (FLICE-inhibitory protein). The relative resistance to CD95/FAS-mediated apoptosis seen in myeloid DC is thought to depend on the expression of CFLAR by these cells (Willems et al., 2000).

While immature DCs in general are quite resistant to extrinsic death factors they have been shown to be very sensitive to UVB irradiation, which leads to apoptosis through intrinsic apoptosis (Nicolo et al., 2001). Intrinsic apoptosis in general results from

intracellular stress such as UV irradiation, cytokine withdrawal or cytotoxic drugs and is controlled by the proteins of the B-cell lymphoma 2 (BCL2) family (Marsden and Strasser, 2003). Proteins belonging to the BCL2 family regulate survival and susceptibility to apoptosis by governing mitochondrial outer membrane permeabilization and release of cytochrome c from mitochondria in the intrinsic apoptotic pathway (Frenzel et al., 2009). This family consists of three different groups of proteins, sharing sequence homology in their BCL2 homology (BH) domains. Pro-survival members constitute one group and include BCL2, MCL1, BCLXL, BCLW and BCL2A1. Pro-apoptotic members are divided into two groups, the multidomain proteins, BAX and BAK and the BH3-only proteins BIM, BID, BAD, PUMA and NOXA (Youle and Strasser, 2008). An intrinsic balance between these proteins controls the activation of BAK and BAX. Activated, BAK and BAX form pores in the outer membrane of the mitochondria, which leads to cytochrome c release, activation of caspases and triggering of the death cascade, resulting in apoptosis. Classically, in living cells, BAK and BAX are thought to be sequestered by pro-survival members of the BCL2 family. Activation of the BH3-only proteins by cellular stress leads to direct activation of BAK and BAX or binding and inhibition of the pro-survival members, resulting in apoptosis. However, the exact mechanisms that regulate these events under different conditions are not fully known.

Aberrant expression of pro-survival BCL2 family proteins is common in human cancers as a consequence of carcinogenic mutations, and associated with resistance to therapy. However, up-regulation of pro-survival BCL2 proteins is also seen in response to inflammatory stimuli, as reported for example in inflammatory bowel disease (IBD), where up-regulation of BCL2 and BCLXL downstream of IL-6 is associated with prolonged T cell survival and reinforced inflammation (Mudter and Neurath, 2007).

Compared to lymphocytes, knowledge of DC survival regulation by the BCL2 family is rather scarce. MCL1 has been described to be expressed at steady state in granulocytes, monocytes and dendritic cells (Kelly and Strasser, 2011, Craig, 2002). However, inflammatory stimuli, drastically enhancing survival of DCs, seemingly act on various molecules of the BCL2 family. TLR signaling, for example, has been shown to up-regulate BCL2 and BCLXL, as well as inhibitor of apoptosis (IAP) proteins, in DCs (Park et al., 2002). In addition, Björck *et al.* have demonstrated that DCs up-regulate BCL2 in response to CD40 ligation by T cells (Björck et al., 1997).

Several cytokines prolong the viability of DCs. The role of FLT3L in differentiation and survival of DCs *in vivo* has already been touched upon. GM-CSF has been shown to synergize with FLT3L to stimulate DC survival *in vivo* (Kingston et al., 2009). Withdrawal of GM-CSF from bone-marrow derived DCs resulted in up-regulation of the pro-apoptotic factor BIM and an accelerated cell death. Further, as M-CSF and RANKL stimulate MGC osteoclast formation by fusion of DCs, BCL2 is up-regulated (Rivollier et al., 2004, Yamashita et al., 2008). On the contrary, in one study, IL-10 promoted DC apoptosis in monocyte-derived DCs from humans by inhibiting

expression of the pro-survival molecules BCL2, BCL2A1 and BCLXL (Chang et al., 2007).

Several of these mechanisms may affect the survival of LCH DCs as is further discussed in section 1.9.3 and 1.9.4.

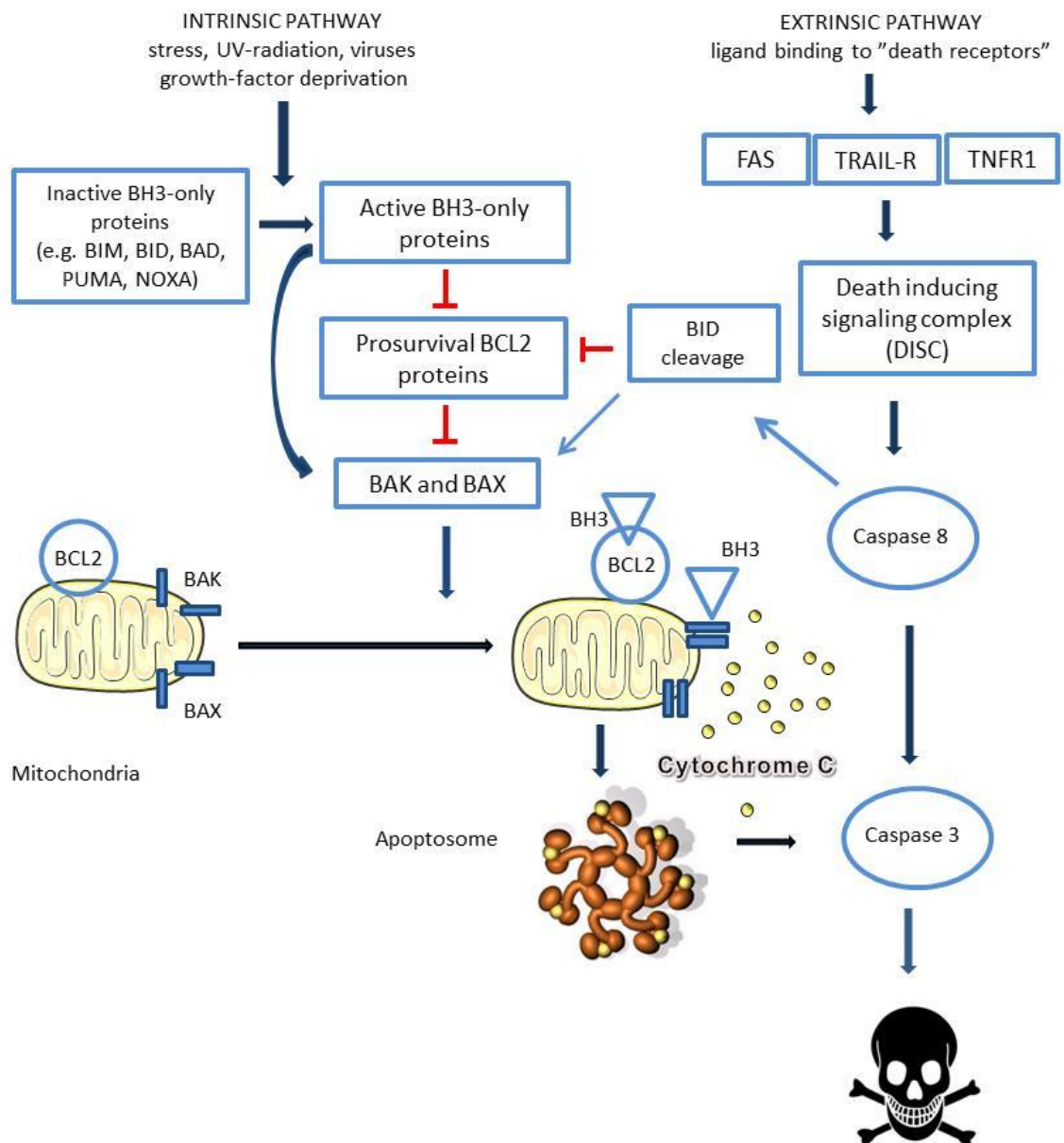


Figure 2. Schematic picture of the intrinsic and extrinsic apoptosis pathways.

1.3 IL-17A

1.3.1 Molecular characteristics

IL-17A was first described in 1993 and was then referred to as cytotoxic T lymphocyte antigen 8 (CTLA8) (Rouvier et al., 1993). It was initially recognized to have a viral homolog encoded within the Herpesvirus Saimiri (HVS), a T lymphotropic virus known to infect primates. Subsequently, several molecules with a homologous domain shared with IL-17A, have been described, constituting the IL-17 family: IL-17A (previously known as IL-17) IL-17B, IL-17C, IL-17D, IL-17E (IL-25) and IL-17F (Iwakura et al., 2011). IL-17A remains the best characterized member of the IL-17 family. The gene for IL-17A is located on chromosome 6p12. IL-17A is to almost 60% homologous to IL-17F and the genes are located nearby in the same chromosomal region. These cytokines share many functions, however, IL-17F is a weaker inducer of inflammatory cytokines than IL-17A. Both IL-17A and IL-17F can be secreted as homodimers but they can also form functional heterodimers called IL-17A/F with an intermediate activity between IL-17A/A “high activity” and IL-17F/F “low activity”. (Chang and Dong, 2007, Wright et al., 2007). The human IL-17A is composed of 155 amino acids and weighs about 17 kDa. Human IL-17F weighs about 18 kDa.

1.3.2 Receptor signaling

Members of the IL-17 family signal through IL-17 receptors (IL-17R). Today five different subunits have been characterized (IL-17RA to IL-17RE). IL-17A/A and IL-17F/F homodimers as well as the IL-17A/F heterodimer signal through a multimeric receptor complex composed of one IL-17RA and two IL-17RC subunits (Kramer et al., 2006, Toy et al., 2006). IL-17RA is ubiquitously expressed, with particularly high levels in immune cells while IL-17RC is preferentially expressed in non-immune cells (Haudenschild et al., 2002, Kuestner et al., 2007). Therefore, it is still not clear how myeloid cells which are IL-17RA⁺/IL-17RC⁻ bind IL-17A. Different expression of IL-17RA and IL-17RC in different cell types may account for tissue specific functions of IL-17A (Zhu and Qian, 2012).

Most genes encoding pro-inflammatory molecules that are up-regulated by IL-17A are induced by the transcription factor NF- κ B (Qian et al., 2007). As IL-17A binds to its receptor the adaptor molecule Act1 is recruited. This in turn leads to recruitment of TRAF6 (an adaptor molecule used also for TLR and TNF signaling), and the kinase TAK1 (transforming growth factor β -activated kinase 1). The Act1/TRAF6/TAK1 complex then activates the transcription factors NF- κ B, C/EBP (CCAT/enhancer-binding proteins) and AP-1. In 2011 it was demonstrated that IL-17RA could also signal through a TRAF6 independent pathway, involving the inducible kinase IKKi (inducible inhibitor of NF- κ B (IkB) kinase), which is recruited to the IL-17R-Act1 complex and mediates Act1 phosphorylation (Iwakura et al., 2011). This pathway is

still not very well characterized. The capacity of IL-17A to up-regulate pro-inflammatory molecules is generally not as strong as that of some other potent pro-inflammatory cytokines, such as TNF α or IL-1 β . However, IL-17A often acts in synergy with other cytokines to up-regulate pro-inflammatory molecules. Several IL-17A target genes are also controlled post transcriptionally by stabilization of mRNA, e.g. CXCL1, CXCL2 and IL-6 (Hartupée et al., 2007, Onishi and Gaffen, 2010).

1.3.3 Sources of IL-17A

Th17 cells, described in 2005, were initially thought to be the exclusive source of IL-17A (Harrington et al., 2005, Park et al., 2005), but later studies have shown that also other cell types can secrete IL-17A, including many cells of the innate immune system in response to innate signals. Such cells include $\gamma\delta$ -T cells NK cells, NKT cells, lymphoid tissue inducer-like cells, neutrophils, macrophages, mast cells and, as presented in **paper III** in this thesis, DCs (Cua and Tato, 2010, Coury et al., 2008). The crucial combination of cytokines to stimulate Th17 differentiation in humans is still debated. Several studies have shown that TGF- β , IL-1 β and IL-6 are important (Manel et al., 2008). Some cytokines also have the capacity to amplify a Th17 response, such as IL-21, IL-23, TNF- α and IL-1 β . Out of these, IL-23 is necessary for the expansion, stabilization and maintenance of the Th17-phenotype and may serve as a survival factor for these cells (McGeachy and Cua, 2008). Th17 cells characteristically express the chemokine receptor CCR6, allowing their migration to sites of inflammation (Hirota et al., 2007). Although other transcription factors may also induce IL-17A, the transcription factor ROR γ t (retinoic acid related orphan receptor gamma t) has been best characterized as a positive regulator of IL-17A (Zhu and Qian, 2012).

1.3.4 IL-17A in host defense

IL-17A is thought to be important in host defense against certain microbes but has also been implied as a driving factor in chronic inflammation.

IL-17A exerts an effect on a wide variety of cells, including fibroblasts, endothelial cells, epithelial cells and immune cells (Kolls and Linden, 2004, Xu and Cao, 2010). Molecules induced by IL-17A include many potent cytokines (e.g. IL-6, G-CSF, TNF- α), chemokines (CXCL1, CXCL2, CXCL8 and CCL20), inflammatory effectors (acute phase proteins, complement factors, nitric oxide, PGE2) and antimicrobial proteins (defensins, mucins). G-CSF and CXCL-8 are important for granulopoiesis and recruitment of neutrophils to sites of inflammation (Schwarzenberger et al., 1998, Forlow et al., 2001). IL-17A also mediates recruitment of Th1 cells through release of chemokines such as CXCL9, CXCL10 and CXCL11 (Khader et al., 2007). By inducing release of CCL20 from fibroblasts and Th17 cells, IL-17A attracts CCR6⁺ DCs and more Th17 cells, thus creating a positive feedback loop favoring their own recruitment and amplifying the inflammatory response (Pene et al., 2008).

IL-17A is rapidly up-regulated in response to microbial infection in mice, and mice lacking IL-17A or IL-17RA are susceptible to infection with various bacteria, fungi and parasites such as *Citrobacter rodentium*, *Escherichia coli*, *Pseudomonas aeruginosa*, *Klebsiella pneumoniae*, *Candida albicans* and *Toxoplasma gondii* (Shibata et al., 2007, Liu et al., 2011, Ye et al., 2001, Huang et al., 2004, Kelly et al., 2005, Mangan et al., 2006). For extracellular bacteria the susceptibility to infection following a defective IL-17A response is largely thought to depend on impaired production of chemokines and the lack of a granulocyte response. When it comes to clearance of intracellular bacteria the role of IL-17A is less clear. IL-17A is thought to contribute to the Th1 response of main importance against these pathogens (Lin et al., 2009, Khader and Gopal, 2010). It is required for an efficient vaccine response to *Mycobacterium tuberculosis* and has been shown to be of importance in the formation of granulomas against mycobacteria (Khader et al., 2007, Umemura et al., 2007, Okamoto Yoshida et al., 2010).

Lately, several genetic conditions where an impaired IL-17A response is thought to contribute to the clinical picture have been identified, including IL-17RA deficiency (Puel et al., 2011) but also hyper Ig-E syndrome (HIES) (Milner et al., 2008) resulting in recurrent cutaneous candidiasis or staphylococcal infections.

There are however also examples of exaggerated IL-17A production following bacterial infection that may lead to increased tissue damage, e.g. gastritis in *Helicobacter pylori* infection (Luzza et al., 2000) or extensive granuloma formation in schistosomiasis (Rutitzky and Stadecker, 2011). In schistosomiasis as well as in mycobacterial infection the balance between an immune response sufficient to take care of the infection and an exaggerated immune response, resulting in granuloma-induced pathogenesis and tissue damage, is important for the clinical outcome. A pathological role of IL-17A in granuloma-induced pathogenesis has been demonstrated by Cruz *et al.* (Cruz et al., 2010). It has for long been known that repeated exposure to *Bacille Calmette-Guerin* (BCG) of animals previously infected with mycobacteria might result in increased tissue damage at the site of infection, a response called the Koch phenomenon. Cruz and co-workers showed that such tissue damage was associated with increased IL-17A producing cells in the lesions and that antibodies blocking IL-17A prevented this pathological response in mice (Cruz et al., 2010).

Further, IL-17A is thought to contribute to the cytokine storm seen in some viral infections. In an influenza infection model survival was better for IL-17RA^{-/-} mice than for wild type mice, linked to a reduction in neutrophil stimulating cytokines and chemokines (Crowe et al., 2009).

1.3.5 IL-17A in chronic inflammatory and autoimmune diseases

The etiology of autoimmune diseases is still not clear even if it is generally believed to be based on an escape of autoreactive T and B cells from the normal selection leading

to tissue infiltration and inflammation. Through animal disease models or the study of patients IL-17A has been implied in the pathogenesis of several inflammatory and autoimmune conditions such as rheumatoid arthritis (RA), multiple sclerosis, IBD, sarcoidosis, psoriasis and systemic lupus erythematosus (SLE) (Onishi and Gaffen, 2010, Vaknin-Dembinsky et al., 2006, Yen et al., 2006, Kotake et al., 1999, Miossec, 2009, Qian et al., 2010, Facco et al., 2011). IL-17A is up-regulated in synovial fluid from patients with RA and in CSF from patients with multiple sclerosis as well as in the inflamed gut in patients with Crohn's disease and ulcerative colitis (Chabaud et al., 1999, Lock et al., 2002, Fujino et al., 2003). In humans, polymorphisms in the IL-23R gene important to maintaining an IL-17A response has been shown to be associated with IBD and psoriasis (Duerr et al., 2006, Nair et al., 2009).

IL-17A has been shown to act in synergy with various other factors such as IL-1 β , IL-22, TNF- α , IFN- γ , oncostatin M, CD40, B cell-activating factor (BAFF) and vitamin D3 (1,25-dihydroxyvitamin D3) (Onishi and Gaffen, 2010, Zhu and Qian, 2012). Considering the broad repertoire of pro-inflammatory molecules induced by IL-17A it contributes to inflammation in several ways. In rheumatoid arthritis for instance it has been suggested to stimulate IL-1 β , TNF- α , IL-6 and CXCL8 and other potent pro inflammatory cytokines and chemokines. It also induces RANKL and MMPs leading to degradation of cartilage matrix, osteoclastogenesis and bone erosion (van den Berg and Miossec, 2009, Shen et al., 2005, Chabaud et al., 2000). Although IL-17A seems clearly destructive in RA and multiple sclerosis, in IBD different animal models have rendered different results and it is still not clear whether IL-17A has a protective role or aggravates inflammation here. Nor is the contribution of IL-17A and IL-17F respectively, clear regarding the pathogenesis of IBD (Zhang et al., 2006, Yang et al., 2008, Xu and Cao, 2010). Another granulomatous disease of unknown etiology where the role of IL-17A is not fully elucidated is sarcoidosis even if IL-17A producing cells have been shown around and inside sarcoid granulomas indicating a role for IL-17A in granuloma formation also in this disease (Facco et al., 2011).

1.3.6 IL-17A in malignancies

Virchow postulated that chronic inflammation might facilitate carcinogenesis and tumor growth already in the 19th century. This can be exemplified by the development of colon carcinoma following IBD or gastric cancer following *Helicobacter pylori* induced gastritis. Vice versa, cancer might be accompanied by inflammation. In many settings neoplastic cells elicit an inflammatory environment, especially in their premalignant state, utilizing the effects of pro-inflammatory substances to survive and grow (Coussens and Werb, 2002, Mantovani et al., 2008). Thus the inflammatory response to cancer is a delicate balance between an immune response aiming at eliminating neoplastic cells versus promoting their growth.

As IL-17A is associated with chronic inflammation there is a potential for IL-17A to be involved in carcinogenesis. Clinically, infiltration of IL-17A producing cells in tumors

has been associated with a poorer prognosis for several cancers including colon, hepatocellular and breast cancer (Tosolini et al., 2011, Wu et al., 2012, Chen et al., 2013). IL-17A induction of MMP2 or MMP9 has also been associated with a higher frequency of hepatocellular carcinoma metastasis (Li et al., 2011).

However, the role of IL-17A in cancer is controversial, probably reflecting the wide variety of effects that IL-17A exerts on different cell types and the intricate interactions between cytokines and different cell types *in vivo*. IL-17A is thought to indirectly enhance tumor growth by inducing growth stimulating factors in various tumors, e.g. induction of VEGF in mouse models of fibrosarcoma or colon adenocarcinoma (Numasaki et al., 2003) or IL-6 promoting growth and survival of human cervical cancer cells in nude mice (Tartour et al., 1999). In these studies no direct effect on tumor proliferation of IL-17A was seen *in vitro*. Nevertheless, a direct pro-survival effect of IL-17A in combination with TGF- β has been shown in breast cancer cells although the molecular mechanisms behind this were not further investigated (Nam et al., 2008). On the other hand for two hematopoietic tumors, mastocytoma and plasmacytoma, IL-17A prevented tumor development in nude mice through stimulating synthesis of specific anti-tumoral CTL (Benchetrit et al., 2002).

Subsequent studies on mice have shown contradictory results regarding tumor development in IL-17A $-/-$ knockout mice (Kryczek et al., 2009, Wang et al., 2009). Wang *et al.* noted a reduction of tumor growth in IL-17A $-/-$ mice and thus a tumor promoting effect of IL-17A, related to induction of IL-6 in tumor and stromal cells (Wang et al., 2009). In contrast, Kryczek *et al.* reported that tumor growth and metastasis was enhanced in IL-17A deficient mice (Kryczek et al., 2009). The conflicting results can presumably be attributed to different models. However, in the study by Kryczek and colleagues the increase in tumor growth was associated with a reduced IFN- γ response, indicating that a potential protective role of IL-17A against tumors might be mediated through (or in concert with) IFN- γ . In line with this, He *et al.* has shown that IL-17RA deficient mice do not develop tumors in contrast to IFN- γ receptor deficient mice (He et al., 2010). In that study it was also shown that IL-17A administration positively correlated to MDSCs infiltrating the tumor and to a reduced CD8 $^{+}$ T cell infiltration. Further analysis showed that IL-17A was required for the development and tumor promoting activity of the MDSC in the mice with tumors.

How IL-17A affects DCs is an important question to address bearing in mind the central role that DCs have in initiating and sustaining immune responses in cancers as well as in autoimmune or chronic inflammatory diseases and in response to pathogens. Following the results from **paper III** indicating that monocyte-derived DCs treated with IL-17A fused to form multinucleated giant cells and were rendered resistant to apoptosis, we proceeded to investigate this issue further in **paper IV**.

1.3.7 IL-17A mediated cell survival

The effects of IL-17A on apoptosis and survival have been investigated in a few studies and depending on the cell type IL-17A affects cell viability differently. Thus, IL-17A has been demonstrated to indirectly enhance survival in fibroblast-like synoviocytes (FLS) from patients with RA by modifying expression of the pro-survival protein synoviolin (Toh et al., 2010). In a separate study, IL-17A has also been shown to prolong survival of FLS from RA patients (in contrast to FLS from patients with osteoarthritis) through up-regulation of BCL2 (Lee et al., 2013). STAT 3 was found to mediate the IL-17A mediated BCL2 regulation in this case. However, it cannot be excluded that this effect was secondary to IL-17A induced IL-6. The different effects of IL-17A on FLS from RA patients and patients with osteoarthritis respectively were attributed to the different amounts of IL-17A receptors expressed on the respective cells, the receptor being more frequent in cells from RA patients.

Studies on mice have shown an increased survival of alveolar macrophages following IL-17A stimulation (Sergejeva et al., 2005). Further, Hou *et al.* have shown an increased survival in astrocytes and an increased survival and up-regulation of BCL2 and BCLXL proteins in B cells and bone marrow cells, but not in bone marrow-derived DC (BMDC), following IL-17A stimulation (Hou et al., 2009). On the other hand, there are also reports of IL-17A having pro-apoptotic effects on various cells, such as vascular endothelial cells and cardiomyocytes (Zhu et al., 2011, Liao et al., 2012). Together with TNF- α , IL-17A has also been reported to promote apoptosis in oligodendrocytes from mice (Paintlia et al., 2011).

Before we undertook our studies, to our knowledge, there were no studies on how IL-17A affects human DC survival, let alone whether this could be a mechanism of importance to sustain granuloma formation in LCH.

1.4 HISTORICAL BACKGROUND OF LCH

Langerhans cell histiocytosis (LCH) is a disease that comes in many guises. This is reflected in the long time it took to group the different aspects of the disease under one diagnosis and the difficulties, still as of today, to establish the etiology of LCH.

Non-fatal but painful bone lesions, possibly LCH, were already described by Hippocrates around 400 BC (Donadieu and Pritchard, 1999). However, LCH begins to emerge in the medical literature in 1865 when Dr. Thomas Smith published a case report on a four and half-year-old boy with skin eruptions and three large erosions in the skull regarded as a congenital condition but later suggested to be the first reported case of LCH (Smith, 1865). Nevertheless, the earliest report of LCH most often referred to is a case report from 1893 by Dr. Alfred Hand at Philadelphia Children's Hospital who described a three-year-old boy with skull lesions, exophthalmos, polydipsia and polyuria, hepatosplenomegaly and a macular rash. These findings were initially ascribed to tuberculosis (Hand, 1893). In 1915, Dr. Arthur Schüller in Vienna described two other patients with skull lesions and exophthalmos, one girl of four who also had diabetes insipidus (DI) and one adolescent with adiposogenital dystrophy. This caused Schüller to believe that the pituitary gland was involved in both cases (Schüller, 1915). It was Dr. Henry A. Christian in Boston, however, who in 1919 suggested that the triad of exophthalmos, skull lesions and DI were interconnected and the eponym Hand-Schüller-Christian disease eventually came in to use. Christian ascribed the findings primarily to pituitary dysfunction (Christian, 1919) and treated the DI successfully with subcutaneous pituitary extract. Hand was however troubled by the lack of effect of pituitary extract on the lytic bone lesions and suggested that the disease was caused by pressure from either a neoplastic or a benign (infectious) process, hereby foreseeing a still ongoing debate (Hand, 1921).

In 1924, Dr. Erich Letterer in Tübingen described an acute, fulminant disorder of the reticulo-endothelial system in a six-months-old child with hepatosplenomegaly, anemia and purpura not perceived as leukemia (Letterer, 1924). Nine years later Dr. Sture Siwe in Lund reported a similar case and grouped them under the name Letterer-Siwe disease, a condition including hepatosplenomegaly, lymphadenopathy, localized tumors of the bone, hemorrhagic tendency, anemia and hyperplasia of non-lipid-storing macrophages in various organs (Siwe, 1933).

A third form of LCH was described in 1940. That year two reports from New York on what was later termed eosinophilic granuloma of the bone, were presented by Dr. Sadao Otani and Dr. Joseph C. Ehrlich (Otani and Ehrlich, 1940) and by Dr. Louis Lichtenstein and Dr. Henry Jaffe (Lichtenstein and Jaffe, 1940) respectively. The condition was thought to be benign in spite of the radiological and the microscopic picture. Surprisingly, already the same year Dr. Arvid Wallgren in Gothenburg, and one year later Dr. Sidney Farber in Boston, presented evidence that bone lesions in the three conditions presented above (Hand-Schüller-Christian disease, Letterer-Siwe

disease and eosinophilic granuloma) were microscopically identical (Farber, 1941, Wallgren, 1940). Dr. Farber suggested that all three disorders represented “variations in degree, stage of involvement and localization of the same basic disease process”. In 1953, Dr. Lichtenstein introduced the unifying concept of “Histiocytosis X” (Lichtenstein, 1953). Twenty years later, in 1973, Nezelof *et al.* suggested that the disease was the result of proliferation and dissemination of LCs (Nezelof et al., 1973). The name was eventually changed to Langerhans cell histiocytosis following the recommendations of the Writing Group of the, at that time, recently founded Histiocyte Society, in 1987 (Chu et al., 1987).

The Histiocyte Society was founded in 1985 with Dr. Christian Nezelof as its first president. The Histiocyte Society is a nonprofit international organization gathering clinicians and researches to share and spread information about the histiocytic disorders as well as coordinating clinical and laboratory studies. The year after, the Histiocytosis Association was founded, a supportive international organization of parents, patients, physicians and friends.

1.5 INCIDENCE AND EPIDEMIOLOGY OF LCH

1.5.1 Incidence

LCH can present at any age from birth to old ages but with a peak incidence in children between 0-4 years of age (Salotti et al., 2009, Guyot-Goubin et al., 2008, Stalemark et al., 2008). The incidence differs in recent studies from 2.2 per million children (0-18) (Muller et al., 2006) and year to 8.9 per million children (0-15 years) and year (Stalemark et al., 2008), probably reflecting differences in the identification of patients (suggesting under-reporting in some studies), and different age cut offs, as LCH is more common at a younger age (Alston et al., 2007, Muller et al., 2006, Salotti et al., 2009, Stalemark et al., 2008, Guyot-Goubin et al., 2008). Nevertheless, genetic or environmental factors influencing the incidence of LCH in different areas cannot be ruled out. In reality, the incidence of LCH may be even higher than reported since mild cases may go underdiagnosed.

The higher incidence in young children was illustrated in a recent study from the UK and Ireland including 94 pediatric LCH cases identified through various methods (Salotti et al., 2009). The incidence rate of LCH in children 0-14 years of age was reported to be 4.1 per million children and year in this study but in children < 1 year of age the incidence was 9.9 per million and year. The incidence dropped markedly in children 10 years and older.

In adults, the incidence is even harder to evaluate since the wide spectrum of clinical manifestations leads the patients to a variety of clinicians and LCH symptoms may go misinterpreted due to lack of awareness of LCH.

Males are affected somewhat more often than females and a male:female ratio as high as 2:1 has been reported (Broadbent et al., 1994).

1.5.2 Associated factors

Several studies have shown an association between smoking and the development of pulmonary LCH in young adults (Colby and Lombard, 1983, Vassallo et al., 2000). Otherwise the knowledge of factors that could possibly contribute to LCH is quite scarce.

In an extensive Danish epidemiological study, including one million children under the age of 15 years, 90 children with LCH were found (diagnosed between 1975 and 1989), giving an incidence of 5.4 per million children per year (Carstensen and Ornvold, 1993). In that study possible effects of pre- and post-natal risk factors such as route of delivery, birth complications, low birth weight, AB0 and Rh blood type, were analyzed but none of these factors turned out to be significant.

Two often cited reports from North America were published in 1997 (Bhatia et al., 1997, Hamre et al., 1997). Hamre *et al.* found an association between LCH and maternal urinary tract infection during pregnancy as well as feeding problems, medication use and post natal blood transfusions during the first six months of life (Hamre et al., 1997). This study also showed an association with a family history of benign tumors. The second study, which was a larger case-control study, including 459 children with LCH, showed an association between LCH and infections in the neonatal period, as well as between LCH and thyroid disease in the proband and in the family (Bhatia et al., 1997). The association with thyroid disease in the proband depended to some extent on pituitary involvement of LCH but remained also after exclusion of such cases. In addition, this study showed a protective role of childhood vaccinations. As with the problems in infancy it is however hard to know whether this could be related causally to LCH. Both studies found an association with solvent exposure and LCH, especially for single system disease.

No association with a family history of thyroid disease was seen in a recently performed case-control study in Los Angeles focusing on the Hispanic population (Venkatramani et al., 2012). Moreover, in this study no statistically significant differences between cases and controls could be found with regard to smokers in the family, maternal problems during pregnancy or pesticide exposure. However, cases were more likely to report a family history of cancer, infection during infancy, and parental occupational exposure to metal, granites, or wood dust. Salotti *et al.* reported only sporadic cases of infections in the neonatal period and only one case of hypothyroidism in a mother in their study (Salotti et al., 2009).

Interestingly, 76% of the children in an incidence study by our team were diagnosed in the fall and the winter (Stalemark et al., 2008). Other studies have reported a higher incidence during summer months in wet regions or during periods of heavy rain-fall (Chen et al., 2003, Soto-Chavez et al., 2007). In the study from the UK and Ireland however, a higher number of cases than expected were seen in March to June (Salotti et al., 2009). As pointed out by Salotti *et al.*, regional variations in infectious rates and time for school holidays may account for these differences.

1.5.2.1 Association with malignancies

There is a well-known association with LCH and malignancies, i.e. LCH and a malignant neoplasm occurring more often in the same individual than could be expected by chance alone. Several reports have shown predominantly hematological malignancies such as acute leukemia, Hodgkin's lymphoma, non-Hodgkin's lymphoma and myeloma, but also solid tumors, including breast cancer, neuroblastoma and lung carcinoma to occur prior to, concurrently with or after a diagnosis of LCH (Egeler et al., 1993b, Fischer et al., 1999, Kager et al., 1999, Rodig et al., 2008). A first literature review on this issue was performed by Egeler *et al.* in 1993 and to study this further the Langerhans Cell Histiocytosis-Malignancy study group was established in 1991 (Egeler et al., 1993b).

Their studies have shown that leukemias are the malignancies most commonly associated with childhood LCH, acute myeloid leukemia (AML) being somewhat more common than acute lymphoblastic leukemia (ALL) (Egeler et al., 1998). The temporal association between LCH and AML is distinct in that AML normally occurs after a diagnosis of LCH while ALL often precedes LCH (Egeler et al., 1998, Egeler et al., 1993b). The reason for these associations is unclear. There may be an underlying genetic instability, LCH may occur as a reactive process in response to disease or treatment, or therapy (chemotherapy and radiotherapy) may induce a secondary malignancy (Egeler et al., 1998, Whitlock et al., 1991). In most cases of lymphoma and lung carcinoma in adults LCH usually occurs concurrently with the primary malignant neoplasm and it has been suggested that these cases represent a Langerhans cell reaction to the primary tumor (Egeler et al., 1993b).

Based on the findings of a chromosomal translocation affecting a myelodysplastic disorder (MDS)-associated region on chromosome 7 in cells from an LCH lesion (further developed in section 1.9.4) and a report on MDS and LCH occurring simultaneously in four children, Egeler has suggested a possible connection between pediatric myelodysplastic disorders and LCH and raised the question of whether LCH could be a myeloid dendritic stem cell disorder (Egeler and Willman, 2000, Surico et al., 2000).

LCH has also been reported to be associated with some major congenital malformations and syndromes such as Di George syndrome and thrombocytopenia-absent radius (TAR) (Sheils and Dover, 1989, Giordano et al., 2011, Levendoglu-Tugal

et al., 1996). However, LCH patients lack the phenotype usually associated with conditions where genetic instability is known to confer an increased risk of neoplasia, such as Fanconi anemia or Li-Fraumeni syndrome (Cohen and Levy, 1989).

1.5.2.2 Association with in vitro fertilization (IVF)

In a recently published large Swedish study, a follow-up of a previous study, 26 692 children born after *in vitro* fertilization (IVF) during the years 1982-2005 were compared to all children born in Sweden during the same years, and not conceived by IVF, regarding the incidence of cancer (Källén et al., 2010, Källén et al., 2005). The study compared data from all IVF clinics in Sweden and linked this information with other data from the Swedish Medical Birth Register and the National Swedish Cancer Register. A small, but statistically significant, increased risk for childhood cancer in general was found; 53 cases against 38 expected, giving a total cancer risk estimate of 1.42 [95% CI 1.09–1.87]. The condition which was most overrepresented was LCH, with six cases found against one expected. In addition, two cases of Letterer Siwe disease in this cohort had been previously identified in the National Hospital Discharge Register (Källén et al., 2005).

As around 3% of all children born in Sweden today are conceived by IVF (Sweden, 2009), it is important to clarify any specific risks that these children may encounter and whether these risks are due to the IVF procedure *per se* or factors underlying IVF. In the case of LCH it is also possible to speculate that risks already known to be associated with IVF, such as children being born preterm or being small for gestational age might be associated with the development of LCH (Jackson et al., 2004). As a means to learn more about LCH we found it interesting to study these children more closely. The results of this study are presented in **Paper II**.

1.5.2.3 Association with autoimmune disorders

Apart from the association with thyroid disease reported by Bhatia *et al.* no certain associations prevail between LCH and autoimmune diseases (Bhatia et al., 1997). LCH has been reported to occur simultaneously with Crohn's disease but no clear association has been proven (Lee-Elliott et al., 1996). Notably, at our clinic we have had a child who was initially misdiagnosed as having Crohn's disease and it can be speculated whether the patient presented in the case report mentioned above also had LCH initially. However, whether there is an association between these granulomatous entities or to what extent LCH is misdiagnosed as Crohn's disease remains to be studied.

1.5.2.4 Familial disease

LCH is usually considered a sporadically occurring disorder. However, a number of case reports have been presented of LCH in family members (Yoon et al., 2013, Shahla et al., 2004, Hanapiah et al., 1993) and around 1% of patients with LCH have been calculated to have another affected family member (monozygotic or dizygotic twin,

sibling, parent, first cousin) (Arico et al., 1999). Arico *et al.* have also shown that concordance for LCH is higher among presumed monozygotic twins than for dizygotic twins (86% versus 12%) indicating a possible genetic component in the pathogenesis of LCH (Arico and Danesino, 2001). Notably, some of the reported cases in these studies were reported before the standardized diagnostic criteria for LCH were introduced in 1987 (Chu et al., 1987). Further, in the Danish study no clustering or familial disease was seen (Carstensen and Ornvold, 1993).

A potential clustering of LCH described in some families may have several explanations. Considering the small number of cases with familial disease one would imagine that the cause of LCH is multifactorial. Arico has also suggested that expression of specific alleles of a group of genes might confer susceptibility to LCH, but to develop LCH another event, a “second hit” would be required.

1.6 CLINICAL PRESENTATION

Clinical manifestations of LCH vary extremely from a single lytic bone lesion resolving spontaneously (more frequent in older children) via recurrent multiple lesions and chronic disease to patients presenting with acute disseminated life-threatening disease. Virtually any organ may be affected but bone lesions are the most common manifestations of LCH (Group, 1996, Bernstrand et al., 2005). In adults liver and spleen involvement is unusual but there is a higher incidence of lung disease, associated with smoking as previously mentioned (Broadbent et al., 1994, Vassallo et al., 2000).

LCH is categorized into single system disease (SS LCH), affecting only one organ, or multisystem disease (MS LCH), affecting two or more organs, with or without organ dysfunction. Bone lesions are further characterized as to whether they are unifocal or multifocal. Extensive multisystem disease is predominantly seen in very young children (Egeler et al., 2010, Huang and Arceci, 1999). The most severe disease is seen in children with involvement of risk organs. These have traditionally been lung, spleen, liver and the hematopoietic system (Lahey, 1975a). However, in the new international treatment study protocol, LCH-IV, that has recently been launched, lung is no longer considered a risk organ. The reasons for this is the frequent association of pulmonary involvement with involvement of other risk organs, a low relative hazard ratio in a multivariate analysis, and that it has proved difficult to evaluate disease activity and therapy response in the lungs.

In the incidence study from our group already mentioned (Stalemark et al., 2008), 69% of the patients had SS LCH at diagnosis and 31% had MS LCH which is in line with other reports (Carstensen and Ornvold, 1993, Salotti et al., 2009). As the burden of disease may vary over time, which may be valuable to identify in addition to disease extension at diagnosis, our group has introduced the concept of “maximal extent of disease” (Bernstrand et al., 2005). This concept includes all organs that have been

involved during the disease course in a particular patient. Of the patients who initially presented with SS LCH in the study mentioned above, one quarter later developed MS LCH, giving a peak incidence of MS LCH at the maximal extent of disease in this cohort of 48%. Of the patients with MS LCH around one third had involvement of risk organs (liver, spleen, lung or hematopoietic system). The majority of these children were under one year of age. This is also in line with other studies (Stalemark et al., 2008).

1.6.1 Prognosis and sequelae

In terms of survival, the prognosis is excellent for children with SS LCH or MS LCH without risk organ involvement (Gadner et al., 2008, Gadner et al., 2001, Howarth et al., 1999). Patients with isolated bone disease have the best prognosis (Howarth et al., 1999). However, although lower than in patients with MS LCH, disease reactivations are common also in patients with bone lesions only. As many as 18-40% of these patients experience reactivation of their disease. (Titgemeyer et al., 2001, Willis et al., 1996). There is also a substantial risk for permanent consequences of the disease, to a large extent depending on the site of the lesion(s). Patients with isolated skin lesions sometimes progress into chronic disease or to MS LCH (Titgemeyer et al., 2001, Bernstrand et al., 2005).

The prognosis for MS LCH correlates with the involvement of risk organs and response to initial therapy as evaluated after six weeks (Gadner et al., 2001). Children with risk organ involvement who fail to respond to initial therapy have substantial morbidity and still today 15% of all patients with risk organ involvement die within 5 years of diagnosis (Gadner et al., 2013). Young children (<2 years of age) are at special risk of developing the more severe forms of the disease, with a higher risk of risk-organ involvement. However, low age of by itself is not an independent risk factor for a poor prognosis (Gadner et al., 2008). When it comes to reactivation of the disease, as many as 37-54% (depending on the length of continuation therapy) of patients with MS LCH without risk organ involvement and 27% of survivors with risk organ involvement still have reactivations of their disease (Gadner et al., 2013). Recurrences may appear late after the initial diagnosis. Lahey *et al.* have reported that a plateau of event-free survival was not reached until 16 years after diagnosis (Lahey, 1975a). Even if most reactivations occur in non-risk organs, during the last ten years several papers have focused on the association between disease reactivations and the risk for permanent consequences (Morimoto et al., 2008, Pollono et al., 2007, Gadner et al., 2008).

Several studies have suggested that the incidence of sequelae in LCH patients may be higher than previously believed (Bernstrand et al., 2005, Haupt et al., 2004, Willis et al., 1996). Haupt *et al.* reported that at least one permanent consequence of LCH occurred in 52% of the patients in their long-term follow-up study (Haupt et al., 2004). The highest number was observed in MS LCH patients where 71% of the survivors reported permanent consequences of their disease. Other studies have given similar

results (Bernstrand et al., 2005, Willis et al., 1996). DI is the most frequently reported sequel occurring in around 15-25% of all patients (Bernstrand et al., 2005, Haupt et al., 2004, Willis et al., 1996, Gadner et al., 2001). Other permanent sequelae include orthopedic problems, endocrinopathies (including growth hormone deficiency), lung fibrosis, liver failure, and/or neurological and neuropsychological problems.

Considering the high number of survivors with long time sequelae it is important to develop uniform criteria and standardize selection of patients who need long term follow-up, to be able to offer appropriate support, as has been suggested by Nanduri *et al.* (Nanduri et al., 2006).

1.6.2 Characteristics of specific organ involvement in LCH

1.6.2.1 Bone

Around 80% of LCH patients have one or several bone lesions at some time during their disease course (Group, 1996, Bernstrand et al., 2005, Broadbent, 1986). Although any bone might be affected in LCH, lesions most frequently occur in the skull. Other common sites are the long bones of the extremities and the flat bones of the pelvis, ribs, mandible, and the spine. Lesions are often accompanied by adjacent soft tissue swelling. Symptoms and complications relate to the site of the lesions ranging from swelling and pain and pathological fractures in the long bones to floating teeth and gingival swelling in the case of mandible involvement, proptosis in periorbital engagement or, the collapse of a vertebrae with a risk of spinal cord compression (Broadbent et al., 1994, Egeler and D'Angio, 1995).

Grois *et al.* have shown that osteolytic lesions of the craniofacial bones are associated with a higher frequency of DI and neurodegeneration (Grois et al., 1994, Grois et al., 2010, Grois et al., 2006). Differential diagnoses include osteomyelitis and malignancies, such as Ewing sarcoma or lymphoma, chronic recurrent multifocal osteomyelitis (CRMO), vanishing bone disease and cat scratch disease.

1.6.2.2 Skin

Skin rashes in LCH are common, seen in around 40% of the patients (Group, 1996, Bernstrand et al., 2005). The clinical presentation varies widely from pinkish brown papules affecting the diaper region, the neck and the axillary folds to lesions on the scalp resembling cradle cap. Skin disease is often an initial presenting feature and is particularly common in infancy (Broadbent et al., 1994). Isolated cutaneous lesions might go undiagnosed and spontaneous regression is frequent (Egeler and D'Angio, 1995). A self-limiting form of LCH ("Hashimoto-Pritzker disease") is seen in neonates (Hashimoto and Pritzker, 1973). Still, general skin involvement in children <2 years has been associated with the development of MS LCH with risk organ disease and a poor prognosis (Broadbent, 1986).

1.6.2.3 Ears

Aural discharge is another common feature in LCH that may arise from extension of a skin rash into the aural canal causing external otitis or from a polyp of LCH tissue from a bony lesion extending into the canal. Engagement of the mastoid and chronic middle ear disease may cause deafness from destruction of the ossicles (Broadbent et al., 1994, Irving et al., 1994).

1.6.2.4 Lymph nodes

Lymph node involvement may occur as part of a disseminated disease or may reflect engagement of neighboring skin or bone lesions (Egeler and D'Angio, 1995). LCH in a lymph node sometimes also occurs as a solitary finding. Most commonly cervical lymph nodes are involved but abdominal, mediastinal, inguinal or axillary glands may also be affected.

1.6.2.5 Thymus

Thymic lesions are more rarely reported in LCH but are frequently seen at autopsy in patients who died from the disease (Egeler and D'Angio, 1995, Hamoudi et al., 1982). Yet, with the use of computed tomography (CT) and positron emission tomography (PET) thymic lesions are increasingly recognized.

1.6.2.6 Liver and spleen

Hepatomegaly is present in one third to one half of the children with disseminated LCH although actual LCH involvement of the liver occurs less frequently (Schmitz and Favara, 1998). In combination with clinical signs of liver dysfunction, hepatomegaly is a poor sign (Broadbent et al., 1994, Lahey, 1975a). Some children with hepatic involvement develop a progressive sclerosing cholangitis requiring liver transplantation (Braier et al., 2002, Jaffe, 2004). Splenomegaly may be massive and contribute to anemia and cytopenia in refractory disease.

1.6.2.7 Hematopoietic involvement – bone marrow

Pancytopenia is a relatively frequent phenomena in patients with disseminated disease but massive infiltration by LCH DCs in the bone marrow is less often seen, and if so associated with a very poor prognosis (McClain et al., 1983). Dysfunction of the hematopoietic system has *per se* been shown to be associated with a poor prognosis regardless of bone marrow infiltration by LCH DCs (Gadner et al., 2001, Lahey, 1975a).

1.6.2.8 Lungs

Isolated pulmonary LCH is most frequently seen in adults, especially in young adult smokers, but may also be seen in children. In the pediatric population, lung involvement is otherwise normally seen in the course of MS LCH (Bernstrand et al., 2001, McDowell et al., 1988). Cough or tachypnea, as well as spontaneous

pneumothorax, can be the initial presentation signs of pulmonary LCH. On plain radiography, interstitial infiltration is typically seen. High resolution computed tomography (HRCT), however, is a more sensitive method to detect nodules and cysts (Bernstrand et al., 2007). For regular monitoring of pulmonary LCH, pulmonary function tests, including diffusing capacity, can also be of value and are not associated with radiation. Lung fibrosis has been reported in up to 33% of patients with pulmonary involvement (Haupt et al., 2004).

1.6.2.9 Gastrointestinal tract

Oral involvement with ulceration of the palatal and gingival mucosa is a rather common feature of LCH and the premature eruption of milk teeth is characteristic. LCH of the gut is rare but probably underestimated in its mild forms. The most common sign is “failure to thrive” (Broadbent et al., 1994). Some cases of LCH may also be misdiagnosed as IBD as mentioned earlier.

1.6.2.10 Endocrine system

The most common endocrinopathy in LCH is diabetes insipidus (DI) that occurs in as many as 15-25% of all LCH patients or 40-50% of those with MS LCH (Bernstrand et al., 2005, Grois et al., 2006, Haupt et al., 2004, Willis et al., 1996, Donadieu et al., 2004b). DI may occur prior to, concurrently with or years after the development of other lesions (Arico and Egeler, 1998). Isolated DI presents a diagnostic challenge and a careful diagnostic work-up is mandatory to exclude other differential diagnoses, such as germ-cell tumors. DI is treated with replacement therapy of anti-diuretic hormone (desmopressin) but no curative treatment for DI has been reported, nor has any patient with established and complete DI reverted to normal (Broadbent and Pritchard, 1997, Dunger et al., 1989). Growth hormone deficiency is the second most observed endocrinopathy in LCH and affects around 10% of the patients (Group, 1996, Bernstrand et al., 2005, Grois et al., 1995, Grois et al., 2010). In patients with DI, overall anterior pituitary deficiency develops in as many as 60%. (Donadieu et al., 2004a, Haupt et al., 2004).

1.6.3 Central nervous system (CNS) involvement

The background to CNS involvement in LCH has been expanded for two reasons. Firstly, CNS involvement causes some of the most severe complications of the disease. Secondly, **paper I** of this thesis deals with neurodegeneration in LCH.

An LCH CNS study was initiated by the Histiocyte Society in the year 2000 to better characterize CNS disease and its natural course in LCH. Through this study a uniform diagnostic and follow-up program was introduced, including serial magnetic resonance imaging (MRI) evaluations, repeated neurological testing with the Expanded Disability Status Scale (EDSS) and the International Cooperative Ataxia Rating Scale (ICARS), psychological studies and electrophysiological examinations. Grois and her colleagues

in Vienna have performed much of the work regarding CNS involvement in LCH. Considering the rarity of LCH and the even rarer event of neurodegeneration, close international collaboration is important for research to proceed in this area.

The concept of CNS-LCH includes tumorous lesions in the soft tissue of the brain, including the pituitary-hypothalamic regions, as well as neurodegenerative lesions (Grois et al., 2010). Clinical symptoms depend on the site and the type of CNS involvement. Tumorous lesions of the choroid plexus, the meninges or in the brain parenchyma are unusual but can lead to headache, seizures and obstruction of the ventricles with increased CNS pressure and even hydrocephalus (Grois et al., 2004, Prayer et al., 2004). DI is considered to reflect LCH infiltration of the hypothalamic pituitary region. The clinical picture accompanying LCH-associated neurodegenerative lesions is highly variable. While some patients do not present any symptoms for years, others develop progressive neurological disturbances. Neurological symptoms sometimes precede an LCH diagnosis but most often develop several years after the initial diagnosis (Grois et al., 1998). Symptoms may follow a cerebellar pontine pattern, starting with mild tremor, reflex disturbances, or discrete gait disturbances sometimes progressing to severe ataxia rendering the patients wheel-chair bound (Grois et al., 2010). Dysphagia, dysarthria and other cranial nerve deficits may occur and in extreme cases neurodegeneration might be fatal (Grois et al., 1998). Abnormal behavior, learning difficulties, or sometimes psychiatric disease are consequences also seen (Grois et al., 2010, Van't Hooft et al., 2008, Nanduri et al., 2003). Disturbances in social behavior, appetite, temperature regulation or sleep might accompany changes in the hypothalamic region (Grois et al., 1998).

Clinical CNS neurodegeneration is thought to affect at least 10% of LCH patients (19% of all patients with multisystem disease) (Bernstrand et al., 2005, Nanduri et al., 2006, Willis et al., 1996). The exact incidence of radiological LCH lesions or LCH-associated neurodegeneration is hard to evaluate since still only patients with clinically suspected or potential CNS involvement usually undergo MRI of the brain. However, a study from our group has indicated that radiological neurodegenerative changes are present in at least 24% of all patients (Laurencikas et al., 2011). Another study has found similar results (20%) (Mittheisz et al., 2007). As mentioned above, the relationship between radiological findings and clinical symptoms is not fully understood where the degree of clinical symptoms often does not correlate to the extension of MRI findings. Presumably this reflects the reserve capacity of the human brain. However, a long-term follow-up of a small group of patients has indicated that radiologic neurodegeneration seems to be a slowly progressive process accompanied by clinical deterioration (Prosch et al., 2007, Wnorowski et al., 2008). Yet, in some patients it seems to halt and further longitudinal studies are needed to better clarify the natural history of radiological and clinical neurodegeneration. Such a study is included in the LCH-IV protocol.

Risk sites to develop DI or other CNS-LCH manifestations are lesions involving the orbital, temporal, sphenoid, ethmoid or mastoid bone and the paranasal sinuses and anterior or middle cranial fossa (Grois et al., 2006). DI is in itself a risk factor for neurodegenerative LCH (Donadieu et al., 2004b, Grois et al., 1995, Haupt et al., 2004). Multisystem disease, chronic and reactivating disease has also been associated with an increased risk of endocrine deficiencies and other CNS complications (Donadieu et al., 2004b, Grois et al., 2010, Grois et al., 2006). In order to better control the disease and avoid reactivations maintenance therapy has been prolonged in the latest international treatment studies (LCH-III and LCH-IV).

1.6.3.1 MRI findings

MRI is today the standard method to detect neurodegenerative lesions in LCH (Martin-Duverneuil et al., 2006, Prayer et al., 2004). The hypothalamic-pituitary region is by far the most commonly involved intracranial region in LCH. The typical finding for DI is enlargement of the pituitary stalk, sometimes progressing into space-occupying tumors extending to the pituitary or hypothalamus (Grois et al., 2010). The characteristic “loss of bright spot” in MRI with gadolinium contrast represents a loss of antidiuretic hormone containing vesicles (Tien et al., 1991). LCH-associated MRI changes in the pineal gland often accompany pituitary findings and comprise solid masses or cystic lesions (Grois et al., 2004). The co-appearance of pituitary and pineal gland involvement perhaps reflects the fact that these organs belong to the same circumventricular organ system located outside the blood-brain-barrier. Tumorous lesions can further occur in the meninges, the choroid plexus and the brain parenchyma as single or multiple lesions. Tumors of the brain parenchyma might follow a random or a vascular pattern (Barthez et al., 2000, Prayer et al., 2004). The differential diagnoses include craniopharyngioma, sarcoidosis, germ cell tumors or other histocytic disorders such as Erdheim-Chester disease or Rosai-Dorfman disease (Prayer et al., 2004).

There are no specific pathological changes detected with MRI in neurodegenerative LCH but the pattern, the signal intensity and the contrast enhancement together with the clinical picture is suggestive for this diagnosis. Importantly, similar findings are not seen in healthy children. Typically, a combination of changes is seen in the cerebellum, the basal ganglia and/or the pons. Less frequently the brain stem or the forebrain are involved (Barthez et al., 2000, Martin-Duverneuil et al., 2006, Prayer et al., 2004). A usual finding is symmetric, hyperintense signal changes on T2-weighted images and hypo- or hyper-intense signals on T1-weighted images involving the gray matter of the cerebellum but sometimes extended to the surrounding white matter. In the basal ganglia the findings usually consist of hyperintense signals on T1-weighted images and variable signal intensity on T2-weighted images, most often involving the globus pallidus. Additionally, two types of white matter changes are also seen, dilated Virchow-Robin spaces and, more seldom, a leukoencephalopathy-like pattern. The role of the dilated Virchow-Robin spaces in CNS-LCH is not clear. They might be related to an active inflammatory process or be the consequence of such a process. Neither is the

significance of the leukoencephalopathy-like pattern clear and such findings should warrant investigation for differential diagnoses such as metabolic or degenerative disorders (Prayer et al., 2004, Grois et al., 2010). Atrophy can be localized to the cerebellar hemispheres or it may be global. It is not a common finding but it is sometimes seen in patients with progressive symptoms (Martin-Duverneuil et al., 2006, Prayer et al., 2004). MRI findings indicative of neurodegenerative LCH are normally irreversible (Wnorowski et al., 2008, Prosch et al., 2007).

1.6.3.2 Experimental radiology

PET studies with the tracer fluorodeoxyglucose (FDG-PET) have shown an increased uptake by tumorous CNS lesions and a reduced uptake in neurodegenerative lesions (Buchler et al., 2005, Calming et al., 2002, Phillips et al., 2009, Steiner et al., 2005). It has been reported that proton magnetic resonance spectrometry that measures the concentration of neuronal metabolites shows a decrease peak of N-acetyl-aspartate infratentorially, corresponding to neurodegenerative findings in the cerebellum of one patient (Steiner et al., 2005). However, these methods need to be evaluated further and have no regular place in the diagnosis of CNS-LCH today.

1.6.3.3 Histopathological findings

Histopathological revision of samples from twelve patients with CNS-LCH, applying modern immunocytochemical techniques and correlating the findings to MRI findings and clinics, was quite recently carried out by the LCH CNS study group (Grais et al., 2005). According to the findings of this group, three types of lesional patterns can be distinguished in CNS-LCH: (1) Circumscribed granulomas in the connective tissue of the brain, corresponding to LCH lesions elsewhere in the body with infiltrating CD1a⁺ cells but accompanied by a higher amount of CD8⁺ T cells than is usually seen. (2) Neurodegenerative lesions, mainly affecting the cerebellum and the brainstem. In these lesions no CD1a⁺ cells are seen but they are characterized by marked inflammation and infiltration of CD8⁺ T cells associated with neuronal and axonal degeneration and myelin loss. This results in atrophy of the cerebellar cortex and white matter. (3) Granulomas of infundibular tumors that invade the hypothalamic region. Here, a diffuse infiltration of the surrounding CNS tissue by CD1a⁺ cells surrounded by neurodegenerative findings (loss of neurons and axons accompanied by heavy inflammation dominated by CD8⁺ T cells) is seen.

1.6.3.4 Etiology of LCH-associated neurodegeneration

The cause of neurodegeneration in LCH is unknown. As Grais *et al.* suggest it is tempting to speculate that it is triggered in response to the heavy cytokine load seen in LCH lesions in neighboring tissues, or even in other parts of the CNS. This inflammation might be sustained even after any initial lesion has disappeared, maybe through a secondary autoimmune process (Grais et al., 2010). It is also possible that neurodegeneration associated with multisystem disease is a form of paraneoplastic syndrome, where antigens characteristic of CNS components are produced by

peripheral tumors (Darnell and Posner, 2003, Imashuku et al., 2004). Autoantibodies in patients suffering from cerebellar degeneration have been described in several cancers (Graus and Dalmau, 2007, Shams'ili et al., 2003). A case with antibodies against a subtype of NMDA receptors (anti-GluRe2, seen in, among other conditions, Rasmussen encephalitis and acute disseminated encephalitis) in a boy with neurodegenerative LCH was recently published (Nakamura et al., 2012). As NMDA receptors are expressed by the Purkinje cells in the cerebellum this could perhaps explain the propensity for neurodegenerative LCH to affect this area. However, this possible etiology needs further exploration. Interestingly, neurodegenerative LCH shares similarities with human immunodeficiency virus (HIV)-related dementia, where an excessive stimulation of NMDA glutamate receptors by neurotoxins or cytokines secreted from virus-infected macrophages and microglia leads to neuronal damage and cell death (Grois et al., 1998, Lipton and Gendelman, 1995). This mechanism has also been proposed as the etiology behind neurodegenerative LCH (Grois et al., 1998). The role of treatment as a cause of neurodegeneration has been lively discussed over the years. However, the fact that neurodegeneration also occurs in patients who have not received any treatment contradicts this theory.

1.6.3.5 Treatment of CNS-LCH

No specific treatment against neurodegenerative LCH has so far been shown to be clearly effective to stop, or slow down, the neurodegenerative process. In LCH-IV, the chemotherapeutic drug cytosine arabinoside/cytarabine (ARA-C) and intravenous immunoglobulin (IVIG) will be evaluated as we and others have reported positive effects of these treatments in patients with clinical signs of neurodegeneration (Allen et al., 2010a, Gavhed et al., 2011, Imashuku et al., 2008). Imashuku *et al.* treated four patients with clinical neurodegeneration with IVIG for >12 months and reported a positive response compared to eight patients who did not receive this treatment (Imashuku et al., 2008). McClain and co-workers treated eight patients with ARA-C alone or in combination with vincristine. Out of these patients five improved clinically and to some extent, also radiologically, with follow-up time varying between two months to seven years (Allen et al., 2010a).

To prevent neurodegeneration from the start, in the future, patients will hopefully benefit from prolonged continuation therapy and more aggressive treatment of “special site” bone lesions. Tumorous CNS lesions usually respond well to treatment but in an attempt to reduce neurodegeneration, 2-chlorodeoxyadenosine/cladribine (2-CdA) will be evaluated as the first-line treatment of isolated CNS lesions in LCH-IV, based on some encouraging experience by Dhall *et al.* (Dhall et al., 2008).

1.6.3.6 Cerebrospinal fluid (CSF) findings

An important problem in diagnosing neurodegeneration is that when MRI findings or clinical findings are evident, substantial CNS damage has already taken place and may be irreversible. Hence, there is a need to detect CNS inflammation and neurodegeneration early, prior to the development of radiological lesions or clinical

deterioration, in order to intensify and evaluate treatment or to initiate experimental treatment in the advent of more specific regimens. Trying to find biomarkers of ongoing neurodegenerative CNS activity was the aim of **paper I** in this thesis.

There are some sporadic case reports of cerebrospinal fluid (CSF) investigations performed in LCH (rather reporting the presence of LCH DCs in the CSF in the case of LCH with CNS involvement) (Ghosal et al., 2001, Hamilton et al., 1982), but to our knowledge no systematic studies of CSF markers or cytokine characteristics of CSF in LCH have so far been published apart from the report presented here (**paper I**). CSF sampling is not routinely performed in LCH.

Biomarkers are (ideally) objective measures of biological or pathogenic processes used to evaluate disease risk or prognosis, to guide clinical diagnosis and to monitor treatment interventions. Since the CSF is in direct contact with the brain, biochemical changes in the brain are often reflected in the CSF. The CSF biomarkers used for the study presented in **paper I** were chosen because they are well established markers of other neurodegenerative and neuroinflammatory diseases, including Alzheimer disease, Parkinson disease, multiple sclerosis and vascular dementia and in the evaluation of acute brain damage such as stroke (Blennow et al., 1995, Blennow et al., 2001, Rosengren et al., 1996, Wallin et al., 1996, Aurell et al., 1991, Teunissen et al., 2005).

The neurofilament protein is a major component of the axonal skeleton proteins and regulates the diameter and shape of the axon. It consists of three chains of different weight, the light (NF-L), medium (NF-M) and heavy (NF-H) chains. Following axonal damage neurofilament is released into the extracellular fluid and can thus be measured in the CSF. Increased NF-L levels are found upon acute damage in multiple sclerosis (Teunissen and Khalil, 2012) but also in neurodegenerative diseases, such as amyotrophic lateral sclerosis (ALS) and vascular dementia (Rosengren et al., 1996).

Tau proteins are microtubule-associated proteins that are thought to be important for the maintenance of axonal microtubules. Hyperphosphorylated tau (p-TAU) is a key component of the neuritic tangles in Alzheimer disease where tau protein levels are typically elevated in the CSF (Blennow et al., 2012). However, tau proteins are also elevated in other neurodegenerative disorders, such as multiple sclerosis and Creutzfeldt-Jakob disease (Otto et al., 1997, Teunissen et al., 2005). There are several isoforms of tau proteins in the CSF and tau can be phosphorylated at several sites (Portelius et al., 2008). The most common assay to measure total tau detects all isoforms of tau independently of phosphorylation status (Blennow et al., 1995). In the following text TAU refers to total tau.

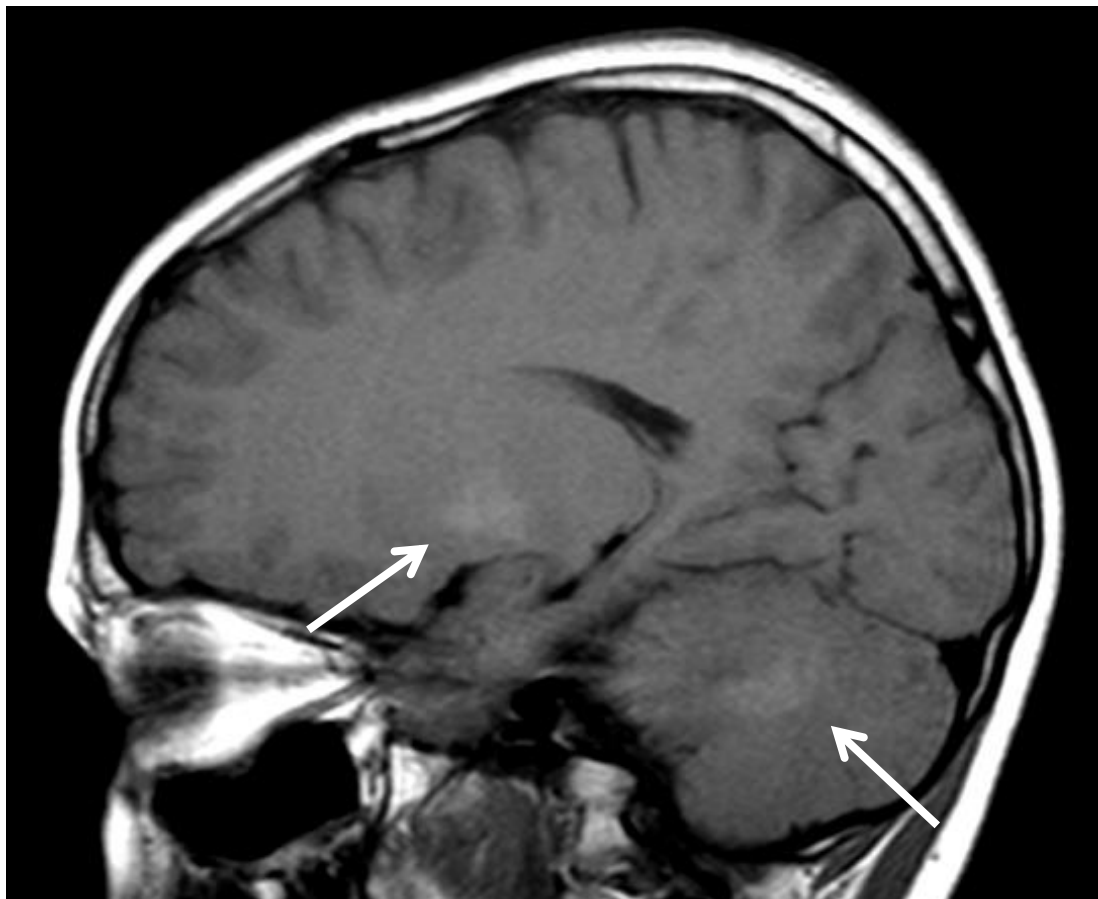
Glial fibrillary acidic protein (GFAP) is an important component of the cytoskeleton in astrocytes and elevated levels are considered to reflect acute astroglial cell damage in CSF but it is also as a marker of astrogliosis following damage to the CNS and elevated

in many chronic brain disorders (Wallin et al., 1996, Aurell et al., 1991, Blennow et al., 2001).

1.6.4 LCH in adults

Adult LCH has been reported to most commonly involve the skin, the lungs, bone and the anterior pituitary gland giving rise to DI (Baumgartner et al., 1997). Isolated pulmonary LCH primarily affects young adult smokers but lung involvement may also be part of a multi-system disease. The prognosis for adults with isolated bone lesions is very good but worse for patients with multi-system disease. An association with MDS has also been reported for adults (Billings et al., 2006).

Figure 3. T1-weighted image demonstrating high signal intensity in nucleus dentatus and globus pallidus due to neurodegenerative changes. Courtesy of Dr. Evaldas Laurencikas.



1.7 DIAGNOSIS

The Histiocyte Society classifies the histiocytic diseases into disorders with varied biological behavior and those that are truly malignant (Favara et al., 1997). The former group is classified based on the affiliated cell type, with macrophages and dendritic cells being the most common cell types involved. Hemophagocytic lymphohistiocytosis (HLH), a severe condition with abnormal macrophage activation, is the most common of the macrophage associated disorders while LCH is the most common of the dendritic cell related diseases. Other forms of dendritic cell related histiocytoses include juvenile xanthogranuloma and related disorders. Erdheim-Chester disease is a rare form of systemic non-Langerhans cell histiocytosis belonging to the juvenile xanthogranuloma family and normally seen in adults only. Truly malignant dendritic cell tumors are extremely rare.

Based on the expression of the key distinguishing markers for LCs, CD1a and Langerin/CD207, LCH is currently classified by the World Health Organization (WHO) as a hematological disease derived from LCs (Jaffe et al., 2008).

1.7.1 Histopathology

The main feature for a diagnosis of LCH is the presence of cells with the morphology of LCH DCs in lesions with typical features. (The characteristics and features of LCH DCs and LCH lesions are further presented in sections 1.9.1 to 1.9.3.) For a definitive diagnosis, some lesional cells should stain positive for CD1a and/or Langerin/CD207 (Chikwava and Jaffe, 2004, Lau et al., 2008, Jaffe et al., 2008). The demonstration of Birbeck granules by electron microscopy was previously the diagnostic “gold standard” for the diagnosis of LCH but since it has been shown that the expression of Langerin/CD207 confirms the presence of Birbeck granules, electron microscopy is no longer necessary (Valladeau et al., 2000). Additional markers helpful in characterizing LCH DCs are CD14, CD68 and S100 (seen in 50-60% of LCH DCs) and ATP-ase and alpha-D-mannosidase on specially prepared sections (Henter et al., 2004, Egeler et al., 2010, Geissmann et al., 2001). Depending on the site of the lesion, histopathological differential diagnoses may include osteomyelitis, (non-) Hodgkin’s lymphoma, malignancies, skin disorders, IBD or sarcoidosis (Egeler et al., 2010, Schmitz and Favara, 1998).

An LCH diagnosis can be made on the basis of a biopsy or through fine needle aspiration, although a shortcoming with fine needle aspiration is that it does not reveal the granulomatous-like appearance seen in histological sections (Schmitz and Favara, 1998). The histopathological picture of LCH lesions is rather uniform independent of the clinical severity (Nezelof and Basset, 1998, Schmitz and Favara, 1998). However, it is influenced to some degree by the site of the lesion and especially by the age of the lesion. Initially the lesions are cell rich, with a predominance of myeloid cells, while

older lesions tend to have a more fibrotic appearance, with few or no CD1a⁺ cells, sometime making diagnosis difficult (Schmitz and Favara, 1998).

1.7.2 Diagnostic evaluation

A modified presentation of pre-treatment diagnostic evaluations as recommended in the LCH-IV study protocol is presented in **Table I**.

Table I. Baseline diagnostic evaluations in LCH

| History | Physical Examination | Laboratory Evaluation | Radiographic Evaluation |
|---|--|--|--|
| Fever Pain Irritability Swelling Skin rashes Otorrhea Loss of appetite Weight loss or poor weight gain Growth failure Polydipsia Polyuria Diarrhea Changes in activity level Dyspnea Cigarette smoke exposure Behavioral and neurological changes | Temperature Height and weight Pubertal status Skin and scalp rashes Jaundice Pallor Bleeding Lymphadenopathy Ear discharge Orbital abnormalities Gum and palatal lesions Dentition Soft tissue swelling Lesions on the genital and anal mucosa Tachypnea, intercostal retractions Ascites or edema Liver and spleen size Neurological signs or symptoms | <u>Full blood count:</u> Hemoglobin White blood cell and differential count Platelet count ESR <u>Blood chemistry:</u> Albumin, bilirubin, ALT, AST, alkaline phosphatase, γ -glutamyl transferase (γ -GT), blood urea nitrogen (BUN), creatinine, electrolytes, ferritin <u>Coagulation studies:</u> PT, APTT/PTT, fibrinogen <u>Early morning urine sample:</u> Specific gravity and osmolality | Chest x-ray Skeletal x-ray survey* Abdominal ultrasound (liver and spleen) |
| *Functional imaging like bone scan or PET is optional and can be performed in addition to skeletal survey. | | | |
| Further laboratory investigations, imaging and clinical assessments are recommended upon specific indications at diagnosis or at follow-up, including MRI of the head or spine, CT scans, neurological assessment, endocrine assessments, bronchoalveolar lavage (BAL), endoscopy, bone marrow aspirate/biopsy and liver, lung or gut biopsies. | | | |

Table II. Definition of risk organ involvement according to LCH-IV

| | |
|---|---|
| Hematopoietic involvement (with or without bone marrow involvement): | At least 2 of the following: Anemia: Hemoglobin <100 g/L, infants <90 g/L, not due to other causes, e.g. iron deficiency. Leukocytopenia: Leukocytes < 4 x 10 ⁹ /L. Thrombocytopenia: Platelets < 100 x 10 ⁹ /L |
| Spleen involvement: | Enlargement > 2 cm below the costal margin in the midclavicular line* |
| Liver involvement: | Enlargement > 3 cm below the costal margin in the midclavicular line* and/or dysfunction (hypoproteinemia < 55 g/L or hypoalbumenia < 25 g/L not due to other causes) and/or histopathological findings of active disease |

*as assessed by palpation

Many teams have looked for a serum marker of LCH activity that could be helpful in diagnosis and disease monitoring. However, no specific marker has yet been validated. Elevated serum levels of soluble IL-2 receptor (sIL-2R) have been reported to correlate with multi-system multi-site LCH and poor response to treatment in two studies (Rosso et al., 2002, Ishii et al., 2006) and sIL-2R has, together with soluble CD40L (sCD40L), been suggested as indicators of inflammation in LCH. They have however not been evaluated in larger studies. Additionally, soluble RANKL (sRANKL) has been reported to be high in serum from LCH patients and the ratio of sRANKL/osteoprotegrin a measure of osteolytic activity in LCH (Ishii et al., 2006).

Angiotensin converting enzyme (ACE) is a marker popularly used to measure disease activity in sarcoidosis, although it is not specific for sarcoidosis and serum levels do not always correlate with the severity of disease (Culver, 2012). While there is one case report of elevated levels of ACE in LCH, ACE levels have been reported to be normal in another three patients (Rosenstein et al., 1995, Lieberman et al., 1979). ACE has not been further evaluated in LCH.

ESR and platelets may be helpful in monitoring disease activity (Calming and Henter, 1998) but the evaluation of treatment and at follow-up relies on the extent of the disease and the organs involved.

1.8 TREATMENT

Treatment of LCH has shifted depending on how the etiology has been perceived. In the 1950's antibiotics were used, but with the shift of view to LCH as being a neoplasm, in the next twenty years the role of chemotherapy in LCH was established (Komp et al., 1977, Lahey, 1975b, Starling et al., 1972, Aronson, 1951). In the 1980's thymic hormones and their derivatives were tried out following reports of LCH as an immunological condition but with limited success and therefore abandoned (Davies et al., 1983, Osband, 1986).

While therapy options for isolated skin lesions and single bone lesions have largely been up to the clinician, three large-scale, international, prospective therapeutic studies (LCH-I to III) for MS LCH have been conducted by the Histiocyte Society since 1991, focusing on the pediatric population. The information and lessons drawn from these studies provide the basis for the next study, LCH-IV, which has recently been opened.

1.8.1 Previous international treatment studies

The first larger co-operative studies, the Italian AIEOP-CNR-HX 83 and the Austrian/German DAL-HX 83/90, demonstrated complete response rates of 60-90% using vinblastine (VBL), etoposide and other chemotherapeutic drugs in combination with prednisolone (PDN) (Ceci et al., 1993, Gadner et al., 1994, Minkov et al., 2000). In LCH-I (1991-1995), 6 months therapy with either VBL or etoposide together with an initial 3-day pulse of methylprednisolone was compared for all patients with MS LCH (Gadner et al., 2001). VBL and etoposide regimens proved similar in terms of response, survival, disease reactivation, permanent consequences and toxicity but were inferior to the results of a more aggressive regimen including five drugs and longer treatment (12 months) that had been administered in the DALHX-83/90 study (Gadner et al., 1994, Minkov et al., 2000). The LCH-I trial demonstrated that involvement of one or several risk organs is associated with a poor prognosis and that the response after 6 weeks treatment is a powerful and independent predictor of outcome.

In LCH-II (1996-2001), MS LCH patients were thus stratified according to risk. Treatment was intensified for the high risk patients (< 2 years old and/or with risk organ involvement (RO+)). These patients were randomized to treatment with either a combination of VBL and PDN alone or with additional etoposide. 6-mercaptopurine was added to the continuation therapy in both arms. However, treatment duration was not prolonged compared to LCH-I (Gadner et al., 2008). Both treatments rendered a faster disease resolution and a higher survival rate than LCH-I but reactivation numbers still remained high (44%). A thorough analysis showed a significantly higher survival rate in the arm that received etoposide, further underlining the benefits of an intensified treatment for RO+ patients. Because of its leukemogenic potential (Haupt et al., 1997) etoposide has however not been further studied in LCH.

Instead, in LCH-III (2001-2008), the addition of methotrexate (MTX) and prolonged treatment duration to 12 months for all RO+ patients was evaluated as well as prolonged intense initial therapy in patients only partially responding after 6 weeks. For patients without risk organ involvement (RO- patients) the impact of 6 versus 12 months treatment was tested. Results recently published have shown that the addition of MTX did not accelerate disease resolution or increase survival for RO+ patients, but was associated with higher levels of cytotoxicity (Gadner et al., 2013). Nevertheless, survival rates for RO+ patients of both arms were better in the LCH-III trial than in previous studies. This has been attributed to the more intense and prolonged initial treatment. An aggressive salvage treatment with 2-CdA-based regimens or bone marrow transplantation also proved to be rather effective, albeit toxic, in patients not responding to the protocol therapy. Twenty one of the twenty seven patients receiving 2-CdA and seven of the ten transplanted patients survived.

An exploratory historical comparison of the response and outcome of RO+ patients in the three LCH trials (with matched patients with regard to diagnostic and stratification criteria) has shown a survival rate of 84% in LCH-III compared to 62% in LCH-I and 69% in LCH-II. LCH-III RO+ patients also had a markedly lower 5-year risk of reactivations compared to the earlier studies; 27% versus 55% (LCH-I) and 44% (LCH-II), stressing the importance of prolonged treatment duration as a way to reduce reactivations. The benefit of prolonged continuation therapy was also shown for the RO-patients.

On the basis of the previous experience indicating that prolonged systemic combination treatment reduced the occurrence of reactivations, an arm for treatment of patients with only bone involvement but with multifocal lesions was also included in LCH-III. (Minkov et al., 2008). These patients were treated with VBL and PDN for 6 months. The same therapy was recommended to patients with single bone lesions at special sites conferring a risk of CNS-complications or damage to the spine.

1.8.2 LCH-IV

The main goals of the recently opened LCH-IV study are to further increase survival of RO+ patients, while not “over-treating” responders, to reduce reactivations and sequelae by prolonging maintenance therapy even more and treating multi-focal bone lesions and “risk-site” single bone lesions more aggressively. As already mentioned, there will also be special protocols to treat isolated CNS-lesions and neurodegeneration.

In the LCH-IV protocol there is a focus on stratification and “risk-tailored” treatment. The basis will still be VBL and PDN but with an early switch to salvage treatments in patients with risk organ involvement and lack of therapy response at 6 or 12 weeks. Salvage treatments include 2-CdA/ARA-C and bone marrow transplantation, based on the positive results from earlier studies (Weitzman et al., 2009, Akkari et al., 2003, Bernard et al., 2005). A second line treatment for patients without risk organ

involvement who fail to respond to initial treatment or reactivate will also be evaluated. This regimen will contain ARA-C, vincristine (VCR) and PDN, relating to a positive previous report regarding this combination of drugs (Egeler et al., 1993a). Experience from a British group indicates that a non-steroidal anti-inflammatory drug (NSAID), indomethacin, might constitute a less toxic alternative to 6-mercaptopurine (6-MP) in continuation therapy and this will also be tested in this cohort (Munn et al., 1999, McLean and Pritchard, 1996). For isolated CNS-tumors 2-CdA will be evaluated and for clinically neurodegenerative LCH, ARA-C or IVIG is recommended as mentioned earlier.

Furthermore, an attempt to collect information on the natural course of conservatively or locally treated isolated lesions will be made in LCH-IV. Such treatment alternatives include curettage, steroid injections or expectancy for single bone lesions (Bernstrand et al., 1996, Cohen et al., 1980) or topical treatment of corticosteroids or nitric mustard on skin lesions (Munn and Chu, 1998).

1.8.3 Alternative treatments

Over the years an abundance of reports on the effect of alternative treatments in LCH have been published. IFN- α has been used successfully in a few cases but has not been properly evaluated (Bellmunt et al., 1992, Jakobson et al., 1987). A few studies have been made on cyclosporine A (CSA). On the whole the results have not proven beneficial as treatment in LCH (Arico, 1991, Mahmoud et al., 1991, Minkov et al., 1999, Minkov et al., 2003). Our group has reported a positive effect of the TNF- α -inhibitor etanercept in a patient with multi-system LCH and risk organ involvement (Henter et al., 2001). Bisphosphonates have been reported to be beneficial in bone lesions but have not become widely used (Morimoto et al., 2011, Sivendran et al., 2011). Lately, following the findings of oncogenic *BRAF* mutations in LCH and Erdheim-Chester disease (developed further in section 1.9.4), treatment with an inhibitor of mutated *BRAF* (vemurafenib) has been reported. In a case report three grown-up patients with refractory Erdheim-Chester disease, and LCH occurring simultaneously in two of the cases, were successfully treated with vemurafenib. Vemurafenib is a drug that is otherwise normally used in melanoma (Haroche et al., 2013).

1.8.4 Treatment for adults

For adults the treatment recommendations are not as thoroughly grounded as for the pediatric population. Treatments that are used for children may sometimes be less effective or even toxic to adults. Thus, many clinicians prefer monotherapy with either 2-CdA or Ara-C to VBL and PDN for adults. Efforts have been made to systematically study adult LCH patients but it has been difficult to recruit patients (Arico, 2004, Girschikofsky et al., 2013, Tatevossian et al., 2006). A recent review summarizes treatment options for LCH in adults (Girschikofsky et al., 2013).

In summary, the treatment of LCH has improved during the last twenty years. Still, with a mortality rate of about 15% in patients with risk organ involvement and a recurrence rate of around 30% for patients with MS-LCH (Gadner et al., 2013), leading to significant suffering and sequelae, there is a need to further improve treatment. To investigate a potential role of IL-17A inhibitors in combination with other chemotherapeutic drugs in the therapy for LCH was one of the goals of **papers IV** and **V**.

1.9 PATHOGENESIS OF LCH

Based on the many common features, Nezelof *et al.* proposed that pathological LCH DCs arise from Langerhans cells (Nezelof et al., 1973). Regardless of theories considering the underlying triggering event, the cells at the heart of LCH lesions were then for many years largely regarded as LCs. However, this has recently been challenged in a series of papers (Allen et al., 2010b, Hutter et al., 2012, Merad et al., 2008).

1.9.1 Characteristics of LCH DCs

Although LCH DCs share many similarities with normal LCs, they are different to normal LCs in terms of shape and phenotype. In contrast to normal LC, LCH DCs are rounded and lack typical dendritic extensions. LCH DCs stained with haematoxylin and eosin have moderate amounts of pink cytoplasm and lobulated nuclei (Schmitz and Favara, 1998). As normal LCs they co-express CD1a and Langerin/CD207 to a high degree (75-100%) as observed in several studies and reported to be independent of disease localization or clinical severity (Dziegiel et al., 2007, Chikwava and Jaffe, 2004, Geissmann et al., 2001). Still, lower numbers of CD1a⁺ cells co-expressing Langerin/CD207 have been reported in LCH lymph nodes (Favara and Steele, 1997) and observations made by our group indicate that LCH DCs in bone lesions may be CD1a⁺ CD207⁻ (unpublished data) which has also been supported by a Dutch study (Rust et al., 2006). LCH DCs are readily also positive for the macrophage marker CD68 and the monocyte marker CD14, preferentially in bone lesions (Geissmann et al., 2001, Emile et al., 1994a). Normal LCs express no CD14 and CD68 (Davis et al., 1988).

On one hand, LCH DCs express some markers normally found on activated/mature LCs, such as CD54 and CD58, and the pattern of adhesion molecules is also consistent with an activated phenotype, e.g. down-regulation of E-cadherin (Geissmann et al., 1997, Emile et al., 1994a). Still, they keep several markers of resting/immature cells, including the Birbeck granules which normally tend to disappear in activated LCs (Teunissen, 1992). Further, LCH DCs rarely express the maturation markers CD83, CD86 or DC-LAMP and continue to express MHC class II molecules intracellularly

(Geissmann et al., 2001). They are also poor stimulators of naïve T cells (Yu et al., 1995). However, following *in vitro* activation of CD40, LCH DCs mature and become functioning antigen presenting DC. It is of interest to note that isolated or self-healing skin lesions have been associated with a more mature phenotype of LCH DCs and a lower number of IL-10 expressing cells than lesions from other disease localizations (Geissmann et al., 2001). Chemokine receptor expression further emphasizes the mixed resting/activated phenotype. Following activation of normal LCs, CCR6 (the receptor for CCL20) is down-regulated and CCR7 up-regulated. CCR7 responds to CCL19 and CCL21, directing the cells toward the lymph nodes. Two groups have reported that LCH DCs express CCR6, one of the groups also found that they expressed CCR7 in addition (Annels et al., 2003, Fleming et al., 2003). β -catenin is an E-cadherin associated molecule connecting to the cytoskeleton that also serves as a transcriptional co-activator. Defective β -catenin has been suggested by Egeler's team to be implied in the maturation arrest of LCH DCs (Egeler et al., 2010).

In conclusion, LCH DCs differ from normal LCs both morphologically, phenotypically and functionally. LCH DCs typically express a mixed macrophage-monocyte-DC phenotype, are semi-mature and are poor at antigen presentation (Geissmann et al., 2001, Nezelof and Basset, 1998).

1.9.2 Origin of LCH DCs

Despite the proposition from Nezelof that LCH DCs originate from LCs it is hard to understand how LCs, that constitute a small population (1-8%) of epidermal cells, might leave the skin and give rise to LCH lesions, accumulating a large number of LC like cells with a low rate of proliferation, in organs where LCs are otherwise not found. The discoveries that LCs are replaced by local proliferation and that they develop as a separate entity of dendritic cells make this even more puzzling (Chorro and Geissmann, 2010). Alternatively than from LCs, LCH DCs may originate from myeloid DC progenitors or precursors.

In 2005, it was indeed demonstrated that myeloid circulating dendritic cells were increased in the blood of LCH patients (Rolland et al., 2005). In the same work it was demonstrated that FLT3L and M-CSF, two cytokines known to increase the number of DC progenitors and monocytes respectively were elevated. Further, GM-CSF has been reported to be elevated in the serum of children with disseminated disease (Emile et al., 1994b). Although it cannot be excluded that these findings were related to treatment, they may support that LCH DCs originate from other cells than LCs, such as blood circulating DCs, DC progenitors expressing the FLT3 receptor, or monocytes.

Additional support for a myeloid origin of LCH DCs is provided by a study from McClain's group from 2010 (Allen et al., 2010b). In this work, global gene expression in Langerin/CD207⁺ cells from thirteen LCH samples (skin and bone) was compared with Langerin/CD207⁺ LCs from normal skin. Because several markers typical for myeloid DC (such as CD1d, CD33 and CD44) were over-expressed in the

Langerin/CD207⁺ cells from LCH subjects compared to normal LC, the authors suggested that a myeloid DC progenitor might actually be the precursor of pathological LCH DCs. Considering that other cells than LCs may express Langerin/CD207, LCH DCs might arise from such a progenitor.

Another study by Hutter *et al.* (Hutter et al., 2012) has further supported the theory that LCH DCs may not derive from LCs. In this study LCH DCs were found to exhibit a distinct transcription profile that separates them from all previously known DCs based on their expression of both the Notch ligand Jagged 2 (*JAG2*) and its receptor *NOTCH1*. The role of NOTCH signaling in DCs is not clear but it is implied in DC differentiation (Cheng et al., 2010). Hutter and co-workers showed that the NOTCH1-JAG2 signaling pathway was active in LCH lesions and that JAG2 signaling induced markers typical for LCH DCs in mo-DCs, indicating a role for this differentiation pathway in LCH: Incubation of monocytes with JAG2 and GM-CSF resulted in their differentiation into CD1a⁺ DCs, independently of IL-4, and addition of TGF- β gave rise to CD1a⁺Langerin/CD207⁺E-cadherin⁻ DCs much alike the phenotype observed for LCH DCs. Considering the recently described mutation of *BRAF* in LCH (described further in section 1.9.4), it is of note that NOTCH was activated independently of *BRAF* mutation status. NOTCH signaling has been suggested in the pathogenesis of many diseases including several hematological malignancies (Radtke et al., 2010). Interestingly, NOTCH signaling in LCH has been discussed before, following the detection of actively mutated *NOTCH1* in a patient with LCH after T-ALL (Rodig et al., 2008).

Discussing the origin of LCH DCs, it is also interesting to note that a mouse model suggestive of multisystem LCH has been created by generating transgenic mice expressing simian virus (SV40) derived oncogenes specifically in classic CD8 α ⁺, Langerin/CD207⁺ DCs derived from mouse spleen (Steiner et al., 2008). These mice develop LCH like lesions in the spleen, liver, bone marrow, thymus and mesenteric lymph nodes, again underlining the possibility of other cells than conventional LCs to be the precursors of LCH DCs. However, this model does not give rise to lesions in bone and skin which are the most common sites of LCH and its relevance to LCH is still not clarified.

An alternative explanation for the differences between LCH DCs and LCs, presented by Badalian-Very *et al.*, is that LCs undergo a transformation reprogramming process, or dedifferentiation, rendering them more alike myeloid DC, similarly to what is seen as epithelial cells undergo the transcriptional reprogramming necessary for neoplastic cells to spread and invade other tissues (Badalian-Very et al., 2013). Loss of E-cadherin and up-regulation of osteopontin was suggested to point in this direction (Allen et al., 2010b, Geissmann et al., 1997).

Whether LCH DCs develop an LCH phenotype in response to intrinsic events (e.g. mutations) or in response to environmental stimuli, possibly in combination with an

underlying immune dysregulatory defect, is not clear. However, LCH lesions are known to be abundant in cytokines with capacity to generate LCs from CD34⁺ myeloid progenitors or monocytes, including GM-CSF, TNF- α , IL-4, and TGF- β (Caux et al., 1992, Geissmann et al., 1998, Jaksits et al., 1999, Garabedian et al., 2011). In both the papers by Allen *et al.* and Hutter *et al.*, LCH samples clustered as being rather homogenous although collected from different sites in the body and at different disease stages, supporting that LCH is indeed one disease (Allen et al., 2010b, Hutter et al., 2012).

In summary, several sources for LCH DCs other than LCs can be proposed, including monocytes, circulating blood DCs or DC progenitors. The idea that LCH DCs may not be of LC origin has now started to become recognized by the LCH research community. Early considering a possible myeloid origin of LCH DCs motivated us to work on mo-DCs from LCH patients in **paper III**. This was by then an original approach.

1.9.3 Characteristics of the LCH lesion

LCH lesions are granulomatous lesions consisting of a mixture of cells, including macrophages, lymphocytes (predominantly CD4⁺ T cells), eosinophils and MGCs. Granulocytes, B cells and plasma cells are occasionally found but are not thought to be an integral part of the LCH lesions (Favara and Jaffe, 1994). In contrast to other granulomatous diseases, CD1a and/or Langerin/CD207⁺ cells are always present and are mandatory for the diagnosis.

Macrophages are usually found in close contact with LCH DCs and T cells in bone and lymph node lesions but not in skin lesions. They have been pointed out as the source of IL-10 in LCH lesions (Geissmann et al., 2001). Eosinophiles are thought to be attracted to LCH lesions by CCL5/Rantes and sustained by IL-5 production from infiltrating T cells (Egeler et al., 1999). Eosinophile infiltration is most prominent in bone lesions. The role of eosinophiles in LCH is still not clarified.

Both CD8⁺ and CD4⁺ T cells are present in LCH lesions. The majority of T cells are CD4⁺ T cells and express markers of recent activation such as CD40, CD45RO and RANKL (Egeler et al., 2000, Annels et al., 2003, da Costa et al., 2005). Importantly, T cells in LCH lesions have been shown to be polyclonal (Senechal et al., 2007). Although the antigen specificity remains unknown the T cells have been suggested to be attracted to the lesions by CCL20 and CXCL11 production from LCH DCs (Annels et al., 2003). In 2007, the presence of CD25⁺ FoxP3⁺ T cells, regulatory T cells, were shown in LCH lesions (Senechal et al., 2007). Up to 20% of the T cells in the bone lesions examined in this study were found to be Tregs. Whether they are a result of an immunological attempt to attenuate a boiling inflammatory pot or the result of tumor (like) induced suppressive activities remains to be elucidated. That regulatory T cells

are not able to stop the inflammatory process is consistent with a non T cell origin of the inflammation in LCH.

LCH lesions are characterized by an abundance of potent pro-inflammatory cytokines and chemokines, a picture sometimes referred to as a “cytokine storm”. The typically inflammatory appearance of the lesions has been held as an argument of an inflammatory etiology but the picture is also similar to what is seen in some malignancies, e.g. Hodgkin’s lymphoma (Badalian-Very et al., 2013). CD4⁺ T cells and LCH DCs are considered to be the major source of cytokines but macrophages, stromal cells and, to a less degree, eosinophils are also prominent cytokine producers (Laman et al., 2003).

Cytokines and chemokines that have been documented in LCH lesions include IL-1 α , IL-1 β , IL-2, IL-3, IL-4, IL-5, IL-7, IL-8, IL-10, IL-11, TGF- α , TGF- β , TNF- α , IFN- γ , GM-CSF, M-CSF, RANKL, leukemia inhibitor factor (LIF), CCL20, CCL5 and CXCL11 (Egeler et al., 1999, de Graaf et al., 1996, Garabedian et al., 2011, Andersson By et al., 2004, Bechan et al., 2006, Annels et al., 2003, da Costa et al., 2005). IL-6 mRNA has been shown by *in situ* hybridization (Foss et al., 1996). While GM-CSF, TNF- α and IL-1 might promote the maturation of LCH DCs, IL-4 and IL-10 may contribute to keeping them in an immature state (Hart, 1997, Geissmann et al., 2001, Garabedian et al., 2011).

Da Costa *et al.* showed that the receptor activator of NF- κ B (RANK) is expressed on LCH DCs and that RANKL and M-CSF is present in LCH lesions (Senechal et al., 2007, da Costa et al., 2005). Based on the findings of Rivollier *et al.*, that stimulation with RANKL and M-CSF can induce differentiation of immature DCs into osteoclasts, and their own findings, this group have thus suggested this pathway as a possible origin of MGCs in LCH (Rivollier et al., 2004, da Costa et al., 2005). As mentioned previously FLT3L and M-CSF has been reported to be increased in the serum of LCH patients in one study (Rolland et al., 2005) as has RANKL (Ishii et al., 2006), IL-1 α , IL-6 (Murakami et al., 2012) and GM-CSF in children with disseminated disease (Emile et al., 1994b). Yet another cytokine that was detected in the serum of LCH patients by our group at the beginning of this thesis is IL-17A and we continued to explore the potential role of IL-17A on DC and in LCH (**papers III-V**).

1.9.4 Theories on the etiology of LCH

1.9.4.1 Is there an underlying immune regulatory defect in LCH?

In 2004 Nezelof and Basset suggested that a limited underlying defect in a yet unidentified molecule, such as a receptor, might hinder the switch from an innate to an adaptive immune response in LCH patients (Nezelof and Basset, 2004). They proposed that proliferation and activation of LCs and macrophages, resulting in aberrant granuloma formation and the cytokine storm, could be viewed as reactive mechanisms trying to compensate for the absence of an adaptive immune response.

As stated, there is a well-known association between LCH and other malignancies but no specific susceptibility to infectious agents or clear association with autoimmune disorders (except for maybe thyroid disorders) has been shown as of today (Bhatia et al., 1997, Nezelof and Basset, 2004) Nor has any specific mutation or allelic variant been reported in LCH patients in this regard.

Reports on immunological abnormalities in LCH children have been recurrent but the findings have been inconsistent and the reasons and implications often not evaluated further. Thus, in the early 1980's Osband *et al.* reported that circulating T cells from LCH patients were spontaneously cytotoxic to cultivated fibroblasts and correlated this to low numbers of suppressor T cells (regulatory T cells) (Osband et al., 1981). This team successfully treated these patients with crude thymic extract. However, this treatment was not successful in a follow-up study (Ceci et al., 1988). In the 1980's, hypergammaglobulinemia in LCH patients was also reported (Lahey et al., 1985). Low T cell counts in LCH children have been reported in some studies (McClain et al., 2003, Ceci et al., 1988). In more recent years, Senechal *et al.* have reported normal absolute lymphocyte counts in peripheral blood from naïve LCH patients but an increased prevalence of circulating Tregs (Senechal et al., 2007). HLA-DRB1*03 has been suggested to protect against multisystem disease (Bernstrand et al., 2003).

There is a link between LCH and hemophagocytic lymphohistiocytosis (HLH) in that severe forms of LCH sometimes are complicated by HLH (Henter et al., 2004). Recently, a male patient carrying the gene for the X-linked lymphoproliferative syndrome (XLP), *SH2D1A*, was also described to develop LCH prior to XLP (Zhang et al., 2011). Mutations in the *SH2D1A* gene cause a T cell dysfunction and result in a defective development of natural killer (NK) T lymphocytes. The authors speculated that this might let LCH DCs survive and thereby contribute to the development of LCH.

In summary, the possibility of a (genetic) immunological dysfunction, perhaps predisposing for an aberrant immune response to a triggering factor or cancer development, is still not fully evaluated as having a potential role in the etiology of LCH.

1.9.4.2 Is LCH an infectious disease?

From the granulomatous appearance and the abundance of cytokines in LCH lesions it is tempting to assume that LCH is triggered by an infectious agent, either directly infecting DCs or by recruiting monocytes or circulating DCs to sites of infection. Hand first suggested that the symptoms described in his first classical report of LCH were due to tuberculosis (Hand, 1893). Still in the late 1940's LCH was thought to be of infectious origin and treated with antibiotics (Aronson, 1951). However, no infectious agent has, so far, been shown to be causative of LCH.

Several studies have been performed trying to identify a viral cause of LCH. Human herpesvirus type 6 (HHV6) has been of special interest since this virus has been reported to be frequently involved in early childhood infections. Likewise, several case reports and one study, have also suggested a role for Epstein-Barr virus (EBV) in LCH (Chen et al., 2004, Sakata et al., 2008, Shimakage et al., 2004).

In a study by Leahy *et al.*, HHV6 DNA was detected by PCR in 14 out of 30 (47%) LCH lesions suggesting a role in the pathogenesis of LCH for this virus (Leahy et al., 1993). However, McClain and co-workers did not find any evidence for a viral etiology of LCH in their studies including lesions from 56 LCH patients examined for nine different viruses (HHV6, herpes simplex virus (HSV), human cytomegalovirus (HCMV), Epstein-Barr virus (EBV), adenovirus, human T cell viruses type I and II (HTLV type I and II), human immunodeficiency virus (HIV) and human parvovirus) by PCR and *in situ* hybridization (McClain and Weiss, 1994, McClain et al., 1994).

Furthermore, in an extensive study from 2008 Jeziorski *et al.* thoroughly examined the role of EBV, HCMV and HHV6 in LCH. In this study, the prevalence of EBV, HCMV and HHV6 in plasma and the antibody response against these viruses in 83 patients and 236 age-matched controls were investigated, as well as the presence and cellular localization of these viruses in LCH tissue samples from 19 patients. The results indicated that, even if low copy numbers of EBV and HHV6 could be detected in LCH lesions, they originated from by-stander lymphocytes and were due to reactivation of these viruses due to the immunosuppressive microenvironment in LCH granuloma. The study did thus not support a role of any of the examined viruses in the pathogenesis of LCH (Jeziorski et al., 2008).

Human herpesvirus type 8 (HHV8) has been studied separately in two studies without evidence for a role of HHV8 in the etiology of LCH (Jenson et al., 2000, Slacmeulder et al., 2002). In 1999, Ristevski *et al.* reported that a new type of endogenous type D retroviral particles were found in a SCID mouse thymic lymphoma that developed secondary to transplantation of LCH biopsy material into mice. Apart from this report there have been no other reports on retroviruses having a role in LCH (Ristevski et al., 1999).

Some members of the herpesvirus family had been investigated in LCH before we undertook our study but previous to the work reported by us in **paper III** there was no complete study of the herpesvirus family in LCH, let alone of the Herpesvirus Saimiri (HVS).

1.9.4.3 Is LCH a neoplastic disease?

A finding that is considered by many as one of the most important pieces of evidence for LCH being a neoplasm, is the results from X-chromosome inactivation studies in 1994 showing that LCH DCs from non-pulmonary LCH were monoclonal, both in localized and disseminated forms of LCH (Willman et al., 1994, Yu et al., 1994). However, the presence of monoclonal cells is *per se* not sufficient proof of a neoplastic

origin since aggressive immune disorders may also sometimes go with oligoclonal expansion of immune cells (Weiss et al., 1985). Additionally, the pathological LCH DCs involved in pulmonary LCH were shown to be non-clonal (Yousem et al., 2001).

A number of cytogenetic alterations have been reported in LCH DCs but, as many other findings in LCH, these findings have been hard to repeat in follow-up studies and are thus of unclear significance. The first cytogenetic alterations in LCH were reported by Betts in 1998 (Betts et al., 1998). In this study, a t(7;12)(q11.2;p13) translocation was found in a small part of unsorted cells from an eosinophilic granuloma. Other abnormalities were found in another four patients. A subsequent study, using comparative genomic hybridization (CGH) and loss of heterozygosity (LOH) analysis, also showed different chromosomal aberrations in LCH DCs. However this study included only seven samples (bone) and the reported abnormalities were nonrecurrent within the set of samples, indicating that they were rather sporadic findings than relevant to LCH pathogenesis (Murakami et al., 2002). Chikwava *et al.* found a higher degree of fractional allelic loss of tumor suppressor genes in samples from patients with multisystem disease and high-risk patients than in patients with SS LCH (Chikwava et al., 2007). In contrast, in a large study from 2009, no genomic aberrations could be found in CD1a⁺ or CD1a⁻ cells from LCH lesions with various techniques, including array CGH and SNP array (da Costa et al., 2009). As stated by the authors of the latter study, cryptic point mutations in unidentified genes (or a small viral insertion) could however not be excluded. Telomere lengths have been evaluated in two separate studies but with contradictory results, perhaps depending on different sensitivity in the methods used (Bechan et al., 2008, da Costa et al., 2007).

Several genes regulating cell survival, proliferation and cell death have been shown to be overexpressed in LCH DCs, mainly by immunohistochemistry and *in situ* hybridization but in some cases with PCR. Both pro survival and pro apoptotic pathways have been shown to be active. Apart from the recent finding of the BRAF V600E mutation, no mutations in these molecules have repeatedly been demonstrated and stimulation might thus depend on cytokine or growth factor stimulation.

Schouten *et al.* showed by immunohistochemistry that LCH DCs expressed TGF- β receptor I and II, p53, MDM2, BCL2, P21, P16 and Rb in more than 90% ($\geq 27/30$) of the tissue samples examined, (Schouten et al., 2002). While TGF- β receptors may play a role in tumor suppression, the other molecules belong to the p53- p21 and p16-Rb pathways, which can induce cell cycle arrest or apoptosis in response to DNA damage (Schouten et al., 2002). Notably, BCL2 was also detected in many other lesional cells. Consistent with this, Savell *et al.* demonstrated BCL2 mRNA and protein expression in LCH DCs in contrast to normal LCs, without finding evidence for any gene rearrangements (Savell et al., 1998). As it has been shown that DCs up-regulate BCL2 in response to CD40 ligation by T cells, up-regulation of BCL2 was suggested to be a secondary event to such a mechanism (Bjorck et al., 1997).

Quite a high number of LCH DCs have been shown to express FAS and/or FASL. The frequency was higher in single-system disease (69%) compared to multisystem lesions (46%). This was interpreted as reflecting the higher spontaneous resolution frequency of solitary lesions and that more prominent lesions have found ways to circumvent apoptosis (Petersen et al., 2003).

The proliferation stimulating oncogenes *MYC* and *HRAS* have also been demonstrated to be expressed in LCH by *in situ* hybridization, interestingly only in late stages of the disease (Abdelatif et al., 1990). Despite different results regarding the expression of the proliferation marker Ki-67 in between 2-25% of LCH DCs, the number of mitoses observed in LCH lesions is usually low (Schmitz and Favara, 1998, Bank et al., 2003, Laman et al., 2003, Senechal et al., 2007, Brabencova et al., 1998, Hage et al., 1993). Thus, the rate of cell division is low even if cell cycle pathways are active. This could perhaps be related to a high expression of P53 as suggested by Egeler *et al.* (Egeler et al., 2010). P53 is the only molecule that has repeatedly been found to be up-regulated in LCH. Normally expressed at low levels, expression of P53 is increased following cellular stress. It blocks progression of the normal cell cycle and may instead induce apoptosis. Being a tumor suppressor gene, it is often absent or mutated in cancer cells.

In the recently published study documenting the BRAF V600E mutation, in a single sample (1/61) a known cancer-related mutation was detected in *P53* (TP53 R175H). No mutations in *P53*, or the regulating protein MDM2, have otherwise been reported, or shown in the two studies that have specifically investigated this (Weintraub et al., 1998, Badalian-Very et al., 2010, da Costa et al., 2009). The normal (non-mutated) expression of P53 in LCH speaks against a neoplastic origin of LCH.

BRAF is a pivotal protein kinase of the RAS-RAF-MAPK signaling pathway which regulates cell survival and proliferation used by several growth factors, e.g. GM-CSF (Nichols and Arceci, 2010). In 2010 the first repeatedly demonstrated mutation, a known oncogenic mutation in *BRAF*, BRAF V600E, was documented in 35/61 (57%) of archived LCH samples from bone and various other organs (Badalian-Very et al., 2010). The authors used a genome assay, OncoMap, which tests 983 alleles from 115 cancer-related genes. The findings were also validated through pyrosequencing. Apart from the recurrent findings of the BRAF V600E mutation, two other validated mutations were noted in one sample each; the mutation in *P53* mentioned above, and MET E168D, a variant allele of c-Met, encoding the hepatocyte growth factor receptor (HGFR), although this allele could be a non-pathogenic polymorphism.

Others have subsequently repeated the results of Badalian-Very *et al.* regarding BRAF V600E (Sahm et al., 2012, Satoh et al., 2012). Satoh *et al.* additionally identified two novel mutations of *BRAF*, a stimulating somatic mutation (BRAF 600DLAT) and a germ line, non-stimulating, mutation (BRAF T599A). (Satoh et al., 2012). This group studied the presence of *BRAF* mutations in peripheral blood mononuclear cells (PBMCs) and monocytes without finding evidence for somatic mutations in *BRAF*

arising at this level. Considering the debate on the origin of LCH DCs it is interesting to note that the mutations reported thus seem to arise in the tissue rather in circulating precursors. That a few progenitor cells harbored the mutation could however not be completely ruled out due to sensitivity limitations of the methods, allowing for a very small *BRAF* mutation-carrying myeloid-restricted clone in the bone marrow to avoid detection.

Meanwhile, using a mutation-specific antibody against BRAF V600E, Sahm *et al.* have shown that the majority of cells co-express CD1a and BRAF V600E while only a fraction of these express Langerin/CD207 (Sahm *et al.*, 2012). Sahm and colleagues also noted that the BRAF V600E mutation was harboured by cells of different maturation status. However, as the authors state, no conclusion can be drawn from this whether mutated cells acquire an LC phenotype or whether LCs dedifferentiate in response to mutations.

In the original study the BRAF V600E mutation was not found in samples of dermatopathic lymphadenopathy, a disease characterized by proliferation of normal LCs, implying that this mutation is specific to pathological LCs (Badalian-Very *et al.*, 2010). The BRAF V600E mutation has later been shown to be present in Erdheim-Chester disease as well, but not in other non-Langerhans cell histiocytoses (Haroche *et al.*, 2012).

Even if the BRAF V600E mutation has been firmly anchored in LCH history the role of this mutation in the pathogenesis of LCH is still not clear. The presence of mutated *BRAF* does not appear to correlate with disease stage even if it was shown to correlate negatively with age by Badalian-Very *et al.* (Badalian-Very *et al.*, 2010). The RAS-RAF-MAPK signaling pathway has also been shown to be active in LCH samples without a BRAF V600E mutation, possibly due to cytokine stimulation. Hence, the significance of BRAF V600E stimulation on this pathway is not clear.

The BRAF V600E mutation has been found in several benign and malignant tumors (Davies *et al.*, 2002, Michaloglou *et al.*, 2008). Alone it is not sufficient to drive tumor development but in the presence of other pro oncogenic mutations it may contribute to tumorigenesis. In benign nevi a BRAF V600E mutation alone is thought to induce a resting state (oncogene-induced senescence) of the cell but in the context of other acquired mutations it may facilitate the development of malignant melanoma. (Michaloglou *et al.*, 2008). A parallel has subsequently been suggested by Badalian-Very *et al.* between self-limiting and aggressive LCH: Oncogene induced senescence may allow the clearance of self-limiting forms of LCH while additional mutations (not yet characterized) might lead to more aggressive forms of LCH.

In a recent review Badalian-Very *et al.* argues that the recurrent findings of BRAF V600E mutation in addition to the formerly described clonality of LCH DCs are sufficient to assign LCH a neoplastic origin, carefully emphasizing neoplastic and not

malignant (Badalian-Very et al., 2013). As the technical advances in genetic research are impressive, new mutations will perhaps soon be described that definitively assign LCH a neoplastic origin. Still, mutations may occur as the result of the heavy inflammation pressure and may not be at the bottom line of LCH etiology. This might be supported by the finding that 40% of samples from isolated pulmonary LCH lesions, that are usually polyclonal, investigated by Badalian-Very *et al.*, turned out to be positive for the BRAF V600E mutation (Badalian-Very et al., 2010). Intriguing are also still the facts that LCH DCs, in spite of disease stage, can be made to mature *in vitro*, that no cell line has successfully been established as well as the documented cases of spontaneous remission of LCH even in multi-systemic disease (Nezelof and Basset, 2004).

As is often the case, LCH etiology may turn out to be a synthesis of all theories. An immune dysregulation, or a pro-survival mutation in a DC progenitor cell, may result in an aberrant inflammatory response following an infection. This in turn may favor increased viability and possibly the accumulation of further mutations as in many cases of inflammation-driven cancer development. In the absence of massive cell division (in restricted cell lines such as DCs) this may give rise to a “pre-malignant like” condition and the generation of LCH lesions.

2 AIMS OF THE THESIS

The overall aim of this thesis was to contribute to the understanding of the pathogenesis, the search for new treatment options and improved monitoring of disease activity in children with LCH, and thus to improved survival and reduction of sequelae of affected individuals.

The specific aims were:

1. To identify laboratory parameters to evaluate *ongoing* neurodegeneration in children with LCH (**paper I**)
2. To clarify whether there is a correlation between IVF and LCH, and, if so, to evaluate possible explanations for such a connection (**paper II**)
3. To study cytokine profiles in LCH and viruses possibly involved in LCH (**paper III**)
4. To understand why IL-17A treated healthy DC, which are LCH-DC-like cells, are resistant to death and if this mechanism can be of importance in explaining LCH (**paper IV-V**)

3 PATIENTS, MATERIAL AND METHODS

This section will briefly describe the patients and methods included in **papers I-V**. For a more extensive description readers are kindly referred to the method section of each paper. **Papers III-V** are based on laboratory work with the focus to clarify effects of IL-17A on DCs and a potential role for IL-17A in the pathogenesis of LCH. They are the result of an international collaboration between France, Italy, Sweden and the Netherlands (**paper III**). The laboratory work was carried out by several team members, mainly under the supervision of Prof. Delprat.

Ethical permission to perform the studies was provided by the Regional Ethical Review Boards in Stockholm and Gothenburg, and the local ethic committees in Italy, France and the Netherlands according to national regulations. Informed consent was obtained from each subject where so requested by the ethical permission.

3.1 PATIENTS

An overview of patients included in **papers I, III and V** is presented in **Table III**.

The aim of **paper I** was to identify biomarkers in the CSF indicative of *ongoing* neurodegeneration associated with LCH. In this paper nine patients diagnosed with LCH, eight at Astrid Lindgren's Children's Hospital, Karolinska University Hospital in Stockholm, and one at Lund University Hospital (median age at LCH diagnosis 2.1 years, range 0.4–6.3 years), and signs of LCH-related radiological neurodegeneration (as detected by MRI) were included. All patients showed either endocrine deficiencies and or clinical symptoms of neurodegeneration such as neurological symptoms or psychosocial problems diagnosed 0–6 years after the LCH diagnosis. The levels of biomarkers in the CSF of these patients were compared with levels in the CSF of 110 patients with newly diagnosed ALL aged 1–16 years (median 4.7 years, mean 6.4 years), who had no signs of CNS-leukemia.

In **papers III and V** patients with different disease categories (SS-LCH or MS-LCH) and with different disease activity, controlled at the clinics participating in the studies were included.

All patients in **papers I, III and V** were assessed with regard to factors that might be relevant to the laboratory findings or affect the findings, such as age at diagnosis and at the time of study, organ involvement during the course of the disease, chemotherapy received prior to and at the time of sampling, and disease activity at sampling. Disease activity was graded according to the LCH-III study protocol in **paper I and III**, and in **paper V** according to LCH-IV. Disease state categories in LCH-IV include non-active disease (NAD), no active disease, resolution of all clinical signs and symptoms; active

disease (AD) better, regression of signs/symptoms, no new lesions; AD stable, persistence of signs or symptoms, no new lesions and AD worse, progression of signs or symptoms and/or appearance of new lesions. In an attempt to describe the severity of the disease at the time of sampling, disease activity was also rated as 0 – 4 where 0 corresponded to NAD resolution, 1 to mild disease (regression of active disease or mild chronic disease, no hypoalbuminemia or ESR elevation, 2 to moderately active disease, mild thrombocytosis, hypoalbuminemia or ESR elevation, 3 to progressive disease or constantly marked active disease, marked hypoalbuminemia or ESR elevation and 4 to life-threatening disease. In **papers I** and **V** no patients fulfilled the criteria for level 4.

Some of the patients were included in more than one study. See **Table III** for details.

The patients in **paper II** were identified through crosslinking birth data from all IVF clinics in Sweden for children born following IVF with the Swedish Cancer Register and the Patient Register (previously the Hospital Discharge Register). Individuals born 1982–2005 were included in the study: a first cohort of children born 1982–2001, reported by Källén *et al.* 2005 (Källén et al., 2005), and a second cohort of children born 2002–2005 that were additionally included in a follow-up study (Källén et al., 2010). The diagnoses that were searched for in the Swedish Cancer Register were: D76.0, C96.0, C96.1 (ICD-10); 202.9 (ICD-9); 202.1 and 289.5 (ICD-7), and in the Patient Register/Hospital Discharge Register: D76.0, C96.0, C96.1 (ICD-10); 202F, 202D, 277W, 272H (ICD-9); 279.03, 279.06 and 279.07 (ICD-8). The National Board of Health and Welfare granted permission for the study and performed the crosslinking.

Eight children conceived by IVF and with an LCH diagnosis were identified this way. The medical records for each child were acquired from the hospitals where the diagnoses were made and the children treated. The records were reviewed to verify the LCH diagnosis and to characterize the disease for each child. Originally we had planned to contact the families to collect more information, such as the reasons for IVF or familial diseases, but after thorough discussions it was concluded that it could not be excluded that this would cause harm to the families and permission from the National Board of Health and Welfare for this was not obtained.

Twenty seven children with LCH, previously identified in a population-based study performed by our group, including all children diagnosed with LCH in the Stockholm County between 1992 and 2001 were chosen as a reference group (Stalemark et al., 2008). The information on neurodegenerative findings in this population comes from a separate study by our group on CNS involvement in LCH (Laurencikas et al., 2011).

Table III. Overview of LCH patients included in the different studies (papers I, III and V).

Patients of paper II (IVF-LCH) are not included for integrity reasons.

| Patient | Sex | Age at diagnosis | Organs involved in the disease course (until latest study) | Chemotherapy received (until latest study) | Paper I Age at study start/Disease activity (class [#])/Sequelae | Paper III Age at study /Disease activity (class [#])/Sequelae | Paper V Age at study /Disease activity (class [#])/Sequelae |
|---------|-----|------------------|---|---|--|---|---|
| 1 | F | 2 y | ears*, skin*, pituitary*, thyroid*, bone, gingiva, neurodegeneration [§] | VBL, CST, MTX, VP-16, 6-MP, radiotherapy, retinoid, IFN α , IVIG | 19 yr/AD, chronic (2→2) / PH, CNS symptoms | 20 yr/AD, chronic (2→1)/PH, CNS symptoms | |
| 2 | F | 5 mo | bone*, skin, spleen, liver, hematopoietic system, thymus, pituitary, neurodegeneration [§] | VBL, CST, MTX, 6-MP, anti-TNF α , 2-CdA, IVIG | 5 yr/AD, progression (3→3)/ DI, GHD, CNS symptoms | 6 yr/ AD, progression (3→3→3)/ DI, GHD, CNS symptoms | 10 -11-11yr/AD, chronic (2→2→2)/ DI, GHD, CNS symptoms |
| 3 | M | 5 mo | bone*, skin*, ears*, spleen*, neurodegeneration [§] | VBL, CST, MTX, 6-MP, VP-16 | 12 yr/AD, chronic (1)/proptosis, CNS symptoms | 13 yr/ AD, chronic (1→1)/proptosis, CNS symptoms | |
| 4 | F | 3 y | bone*, pituitary, neurodegeneration [§] | CST, 6-MP, MTX, IFN α | 15 yr/NAD (0)/DI | 17 yr/NAD (0)/DI | |
| 5 | M | 16 mo | bone*, skin*, ears*, gingiva*, lungs, neurodegeneration [§] | CST, VBL, 6-MP, MTX, anti-TNF, VP-16 | 6 yr/AD, chronic (2→1)/ CNS symptoms | | |
| 6 | M | 6 y | ears*, bone*, pituitary*, skin, neurodegeneration [§] | CST, VBL, 6-MP, MTX, 2-CdA | 13 yr/AD, progression (3→3)/ PH, CNS symptoms | | 18-20 yr/AD, chronic (2→1)/ PH, CNS symptoms |
| 7 | M | 2 y | ears*, skin* pituitary, neurodegeneration [§] | CST, MTX, 6-MP | 7 yr/ AD, chronic (2)/DI | | |
| 8 | M | 2 y | bone*, skin*, ears*, pituitary, neurodegeneration [§] | VBL, CST, MTX, 6-MP | 9 yr/NAD (0) /DI, GHD, CNS symptoms | | |
| 9 | M | 4 y | bone*, pituitary*, skin, neurodegeneration [§] | | 10 yr/NAD (0) /DI, GHD | | 13-15 yr/NAD resolution (0→0)/DI, GHD |
| 10 | M | 16 mo | skin*, lung*, liver*, lymph node*, spleen* | VBL, CST, MTX, 6-MP, 2CdA, ARA-C | | 3 yr/AD, stable (2)/liver failure | |

| | | | | | | | |
|----|---|-------|---|---|--|---|----------------------------|
| 11 | M | 2 yr | lymph node*, lung* | VBL, CST, 6-MP, MTX | | 3 yr/NAD (0)/liver failure | |
| 12 | F | 15 mo | bone*, skin* | VBL, CST | | 18 mo/Active disease, diagnosis (3→1→1) | |
| 13 | M | 10 yr | lung*, bone* | VBL, CST, 6-MP | | 13 yr/NAD (0) | |
| 14 | F | 55 yr | lung*, bone* | VBL, CST, 6-MP | | 55 yr/AD, better (1) | |
| 15 | M | 9 yr | bone* | VBL, CST | | 11 yr/NAD (0) | |
| 16 | M | 7 mo | skin*, lymph node*, liver*, ears*, spleen, bone, hematopoietic system, intestines | VBL, CST, MTX, VP-16, 2CdA, ARA-C, 6-MP | | 14 mo/AD, progression (4) | 5 yr/AD, better (2) |
| 17 | F | 4 mo | bone*, skin*, lung*, lymph node* | VBL, CST, MTX, 6-MP | | 6 yr/AD, better (1) | |
| 18 | M | 5 mo | skin*, lung*, lymph node*, ears* | VBL, CST, 6-MP | | 7 yr/NAD (0) | |
| 19 | M | 14 mo | bone*, skin*, spleen* | VBL, CST, 2CdA, ARA-C, 6-MP | | | 2 yr/NAD (0) |
| 20 | M | 10 mo | skin*, bone, pituitary | VBL, CST, 6-MP | | | 3 yr/Reactivation (3)/DI |
| 21 | M | 7 mo | bone*, skin* | | | | 7 mo/Active, diagnosis (3) |
| 22 | F | 2 mo | skin*, spleen | VBL, CST, 6-MP, MTX | | | 4-6 yr/AD, chronic (1→1) |
| 23 | F | 14 yr | bone*, mucosal membranes, lung, pituitary | VBL, CST | | | 15 yr/AD, better (1)/DI |
| 24 | M | 2 yr | bone*, skin* | VBL, CST | | | 2 yr/AD, better (1) |
| 25 | F | 2 yr | bone*, central nervous system* | VBL, CST | | | 3 yr/AD, better (1) |
| 26 | M | 2 yr | skin* | | | | 2 yr/Active, diagnosis (2) |
| 27 | F | 9 yr | skin* | | | | 9 yr/Active, diagnosis (2) |
| 28 | M | 3 yr | bone* | VBL, CST | | | 3 yr/AD, better (1) |
| 29 | M | 18 mo | bone* | VBL, CST | | | 3 yr/AD, better (1) |

| Patient | Sex | Age at diagnosis | Organs involved in the disease course (until latest study) | Chemotherapy received (until latest study) | Paper I Age at study start/Disease activity (class [#]) /Sequelae | Paper III Age at study /Disease activity (class [#])/Sequelae | Paper V Age at study /Disease activity (class [#])/Sequelae |
|---------|-----|------------------|--|--|---|---|---|
| 30 | F | 17 mo | skin*, lymph node*, bone* | CST | | | 19 yr/AD, chronic (1)/coxarthrosis |
| 31 | F | 7 yr | bone* | | | | 7 yr/Active, diagnosis (2) |
| 32 | M | 2 yr | bone* | VBL, CST | | | 3 yr/AD, better (2) |
| 33 | F | 4 yr | bone* | | | | 5 yr/ NAD (0) |

In **paper III** an additional 10 paraffin imbedded tissue samples from the Netherlands were investigated with immunofluorescence for the presence of IL-17A (7 bone, 3 skin) and 10 tissue samples from Sweden (6 bone, 3 skin and 1 lymph node), taken at diagnosis, were investigated for the presence of herpes viruses. Three of the patients whose lesions were examined were later sampled for blood in **paper III** (pat 2, 16 and 19) and three (2, 6 and 16) were sampled for blood in **paper V** while two (6 and 7) were sampled for CSF in **paper I**. In **paper V** paraffin imbedded tissue samples from 2 patients were analyzed for the presence of BCL2A1. One of these patients (34) was also sampled for blood in this paper.

Chemotherapy at study: Paper I: Patients 1, 2, 5, 6 and 7 had ongoing chemotherapy during the study. **Paper III:** Patients 1, 2, 10, 11, 12, 14 and 16 had ongoing chemotherapy during the study. **Paper V:** Patients 2, 6, 16, 20, 22, 23, 24, 25, 28, 29 and 32 had ongoing chemotherapy during the study.

Abbreviations: (Disease state categories in this table have been adjusted for all patients according to LCH-IV.) 2CdA, Cladribine; 6-MP, 6-mercaptopurine; AD, active disease (better, regression of signs/symptoms, no new lesions; chronic, chronic disease; stable, persistence of signs or symptoms, no new lesions; worse, progression of signs or symptoms and/or appearance of new lesions); ARA-C cytarabine; CNS symptoms, clinical CNS symptoms of variable character and degrees; CST, corticosteroids; DI, Diabetes insipidus; GHD, Growth hormone deficiency; IVIG, intravenous immunoglobulin; MTX, methotrexate; NAD, no active disease, resolution of all clinical signs and symptoms; PH, panhypopituitarism; VBL, vinblastine; VP-16, etoposide.

#Disease activity classes: (→, sampled two or three times) 0, resolution (no signs of active disease); 1, mild (regression of active disease or mild chronic disease; no hypoalbuminemia or ESR elevation); 2, moderate (moderately active disease; mild thrombocytosis, hypoalbuminemia, or ESR elevation); 3, marked (progressive disease or constant markedly active disease; marked hypoalbuminemia or ESR elevation); 4, life-threatening disease; *indicates organ involved at diagnosis; §CNS neurodegeneration evidenced by MRI.

3.2 MATERIAL AND METHODS

3.2.1 CSF sampling and MRI evaluation

In **paper I**, CSF was collected at the time of lumbar puncture, centrifuged for elimination of cells, and the supernatant separated into smaller portions immediately frozen to -20° C. The samples were transported in a frozen state to the laboratory where the analyses were carried out. Samples were collected from the LCH patients 4.6-12.8 years after the LCH diagnosis.

The patients in **paper I** were investigated by MRI prior to and following CSF sampling. The most recent MRI prior to the first CSF sampling was performed at a median age of 9.5 years (range 5.4-18.7 years). The CSF sampling was performed 0-6 months after the MRI (median 2 months). The next MRI was performed 2-22 months (median 9 months) after the CSF sampling. The MRI pictures were examined by a neuroradiologist who was blinded to the results. The severity of neurodegeneration was graded by the neuroradiologist where MR-level “+” (mild) indicates increased signal in the basal ganglia and nucleus dentatus (T1 weighted) and locally increased signal (T2-weighted) in the cerebellar white matter, predominantly in connection with the nucleus dentatus. MR-level “++” (moderate) includes the findings of MR-level “+” and, additionally, abnormally increased signal in the brainstem, thalami and corpus calosum. MR-level “+++” (severe) includes the findings in MR-level “++” and, in addition, subcortical and periventricular white matter and gray matter changes. Consecutive MRI examinations were compared and the development of MRI changes over time was classified as “Regression or status quo” or “Progression”. Correlations between CSF biomarker values and the extension of MRI abnormalities, changes of MRI over time and relation to disease activity outside CNS were made.

In four of the nine patients CSF sampling was repeated at least once, two of these patients were sampled repeatedly over a period of 19 and 15 months, respectively.

3.2.2 Blood samples and synovial fluid

All experiments in **paper IV** were carried out on blood samples from healthy adult blood donors. Controls in **paper III** and **V** also consisted of blood samples from healthy adult blood donors. Synovial fluid from six patients with rheumatoid arthritis served as a positive control for IL-17A in **paper III**. In **paper III**, blood samples from 13 patients with LCH, from Sweden (n = 7) and Italy (n = 6), were obtained. In **paper V** blood samples from 19 patients with LCH (11 males and 8 females), from Sweden (n = 8) and Italy (n = 11) were included.

3.2.3 Tissue samples

In **paper III** immunohistological studies were carried out on 10 paraffin embedded tissue samples (3 from skin and 7 from bone) from Dutch patients with LCH. Another 10 tissue samples (6 from bone, 3 from skin and 1 from a lymph node) from as many Swedish patients with LCH were examined with regard to the presence of herpesviruses. In **paper V** immunohistological studies were carried out on two paraffin embedded LCH tissue samples (bone) from Sweden.

3.2.4 Cell cultures

Considering the fact that LCH is such a rare disease and the scarcity of freshly available lesional cells, as well as the low circulating numbers of DCs in peripheral blood, DCs derived from monocytes constitute an alternative approach to study the effects of cytokines and other substances on DCs that might be of relevance in LCH. The role of monocytes as precursors of DCs *in vivo* has been established as previously outlined (Cheong et al., 2010, Segura et al., 2013) and the relevance in LCH is further supported by the recent findings pointing at a potential myeloid precursor of LCH DCs (Allen et al., 2010a, Hutter et al., 2012, Merad et al., 2008).

In **papers III, IV and V**, CD14⁺ monocytes were purified from the peripheral blood of LCH patients or healthy controls by ficoll and percoll gradients, followed by negative magnetic depletion of cells expressing CD3, CD56 or CD19. CD1a⁺ CD83⁻ immature monocyte-derived DCs were generated *in vitro* after 6 days of culture with GM-CSF (50 ng/ml) and IL-4 (500 U/ml) as presented by Rivollier *et al.* 2004 (Rivollier et al., 2004).

DCs were seeded in concentrations of 1,600–4,800 cells/mm² in α -MEM (Life Technologies) supplemented with 10% fetal calf serum (FCS), 2 mM L-glutamine, 100 U/ml penicillin and 100 μ g/ml streptomycin (Life Technologies) in the presence of medium only, M-CSF, GM-CSF, RANKL, TNF- α , IL-17A and IFN- γ solely or in combinations. Cytokines were replenished every week. IL-17A-dependent fusion activity in serum samples from LCH patients was studied by investigating fusion efficiency in healthy DCs after 12 days' culture with IFN- γ and 5% serum from either healthy donors or patients with LCH, followed by addition of blocking antibodies against IL-17A or IFN- γ , respectively. In the experiments evaluating the effect of chemotherapeutic compounds on IL-17A and IFN- γ treated healthy mo-DCs, drugs were added either concomitantly with cytokines, or 24 hours later.

To evaluate the source of IL-17A in serum from LCH patients, lymphocytes were also purified from the blood and T cells activated by a combination of antibodies to CD3 and to the co-stimulator CD28.

3.2.5 DC survival and fusion efficiency studied after TRAP and Hoechst staining

In long term cultures, surviving DCs became adherent and fused to form MGCs. Fixation of these adherent cells and staining with Tartrate resistant acidic phosphatase (TRAP) and Hoechst double staining was used in **paper III** and **paper V** to visualize the cytoplasm and the nuclei respectively. The total number of nuclei in viable mono or multi-nucleated (strictly > 2 nuclei) cells, per well and over time, was counted. This permitted us to calculate percentages of surviving cells at different time points as well as the fusion efficiency, defined as the percentage of nuclei inside giant cells.

3.2.6 Flow cytometry analyses (FACS)

Flow cytometers use laser light to characterize particles in a stream of homogenous fluid. The particles can be characterized and sorted according to size and density as well as to fluorescence that can be manipulated by fluorescent antibodies bound to intra- or extracellular molecules whose presence and amounts can then be investigated.

In **papers III-V** flow cytometry was used for a number of purposes ranging from cell phenotype characterization and evaluation of production of IL-17A and other proteins to assessment of viability and proliferation. A drawback of this method (as with all methods using antibodies to detect molecules) is that the binding of antibodies may not be specific. Complimentary experiments to detect cytokine mRNA (RT-PCR) in the cells can be of value in this context. On the other hand, the mere detection of mRNA does not prove that there really are elevated levels of the protein since there might be discrepancies between transcription and translation of the protein (Raqib et al., 1996, Schindler et al., 1990). MRNA is also easily destroyed if samples are not treated correctly. Western blot provides an alternative method to detect cytokines and other molecules in tissues or cells. To confirm that a molecule detected by intracellular flow cytometry staining is really secreted, analyses to show the molecule in the cell supernatant should ideally be performed.

3.2.6.1 Extra- and intracellular stainings

Immunostaining was performed in 1% bovine serum albumin (BSA) and 3% human serum- phosphate buffered saline (PBS). For intracytoplasmic staining we blocked the Golgi apparatus with BD GolgiStop TM, fixed and permeabilized the cells with 0,33% saponin for 30 minutes. Fluorescence was quantified on an LSRII (Becton Dickinson) and analyzed using FlowJo software.

3.2.6.2 CFSE and CD14-PE labeling for proliferation study

Through the carboxyfluorescein diacetate succinimidyl ester (CFSE) assay it is possible to evaluate cell proliferation by flow cytometry by following the serial halving of the fluorescence intensity of the vital dye CFSE. With this technique 8-10 of discrete cell

divisions can be visualized. An advantage of this technique is that one can mark the cells with other surface markers to track modifications as the cells divide and it is also possible to sort out vital cells to perform functional analyses, in contrast to other proliferation assays that usually measures proliferation at a population level (Lyons, 2000).

To evaluate if DCs treated with IL-17A proliferated, in **paper IV**, DCs were suspended at 10^7 cells/mL in α Minimum Essential Medium (α -MEM) containing 2% FCS. After 15 minutes of incubation in the presence of $10\mu\text{M}$ CFSE, the CFSE incorporation was blocked by the addition of a large excess of α -MEM, containing 2% FCS. DCs were then washed twice by centrifugation at 1500 rpm for 10 minutes at 4°C in α -MEM containing 2% FCS and seeded in α -MEM containing 10% FCS with indicated cytokines. Cells were then harvested on day 7 by trypsin treatment (Sigma-Aldrich) and scraping, and finally immunostained with a CD14-PE antibody. The expression of CD14-PE and CFSE was quantified on an LSRII (Becton Dickinson) and analyzed using FlowJo software.

3.2.6.3 *DiOC6 and PI labeling for cell survival quantification by flow cytometry*

3,3'-dihexyloxycarbocyanine iodide (DiOC6) is a fluorochrome that stains intact mitochondria and is thus specific for viable cells (Zamzami et al., 1995). Propidium iodide (PI) is incorporated in the DNA of dead cells whose cell membranes have been permeabilized. Living cells are thus DiOC6^+ , PI $^-$.

Between day 0 and 7, > 95% of the IL-17A-treated DC were mononucleated and generally not adherent, available for flow cytometry analysis. In **paper IV** and **V**, DiOC 6 and PI double staining followed by flow cytometry analysis was used to evaluate the effects of IL-17A, with or without IFN- γ , on the survival of DCs from healthy donors and the survival of DCs from LCH patients compared to DCs from healthy controls. DiOC 6 and PI double staining was also used to evaluate the effect of 17 different chemotherapeutic compounds on IL-17A and IFN- γ -treated healthy DCs.

Cells were incubated 15 min at 37°C with 40 nM DiOC 6 (Molecular Probes) in culture medium. The total number of viable cells per well was quantified by a time-monitored flow cytometry analysis. As the cells were found not to proliferate, the number of viable cells at day 7 were compared to the initial number of cells introduced at day 0, and the percentage of remaining viable cells calculated. Likewise, the percentage of cell death was compared for IL-17A and IFN- γ treated DCs exposed to different chemotherapeutic compounds compared to DCs treated with cytokines only at different time points (0, 4, 24, 48, 72 h).

3.2.6.4 *Functional analysis of mannose receptor (MR)-mediated endocytosis*

To evaluate functional properties of IL-17A-treated monocyte-derived DCs (mo-DCs), in **paper V**, the endocytotic capacity of DCs was analyzed with dextran FITC, a probe for MR-mediated endocytosis. As, in addition to receptor-mediated endocytosis, there

is some uptake of dextran FITC by pinocytosis, preincubation with mannan was performed to block the MR-mediated endocytosis and separate MR-mediated endocytosis from the background fluorescence of dextran FITC uptake by pinocytosis. Cells were cooled down in an ice water bath. Studies were performed at 0, 10 and 30 min by re-warming the cells in a water bath to 37° C in the presence of dextran FITC (1 mg/ml), or a 10 min pre-incubation with mannan (1 mg/ml) followed by dextran FITC (1 mg/ml). For quantitative evaluation of the receptor density, two-dimensional dot plot analysis was performed for the respective monocytes, mo-DCs, and these DCs treated with IL-17A for 7 days. Populations were gated out manually. The mean fluorescence intensity (MFI) of the FITC signal was determined and fluorescent dye uptake was quantified by calculating the fluorescent index (FI) for the different time points: $FI = [MFI(10,30 \text{ min}) - MFI(0 \text{ min})] / MFI(0 \text{ min})$. This normalization procedure was used to compensate for donor variability.

3.2.7 Methods to detect soluble molecules in serum and supernatants

Enzyme-linked immunosorbent assays (ELISAs) are commonly used antibody based assays to detect molecules in liquid samples. ELISAs were used in **papers I and III**. In **paper I**, CSF from all LCH patients was analyzed with regard to GFAP, NF-L and total TAU (normal and phosphorylated) using sandwich ELISAs as described previously by Prof. Rosengren and his team (Blennow et al., 1995, Rosengren et al., 1992, Rosengren et al., 1996). The analyses were carried out at the Clinical Neurochemistry Laboratory in Mölndal, Sweden, as part of their routine clinical test panel. Controls samples were analyzed for NF-L (110) and GFAP (108). For all CSF analyses of all the LCH patients except two, an assay with an NF-L detection level of 125 ng/L was used. In the remaining two cases some of the samples were analyzed with a higher dilution of the secondary antibody leading to a higher detection level of NF-L (250 ng/L).

3.2.7.1 Reference values for biomarkers in the CSF

As lumbar puncture is rarely performed in healthy children there is a lack of reference values for CSF biomarkers in children. Thanks to collaboration with Prof. Lars Rosengren and his colleagues in Gothenburg we were able to use a large set of CSF samples taken from children with ALL, with no signs of neurological involvement and prior to therapy, as controls with regard to GFAP and NF-L (Osterlundh et al., 2008).

The detection level of GFAP was 32 ng/L. The mean GFAP concentration in this group was 177 ng/L (SD 98 ng/L, median 159 ng/L, range 16–488 ng/L, n=108), corresponding to a mean value +1 SD of 275 ng/L and a mean value +2 SD of 373 ng/L. Based on the mean value of our ALL controls and their +2 SD levels and the established laboratory reference level (175 ng/L), the GFAP reference level in the current study was set at 275 ng/L (precisely 274 ng/L). Importantly, the GFAP content was not correlated to age ($r=0.04$) in our controls.

For NF-L, the detection level of the assay used for the controls was 125 ng/L. The NF-L content was below the detection limit of 125ng/L in all the 110 ALL control CSF samples and the laboratory defined all values above this level as pathological.

TAU was previously studied at our laboratory in 15 healthy young individuals aged 17–37 years and the CSF levels were all ≤ 250 ng/L (mean 143 ng/L, SD 74 ng/L). Accordingly, TAU levels >250 ng/L were considered abnormal in our pediatric patient cohort. This is in line with a Dutch study reporting an upper 95% confidence interval for TAU in healthy children to 178 ng/L (Van Gool et al., 2000). Since TAU levels have been reported to be age dependent in adults there have been concerns regarding whether there are also differences within the pediatric population (Sjogren et al., 2001). However, it has been reported that TAU levels in the CSF are not age-dependent in children aged 0–18 years (Van Gool et al., 2004). TAU was not analyzed in the ALL controls.

In **paper III** we measured the amounts of IL-17A, RANKL and IL-22 in serum and cell culture supernatants with commercial ELISA kits (PeproTech). The amounts of IL-1 β , TNF- α and MMP-9 and MMP-12 were measured with the multiplex assays (R&D Systems and Becton Dickinson). An advantage of multiplex analysis to ELISA is that, although still much more expensive, several molecules can be analyzed simultaneously from a sample of similar size. This also allows for multiple correlation studies to be done more easily.

3.2.8 IL-17A/anti-IL-17A IgG autoimmune complex titration of serum

In **paper III**, an experiment to capture potential antibodies against IL-17A in serum from LCH patients was set up. The anti-human-IL-17A of the commercial ELISA kit described earlier was used to coat ELISA Nunc Maxisorp microplates overnight. Serum samples from LCH patients were then added to the wells and incubated for 2 h before three washes, whereupon addition of a goat anti-human IgG-Fc γ -antibody coupled to peroxidase was added for 30 minutes. After three washes the ABTS Liquid substrate solution (Sigma) was introduced. Color development was then monitored by reading the plate every 5 minutes for 20 minutes. The experiment was repeated with the addition of recombinant human IL-17A in the saturating concentration of 5 ng/mL to specifically separate the immune complexes.

3.2.9 Immunohistochemical techniques

Compared to conventional microscopes, confocal microscopy allows for better optical resolution and reconstruction of three dimensional structures. It is often used in combination with immunofluorescence, where primary antibodies directed towards molecules in the sample are revealed by fluorochromes either directly coupled (primary immunofluorescence) or indirectly coupled to anti-isotype secondary antibodies (secondary, or indirect, immunofluorescence). These fluorochromes emit light of

specific wavelengths that can be read and quantified. An advantage of this technique compared to traditional histochemistry is that double or triple marking of cells is possible.

In **papers III** and **V** immunofluorescence and confocal microscopy analyses were carried out on paraffin embedded biopsies to investigate whether IL-17A and BCL2A1 could be detected in LCH lesions and linked to LCH DCs.

Two different protocols were used. For the IL-17A detection, 4- μ m biopsy sections were deparaffinized and exposed to heat-mediated antigen-retrieval in a microwave using citrate buffer (10 mM, pH 6.0) and then incubated with primary antibodies overnight at 37°C in PBS-1% BSA. For the BCL2A1 detection 4- μ m paraffin-embedded bone and skin biopsies were deparaffinized and rehydrated. Following epitope retrieval, tissue sections were incubated 30 minutes in PBS-1% BSA with 3% human serum to block Fc receptors. They were then incubated with primary antibodies, overnight at 37°C. Replacement of the primary antibodies by non-relevant antibodies of the same immunoglobulin isotype was used as a negative control. Slides were then washed three times in PBS-1% BSA. In the IL-17A protocol, slides were incubated for 15 minutes in PBS-1% BSA with 10% normal goat serum to block unspecific binding. Detection of the primary antibodies was performed with suitable isotype-specific secondary Alexa Fluor 488, 546 and 647-conjugated antibodies (Invitrogen, 10 μ g/mL) for 30 min. Following three washes in PBS-1% BSA, sections were mounted using Mowiol and then analyzed by confocal microscopy using a Carl Zeiss MicroImaging Inc. LSM 510 confocal microscope. Image acquisition was performed using MetaMorph 7.0 Software (Molecular Devices).

In **paper IV** immunofluorescence techniques were also used to study the modifications induced by IL-17A on the cytoskeleton of mo-DCs transforming into MGCs and the effect of vinblastine (VBL), known to affect the microtubule network, on these cells.

3.2.9.1 Immunocytofluorescence labeling of p65/RelA

In **paper IV** the intracellular signaling pathway for IL-17A-mediated induction of *BCL2A1* was investigated through studying nuclear translocation of the nuclear factor p65/RelA, a member of the NF- κ B transcription factor family expressed in immature DC and a known regulator of *BCL2A1* expression (D'Souza et al., 2004).

Mo-DCs were cultured in the 8-well Lab-Tek TM Chamber Slide TM System (Nunc, Thermo Scientific) and the cellular location of p65/RelA before and after stimulation with IL-17A was investigated. At the indicated times, the chamber slides were gently centrifuged and cells were fixed in PBS with 4% paraformaldehyde for 30 min at 4° C. Cells were permeabilized with PBS, 0.2% Triton X-100 for 20 minutes at room temperature. After saturation (30 minutes at room temperature in PBS-1% BSA, 3% human serum), cells were incubated 2 h with 4 μ g/mL anti-p65/RelA in PBS-1% BSA (C20, Santa Cruz Biotechnology, CA). After three washes in PBS-1% BSA, cells were

incubated 30 minutes at room temperature in the dark with Alexa Fluor 647 Goat anti-rabbit IgG (10mg/mL, Molecular Probes, Invitrogen, CA). Finally, after three washes, cells were mounted in Dako Fluorescent Mounting medium (Dako, Denmark), and immunostaining images were analyzed using a Leica TCS-SP5 laser scanning confocal microscope (Leica, Wetzlar, Germany).

The effect on p65/RelA translocation by the NF- κ B inhibitor Bay-11-7085 was also investigated.

3.2.10 Affymetrix genechip study, microarray analysis

Microarray analyses have become widely used in the last decade to characterize mRNA expression patterns in subsets of cells. We purified RNA from mo-DCs derived from LCH patients or healthy controls, either untreated (LCH patients and healthy donors) or cultured for 12 days with IL-17A alone, or in combination with IFN- γ (healthy donors), after cell lysis, extraction in Trizol (Invitrogen) and purification on a MEGAclear column (Ambion) to reach an RNA integrity number > 9 with Agilent bioanalyser. ProfileXpert (<http://www.profilexpert.fr>) carried out the chip study.

3.2.11 Real-time quantitative PCR

In **paper IV**, RT-PCR was used to verify IL-17A induction of BCL2A1 mRNA indicated in the transcriptome analysis. Total RNA from 2 million cells was extracted using Trizol[®] (Invitrogen) and RNeasy Mini Kit[®] (Qiagen, Düsseldorf, Germany) to reach an RNA integrity number > 9 with the Agilent bioanalyzer. RT-PCR reactions were performed with Super Script[®] II Reverse Transcriptase (Invitrogen). One μ g total RNA was reverse-transcribed using oligo(dT)₁₂₋₁₈ Primers (Invitrogen). For expression studies, 25 ng of cDNA were amplified in Stratagene Mx3000P apparatus (Agilent Technologies), using the QuantiTect[®] SYBR[®]Green PCR Kit (QIAGEN). Primer sequences were as follows: BCL2A1, ACA GGC TGG CTC AGG ACT ATCT (forward), CTC TGG ACG TTT TGC TTG GAC (reverse); GAPDH, CAC CCA CTC CTC CAC CTT TGAC (forward), GTC CAC CAC CCT GTT GCT GTAG (reverse); TBP, QuantiTect primers specific Hs_TBP_1_SG QuantiTect Primer Assay (Qiagen). All samples were normalized to expression of GAPDH or TBP.

In **paper III**, RT-PCR experiments were run to examine paraffin embedded tissue samples from 10 LCH lesions, 2 peripheral blood lymphocyte samples and 11 serum samples from LCH patients for the eight known human herpesviruses (HSV-1, HSV-2, VZV, EBV, CMV, HHV-6, HHV-7 and HHV-8) (Lundberg et al., 2006). We also constructed a PCR to detect Herpesvirus Saimiri (HVS) polymerase DNA. The PCR was constructed as a nested PCR involving two steps. A first step was performed with an outer forward primer: ACA CTA GAG GGT GCG AGC G and outer reverse primer: TAT GTT GTA AGG TGG CCA TTC for 20 cycles. Then a second set was performed with an inner forward primer: AAA TTT AGC CCA TCT TGT GC and an

inner reverse primer: GAG GAC ATG CAG ACT TAC AT for 40 cycles. The PCR product responded to a 250 base pair long fragment. A positive control was kindly provided by Armin Essner (Institut für Klinische und Molekulare Virologie, Erlangen, Germany) in the form of a cosmid, Cosmid 261, containing the full sequence of HVS polymerase and HVS viral IL-17A. It was positive down to 21 viral copies for HVS polymerase detection. Since HVS encodes a viral homolog of human IL-17A, 1 lesion and 6 peripheral blood lymphocyte samples from LCH patients were also analyzed for the HVS IL-17A DNA. The Cosmid 261 was positive down to 10 viral copies for HVS IL-17A detection.

3.2.12 Western blot analysis

Western blot analysis was used in **paper III** to validate the mRNA findings of BCL2A1 and MCL1 on the protein level. Three million cells were harvested, sonicated and lysed for 1 h at 4° C with RIPA buffer containing a protease inhibitor cocktail (Roche, Indianapolis, USA). Cellular debris were pelleted by centrifugation (10,000 g 15 min at 4° C) and protein extracts (100 µg per lane) were loaded on to a 12% SDS-polyacrylamide gel and blotted onto PVDF sheet (Bio-Rad Laboratories, Hercules, CA). Filters were blocked with 5% BSA in PBS/0.1% Tween 20 (PBS-T) for 2 h and then incubated over-night at 4° C with anti-BCL2A1/BFL1, 0.9 µg/mL in PBS-T (rabbit polyclonal ab75887, Abcam, Cambridge, UK). After three washes with PBST, filters were incubated 1 h with Biotin-conjugated goat antirabbit IgG, 2 µg/mL in PBS-T, 5% BSA (Molecular Probes/Invitrogen, Eugene, OR). After three washes with PBST, filters were incubated 1 h with HRP-conjugated Streptavidin (StrepTactin-HRP, Bio-Rad Laboratories, Hercules, CA,) dilution 1:50,000 in PBS-T, 5% BSA. Detection was performed using Immun-Star™ WesternCTM Kit chemiluminescence system (Bio-Rad Laboratories, Hercules, CA,). Actin staining was realized using a rabbit polyclonal anti-βActin from SantaCruz (sc-130656, Santa Cruz, CA,) to calibrate the samples.

3.2.13 Statistical analyses

Paper I: The CSF levels of biomarkers for the control group (GFAP and NF-L) were compared to those of the patients with neurodegenerative LCH. TAU was not analyzed in the controls. Comparison of GFAP was performed with the nonparametric Mann–Whitney U test. With regard to NF-L, for which many values were below the minimal detection level, Fisher’s exact test was used to compare values that were above the detection levels in controls and patients, respectively. Fisher’s exact test was also used to analyze if there was any association between neuromarker concentrations and disease activity outside the CNS (“No active disease” and “Active disease,” including chronic disease and progressive disease). For this test the neuromarker concentrations in the CSF were categorized as below or above the reference values presented above. Further, the course of radiological ND over time was categorized into two categories (“status quo or regression” and “progression”), and the differences in neuromarker

levels between the two categories were analyzed by Mann–Whitney U tests. The association between neuromarker levels and extension of radiological ND (mild, moderate, severe) was studied by Spearman’s rho. Correlations between the neuromarkers were analyzed by Pearson’s correlation test.

Paper II: The odds ratio (OR) for the children born following IVF to develop LCH were calculated by comparing the risk of LCH in the group of children born following IVF to the risk of LCH in the general population as found in the Stockholm County study. Differences in disease characteristics between children with LCH born after IVF and children with LCH in the general population were calculated by Fisher’s exact test except for age at diagnosis, which was calculated by the Mann–Whitney U test.

Paper III-V: Linear or polynomial statistical analyses and Mann-Whitney U test from GraphPad Prism 5 software were applied to detect correlations and differences between subgroups; $p < 0.05$ was regarded significant.

3.2.14 Chemotherapeutic compounds

Drugs used in **paper IV** and **V** were kindly provided by the Karolinska University Hospital pharmacy except for dexamethasone, 6-mercaptopurine and fludarabine, which were purchased from Sigma Aldrich (St Louis, MO, USA). The drugs used in the study are presented in **Table IV**. A rough estimate of the magnitude of the microenvironment concentration around cells, *in vivo*, following administration of clinical doses, was calculated by approximating that the drug could be distributed in half of the body aqueous volume (30L) with the formula: [(injected concentration) x injected volume] / 30. The results were also compared to those indicated by pharmacokinetic studies.

Table IV. Cytotoxic drugs tested on IL-17A and IFN- γ treated mo-DCs (papers IV and V)

| | |
|---------------------------------------|---|
| Glucocorticoids | hydrocortisone methylprednisolone prednisolone betamethasone dexamethasone |
| Calcineurin inhibitors | cyclosporine A tacrolimus |
| Purine analogues | cladribine 6-mercaptopurine fludarabine |
| Pyrimidine analogue | cytarabine |
| Folate acid antagonist | methotrexate |
| Organometallic complex, purine linker | cisplatin |
| Vinca alkaloids | vinblastine, vincristine |
| Anthracycline antibiotic | doxorubicine |
| Topoisomerase II inhibitor | etoposide |

4 RESULTS AND DISCUSSION

Studying rare diseases has its limitations in terms of available patient material and the possibility to strictly follow optimal study designs. The Histiocyte Society is crucial to the coordination of international collaboration efforts and to drive LCH research forward. Nevertheless, small studies from individual centers, in spite of their shortcomings, are also important to improve knowledge of LCH and generate ideas for further studies.

4.1 BIOMARKERS TO DETECT ONGOING NEURODEGENERATION IN LCH

As outlined in the introduction the exact incidence of neurodegenerative disease in patients with LCH is unknown. However, many studies have indicated that the incidence is higher than previously expected (Grois et al., 2010, Haupt et al., 2004, Laurencikas et al., 2011, Willis et al., 1996, Bernstrand et al., 2005, Mittheisz et al., 2007).

MRI is currently the standard diagnostic tool used to detect or confirm neurodegeneration in LCH. The relationship between radiological neurodegeneration and overt clinical symptoms is still not fully clarified. Neurodegenerative MRI findings may sometimes precede clinical symptoms, probably reflecting the reserve capacity of the human brain. Still, neurodegeneration in LCH seems to be a slowly progressive process and when MRI findings are present substantial neuronal loss is likely to already have occurred. It is unknown what initiates the neurodegenerative process in LCH or what drives it to progress to fatal disease in some cases while it seemingly halts in others. Nor do we know how this process can be efficiently stopped. The histopathological pattern, however, suggests that chronic inflammation contributes to the neuronal injury (Grois et al., 2010, Grois et al., 2005). Risk factors to develop neurodegeneration include lesions in the craniofacial bones, intracranial lesions, DI, multisystem LCH and long standing disease activity (outside the CNS) (Donadieu et al., 2004b, Grois et al., 2010, Grois et al., 2006, Haupt et al., 2004).

In line with the evidence from multiple sclerosis that early treatment is important to minimize the consequences of the disease (Khademi et al., 2013), methods to detect signs of *ongoing* neurodegenerative disease early on could also be of high value in LCH. Even if there is currently no specific treatment for neurodegenerative LCH, this could help to evaluate effects of systemic or experimental therapy more rapidly than is possible with MRI. Investigating biomarkers in the CSF of patients with neurodegenerative LCH might also help us to better understand the underlying process.

In **paper I** we evaluated the findings of three biomarkers (TAU, GFAP and NF-L) in the CSF from nine LCH patients with radiological signs of neurodegeneration in addition to endocrine, neuromotor, cognitive and/or behavioral abnormalities. The patients were investigated by MRI prior to and following CSF sampling. One of these patients had not received any systemic treatment in line with previous reports, indicating that neurodegeneration in LCH is not induced by therapy.

Table V. Neuromarkers in children with LCH and radiological signs of neurodegeneration

| Patient | GFAP* | NF-L* | TAU* | Extension of radiological neurodegeneration at LP [#] | Course of radiological neurodegeneration** | Clinical CNS symptoms/ endocrine dysfunction |
|---------|------------|------------|------------|--|--|--|
| 1 | 400 | <125 | 340 | ++ | 0 | Hypothalamic symptoms, cognitive impairment/PH |
| 2 | 500 | 310 | 430 | +++ | + | Neurological symptoms (ataxia, tremor)/DI, GHD |
| 3 | 310 | <125 | 310 | + | 0 | Neuropsychological abnormalities |
| 4 | 480 | <125 | 130 | ++ | + | DI |
| 5 | 280 | 270 | 570 | ++ | + | Neuropsychological abnormalities |
| 6 | 420 | <125 | 320 | ++ | 0 | Neuropsychological abnormalities/PH |
| 7 | 510 | <125 | 830 | ++ | + | DI |
| 8 | 170 | 150 | 260 | + | + | Neuropsychological abnormalities, DI, GHD |
| 9 | 420 | 150 | 180 | + | 0 | DI, GHD |

*Pathological values in bold text. Reference values: GFAP > 275 ng/L, NF-L > 125 ng/L, TAU > 250 ng/L; **Course of radiological neurodegeneration from previous MRI: “0”: status quo, “+”: progression [#] Extension of radiological neurodegeneration at lumbar puncture: “+”: Increased signal in basal ganglia and nucleus dentatus (T1-weighted) and locally increased signal (T2-weighted) in the cerebellar white matter, predominantly in connection with nucleus dentatus, “++”: As “+” and in addition abnormally increased signal in brainstem, thalami and corpus callosum, “+++”: As “++” and in addition subcortical and periventricular white matter and gray matter changes; DI: Diabetes insipidus, GHD: Growth hormone deficiency; PH: Panhypopituitarism.

As described in the background we chose the three neuromarkers mentioned above because they are well established markers proven to be helpful in the diagnosis and monitoring of other neurodegenerative and neuroinflammatory diseases, including multiple sclerosis, ALS, Alzheimer disease, Parkinson disease and vascular dementia and to evaluate acute brain damage such as stroke (Blennow et al., 1995, Blennow et al., 2001, Rosengren et al., 1996, Wallin et al., 1996, Teunissen et al., 2005, Aurell et al., 1991). They also reflect damage to different components of the CNS; while GFAP is a marker of astroglial cell damage, NF-L and TAU reflect neuronal damage.

All patients in our study had increased levels of at least one biomarker compared to the reference values presented in section 3.2.7.1. Biomarkers were elevated in eight (GFAP), seven (TAU) and four (NF-L) out of nine patients, respectively. Since our patient group was small it was not possible to carry out extensive statistical analyses with reliable results. However, when comparing mean values between patients and controls, the LCH patients had significantly higher values of GFAP and NF-L than the controls. TAU was not analyzed in the control group. GFAP levels correlated with the extension of MRI changes in our patient group, which may reflect the active role of astrocytes in inflammation and repair of brain tissue (Osterlundh et al., 2008). No such correlation could be seen with NF-L or TAU. NF-L on the other hand tended to correlate to progression of MRI changes, although this could not be proven to be statistically significant.

The most severely ill patient, who deteriorated during the study period both clinically and radiologically, had the highest values of NF-L and GFAP. She underwent repeated CSF sampling and MRI investigations during the study period. All her CSF markers were elevated compared to reference values and controls throughout the whole study period, suggesting that elevation of these markers is a reproducible finding. However, repeated, markedly high NF-L levels, was the most explicit finding and, preliminarily, it appears to us as if elevated NF-L levels in patients with *ongoing* neurodegeneration is the most alarming sign.

As pointed out in the material and method section, reference values regarding neuromarkers in CSF are scarce. One may argue that the patients in the control group were not completely healthy (newly diagnosed ALL patients without signs of CNS disease), but NF-L values were below detection level for all patients in the control group. The results for GFAP were somewhat higher than previously reported in a small cohort of 10 healthy children (Rosengren et al., 1992). At the time of our study no other references regarding healthy children were available for comparison and the children with LCH as a group had higher values than the control group. Importantly, the GFAP or NF-L content in our controls was not correlated to age. Neither TAU has been previously reported to be age dependent in the pediatric population (Van Gool et al., 2000).

A recently published multi-center, retrospective study compared CSF biomarkers in patients with different neurological disorders to patients investigated for various symptoms that concluded in diagnoses seemingly not involving the CNS (transient headache, diffuse pain, suspected infections or habitual walking changes) (Shahim et al., 2013). In that study a weak correlation to age was seen for all the neuromarkers used by us (NF-L, TAU, and GFAP). If this finding is confirmed it will be important to take into consideration in future studies. However, to us, the most important finding of the study was that a clear difference in neuromarker levels, especially for NF-L, was observed between progressive and stable encephalopathy. This strengthens the potential of these neuromarkers to be used as indicators of ongoing neurodegeneration in LCH.

Notably, in spite of lumbar puncture being carried out according to routine procedures by experienced physicians using fine needles, in our study, more patients than expected suffered complications after CSF sampling. These included severe headache and in one case a prominent spinal fluid leakage. The reasons for the increased risk of complications are unclear. The intracranial pressure (ICP) was not measured in the study and thus we do not know whether this might have contributed to spinal fluid leakage. However, one can also speculate as to whether inflammation-induced changes in the dura might predispose for complications.

Our study included a very small number of patients and should be regarded as a pilot study. The results indicate that patients with neurodegenerative LCH have elevated levels of at least one CSF biomarker and that NF-L, TAU and GFAP analyzed together may be useful to detect *ongoing* neurodegeneration in LCH. However, further studies are needed to evaluate the relationship between these biomarkers and the progression of neurodegeneration versus the accumulated CNS damage, as well as their relationship to clinical symptoms. Consistent with previous reports, we did not see any case of regression of the neurodegenerative MRI findings although the progression seemed to halt in some patients. (Prosch et al., 2007, Wnorowski et al., 2008). It would, however, be interesting to do a long-term clinical and radiological follow-up study of the children in our study group to further evaluate the natural course of neurodegeneration.

Within the LCH-IV study protocol, we and McClain's group, plan to carry out studies on CSF as optional studies. Considering the inflammatory nature of neurodegenerative lesions in LCH it would be interesting to study not only neurodegenerative markers in CNS but perhaps also inflammatory markers as indicators of ongoing inflammation. Although pathological in sporadic cases, the CSF of the children in our study did not typically show pathological values of markers often used clinically to diagnose CNS inflammation, such as albumin, leukocytes or oligoclonal bands. This might reflect that the process is usually a rather low grade, but constant, inflammatory process. Dramatic flares are uncommon. It also underlines the need for other CSF markers. CSF markers that have been used in some neuroinflammatory diseases and that could be of interest to investigate in LCH are for example CCL2 (MCP-1), CXCL13, MMP-9, Osteopontin,

and IL-17A, of which the three last molecules have also been described in LCH lesions. To evaluate a broad panel of markers that could be of interest, multiplex studies, or even proteomics, on CSF might be considered.

As neurodegeneration in LCH has been suggested to be a paraneoplastic phenomenon it might also be interesting to study anti-neuronal antibodies in the CSF of a larger set of patients with neurodegeneration. Such antibodies could include the anti-glutamate receptor antibody, GluRe2, or perhaps anti-purkinje cell antibodies (anti-Yo) as seen in cerebellar degeneration in for example breast cancer or other gynecological malignancies. The presence of specific auto-antibodies could provide an explanation as to why the neurodegeneration in LCH follows specific radiological patterns. However, this could perhaps also partly be explained by the vulnerability of these areas in terms of collateral blood supply. Speculatively, the unspecific symptoms experienced by some patients with neurodegenerative LCH, like headache, tiredness and dizziness might be attributed to cytokine production.

IL-17A is thought to be of importance in the pathogenesis of multiple sclerosis (Lock et al., 2002, Matusevicius et al., 1999, Zhang et al., 2003). In **papers III-V** we investigated different aspects of IL-17A that might be of relevance in the pathogenesis of LCH. Possibly, in LCH, IL-17A and other cytokines in the circulation contribute to inflammation of the meninges and disruption of the blood brain barrier, allowing the influx of inflammatory substances and inflammatory cells into the CNS, as has been shown in multiple sclerosis (Kebir et al., 2007). This could trigger and sustain an inflammatory process leading to neuronal damage and eventually neurodegeneration. Our findings support a survival-promoting effect of IL-17A on DCs as will be explained further on. However, IL-17A in synergy with TNF- α has been shown to induce apoptosis in oligodendrocytes (Paintlia et al., 2011). The discrepancy could perhaps be explained by the well-known fact that IL-17A has different roles in different cell types, and might be of relevance to the neurodegeneration seen in LCH. One may also speculate that antibodies directed against IL-17A, or against an IL-17A-like substance, might cross-react with neuronal factors, mimicking a paraneoplastic process.

4.2 LCH IN CHILDREN CONCEIVED BY IVF

To understand the etiology of LCH, epidemiological studies may be of value. The aim of **paper II** was to confirm the findings of Källén *et al.* indicating that LCH was overrepresented in Swedish children born following IVF 1982-2005 (Källén et al., 2010, Källén et al., 2005). We wanted to verify the diagnoses, and examine whether any specific form of LCH was more common in the children conceived by IVF than in the general population.

Upon reviewing the medical records for the eight children identified in the registers (until 2008 in our case) seven cases were confirmed to have LCH. One patient turned

out to have been wrongly registered in the Patient Register/Hospital Discharge Register as LCH while the actual diagnosis was retinoblastoma (C69.2). Of the seven remaining cases, six had a definite diagnosis of LCH and were included in the National Cancer Register. One child had a presumptive diagnosis of LCH with a clinical picture fitting well into LCH but with repeated biopsies that were not fully conclusive, possibly because they were taken late in the course of LCH.

Compared to children in the Stockholm County study the OR to develop LCH for all the 26 692 children conceived by IVF was 3.2 [95% confidence interval (CI) 1.4-7.3]. Interestingly, all children were born prior to 2002. For the first cohort of 16 280 children studied by Källén *et al.*, born 1982-2001, the OR was 5.2 [95% CI 2.3-11.9]. There was obviously no increased risk to develop LCH in the subsequent cohort of children born 2002-2005. Intracytoplasmic sperm injection (ICSI), used mainly in male infertility and much more common in the second cohort, does thus not appear to have affected the rate of LCH in the offspring.

Table VI compares children affected by LCH, conceived respectively not conceived by IVF. Due to the risk of personal identification the data of this group of children cannot be presented individually.

The reference group was chosen since it included children of similar ethnic and environmental background, and it was carried out on children born during approximately the same period of time. Compared to other studies, a higher incidence of LCH among the children (0-15 years of age) in our reference group was previously reported (Stalemark *et al.*, 2008). Apart from this, characteristics were in line with other studies (Carstensen and Ornvold, 1993, Salotti *et al.*, 2009). The information on neurodegenerative findings in this population stems from a separate study by our group on CNS involvement in LCH (Laurencikas *et al.*, 2011). Since the groups are not matched and one (children born following IVF) is based on year of birth and the other (controls) on year of diagnosis (1992-2001) one should be cautious in interpreting the results. However, our study shows that the overrepresentation of LCH in children conceived by IVF was not due to misdiagnosis or overrepresentation of mild forms of the disease. Perhaps of relevance, the children with LCH conceived by IVF were younger at diagnosis than the children in the Stockholm County study, early onset being a known risk factor for severe forms of LCH (Gadner *et al.*, 2008).

Bearing in mind that an abundance of variables was studied in the original publication by Källén *et al.*, it could be argued that the correlation between IVF and LCH for children born 1982-2001 is only a random finding related to statistical mass significance. One could also argue that since IVF has gradually become more common, the rate of LCH should increase in the follow-up cohort of children born 2002-2005 if there was a true connection between LCH and IVF, which was not the case. In this context, one could also consider the lack of difference in fertility between mothers of children with LCH and controls reported by Hamre *et al.* (Hamre *et al.*, 1997). Neither

has it been reported in previous studies focusing on cancer risk in children conceived by IVF that LCH occurs more frequently in children born following IVF. However, it is not clear whether LCH has been included in these studies (Bruinsma et al., 2000, Klip et al., 2001). Yet, there might also be important information underlying the discrepancy observed between the cohorts in our study.

It is difficult to separate potential effects of the IVF procedure from effects imposed by drugs used in the IVF treatment and from underlying maternal (or paternal) characteristics. Due to ethical considerations we were not able to gather information on the reasons for IVF in each specific case or information on which therapies that had been used, nor did we have any information on underlying diseases in the mothers or on inherited conditions. In the children's medical records one mother was reported to have hypothyroidism, which may be of interest considering the previously reported connection between LCH and thyroid disease. With regard to infections, it is interesting to note that around the year 2000 synthetic gonadotropins began to substitute the use of gonadotropins extracted from the urine of pregnant women on a large scale (Huirne et al., 2004). One may speculate that an unknown substance might have been enriched in this extraction process, transmitted to the women and passed on to the fetus.

There is also the possibility that the IVF procedure or IVF treatment might impose genetic or epigenetic changes in the embryo. IVF treatment and assisted reproductive technologies (ART) in general have indeed been associated with epigenetic modifications that may affect fetal growth or development (Khosla et al., 2001). Genomic imprinting is an epigenetic mechanism causing only one allele of a gene to be silenced by DNA methylation or other epigenetic modifications. This is a prerequisite for many genes to function physiologically but it sometimes also results in pathological processes, i.e. imprinting disorders. For many years there has been a concern that IVF and ICSI might lead to an increase in imprinting disorders. Some imprinting disorders, including Beckwith-Wiedemann syndrome, have been reported to occur more frequently in children following IVF (Cox et al., 2002, DeBaun et al., 2003, Odom and Segars, 2010, Sutcliffe et al., 2006). Retinoblastoma is a neoplastic disease that, in several case reports and small studies, has been reported to be overrepresented in children conceived by IVF (Anteby et al., 2001, Lee et al., 2004, Marees et al., 2009). As hypermethylation, leading to inactivation, of the tumor suppressor gene *RB1* has been shown to play a role in retinoblastoma development, aberrant imprinting could also be a possible mechanism of IVF-associated retinoblastoma (Manipalviratn et al., 2009). However, several population-based studies have not been able to demonstrate a correlation between IVF and retinoblastoma (Bradbury and Jick, 2004, Foix-L'Helias et al., 2012, Lidegaard et al., 2005) and it was recently shown that hypermethylation of the *RB1* promoter is not responsible for tumor development in children with retinoblastoma and conceived by IVF (Dommering et al., 2012). In the Swedish material there were two cases of malignant eye neoplasms reported against one expected (Källén et al., 2010).

Epigenetic changes inherited, or occurring in the embryo, may be relevant in the pathogenesis of LCH, considering the reported cases of familial disease and the known association between malignancies on the one hand and the absence of mutations (apart from BRAF V600E) on the other (Arico and Danesino, 2001, Arico et al., 1999, Egeler et al., 1998, Egeler et al., 1993b). Relating to the findings of IL-17A in LCH presented later in this discussion, it may be interesting to note that increased endometrial secretion of several cytokines, including IL-17A, has been documented after the use of ART when comparing stimulated to normal ovulatory cycles, which might affect the embryo (Boomsma et al., 2010).

As described in the introduction no association with LCH and birth complications or low birth weight has been seen (Carstensen and Ornvold, 1993). Consistent with this, in spite of the well-known association between IVF and preterm delivery and children being small for gestational age (SGA) (Jackson et al., 2004), there were no reports in our material of neonatal complications, or low birth weight, with the exception of one child being born preterm.

The findings of **paper II** support a, possibly temporary, overrepresentation of LCH in children born following IVF which was not due to over-diagnosis of mild forms of the disease. However, we suggest that the possible association between LCH and IVF should be investigated in independent studies in other countries. Should the correlation between IVF and LCH be confirmed, further studies should be undertaken to investigate whether the cause is related to the IVF procedure, ART drugs used in the IVF treatment, or underlying characteristics of the mothers explaining the subfertility.

Table VI. Comparison between children affected by LCH, conceived respectively not conceived by IVF

| | Children with LCH conceived by IVF (n=7) | Children with LCH not conceived by IVF* (n=27) | P value[#] |
|--|---|---|----------------------------|
| Median age at diagnosis | 2.0 years | 4.3 years | 0.15 |
| Sex: | | | |
| Male | 3 (43%) | 15 (56%) | 0.68 |
| Female | 4 (57%) | 12 (44%) | |
| Extension at diagnosis: | | | |
| Single system | 4 (57%) | 19 (70%) | 0.66 |
| Multisystem | 3 (43%) | 8 (30%) | |
| Maximal extent of disease [§] : | | | |
| Single system | 1 (14%) | 14 (52%) | 0.10 |
| Multisystem | 6 (86%) | 13 (48%) | |
| Risk organ involvement at maximal extent of disease [§] : | | | |
| Yes | 1 (14%) | 5 (19%) | 1.00 |
| No | 6 (86%) | 22 (81%) | |
| Endocrine sequelae ^{**} : | | | |
| Yes | 2 (33%) | 5 (19%) | 0.58 |
| No | 4 (67%) | 22 (81%) | |
| Neurodegenerative MRI findings ^{**†} | | | |
| Yes | 2 (33%) | 6 (22%) | 0.62 |
| No | 4 (67%) | 21 (78%) | |
| Treatment: | | | |
| Systemic | 5 (71%) | 12 (44%) | 0.40 |
| Local or wait-and-see | 2 (29%) | 15 (56%) | |

*Children <15 years in Stockholm County treated for LCH 1992-2001 with children born after IVF (two) excluded (Stalemark et al., 2008); [#]P values calculated by Fisher's exact test, except for age at diagnosis which was calculated by Mann-Whitney test; [§]Maximal extent of disease includes all organs that have been involved during the disease course (Bernstrand et al., 2005); ^{**}Missing long-term data in one patient; [†]For neurodegenerative MRI findings in children with LCH, see (Laurencikas et al., 2011).

4.3 A POSSIBLE ROLE FOR IL-17A IN LCH

4.3.1 Initial findings of IL-17A in LCH (paper III)

As stated by Peters *et al.*, LCH is in many ways a disease that is difficult to study (Peters et al., 2011). Apart from being a rare condition there are no validated *in vitro* or animal models. Research has to rely to a high extent on analyses of frozen or paraffin embedded tissue samples. Interpretation of data is also difficult since there is a lack of standardized control tissues (tissue samples or LCs from normal skin or dermatopathic lymphadenopathy containing “normal” LCs have been used in many studies, more seldom normal bone tissue has been used as controls). Working on Langerin/CD207 or CD1a sorted cells from fresh LCH lesions has its limitations because this process takes several hours which may affect the function of the cells. By sorting the cells by either Langerin/CD207 or CD1a it is also possible that all LCH DCs are not captured. As an alternative approach, we set out to study mo-DCs from LCH patients. This could allow experiments to be carried out on a larger scale. Support for this approach can be found in the growing body of evidence of a myeloid origin of the LCH DCs (DC progenitors or even monocytes), as described in the background (Allen et al., 2010b, Hutter et al., 2012, Merad et al., 2008). At the time this was however an original approach.

RANKL is important for osteoclast formation and stimulation of osteolysis and the RANK-RANKL axis has been shown to be active in LCH (da Costa et al., 2005, Ishii et al., 2006). It is known that IL-17A up-regulates RANKL in osteoblasts (Kotake et al., 1999) and the similarities between LCH and many other chronic inflammatory disorders where IL-17A is known to be involved in the pathogenesis, including bone destruction and granuloma formation, provided the rationale to study the role of IL-17A in LCH more closely.

In **paper III**, IL-17A was measured in serum from LCH patients. We found that IL-17A levels were increased in serum from patients with active LCH compared to controls, although, importantly, no correlation to disease activity or disease extension (MS LCH or SS LCH) could be made to IL-17A levels in serum. By immunofluorescence and confocal microscopy we then also demonstrated IL-17A in bone and skin lesions from LCH patients. Triple staining showed that IL-17A was associated with only a few T cells but instead overwhelmingly with CD1a⁺, and Langerin/CD207⁺ cells, as well as MGCs, indicating that IL-17A in LCH serum and lesions might originate from DCs rather than T cells.

This was further supported by analysis of cell populations from peripheral blood. In contrast to T cells that expressed and secreted IL-17A at levels similar to controls following proper stimulation, a proportion of mo-DCs from LCH patients spontaneously stained positive for intracellular IL-17A by flow cytometry, and secreted IL-17A into the supernatant as measured by ELISA. Indications that cells other than T cells are the major source of IL-17A in LCH were also obtained by the lack of IL-22 in

serum from these patients. IL-22 is normally secreted in parallel to IL-17A from Th17 cells (Harrington et al., 2005, Park et al., 2005). We did not see any IL-17A production in monocytes from the six patients whose monocytes were analyzed in this study. To our knowledge this is the only disorder where IL-17A production has been described in DCs. However, in recent years, IL-17A production has been described in a number of cells belonging to the innate immune system (Cua and Tato, 2010, Sutton et al., 2012). Moreover, in two other granulomatous diseases of unknown origin, Crohn's disease and sarcoidosis, IL-17A production has been described in myeloid cells defined as macrophages, in addition to T cells (Facco et al., 2011, Fujino et al., 2003). Whether IL-17A production from DCs in LCH (or perhaps myeloid cells in related granulomatous diseases in general) reflects a physiological process, or is pathogenic, has still not been answered, as will be elaborated upon below.

Interestingly, we also found that mo-DCs from LCH patients responded to autocrine or paracrine IL-17A production. They spontaneously started to undergo cell fusion after 6-8 days in culture (reaching a plateau phase after 10-12 days) to form long-lived MGCs and this process was dependent on IL-17A since antibodies against IL-17A turned out to block it in contrast to antibodies against IFN- γ . However, IFN- γ potentiated cell fusion.

The MGCs in LCH lesions are still of unknown origin. These MGCs express CD68 and sometimes also CD1a (da Costa et al., 2005). To a varying degree, depending on the site of the lesion, they also express osteoclast markers, e.g. vitronectin receptor (VPN), cathepsin K, TRAP and MMP-9, and have been suggested by da Costa *et al.* to be derived from the fusion of immature DCs upon RANKL and M-CSF stimulation (da Costa et al., 2005). Fusion upon stimulation by IL-17A might be an alternative or additional origin of MGCs in LCH lesions. This is supported by our findings that IFN- γ , which is present in LCH lesions, stimulated cell fusion along this pathway in contrast to in the M-CSF and RANKL pathway where cell fusion was inhibited by IFN- γ (Takayanagi et al., 2000). As it was shown that IFN- γ inhibited M-CSF and RANKL cell fusion by inhibiting TRAF6, important also in the classically described IL-17A signaling pathway, IL-17A signaling inducing cell fusion and cell survival of DCs may be mediated through the alternative, TRAF6 independent, pathway.

Although serum levels of IL-17A did not correlate with disease activity, the grade of IL-17A-dependent fusion did. Using a biological assay measuring the fusion activity of healthy mo-DCs exposed to LCH serum and specific for IL-17A, we found a correlation between disease severity and fusion activity. The biological assay is important because with ELISA we may capture, perhaps not only free IL-17A, but also IL-17A bound to other molecules, or post-translationally modified IL-17A, not knowing whether it is active or not. To our knowledge no soluble receptor, antagonizing IL-17A signaling, has been described *in vivo*, although soluble forms of the IL-17RC have been identified in protein studies (Haudenschield et al., 2002). Alternatively, the degree of IL-17A receptor expression, and thus the sensitivity

towards IL-17A, may vary between patients, as has later been demonstrated by Murakami *et al.* (Murakami et al., 2012).

Notably, we detected the presence of immune complexes directed against IL-17A in the serum of LCH patients, indicating either excessive production of the molecule or an immunogenic variant of canonical IL-17A. Since there is a viral homologue to IL-17A, expressed by the Herpesvirus Saimiri, known to infect some primate species (*Callithrix jacchus* and *Saguinus oedipus*) where it might induce T cell lymphoma, we also analyzed tissue and serum samples for the presence of Herpesvirus Saimiri and other viruses of the herpes group. However, in line with results from previous studies, these analyses did not imply any virus of the herpes group in the pathogenesis of LCH. The role of a possible, yet unidentified virus in the pathogenesis of LCH can of course still not be excluded.

4.3.2 Effects of IL-17A on immature monocyte-derived DCs from healthy donors

Spurred by the findings in LCH we continued to study how IL-17A modified immature mo-DCs from healthy donors. Independently of the LCH context this might also be relevant to other diseases where IL-17A may have a central role. We confirmed that IL-17A induces fusion of immature mo-DCs from healthy donors into MGCs, a process augmented by, but not dependent on IFN- γ (or TNF- α). This finding has since then been confirmed by others and is thought to contribute to aberrant osteoclast formation in multiple myeloma (Tucci et al., 2013). It is well known that IL-17A works in synergy with other inflammatory cytokines and the functions of IL-17A are often studied in combination with other cytokines such as TNF- α (Onishi and Gaffen, 2010). In contrast to the combination of M-CSF and RANKL, IL-17A did not induce fusion in monocytes. This could, however, be achieved by the addition of GM-CSF which is present in LCH lesions (Egeler et al., 1999). Similarly to in the M-CSF and RANKL pathway of cell fusion, LPS-matured DCs did not fuse in the presence of IL-17A.

In **papers III** and **IV**, we further elaborated on how IL-17A affected mo-DCs in various ways. **Paper III** focuses on the pro-inflammatory characteristics of these cells while **paper IV**, focuses on how IL-17A affects the viability of mo-DCs and potentially sustains DC function in a tumoral microenvironment. At the base of our observations was a transcriptomic analysis comparing IL-17A-treated mo-DCs to unstimulated mo-DCs. We then tried to confirm these initial observations by additional methods for key events.

Interestingly, phenotype analysis of IL-17A-treated DCs showed that they shared many characteristics with LCH DCs. They acquired a semi-mature, mixed macrophage-DC phenotype expressing CD14, CD68, CD1a, MHC-II and CCR6 and they were CD40^{high}. Like the MGCs in LCH lesions, MGCs induced by IL-17A expressed high levels of tissue destructive enzymes such as TRAP, MMP-9 and MMP-12.

IL-17A-treated mo-DCs also showed some similarities with M2 macrophages known to promote tumor growth in several ways as outlined in the background (e.g. by secretion of tissue degrading enzymes, promotion of angiogenesis and inhibition of adaptive anti-tumor responses through induction and recruitment of Tregs and by keeping DCs in an immature state) (Mantovani et al., 2013, Sica et al., 2008). IL-17A-treated mo-DCs expressed high levels of mRNA for M2-related molecules such as CCL22, CD206, CD163 and an IL-1 receptor antagonist, IL-1RA. However, they did not express cytokines known to be associated with M2 macrophages such as IL-4, IL-10 or IL-13 and thus resembled “pre-M2 macrophages-DCs” rather than traditional M2 type macrophages. Nor did they secrete M1 cytokines such as IFN- γ , IL-1 β or IL-12.

The role of IL-17A in cancer is controversial with pro-tumor versus anti-tumor effects described, as presented in the background. IL-17A and prostaglandin E2 (PGE2) have previously been shown to contribute to M2 differentiation of macrophages recruited to the tumoral microenvironment in lung cancer. However, in that study the driving force for M2 differentiation was attributed to PGE2 rather than to IL-17A (Liu et al., 2012).

Since DCs are central in priming and activating T cells they may either stimulate anti-tumor responses or conversely induce tumor cell tolerance by several mechanisms. When DCs fight against cancer cells, they prime T cells, promoting the differentiation of tumor specific CTLs. On the other hand, when DCs are skewed towards contributing to tumor development, not only are they incapable of priming T cells, but they also induce Tregs and stimulate angiogenesis. *In vivo*, the net effect of several cytokines is likely to determine the function and phenotype of DCs in the microenvironment of a tumorous or inflammatory (infectious) lesion. Interestingly, LCH lesions are characterized by a pro-inflammatory, still ineffective immune response. A high number of regulatory T cells have been demonstrated in the lesions, suggested to contribute to the failure of the host to eliminate LCH DCs (Senechal et al., 2007). IL-17A-treated DCs expressed both RANKL and CCL22. It has been shown in breast tumors that CCL22 attracts regulatory T cells (Gobert et al., 2009) and this function has also been demonstrated for RANKL in the skin (Loser et al., 2006). IL-17A secreted from LCH DCs (or other cells in the lesion) might thus be one explanation for Tregs in LCH lesions. Together with IL-10, IL-4 and other immunosuppressive cytokines demonstrated in the lesions (Egeler et al., 1999, Geissmann et al., 2001), IL-17A may contribute to an impaired clearance of the LCH DCs due to tolerance induced by T regs.

4.3.3 IL-17A increases viability of mo-DCs from healthy donors

It was noted already in **paper III** that IL-17A prolongs survival of healthy mo-DCs enabling them to undergo fusion after 6-8 days. In **paper IV**, we further verified this increased viability and investigated the mechanisms behind it. Compared to lymphocytes, not so much information has been published on what sustains survival in human immature dendritic cells that are normally short lived (up to 48 h for mo-DCs

cultured in medium alone *in vitro*). We used information collected in the transcriptome analysis to identify pro-apoptotic and pro-survival genes that were expressed differently in these groups and that might be of importance for IL-17A-induced survival of mo-DCs. Of the pro-survival BCL2 family members, unstimulated cells expressed only *MCL1*, insufficient to maintain survival for longer periods of time. In contrast, exposure to IL-17A led to significant up-regulation of another pro-survival gene, *BCL2A1*. *MCL1* was still highly expressed but to a lower degree. These findings were verified at protein level with FACS and Western blot. While IFN- γ did potentiate IL-17A induced DC fusion, it did not affect survival or expression of *BCL2A1* either at mRNA or protein level.

Myeloid cell leukemia sequence 1 (*MCL1*) was first discovered as a pro-survival member of the BCL2 family in a human myeloblastic leukemia cell line (Kozopas et al., 1993). B-cell lymphoma 2 related protein A1 (*BCL2A1*), is mainly expressed in B cells but has been described as being overexpressed in several hematological as well as non-hematological malignancies including B cell chronic lymphocytic leukemia (B CLL) and AML, where expression of *BCL2A1* correlates with chemoresistance and poor prognosis (Feuerhake et al., 2005, Monti et al., 2005, Morales et al., 2005, Simpson et al., 2006, Olsson et al., 2007). However, transgenic mice do not develop lymphomas indicating that *BCL2A1* alone is not sufficient to promote tumorigenesis (Chuang et al., 2002).

Both *BCL2A1* and *MCL1* have been shown to be of importance for increased survival of myeloid cells such as macrophages and neutrophils in response to various inflammatory molecules (Ottina et al., 2012, Marsden and Strasser, 2003). In DCs, up-regulation of *BCL2A1* has been shown to occur in response to LPS or BCG (Ishii et al., 2005).

In our studies, silencing of *BCL2A1* through introduction of siRNA was not possible since this resulted in DC maturation. Neither were we able to find any suitable inhibitor of *BCL2A1*. Thus, we have not been able to definitively prove that the pro-survival effect seen with IL-17A is dependent on *BCL2A1*. Intracellular expression of *BCL2A1* and IL-17A showed a clear correlation, as did *BCL2A1* expression to survival. Still, it is possible that other mechanisms might contribute to the IL-17A-mediated survival. The pro-apoptotic genes, *BCL2L1* and *BID* were expressed at low levels in unstimulated cells in our transcriptome analysis and their amounts decreased with about fifty percent after treatment with IL-17A. Additionally, there might be other genes affecting cell survival that we have not studied.

The p65/RelA protein is a member of the NF- κ B transcription factor family known to regulate *BCL2A1*, and expressed in immature DCs. IL-17A-dependent induction of *BCL2A1* was shown to be mediated through the NF- κ B pathway by investigating the cellular location of the p65/RelA protein in untreated DCs and DCs treated with IL-17A. Further, addition of the NF- κ B inhibitor Bay-11-7085 blocked *BCL2A1* mRNA

induction by IL-17A. It has previously been shown that the balance between NF- κ B and JNK/AP-1 activity controls apoptosis in DCs (Kriehuber et al., 2005) where JNK-AP1 is under negative feedback control of NF- κ B. Thus, this pathway may also contribute to the increased survival of IL-17A treated DCs.

In **paper IV**, we further investigated the effects of chemotherapeutic drugs and corticosteroids on the survival of IL-17A and IFN- γ -treated mo-DCs. This might be of interest in many disorders where IL-17A has been implied in the pathogenesis, including both cancers and chronic inflammatory disorders. Given that pathological DCs are the key target for chemotherapy in LCH and that our previous results indicate a role for IL-17A in LCH, it might be of specific interest in LCH. The agents tested targeted corticosteroid receptors, calcineurin, DNA synthesis, topoisomerase II and microtubules.

A high expression of BCL2A1 has previously been associated with chemoresistance to fludarabine and etoposide in progressive lymphocytic leukemia cells or a cell line from fibrosarcoma *in vitro* (Morales et al., 2005, Wang et al., 1999a) and different sensitivity towards doxorubicin and etoposide has also been reported in freshly generated DC (Chao et al., 1999). In line with these results, the cells in our model were, to different degrees, resistant to a variety of the agents tested including glucocorticoids, fludarabine, etoposide, 6-mercaptopurine, methotrexate and the calcineurin inhibitors cyclosporine A and tacrolimus. Nevertheless, drugs that exerted a killing effect within the tested concentrations were VBL, vincristine, doxorubicin, cisplatin, ARA-C and 2-CdA. The threshold for killing mediated by doxorubicin, cisplatin and 2-CdA corresponded to high doses, exceeding therapeutic doses. Ara-C was also efficient in high doses while VBL and vincristine killed at more moderate doses.

Our *in vitro* system was of course reductionist regarding what happens in the body where bioavailability differs and enzymatic modifications of drugs take place. This could perhaps explain why we observed variable effects for drugs with similar mechanisms of actions. Still, it might provide a hint on how IL-17A-stimulated DCs respond to different drugs. It is interesting to note that VBL, which is the basis of the first line treatment in LCH, was also revealed to be efficient in our model. Moreover, high-dose ARA-C together with 2-CdA has been reported to have favorable results in the treatment of severe LCH in the LCH Salvage 2005 protocol (Bernard et al., 2005), and these drugs will also be used in the salvage regimen of LCH-IV. Furthermore, in LCH-IV, a combination of low-dose ARA-C and vincristine will be evaluated as a second-line treatment for non-risk LCH.

To study whether VBL or ARA-C mediated degradation of BCL2A1 or MCL1, we performed western blots and found that these drugs mediated a decrease in MCL1 levels but did not affect BCL2A1 expression. Interestingly, it has recently been shown that vincristine, acting through mechanisms similar to VBL, mediates degradation of MCL1 (Wertz et al., 2011). Our study extends these results to also include VBL.

Additionally, immunofluorescence experiments demonstrated that VBL also disrupted the microtubule network in IL-17A treated DCs fused into giant cells.

Our results show that neither BCL2A1 nor MCL1 alone are sufficient to keep DCs alive. We conclude that both MCL1 and BCL2A1 are necessary to sustain long term survival of IL-17A-treated DCs.

4.3.4 Increased survival of monocyte derived DCs from LCH patients is linked to up-regulation of BCL2A1

Since the proliferation rate of LCH DCs is normally considered to be low (Brabencova et al., 1998, Senechal et al., 2007) it has been proposed that recruitment of pathogenic DCs or increased survival of LCH DCs may be responsible for the accumulation of LCH DCs in the lesions. Based on the findings of **papers III and IV**, in **paper V**, we investigated whether BCL2A1 expression might also contribute to increase viability of LCH DCs. We studied whether BCL2A1 was expressed in LCH lesions and whether it could be detected in mo-DCs from patients with LCH.

We confirmed that mo-DCs were resistant to spontaneous apoptosis compared to DCs from healthy donors by studying survival of these cells at day seven with flow cytometry analysis and DiOC6/PI. Using immunofluorescence and confocal microscopy we found that BCL2A1 protein was present in mononuclear CD1a⁺ cells as well as MGCs in LCH lesions from bone. Further, in contrast to DCs from healthy donors, BCL2A1 expression nicely paralleled IL-17A expression in mo-DCs from LCH patients as assessed by both transcriptome analysis and FACS intracellular staining at mRNA and at protein levels respectively. Two different antibodies against IL-17A were tested and gave the same results. BCL2A1 levels correlated to the degree of survival. This indicates that BCL2A1 up-regulation is due to IL-17A stimulation also in LCH. Yet, as *BCL2A1* is known to be up-regulated in DCs by LPS and BCG (Ishii et al., 2005), signals other than IL-17A may induce BCL2A1 expression in LCH lesions, *in vivo*.

As for healthy DCs it was not possible to block BCL2A1 directly. However, blocking IL-17A impaired both BCL2A1 expression and DC survival. Interestingly, VBL and anti-IL-17A antibodies acted synergistically to kill mo-DCs from LCH patients, allowing for lower doses of VBL to be used and overcoming the resistance to VBL that was noted in the DCs from one patient.

BCL2 has previously been reported to be expressed in LCH lesions (Savell et al., 1998, Schouten et al., 2002). We did not see any up-regulation of BCL2 in mo-DCs from LCH patients but we did on the other hand not examine the LCH lesions for this protein and it could be induced by other cytokines in the lesions *in vivo*. Our findings of BCL2A1 in LCH lesions might be supported by the increased expression of *BCL2A1* also in the LCH derived CD207⁺ cells compared to normal LCs in the transcriptome

analysis performed by Allen *et al.* (Allen et al., 2010b). Many of the pro-survival and pro-apoptotic molecules previously detected in LCH lesions were not otherwise found to be expressed or up-regulated in this transcriptome analysis. Instead, the authors noted a high expression of the pivotal inflammatory cytokine osteopontin (expressed by the gene *SPPI*) compared to Langerin/CD207⁺ cells from the skin. As suggested by Allen *et al.*, osteopontin might be another cytokine of interest to study further since it has also been associated with granuloma formation, cell survival, T cell activation and induction of Tregs (Wang and Denhardt, 2008).

4.3.5 Is there really any IL-17A in LCH?

Since **paper III** was published there has been a lively debate as to whether IL-17A does or does not play a role in LCH. McClain's group investigated the presence of IL-17A mRNA and IL-17A protein in Langerin/CD207⁺ cells, CD1a⁺ cells and T cells derived directly from LCH lesions without being able to demonstrate the presence of IL-17A (Allen and McClain, 2009, Peters et al., 2011). They concluded that IL-17A was not present in LCH lesions and suggested that unspecific binding of antibodies might explain our findings of IL-17A. However, their studies leave many questions that remain to be answered and do not exclude a role for IL-17A in LCH.

Firstly, as described in the background, a central problem in LCH research all along has been the difficulties to reproduce data. Differences in patient samples, cell types, the handling of material, techniques or interpretation of results may explain the discrepancies in results. As has been pointed out, several proteins previously reported to be present in LCH lesions were not found to be expressed in the transcriptome analysis performed by McClain's group (Allen et al., 2010b). Their findings are strengthened by the fact that they did not detect any IL-17A mRNA in CD1a or Langerin/CD207⁺ cells from LCH lesions in contrast to in T cells from tonsils using PCR on a separate set of samples (Peters et al., 2011). However, IL-17A mRNA might still be present in these cells but in low concentrations and thus not detected, or degraded upon sample processing including cell sorting. An alternative approach to minimize degradation of mRNA due to sample handling could be to perform *in situ* hybridization, to detect IL-17A mRNA in LCH lesions.

Peters *et al.* used western blot to test the specificity of the antibodies against IL-17A used in our study. With this method they failed to demonstrate IL-17A in either LCH lysates or tonsil lysates (serving as their physiological positive control) with the PeproTech antibodies used by us for ELISA (PeproTech 500-P07G). On the other hand, the R&D Systems antibodies (R&D Systems 41802) that we used for intracellular staining (FACS and immunohistochemistry) strongly bound to a protein corresponding to the same size as IL-17A in both LCH lysates and tonsil lysates. Nevertheless, Peters *et al.* argued that this was a nonspecific protein since they could not identify any IL-17A peptides by massspectromery analysis in this band. However, this may result from material limitation because they did not identify this band at all,

again nor in the tonsil lysates. In conclusion, they challenged the specificity of a commercial antibody used in several papers without really proving that it is unspecific. By contrast we used two different antibodies to identify IL-17A by immunofluorescence inside the LCH lesions, the monoclonal antibody mentioned above (R&D Systems 41802) and a polyclonal goat antibody (R&D Systems AF-317-NA).

Studies from different groups have rendered different results with the same or different ELISA kits and multiplex methods regarding IL-17A in serum from LCH patients compared to healthy donors (Makras et al., 2012, Peters et al., 2011, Murakami et al., 2012).

Differences in subgroups (age, gender etc.) of patients and controls could account for these differences. It should be noted that some of our patients received chemotherapy at the time of sampling as reported in the paper. This might have influenced IL-17A levels and measurements should ideally be performed in newly diagnosed patients. However, history has also shown that it is difficult to study cytokines, which are normally short-lived molecules, in serum, especially if the receptors are widely expressed, as is the case with IL-17RA. Illustrating this point, during the 1990's, conflicting results regarding the serum levels of TNF- α were reported in patients with rheumatoid arthritis, although time has shown that TNF- α is indeed of major importance in this disease where many patients benefit from TNF- α inhibitors (Corvetta et al., 1990, Saxne et al., 1988).

Different ELISA kits bind to different epitopes of cytokines which may result in different specificity. Since IL-17F share some homology with IL-17A one may wonder if there is any cross reactivity with this cytokines in spite of what is promised by the manufacturers. However, we have measured IL-17F in LCH serum with antibodies specific for IL-17F without finding any IL-17F (unpublished data) speaking against this explanation to be accountable for the discrepancies noted. Another possibility is that physiologically or pathologically modified molecules are recognized to different degrees by different antibodies.

Secondly, and to the best of our knowledge not yet approached by any other team, is the capacity of mo-DCs from LCH patients to fuse and form long-lived MGCs in contrast to mo-DCs from healthy donors. In our system this process was specifically blocked by neutralizing antibodies against IL-17A. This demonstrates a role of this cytokine, or an IL-17A-like molecule with similar biological activity, perhaps corresponding to a genetically modified form of IL-17A or a molecule of exogenous origin, to be involved in the fusion mechanism. The IL-17A fusion capacity correlated to the disease severity. Interestingly, Murakami *et al.* recently reported that the expression of IL-17RA is higher in LCH DCs from patients with MS LCH than in patients with SS LCH, indicating that the level of receptor expression may also account for the amplitude of the response to IL-17A. Murakami *et al.* further suggest an

endocrine mode of action of IL-17A as they did not detect IL-17A protein in LCH DCs by mass spectrometry. However, only one sample was explored after laser capture microdissection of CD1a⁺ cells of the lesion.

The similarities to IL-17A related chronic inflammatory disorders, in terms of granuloma formation (IBD), bone resorption (RA) and neurodegeneration (multiple sclerosis) and the effects of IL-17A on mo-DCs from healthy donors make it plausible that IL-17A is somehow involved in the pathogenesis of LCH. Still, there is the risk of an “Emperor’s New Clothes” phenomenon, i.e. that we see what we want to see, and all new findings should legitimately be questioned. Several other cytokines also have the potential to explain many of the pathological characteristics of LCH lesions, including RANKL (osteoclastogenesis, Treg accumulation), TNF- α (induction of pro-inflammatory molecules e.g. RANKL), GM-CSF (prolonged DC survival) or osteopontin (cell survival, granuloma formation) to mention just a few. Thus, it will be of great interest to follow further independent studies regarding the role of IL-17A in LCH.

Provided that a role of IL-17A and BCL2A1 in LCH is confirmed, targeting BCL2A1 or IL-17A activity in LCH might be worth considering. Among the new generation of anti-cancer drugs, small molecule inhibitors (SMI), that are under development, Obatoclax and Sabutoclax have been shown to target MCL1 or, MCL1 and BCL2A1, respectively (Nguyen et al., 2007, Wei et al., 2009). Sorafenib, developed as a BRAF inhibitor, has been shown to reduce MCL1 translation, leading to increased apoptosis in leukemia cells, and might be of special interest in LCH, considering the role that BRAF has been assigned in recent research (Rahmani et al., 2007).

Monoclonal antibodies directed against cytokines such as TNF- α , IL-1 β and IL-6 have been in clinical use in the treatment of autoimmune and chronic inflammatory disorders for many years now. As the detrimental effects of cancer-associated inflammation are becoming clearer, there are also several ongoing studies targeting cytokines and their receptors (such as CSF-1R, the receptor for M-CSF and IL-34) in various cancers (Biswas et al., 2013).

Several clinical trials regarding inhibition of IL-17A are ongoing for various chronic inflammatory disorders, evaluating various IL-17A specific antibodies such as secukinumab and ixekizumab. There are also trials currently underway using an antibody, brodalumab, against the IL-17A receptor IL-17RA. Besides psoriasis (phase II completed, III ongoing), promising results have been reported for rheumatoid arthritis (phase II completed, III ongoing) and multiple sclerosis (phase II ongoing) (Deiss et al., 2013, Kellner, 2013, Miossec and Kolls, 2012). However, clinical trials of secukinumab and brodalumab failed to ameliorate symptoms in patients with Crohn’s disease, even leading to worsened symptoms in some patients (Miossec and Kolls, 2012). This, again, stresses that it is not clear whether IL-17A is the cause or a consequence of the disease in granulomatous disorders of unknown origin. Thus any

future trial aiming at inhibiting IL-17A in LCH should be carefully and cautiously considered.

The etiology of LCH remains to be revealed. The involvement of IL-17A in LCH is only one track among many others to study. Still, during recent years many steps to better understand the pathogenesis of the disease have been made and models embracing inflammatory aspects as well as neoplastic aspects of its origin are arising. As indicated by the results of Murakami and colleagues, LCH might perhaps be understood as a premalignant inflammatory disorder where cells with an underlying mutation, or perhaps a genetic variation in for example IL-17RA expression, overreact to infectious or other environmental stimuli. This might lead to inflammation and up-regulation of survival pathways of LCH DCs, in turn favoring pro-survival mutations, and allowing for the accumulation of LCH granulomas (Murakami et al., 2012). As stipulated early on by our team, the potential role of myeloid DC progenitors rather than LCs as precursors for LCH DCs is now becoming increasingly recognized.

Although no infectious agent has been associated with LCH, a specific disease causing pathogen, perhaps initiating the disease process by a “hit and run” mechanism, has, on the other hand, still not been excluded.

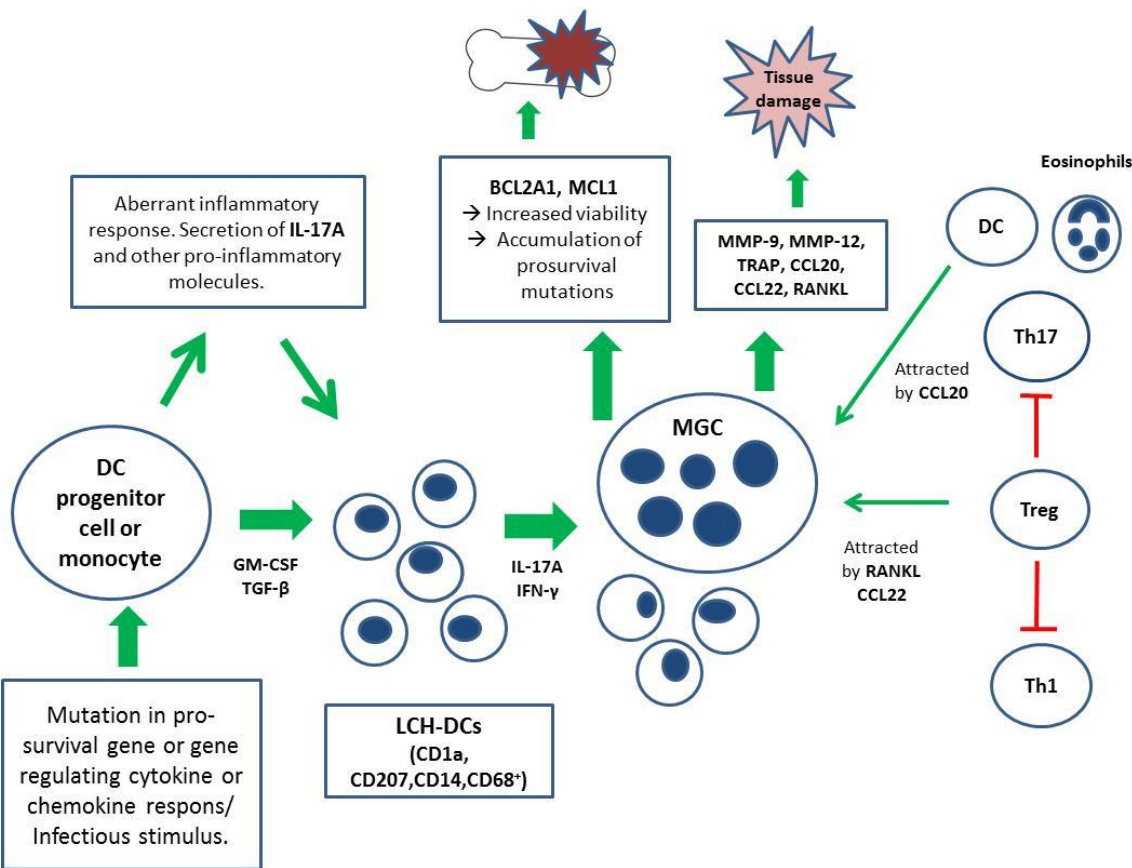


Figure 4. A possible model for IL-17A mediated functions in LCH.

5 CONCLUSIONS

- The study reported in **paper I** in this thesis is the first systematic study of CSF in children with neurodegenerative LCH. The results indicate that patients with neurodegenerative LCH have increased levels of at least one CSF biomarker and that NF-L, TAU and GFAP analyzed together may be useful to detect *ongoing* neurodegeneration in LCH. NF-L might be of special interest as a marker of progressive neurodegeneration. However, further studies are needed to evaluate the relationship between these biomarkers and the extension and progression of neurodegeneration, radiologically as well as clinically.
- The findings of **paper II** support a, possibly temporary, overrepresentation of LCH in children conceived by IVF which was not due to over-diagnosis of mild forms of the disease. This finding is intriguing but remains to be confirmed in independent studies in other countries. Should a correlation between IVF and LCH be proven, further studies would be valuable to investigate whether the cause is related to the IVF procedure, ART drugs used in the IVF treatment or underlying characteristics of the mothers explaining the subfertility.
- In **papers III** and **IV** we demonstrate that IL-17A modifies monocyte-derived immature DCs to cells with a mixed macrophage-DC phenotype. These cells are resistant to apoptosis which is associated with up-regulation of the pro-survival protein BCL2A1. They are also prone to undergo cell fusion to form MGCs. IL-17A-treated DCs express a variety of pro-inflammatory molecules and share some characteristics with tumor promoting M2 macrophages seen in the microenvironment of various tumors. They also resemble LCH DCs.
- The significance of IL-17A in the pathogenesis of LCH remains to be confirmed. Yet, our findings in **papers III** and **V** indicate a role for this cytokine in LCH where IL-17A might contribute to the pro-inflammatory tissue degrading environment characteristic of LCH lesions, and an inefficient immune response resulting in the failure of the body to clear the LCH lesions. Moreover, IL-17A may contribute to an increased viability of LCH DCs allowing for the formation of MGCs and favoring pro-survival mutations.
- The findings in **paper III** indicate that dendritic cells are the major source of IL-17A in LCH. Whether this is an intrinsic characteristic of LCH or a common phenomenon that will also be reported in other inflammatory disorders remains to be seen. However, that myeloid DC progenitors or precursors may be affected and relevant in the pathogenesis of LCH is increasingly recognized by the LCH research community.

6 GENERAL REMARKS AND FUTURE PERSPECTIVES

The overall aim of this thesis was to contribute to a better understanding of LCH. While the underlying cause of LCH still remains elusive, hopefully the papers included here will contribute in different ways to the growing body of knowledge of LCH, and inspire future research.

Since neurodegeneration in LCH is one of the most severe consequences of the disease, further studies in this area are highly important. Studying inflammatory markers and other molecules in the CSF might help to better understand the neurodegenerative process and to develop appropriate treatments. In line with this, our group plans to expand our CSF studies in the coming years. Apart from the importance of international collaboration on this issue, patients might also gain from increased collaboration with neurologists. A major clinical challenge will be how to identify children with signs of CNS inflammation and progressive neurodegeneration early on who could benefit from prompt treatment, before the process presumably has entered a phase where it is difficult to stop and clearly has caused significant harm. Motivating examinations and treatment in children who are still neurologically intact may be difficult, as is the question of when to stop treatment. Such decisions could be supported by the monitoring of reliable biomarkers in the CSF (or serum).

The study of cytokines in LCH naturally came to circle a great deal around IL-17A, following the initial findings of **paper III** and this story is, as reflected in the discussion, still ongoing. Independent studies will verify whether IL-17A is of importance in the pathogenesis of LCH. These should optimally include studies of both the IL-17A protein and its receptor IL-17RA. It would be interesting to study expression levels of IL-17A, ROR γ t and IL-17RA in cells that might be the source of LCH DCs. Furthermore it might be interesting to sequence IL-17A and IL-17RA in CD1a⁺ sorted LCH DCs or mo-DCs from LCH patients to look for mutations in this pathway. By comparing any findings in LCH to those of other granulomatous diseases we could perhaps learn more about this group of diseases as a whole.

In a broader perspective, the speed of technical progress facilitating the search for somatic or germ line mutations in LCH, is indeed inspiring. Apart from screening LCH DCs, or suspected precursors, for oncogenic mutations, directed analyzes of receptors, cytokines and chemokines that might mediate an aberrant recruitment, skewed maturation, or skewed T cell activation of DCs would be very interesting to perform. Why not focus directly on CD1a or CD207 for example?

Alternatively, improved possibilities to identify new pathogens may perhaps lead further along the pathway of solving the LCH enigma.

7 SVENSK SAMMANFATTNING

Langerhans cell histiocytos (LCH) är en ovanlig sjukdom vars orsak är okänd. LCH kan drabba alla åldrar men är vanligast hos barn. Små barn är i högre grad drabbade av allvarliga former av sjukdomen. Vid LCH bildas det granulomatösa inflammationshärdar i olika organ. Dessa innehåller alltid dendritiska celler positiva för markören CD1a. Flerkärniga jätteceller av okänd härkomst är också vanligt förekommande. Sjukdomsförloppet vid LCH är extremt varierande. Vissa får bara en enstaka, självläkande inflammationshärd i skelettet eller huden, medan andra får återkommande inflammationer i flera ben eller andra organ, och ytterligare andra drabbas av utbredda sjukdomshärdar förenliga med ett dramatiskt, livshotande sjukdomsförlopp. Nyligen identifierades i vävnadsprover av LCH en mutation i genen *BRAF*, som kodar för ett protein viktigt för cellsignalerings via den s.k. RAS-RAF-MAPK- kaskaden, av betydelse för cellens överlevnad och proliferation. Trots detta vet man ännu inte om LCH är en tumörsjukdom eller om mutationer som *BRAF* uppkommer sekundärt, till följd av att cellerna (över)stimulerats av inflammatoriska signaler.

Spridda former av sjukdomen behandlas vanligen med kortison och cytostatika. Överlevnaden vid LCH är god, förutom vid utbredda former av sjukdomen där bättre behandlingsmetoder behövs. Dessvärre utvecklas ofta olika former av följd tillstånd efter sjukdomen. En allvarlig sådan komplikation är en långsamt tilltagande neurodegeneration som utvecklas hos omkring 10-25% av barnen. Man har kopplat utvecklingen av neurodegeneration till, sannolikt sjukdomsmedierad, inflammation i centrala nervsystemet men man vet inte vad som orsakar denna eller hur den kan stoppas. När förändringar syns vid magnetkameraundersökningar (MR) har betydande nervskador redan skett. Det finns således ett behov av att hitta markörer som kan identifiera neurodegeneration tidigare i förloppet. Sådana skulle även kunna användas till att snabbare utvärdera behandlingsförsök än vad som är möjligt med MR.

I avhandlingens första artikel studerade vi tre välkända biomarkörer för neurodegeneration i ryggmärgs-vätska från barn med röntgenologiskt verifierad neurodegenerativ LCH; NF-L, Tau and GFAP. Samtliga dessa barn hade förhöjda värden av åtminstone en av dessa markörer. Analyserade tillsammans kan de således vara av värde för att upptäcka neurodegeneration vid LCH. NF-L kan eventuellt vara av särskilt värde för att avspegla progressiv neurodegeneration men fortsatta studier krävs för att klargöra detta.

Tidigare registerstudier har indikerat en överrepresentation av LCH hos barn födda efter in vitro fertilisering (IVF) i Sverige 1982-2005. Detta sporrade oss till att undersöka dessa fall närmare i avhandlingens andra artikel. Genom att konfirmera diagnoserna och karakterisera sjukdomsbilden hos barnen som identifierats i registerstudien verifierade vi en, möjligen tidsbunden, överrepresentation av LCH hos barn födda efter IVF vilken inte berodde på överdiagnostik av milda sjukdomsformer. Orsaken till detta, vilket möjligen skulle kunna återspegla orsaken till LCH, är dock inte känd och ett eventuellt samband mellan IVF och LCH behöver konfirmeras i separata studier.

I avhandlingens tre sista artiklar studerade vi betydelsen av den inflammationsfrämjande molekylen IL-17A vid LCH. Vi fann att IL-17A på många sätt påverkade dendritiska celler framställda från monocytter. De IL-17A-behandlade cellerna antog en speciell fenotyp, en blandning av dendritiska celler och makrofager, med förstärkt överlevnadspotential vilket var associerat med uppreglering av ett överlevnadsstimulerande protein, BCL2A1. Dessa celler tenderade att fusionera och bilda flerkärniga jätteceller, de uttryckte en uppsjö av proinflammatoriska ämnen och liknade på många sätt de patologiska celler som ses vid LCH. Vid studier av vävnadsprover av LCH fann vi rikligt med IL-17A, och monocytframställda dendritiska celler från LCH patienter utsöndrade spontant IL-17A till skillnad från friska kontroller. Dessa celler hade en förlängd överlevnad jämfört med friska kontroller, uttryckte BCL2A1 och bildade spontant jätteceller, en process som gick att bryta med antikroppar mot IL-17A.

Betydelsen och förekomsten av IL-17A vid LCH är omdebatterad. Sammantaget talar våra fynd dock för en betydelse av IL-17A i patogenesen till LCH där IL-17A kan bidra till LCH-härdarnas inflammatoriska karaktär, en förlängd överlevnad av patologiska celler och bildandet av jätteceller. Huruvida en uppreglering av IL-17A vid LCH skulle vara fysiologisk, som del i ett försvar mot ett främmande antigen, eller bero på en mutation, alternativt viralt stimulerad produktion, är ännu heller ej klarlagt.

8 ACKNOWLEDGMENTS

First of all I would like to thank all the children and their families who have so generously contributed to our studies.

Papers III-V are part of an international collaboration which would not have come about without Prof. **Christine Delprat**, Centre National de la Recherche Scientifique, UMR5239 - Laboratoire de Biologie Moléculaire de la Cellule, Université Claude Bernard Lyon 1, Lyon, France.

Apart from my own supervisor, Prof. **Jan-Inge Henter**, Prof. **Maurizio Aricò** and Prof. **Martin Egeler** have also been essential partners in this collaboration.

In the work with this thesis, many persons have been invaluable to me. I would like to thank you all sincerely. In particular I would like to acknowledge:

In research:

Jan-Inge Henter, my main supervisor, for being a great researcher with a big heart. Others have said it before, but your enthusiasm, curiosity and clearness is amazing. With you, everything has a solution and things always take a new turn. Your talent to create networks is unique. Thanks also for being so supportive and accessible, taking care of your research team in the midst of all other duties.

Christine Delprat, my French co-supervisor, for teaching me immunology and science. Your brilliance and rationality is breath taking. I am happy to have had the possibility to learn from you. Thanks also for opening up your home to me so generously.

Desirée Gavhed, my co-supervisor. Where would I be without you? You are one of the most considerate persons I know, but you are also such a wise person, thinking an extra turn and coming up with wise comments. I am also forever indebted to you for all the practical help.

All group members at the Childhood Cancer Research Unit (BCFE). **Magda**, for moving up to this cold country to drive LCH research forward here. **AnnaCarin**, **Maja** and **Helena** for sharing concerns for and highlights of research, clinical work and family in a hectic time of our lives. **Marie**, **Elisabet**, **Tatiana**, **Egle**, **Bianca**, **Alexandra**, **Miriam**, **Lena-Maria**, **Geraldine** for being such great persons and for all exciting discussions and laughs that we have shared at group retreats and at other times.

Henter group extended: **Yenan T. Bryceson**, **Bengt Fadeel** and **Chengyun Zheng** for the generous sharing of your expertise and knowledge.

Mattias Svensson, and your group at Center for Infectious Medicine, for letting me into your group and for teaching me the basics of immunohistochemistry. In a broader perspective for providing a haven for laboratory LCH research in Sweden.

All team members in Lyon. **Alex**, brother in arms. **Fabienne**, big sister in research and motherhood. **Bachar**, **Carine**, for all your fantastic work with developing our studies on BCL2A1 and LCH.

Members of **Chantal Rabourdin-Combe's** team, INSERM U851, 2008.

All co-authors. Prof. **Orvar Finnström** for initiating the study of children with LCH following IVF. **Evaldas Laurencikas** for your expertise on neurodegenerative LCH and for being available for questions and patients discussions.

Erik Onelöv for valuable help with statistics in **paper II**.

Staffan Eksborg for advice and literature on chemotherapeutic drugs.

Mia Brytting, **Lena Jägdahl** and their colleagues at the Swedish Institute for Communicable Disease Control (SMI) for introducing me to virology and PCR.

Ann-Mari Svennerholm, my mentor, for just knowing that you were there.

In clinical work:

Bo Magnusson, for being a great boss, letting us all develop along our own ways.

My clinical supervisor **Anna Nilsson**, for inspiration and guidance.

All wonderful colleagues at Astrid Lindgren Children's Hospital.

Family and friends:

All my dear friends and their families. **Hanna** and **Karin**, maybe our cultural club will have a re-start now. CF. QB. Dear friends in Stockholm, Gothenburg and elsewhere. Together we have been brave and smart, weak and lost.

My parents, **Jane** and **Dan**, for your ever-lasting love and support. **William**, **Kim**, **Agnes**, **Violet** and **Sten**. Being with you always fills me with warmth and happiness.

Bodil and **Arne**, my sweet parents-in-law. Thank you endlessly for all your support and for taking care of us at so many times. **Jon, Katrin, Lukas** and **Maj**. You enrich our lives. Without you, nor would there be any buns and we would live in a house about to fall down. **Stina** and **Ernesto**, thank you for showing us the possibility of another life. Stina, you are the best aunt ever.

My cousins and other members of my extended family.

Hedvig and **Albert** for reminding me of what is most important in life and for the joy it brings me to be with you.

Per. For being there every day. For all your love and patience.

Funding:

The studies in this thesis were funded by grants from: **France:** Institut National de la Santé Et de la Recherche Médicale, Université Claude Bernard de Lyon, Fondation pour la Recherche Médicale, DEQ2005120572, Émergence project of Rhône-Alpes Region , Ligue Contre le Cancer Ardèche Drome and Rhône, Institut National contre le Cancer-cancéropole 2004-2005, Association pour la Recherche sur le Cancer 3637, Association de Recherche sur la Polyarthrite and French Ministry of Research ACI8BC05H, CNRS, INSERM, Université de Lyon, Institut Universitaire de France, Fondation Innovations en Infectiologie, Fondation de France 2008002100 and Agence Nationale de la Recherche 08-MIEN-001-02. **USA:** The Histiocytosis Association of America 2006 and the Histiocytosis Association of America 2008. **Canada:** The Histiocytosis Association of Canada. **Italy:** The Italian Ministry of Health, Progetto di Ricerca Finalizzata 2004: “Istiocitosi e Tumori” and Progetto di Ricerca Finalizzata 2008: “Getting deeper in histiocytosis”, Regione Toscana, Progetto di Ricerca Malattie Rare 2008 and Associazione Italiana Ricerca Istiocitosi (AIRI). **Sweden:** The Swedish Children’s Cancer Foundation, the Swedish Cancer Society, the Swedish Research Council, the Märta and Gunnar V Philipson Foundation, the Cancer and Allergy Foundation of Sweden, Karolinska Institutet (KID project) and the Stockholm County Council (ALF project).

9 REFERENCES

- ABDELATIF, O. M., CHANDLER, F. W., PANTAZIS, C. G. & MCGUIRE, B. S. 1990. Enhanced expression of c-myc and H-ras oncogenes in Letterer-Siwe disease. A sequential study using colorimetric in situ hybridization. *Arch Pathol Lab Med*, 114, 1254-60.
- AJAMI, B., BENNETT, J. L., KRIEGER, C., TETZLAFF, W. & ROSSI, F. M. 2007. Local self-renewal can sustain CNS microglia maintenance and function throughout adult life. *Nat Neurosci*, 10, 1538-43.
- AKKARI, V., DONADIEU, J., PIGUET, C., BORDIGONI, P., MICHEL, G., BLANCHE, S., CASANOVA, J. L., THOMAS, C., VILMER, E., FISCHER, A. & BERTRAND, Y. 2003. Hematopoietic stem cell transplantation in patients with severe Langerhans cell histiocytosis and hematological dysfunction: experience of the French Langerhans Cell Study Group. *Bone Marrow Transplant*, 31, 1097-103.
- ALLEN, C. E., FLORES, R., RAUCH, R., DAUSER, R., MURRAY, J. C., PUC CETTI, D., HSU, D. A., SONDEL, P., HETHERINGTON, M., GOLDMAN, S. & MCCLAIN, K. L. 2010a. Neurodegenerative central nervous system Langerhans cell histiocytosis and coincident hydrocephalus treated with vincristine/cytosine arabinoside. *Pediatr Blood Cancer*, 54, 416-23.
- ALLEN, C. E., LI, L., PETERS, T. L., LEUNG, H. C., YU, A., MAN, T. K., GURUSIDDAPPA, S., PHILLIPS, M. T., HICKS, M. J., GAIKWAD, A., MERAD, M. & MCCLAIN, K. L. 2010b. Cell-specific gene expression in Langerhans cell histiocytosis lesions reveals a distinct profile compared with epidermal Langerhans cells. *J Immunol*, 184, 4557-67.
- ALLEN, C. E. & MCCLAIN, K. L. 2009. Interleukin-17A is not expressed by CD207(+) cells in Langerhans cell histiocytosis lesions. *Nat Med*, 15, 483-4; author reply 484-5.
- ALSTON, R. D., TATEVOSSIAN, R. G., MCNALLY, R. J., KELSEY, A., BIRCH, J. M. & EDEN, T. O. 2007. Incidence and survival of childhood Langerhans cell histiocytosis in Northwest England from 1954 to 1998. *Pediatr Blood Cancer*, 48, 555-60.
- ANDERSSON BY, U., TANI, E., ANDERSSON, U. & HENTER, J. I. 2004. Tumor necrosis factor, interleukin 11, and leukemia inhibitory factor produced by Langerhans cells in Langerhans cell histiocytosis. *J Pediatr Hematol Oncol*, 26, 706-11.
- ANNELS, N. E., DA COSTA, C. E., PRINS, F. A., WILLEMZE, A., HOGENDOORN, P. C. & EGELER, R. M. 2003. Aberrant chemokine receptor expression and chemokine production by Langerhans cells underlies the pathogenesis of Langerhans cell histiocytosis. *J Exp Med*, 197, 1385-90.
- ANTEBY, I., COHEN, E., ANTEBY, E. & BENEZRA, D. 2001. Ocular manifestations in children born after in vitro fertilization. *Arch Ophthalmol*, 119, 1525-9.
- ARICO, M. 1991. Cyclosporine therapy for refractory Langerhans cell histiocytosis. *Blood*, 78, 3107.
- ARICO, M. 2004. Langerhans cell histiocytosis in adults: more questions than answers? *Eur J Cancer*, 40, 1467-73.

- ARICO, M. & DANESINO, C. 2001. Langerhans' cell histiocytosis: is there a role for genetics? *Haematologica*, 86, 1009-14.
- ARICO, M. & EGELER, R. M. 1998. Clinical aspects of Langerhans cell histiocytosis. *Hematol Oncol Clin North Am*, 12, 247-58.
- ARICO, M., NICHOLS, K., WHITLOCK, J. A., ARCECI, R., HAUPT, R., MITTLER, U., KUHNE, T., LOMBARDI, A., ISHII, E., EGELER, R. M. & DANESINO, C. 1999. Familial clustering of Langerhans cell histiocytosis. *Br J Haematol*, 107, 883-8.
- ARONSON, R. P. 1951. Streptomycin in Letterer-Siwe's disease. *Lancet*, 1, 889-90.
- AUFFRAY, C., SIEWEKE, M. H. & GEISSMANN, F. 2009. Blood monocytes: development, heterogeneity, and relationship with dendritic cells. *Annu Rev Immunol*, 27, 669-92.
- AURELL, A., ROSENGREN, L. E., KARLSSON, B., OLSSON, J. E., ZBORNIKOVA, V. & HAGLID, K. G. 1991. Determination of S-100 and glial fibrillary acidic protein concentrations in cerebrospinal fluid after brain infarction. *Stroke*, 22, 1254-8.
- BADALIAN-VERY, G., VERGILIO, J. A., DEGAR, B. A., MACCONAILL, L. E., BRANDNER, B., CALICCHIO, M. L., KUO, F. C., LIGON, A. H., STEVENSON, K. E., KEHOE, S. M., GARRAWAY, L. A., HAHN, W. C., MEYERSON, M., FLEMING, M. D. & ROLLINS, B. J. 2010. Recurrent BRAF mutations in Langerhans cell histiocytosis. *Blood*, 116, 1919-23.
- BADALIAN-VERY, G., VERGILIO, J. A., FLEMING, M. & ROLLINS, B. J. 2013. Pathogenesis of Langerhans cell histiocytosis. *Annu Rev Pathol*, 8, 1-20.
- BANK, M. I., RENGTVED, P., CARSTENSEN, H. & PETERSEN, B. L. 2003. Langerhans cell histiocytosis: an evaluation of histopathological parameters, demonstration of proliferation by Ki-67 and mitotic bodies. *APMIS*, 111, 300-8.
- BARTHEZ, M. A., ARAUJO, E. & DONADIEU, J. 2000. Langerhans cell histiocytosis and the central nervous system in childhood: evolution and prognostic factors. Results of a collaborative study. *J Child Neurol*, 15, 150-6.
- BAUMGARTNER, I., VON HOCHSTETTER, A., BAUMERT, B., LUETOLF, U. & FOLLATH, F. 1997. Langerhans'-cell histiocytosis in adults. *Med Pediatr Oncol*, 28, 9-14.
- BECHAN, G. I., EGELER, R. M. & ARCECI, R. J. 2006. Biology of Langerhans cells and Langerhans cell histiocytosis. *Int Rev Cytol*, 254, 1-43.
- BECHAN, G. I., MEEKER, A. K., DE MARZO, A. M., RACKE, F., JAFFE, R., SUGAR, E. & ARCECI, R. J. 2008. Telomere length shortening in Langerhans cell histiocytosis. *Br J Haematol*, 140, 420-8.
- BELLMUNT, J., ALBANELL, J., SALUD, A., ESPANOL, T., MORALES, S. & SOLE-CALVO, L. A. 1992. Interferon and disseminated Langerhans cell histiocytosis. *Med Pediatr Oncol*, 20, 336-7.
- BENCHETRIT, F., CIREE, A., VIVES, V., WARNIER, G., GEY, A., SAUTES-FRIDMAN, C., FOSSIEZ, F., HAICHEUR, N., FRIDMAN, W. H. & TARTOUR, E. 2002. Interleukin-17 inhibits tumor cell growth by means of a T-cell-dependent mechanism. *Blood*, 99, 2114-21.
- BERNARD, F., THOMAS, C., BERTRAND, Y., MUNZER, M., LANDMAN PARKER, J., OUACHE, M., COLIN, V. M., PEREL, Y., CHASTAGNER, P., VERMYLEN, C. & DONADIEU, J. 2005. Multi-centre pilot study of 2-chlorodeoxyadenosine and cytosine arabinoside combined chemotherapy in refractory Langerhans cell histiocytosis with haematological dysfunction. *Eur J Cancer*, 41, 2682-9.

- BERNSTRAND, C., BJORK, O., AHSTROM, L. & HENTER, J. I. 1996. Intralesional steroids in Langerhans cell histiocytosis of bone. *Acta Paediatr*, 85, 502-4.
- BERNSTRAND, C., CARSTENSEN, H., JAKOBSEN, B., SVEJGAARD, A., HENTER, J. I. & OLERUP, O. 2003. Immunogenetic heterogeneity in single-system and multisystem langerhans cell histiocytosis. *Pediatr Res*, 54, 30-6.
- BERNSTRAND, C., CEDERLUND, K. & HENTER, J. I. 2007. Pulmonary function testing and pulmonary Langerhans cell histiocytosis. *Pediatr Blood Cancer*, 49, 323-8.
- BERNSTRAND, C., CEDERLUND, K., SANDSTEDT, B., AHSTROM, L., LUNDELL, M., DAHLQUIST, G. & HENTER, J. I. 2001. Pulmonary abnormalities at long-term follow-up of patients with Langerhans cell histiocytosis. *Med Pediatr Oncol*, 36, 459-68.
- BERNSTRAND, C., SANDSTEDT, B., AHSTROM, L. & HENTER, J. I. 2005. Long-term follow-up of Langerhans cell histiocytosis: 39 years' experience at a single centre. *Acta Paediatr*, 94, 1073-84.
- BETTS, D. R., LEIBUNDGUT, K. E., FELDGES, A., PLUSS, H. J. & NIGGLI, F. K. 1998. Cytogenetic abnormalities in Langerhans cell histiocytosis. *Br J Cancer*, 77, 552-5.
- BHATIA, S., NESBIT, M. E., JR., EGELER, R. M., BUCKLEY, J. D., MERTENS, A. & ROBISON, L. L. 1997. Epidemiologic study of Langerhans cell histiocytosis in children. *J Pediatr*, 130, 774-84.
- BILLINGS, S. D., HANS, C. P., SCHAPIRO, B. L., MARTIN, R. W., 3RD, FIVENSON, D., FRULAND, J. E., MOORES, W. B. & COTTON, J. 2006. Langerhans cell histiocytosis associated with myelodysplastic syndrome in adults. *J Cutan Pathol*, 33, 171-4.
- BIRBECK, M., BREATHNACH, A. & EVERALL, J. 1961. An electron microscope study of basal melanocytes and high-level of clear cells (Langerhans cells) in vitiligo. *J Invest Dermatol*, 37, 51-63.
- BISWAS, S. K., ALLAVENA, P. & MANTOVANI, A. 2013. Tumor-associated macrophages: functional diversity, clinical significance, and open questions. *Semin Immunopathol*, 35, 585-600.
- BJORCK, P., BANCHEREAU, J. & FLORES-ROMO, L. 1997. CD40 ligation counteracts Fas-induced apoptosis of human dendritic cells. *Int Immunol*, 9, 365-72.
- BLENNOW, K., WALLIN, A., AGREN, H., SPENGER, C., SIEGFRIED, J. & VANMECHELEN, E. 1995. Tau protein in cerebrospinal fluid: a biochemical marker for axonal degeneration in Alzheimer disease? *Mol Chem Neuropathol*, 26, 231-45.
- BLENNOW, K., ZETTERBERG, H. & FAGAN, A. M. 2012. Fluid biomarkers in Alzheimer disease. *Cold Spring Harb Perspect Med*, 2, a006221.
- BLENNOW, M., SAVMAN, K., ILVES, P., THORESEN, M. & ROSENGREN, L. 2001. Brain-specific proteins in the cerebrospinal fluid of severely asphyxiated newborn infants. *Acta Paediatr*, 90, 1171-5.
- BOOMSMA, C. M., KAVELAARS, A., EIJKEMANS, M. J., FAUSER, B. C., HEIJNEN, C. J. & MACKLON, N. S. 2010. Ovarian stimulation for in vitro fertilization alters the intrauterine cytokine, chemokine, and growth factor milieu encountered by the embryo. *Fertil Steril*, 94, 1764-8.
- BRABENCOVA, E., TAZI, A., LORENZATO, M., BONAY, M., KAMBOUCHNER, M., EMILE, J. F., HANCE, A. J. & SOLER, P. 1998. Langerhans cells in Langerhans cell granulomatosis are not actively proliferating cells. *Am J Pathol*, 152, 1143-9.

- BRADBURY, B. D. & JICK, H. 2004. In vitro fertilization and childhood retinoblastoma. *Br J Clin Pharmacol*, 58, 209-11.
- BRAIER, J., CIOCCA, M., LATELLA, A., DE DAVILA, M. G., DRAJER, M. & IMVENTARZA, O. 2002. Cholestasis, sclerosing cholangitis, and liver transplantation in Langerhans cell Histiocytosis. *Med Pediatr Oncol*, 38, 178-82.
- BROADBENT, V. 1986. Favourable prognostic features in histiocytosis X: bone involvement and absence of skin disease. *Arch Dis Child*, 61, 1219-21.
- BROADBENT, V., EGELER, R. M. & NESBIT, M. E., JR. 1994. Langerhans cell histiocytosis--clinical and epidemiological aspects. *Br J Cancer Suppl*, 23, S11-6.
- BROADBENT, V. & PRITCHARD, J. 1997. Diabetes insipidus associated with Langerhans cell histiocytosis: is it reversible? *Med Pediatr Oncol*, 28, 289-93.
- BRUINSMA, F., VENN, A., LANCASTER, P., SPEIRS, A. & HEALY, D. 2000. Incidence of cancer in children born after in-vitro fertilization. *Hum Reprod*, 15, 604-7.
- BUCHLER, T., CERVINEK, L., BELOHLAVEK, O., KANTOROVA, I., MECHL, M., NEBESKY, T., VORLICEK, J. & ADAM, Z. 2005. Langerhans cell histiocytosis with central nervous system involvement: follow-up by FDG-PET during treatment with cladribine. *Pediatr Blood Cancer*, 44, 286-8.
- BURSCH, L. S., WANG, L., IGYARTO, B., KISSENPENNIG, A., MALISSEN, B., KAPLAN, D. H. & HOGQUIST, K. A. 2007. Identification of a novel population of Langerin+ dendritic cells. *J Exp Med*, 204, 3147-56.
- CALMING, U., BEMSTRAND, C., MOSSKIN, M., ELANDER, S. S., INGVAR, M. & HENTER, J. I. 2002. Brain 18-FDG PET scan in central nervous system langerhans cell histiocytosis. *J Pediatr*, 141, 435-40.
- CALMING, U. & HENTER, J. I. 1998. Elevated erythrocyte sedimentation rate and thrombocytosis as possible indicators of active disease in Langerhans' cell histiocytosis. *Acta Paediatr*, 87, 1085-7.
- CARSTENSEN, H. & ORNVOLD, K. 1993. The epidemiology of Langerhans cell histiocytosis in children in Denmark, 1975-1989. *Med Pediatr Oncol*, 21, 387-8 (abstract).
- CAUX, C., DEZUTTER-DAMBUYANT, C., SCHMITT, D. & BANCHEREAU, J. 1992. GM-CSF and TNF-alpha cooperate in the generation of dendritic Langerhans cells. *Nature*, 360, 258-61.
- CECI, A., DE TERLIZZI, M., COLELLA, R., LOIACONO, G., BALDUCCI, D., SURICO, G., CASTELLO, M., TESTI, A. M., DE BERNARDI, B., INDOLFI, P. & ET AL. 1993. Langerhans cell histiocytosis in childhood: results from the Italian Cooperative AIEOP-CNR-H.X '83 study. *Med Pediatr Oncol*, 21, 259-64.
- CECI, A., DE TERLIZZI, M., TOMA, M. G., CALCULLI, G., CAPUTO, R., CASTELLO, M., INDOLFI, P. & ROSATI, D. 1988. Heterogeneity of immunological patterns in Langerhan's histiocytosis and response to crude calf thymic extract in 11 patients. *Med Pediatr Oncol*, 16, 111-5.
- CHABAUD, M., DURAND, J. M., BUCHS, N., FOSSIEZ, F., PAGE, G., FRAPPART, L. & MIOSSEC, P. 1999. Human interleukin-17: A T cell-derived proinflammatory cytokine produced by the rheumatoid synovium. *Arthritis Rheum*, 42, 963-70.
- CHABAUD, M., GARNERO, P., DAYER, J. M., GUERNE, P. A., FOSSIEZ, F. & MIOSSEC, P. 2000. Contribution of interleukin 17 to synovium matrix destruction in rheumatoid arthritis. *Cytokine*, 12, 1092-9.

- CHANG, S. H. & DONG, C. 2007. A novel heterodimeric cytokine consisting of IL-17 and IL-17F regulates inflammatory responses. *Cell Res*, 17, 435-40.
- CHANG, W. L., BAUMGARTH, N., EBERHARDT, M. K., LEE, C. Y., BARON, C. A., GREGG, J. P. & BARRY, P. A. 2007. Exposure of myeloid dendritic cells to exogenous or endogenous IL-10 during maturation determines their longevity. *J Immunol*, 178, 7794-804.
- CHAO, D., BAHL, P., HOULBROOK, S., HOY, L., HARRIS, A. & AUSTYN, J. M. 1999. Human cultured dendritic cells show differential sensitivity to chemotherapy agents as assessed by the MTS assay. *Br J Cancer*, 81, 1280-4.
- CHEN, C. J., HO, T. Y., LU, J. J., SHEU, L. F., LEE, S. Y., TIEN, C. H. & CHENG, S. N. 2004. Identical twin brothers concordant for Langerhans' cell histiocytosis and discordant for Epstein-Barr virus-associated haemophagocytic syndrome. *Eur J Pediatr*, 163, 536-9.
- CHEN, M., WANG, Y. H., WANG, Y., HUANG, L., SANDOVAL, H., LIU, Y. J. & WANG, J. 2006. Dendritic cell apoptosis in the maintenance of immune tolerance. *Science*, 311, 1160-4.
- CHEN, R. L., LIN, K. S., CHANG, W. H., HSIEH, Y. L., CHEN, B. W., JAING, T. H., YANG, C. P., HUNG, I. J., PENG, C. T., SHU, S. G., LU, M. Y., JOU, S. T., LIN, K. H., LIN, D. T., LIN, M. T., CHEN, J. S., LIU, H. C., CHEN, S. H., LIANG, D. C., CHIOU, S. S., CHANG, T. T., SHEEN, J. M., HSIAO, C. C., CHENG, S. N. & LIN, J. C. 2003. Childhood Langerhans cell histiocytosis increased during El Nino 1997-98: a report from the Taiwan Pediatric Oncology Group. *Acta Paediatr Taiwan*, 44, 14-20.
- CHEN, W. C., LAI, Y. H., CHEN, H. Y., GUO, H. R., SU, I. J. & CHEN, H. H. 2013. Interleukin-17-producing cell infiltration in the breast cancer tumour microenvironment is a poor prognostic factor. *Histopathology*, 63, 225-33.
- CHENG, P., ZHOU, J. & GABRILOVICH, D. 2010. Regulation of dendritic cell differentiation and function by Notch and Wnt pathways. *Immunol Rev*, 234, 105-19.
- CHEONG, C., MATOS, I., CHOI, J. H., DANDAMUDI, D. B., SHRESTHA, E., LONGHI, M. P., JEFFREY, K. L., ANTHONY, R. M., KLUGER, C., NCHINDA, G., KOH, H., RODRIGUEZ, A., IDOYAGA, J., PACK, M., VELINZON, K., PARK, C. G. & STEINMAN, R. M. 2010. Microbial stimulation fully differentiates monocytes to DC-SIGN/CD209(+) dendritic cells for immune T cell areas. *Cell*, 143, 416-29.
- CHIKWAVA, K. & JAFFE, R. 2004. Langerin (CD207) staining in normal pediatric tissues, reactive lymph nodes, and childhood histiocytic disorders. *Pediatr Dev Pathol*, 7, 607-14.
- CHIKWAVA, K. R., HUNT, J. L., MANTHA, G. S., MURPHY, J. E. & JAFFE, R. 2007. Analysis of loss of heterozygosity in single-system and multisystem Langerhans' cell histiocytosis. *Pediatr Dev Pathol*, 10, 18-24.
- CHORRO, L. & GEISSMANN, F. 2010. Development and homeostasis of 'resident' myeloid cells: the case of the Langerhans cell. *Trends Immunol*, 31, 438-45.
- CHORRO, L., SARDE, A., LI, M., WOOLLARD, K. J., CHAMBON, P., MALISSEN, B., KISSENPENNIG, A., BARBAROUX, J. B., GROVES, R. & GEISSMANN, F. 2009. Langerhans cell (LC) proliferation mediates neonatal development, homeostasis, and inflammation-associated expansion of the epidermal LC network. *J Exp Med*, 206, 3089-100.
- CHRISTIAN, H. A. 1919. Defects in membranous bones, exophthalmos and diabetes insipidus; an unusual syndrome of dyspituitarism. *Med Clin North Am*, 3, 849-857.

- CHU, T., D'ANGIO, G. J., FAVARA, B. E., LADISCH, S., NESBIT, M. & PRITCHARD, J. 1987. Histiocytosis syndromes in children. *Lancet*, 2, 41-2.
- CHUANG, P. I., MOREFIELD, S., LIU, C. Y., CHEN, S., HARLAN, J. M. & WILLERFORD, D. M. 2002. Perturbation of B-cell development in mice overexpressing the Bcl-2 homolog A1. *Blood*, 99, 3350-9.
- COHEN, M., ZORNOZA, J., CANGIR, A., MURRAY, J. A. & WALLACE, S. 1980. Direct injection of methylprednisolone sodium succinate in the treatment of solitary eosinophilic granuloma of bone: a report of 9 cases. *Radiology*, 136, 289-93.
- COHEN, M. M. & LEVY, H. P. 1989. Chromosome instability syndromes. *Adv Hum Genet*, 18, 43-149, 365-71.
- COLBY, T. V. & LOMBARD, C. 1983. Histiocytosis X in the lung. *Hum Pathol*, 14, 847-56.
- CORVETTA, A., LUCHETTI, M. M., POMPONIO, G., DELLA BITTA, R., RECCHIONI, A., STRUSI, P., DE SIO, G. & DANIELI, G. 1990. Interleukin-2, soluble interleukin-2 receptor and tumor necrosis factor in sera from patients with rheumatoid arthritis. *Ric Clin Lab*, 20, 275-81.
- COURY, F., ANNELS, N., RIVOLLIER, A., OLSSON, S., SANTORO, A., SPEZIANI, C., AZOCAR, O., FLACHER, M., DJEBALI, S., TEBIB, J., BRYTTING, M., EGELER, R. M., RABOURDIN-COMBE, C., HENTER, J. I., ARICO, M. & DELPRAT, C. 2008. Langerhans cell histiocytosis reveals a new IL-17A-dependent pathway of dendritic cell fusion. *Nat Med*, 14, 81-7.
- COUSSENS, L. M. & WERB, Z. 2002. Inflammation and cancer. *Nature*, 420, 860-7.
- COX, G. F., BURGER, J., LIP, V., MAU, U. A., SPERLING, K., WU, B. L. & HORSTHEMKE, B. 2002. Intracytoplasmic sperm injection may increase the risk of imprinting defects. *Am J Hum Genet*, 71, 162-4.
- CRAIG, R. W. 2002. MCL1 provides a window on the role of the BCL2 family in cell proliferation, differentiation and tumorigenesis. *Leukemia*, 16, 444-54.
- CROWE, C. R., CHEN, K., POCIASK, D. A., ALCORN, J. F., KRIVICH, C., ENELOW, R. I., ROSS, T. M., WITZTUM, J. L. & KOLLS, J. K. 2009. Critical role of IL-17RA in immunopathology of influenza infection. *J Immunol*, 183, 5301-10.
- CRUZ, A., FRAGA, A. G., FOUNTAIN, J. J., RANGEL-MORENO, J., TORRADO, E., SARAIVA, M., PEREIRA, D. R., RANDALL, T. D., PEDROSA, J., COOPER, A. M. & CASTRO, A. G. 2010. Pathological role of interleukin 17 in mice subjected to repeated BCG vaccination after infection with *Mycobacterium tuberculosis*. *J Exp Med*, 207, 1609-16.
- CUA, D. J. & TATO, C. M. 2010. Innate IL-17-producing cells: the sentinels of the immune system. *Nat Rev Immunol*, 10, 479-89.
- CULVER, D. A. 2012. Sarcoidosis. *Immunol Allergy Clin North Am*, 32, 487-511.
- D'SOUZA, B. N., EDELSTEIN, L. C., PEGMAN, P. M., SMITH, S. M., LOUGHRAN, S. T., CLARKE, A., MEHL, A., ROWE, M., GELINAS, C. & WALLS, D. 2004. Nuclear factor kappa B-dependent activation of the antiapoptotic bfl-1 gene by the Epstein-Barr virus latent membrane protein 1 and activated CD40 receptor. *J Virol*, 78, 1800-16.
- DA COSTA, C. E., ANNELS, N. E., FAAIJ, C. M., FORSYTH, R. G., HOGENDOORN, P. C. & EGELER, R. M. 2005. Presence of osteoclast-like multinucleated giant cells in the bone and nonostotic lesions of Langerhans cell histiocytosis. *J Exp Med*, 201, 687-93.
- DA COSTA, C. E., EGELER, R. M., HOOGEBOOM, M., SZUHAI, K., FORSYTH, R. G., NIESTERS, M., DE KRIJGER, R. R., TAZI, A., HOGENDOORN, P. C.

- & ANNELS, N. E. 2007. Differences in telomerase expression by the CD1a+ cells in Langerhans cell histiocytosis reflect the diverse clinical presentation of the disease. *J Pathol*, 212, 188-97.
- DA COSTA, C. E., SZUHAI, K., VAN EIJK, R., HOOGEBOOM, M., SCIOT, R., MERTENS, F., BJORGVINSDOTTIR, H., DEBIEC-RYCHTER, M., DE KRIJGER, R. R., HOGENDOORN, P. C., EGELER, R. M. & ANNELS, N. E. 2009. No genomic aberrations in Langerhans cell histiocytosis as assessed by diverse molecular technologies. *Genes Chromosomes Cancer*, 48, 239-49.
- DARNELL, R. B. & POSNER, J. B. 2003. Paraneoplastic syndromes involving the nervous system. *N Engl J Med*, 349, 1543-54.
- DAVIES, E. G., LEVINSKY, R. J., BUTLER, M., BROADBENT, V., PRITCHARD, J. & CHESSELLS, J. 1983. Thymic hormone therapy for histiocytosis X? *N Engl J Med*, 309, 493-4.
- DAVIES, H., BIGNELL, G. R., COX, C., STEPHENS, P., EDKINS, S., CLEGG, S., TEAGUE, J., WOFFENDIN, H., GARNETT, M. J., BOTTOMLEY, W., DAVIS, N., DICKS, E., EWING, R., FLOYD, Y., GRAY, K., HALL, S., HAWES, R., HUGHES, J., KOSMIDOU, V., MENZIES, A., MOULD, C., PARKER, A., STEVENS, C., WATT, S., HOOPER, S., WILSON, R., JAYATILAKE, H., GUSTERSON, B. A., COOPER, C., SHIPLEY, J., HARGRAVE, D., PRITCHARD-JONES, K., MAITLAND, N., CHENEVIX-TRENCH, G., RIGGINS, G. J., BIGNER, D. D., PALMIERI, G., COSSU, A., FLANAGAN, A., NICHOLSON, A., HO, J. W., LEUNG, S. Y., YUEN, S. T., WEBER, B. L., SEIGLER, H. F., DARROW, T. L., PATERSON, H., MARAIS, R., MARSHALL, C. J., WOOSTER, R., STRATTON, M. R. & FUTREAL, P. A. 2002. Mutations of the BRAF gene in human cancer. *Nature*, 417, 949-54.
- DAVIS, A. L., MCKENZIE, J. L. & HART, D. N. 1988. HLA-DR-positive leucocyte subpopulations in human skin include dendritic cells, macrophages, and CD7-negative T cells. *Immunology*, 65, 573-81.
- DE GRAAF, J. H., TAMMINGA, R. Y., DAM-MEIRING, A., KAMPS, W. A. & TIMENS, W. 1996. The presence of cytokines in Langerhans' cell histiocytosis. *J Pathol*, 180, 400-6.
- DEBAUN, M. R., NIEMITZ, E. L. & FEINBERG, A. P. 2003. Association of in vitro fertilization with Beckwith-Wiedemann syndrome and epigenetic alterations of LIT1 and H19. *Am J Hum Genet*, 72, 156-60.
- DEISS, A., BRECHT, I., HAARMANN, A. & BUTTMANN, M. 2013. Treating multiple sclerosis with monoclonal antibodies: a 2013 update. *Expert Rev Neurother*, 13, 313-35.
- DELVES, P. J. & ROITT, I. M. 2000a. The immune system. First of two parts. *N Engl J Med*, 343, 37-49.
- DELVES, P. J. & ROITT, I. M. 2000b. The immune system. Second of two parts. *N Engl J Med*, 343, 108-17.
- DHALL, G., FINLAY, J. L., DUNKEL, I. J., ETTINGER, L. J., KELLIE, S. J., ALLEN, J. C., EGELER, R. M. & ARCECI, R. J. 2008. Analysis of outcome for patients with mass lesions of the central nervous system due to Langerhans cell histiocytosis treated with 2-chlorodeoxyadenosine. *Pediatr Blood Cancer*, 50, 72-9.
- DIEHL, G. E., YUE, H. H., HSIEH, K., KUANG, A. A., HO, M., MORICI, L. A., LENZ, L. L., CADO, D., RILEY, L. W. & WINOTO, A. 2004. TRAIL-R as a negative regulator of innate immune cell responses. *Immunity*, 21, 877-89.

- DOMMERING, C. J., VAN DER HOUT, A. H., MEIJERS-HEIJBOER, H., MAREES, T. & MOLL, A. C. 2012. IVF and retinoblastoma revisited. *Fertil Steril*, 97, 79-81.
- DONADIEU, J. & PRITCHARD, J. 1999. Langerhans cell histiocytosis - 400 BC? *Med Pediatr Oncol*, 33, 520 (abstract).
- DONADIEU, J., ROLON, M. A., PION, I., THOMAS, C., DOZ, F., BARKAOUI, M., ROBERT, A., DEVILLE, A., MAZINGUE, F., DAVID, M., BRAUNER, R., CABROL, S., GAREL, C. & POLAK, M. 2004a. Incidence of growth hormone deficiency in pediatric-onset Langerhans cell histiocytosis: efficacy and safety of growth hormone treatment. *J Clin Endocrinol Metab*, 89, 604-9.
- DONADIEU, J., ROLON, M. A., THOMAS, C., BRUGIERES, L., PLANTAZ, D., EMILE, J. F., FRAPPAZ, D., DAVID, M., BRAUNER, R., GENEREAU, T., DEBRAY, D., CABROL, S., BARTHEZ, M. A., HOANG-XUAN, K. & POLAK, M. 2004b. Endocrine involvement in pediatric-onset Langerhans' cell histiocytosis: a population-based study. *J Pediatr*, 144, 344-50.
- DUERR, R. H., TAYLOR, K. D., BRANT, S. R., RIOUX, J. D., SILVERBERG, M. S., DALY, M. J., STEINHART, A. H., ABRAHAM, C., REGUEIRO, M., GRIFFITHS, A., DASSOPOULOS, T., BITTON, A., YANG, H., TARGAN, S., DATTA, L. W., KISTNER, E. O., SCHUMM, L. P., LEE, A. T., GREGERSEN, P. K., BARMADA, M. M., ROTTER, J. I., NICOLAE, D. L. & CHO, J. H. 2006. A genome-wide association study identifies IL23R as an inflammatory bowel disease gene. *Science*, 314, 1461-3.
- DUNGER, D. B., BROADBENT, V., YEOMAN, E., SECKL, J. R., LIGHTMAN, S. L., GRANT, D. B. & PRITCHARD, J. 1989. The frequency and natural history of diabetes insipidus in children with Langerhans-cell histiocytosis. *N Engl J Med*, 321, 1157-62.
- DZIEGIEL, P., DOLILNSKA-KRAJEWSKA, B., DUMANSKA, M., WECLAWEK, J., JELEN, M., PODHORSKA-OKOLOW, M., JAGODA, E., FIC, M. & ZABEL, M. 2007. Coexpression of CD1a, langerin and Birbeck's granules in Langerhans cell histiocytoses (LCH) in children: ultrastructural and immunocytochemical studies. *Folia Histochem Cytobiol*, 45, 21-5.
- EGELER, R. M. & D'ANGIO, G. J. 1995. Langerhans cell histiocytosis. *J Pediatr*, 127, 1-11.
- EGELER, R. M., DE KRAKER, J. & VOUTE, P. A. 1993a. Cytosine-arabinoside, vincristine, and prednisolone in the treatment of children with disseminated Langerhans cell histiocytosis with organ dysfunction: experience at a single institution. *Med Pediatr Oncol*, 21, 265-70.
- EGELER, R. M., FAVARA, B. E., LAMAN, J. D. & CLAASSEN, E. 2000. Abundant expression of CD40 and CD40-ligand (CD154) in paediatric Langerhans cell histiocytosis lesions. *Eur J Cancer*, 36, 2105-10.
- EGELER, R. M., FAVARA, B. E., VAN MEURS, M., LAMAN, J. D. & CLAASSEN, E. 1999. Differential In situ cytokine profiles of Langerhans-like cells and T cells in Langerhans cell histiocytosis: abundant expression of cytokines relevant to disease and treatment. *Blood*, 94, 4195-201.
- EGELER, R. M., NEGLIA, J. P., ARICO, M., FAVARA, B. E., HEITGER, A., NESBIT, M. E. & NICHOLSON, H. S. 1998. The relation of Langerhans cell histiocytosis to acute leukemia, lymphomas, and other solid tumors. The LCH-Malignancy Study Group of the Histiocyte Society. *Hematol Oncol Clin North Am*, 12, 369-78.

- EGELER, R. M., NEGLIA, J. P., PUC CETTI, D. M., BRENNAN, C. A. & NESBIT, M. E. 1993b. Association of Langerhans cell histiocytosis with malignant neoplasms. *Cancer*, 71, 865-73.
- EGELER, R. M., VAN HALTEREN, A. G., HOGENDOORN, P. C., LAMAN, J. D. & LEENEN, P. J. 2010. Langerhans cell histiocytosis: fascinating dynamics of the dendritic cell-macrophage lineage. *Immunol Rev*, 234, 213-32.
- EGELER, R. M. & WILLMAN, C. L. 2000. Is Langerhans cell histiocytosis a myeloid dendritic stem cell disorder related to myelodysplastic disorders? *Med Pediatr Oncol*, 35, 426-7.
- EMILE, J. F., FRAITAG, S., LEBORGNE, M., DE PROST, Y. & BROUSSE, N. 1994a. Langerhans' cell histiocytosis cells are activated Langerhans' cells. *J Pathol*, 174, 71-6.
- EMILE, J. F., TARTOUR, E., BRUGIERES, L., DONADIEU, J., LE DEIST, F., CHARNOZ, I., FISCHER, A., FRIDMAN, W. H. & BROUSSE, N. 1994b. Detection of GM-CSF in the sera of children with Langerhans' cell histiocytosis. *Pediatr Allergy Immunol*, 5, 162-3.
- FACCO, M., CABRELLE, A., TERAMO, A., OLIVIERI, V., GNOATO, M., TEOLATO, S., AVE, E., GATTAZZO, C., FADINI, G. P., CALABRESE, F., SEMENZATO, G. & AGOSTINI, C. 2011. Sarcoidosis is a Th1/Th17 multisystem disorder. *Thorax*, 66, 144-50.
- FARBER, S. 1941. The nature of "Solitary or Eosinophilic Granuloma" of bone. *Am J Pathol*, 17, 625-29.
- FAVARA, B. E., FELLER, A. C., PAULI, M., JAFFE, E. S., WEISS, L. M., ARICO, M., BUCKSKY, P., EGELER, R. M., ELINDER, G., GADNER, H., GRESIK, M., HENTER, J. I., IMASHUKU, S., JANKA-SCHAUB, G., JAFFE, R., LADISCH, S., NEZELOF, C. & PRITCHARD, J. 1997. Contemporary classification of histiocytic disorders. The WHO Committee On Histiocytic/Reticulum Cell Proliferations. Reclassification Working Group of the Histiocyte Society. *Med Pediatr Oncol*, 29, 157-66.
- FAVARA, B. E. & JAFFE, R. 1994. The histopathology of Langerhans cell histiocytosis. *Br J Cancer Suppl*, 23, S17-23.
- FAVARA, B. E. & STEELE, A. 1997. Langerhans cell histiocytosis of lymph nodes: a morphological assessment of 43 biopsies. *Pediatr Pathol Lab Med*, 17, 769-87.
- FEUERHAKE, F., KUTOK, J. L., MONTI, S., CHEN, W., LACASCE, A. S., CATTORETTI, G., KURTIN, P., PINKUS, G. S., DE LEVAL, L., HARRIS, N. L., SAVAGE, K. J., NEUBERG, D., HABERMANN, T. M., DALLA-FAVERA, R., GOLUB, T. R., ASTER, J. C. & SHIPP, M. A. 2005. NFkappaB activity, function, and target-gene signatures in primary mediastinal large B-cell lymphoma and diffuse large B-cell lymphoma subtypes. *Blood*, 106, 1392-9.
- FISCHER, A., JONES, L. & LOWIS, S. P. 1999. Concurrent Langerhans cell histiocytosis and neuroblastoma. *Med Pediatr Oncol*, 32, 223-4.
- FLEMING, M. D., PINKUS, J. L., FOURNIER, M. V., ALEXANDER, S. W., TAM, C., LODA, M., SALLAN, S. E., NICHOLS, K. E., CARPENTIERI, D. F., PINKUS, G. S. & ROLLINS, B. J. 2003. Coincident expression of the chemokine receptors CCR6 and CCR7 by pathologic Langerhans cells in Langerhans cell histiocytosis. *Blood*, 101, 2473-5.
- FOIX-L'HELIAS, L., AERTS, I., MARCHAND, L., LUMBROSO-LE ROUIC, L., GAUTHIER-VILLARS, M., LABRUNE, P., BOUYER, J., DOZ, F. & KAMINSKI, M. 2012. Are children born after infertility treatment at increased risk of retinoblastoma? *Hum Reprod*, 27, 2186-92.

- FORLOW, S. B., SCHURR, J. R., KOLLS, J. K., BAGBY, G. J., SCHWARZENBERGER, P. O. & LEY, K. 2001. Increased granulopoiesis through interleukin-17 and granulocyte colony-stimulating factor in leukocyte adhesion molecule-deficient mice. *Blood*, 98, 3309-14.
- FOSS, H. D., HERBST, H., ARAUJO, I., HUMMEL, M., BERG, E., SCHMITT-GRAFF, A. & STEIN, H. 1996. Monokine expression in Langerhans' cell histiocytosis and sinus histiocytosis with massive lymphadenopathy (Rosai-Dorfman disease). *J Pathol*, 179, 60-5.
- FRENZEL, A., GRESPI, F., CHMELEWSKI, W. & VILLUNGER, A. 2009. Bcl2 family proteins in carcinogenesis and the treatment of cancer. *Apoptosis*, 14, 584-96.
- FUJIKAWA, Y., QUINN, J. M., SABOKBAR, A., MCGEE, J. O. & ATHANASOU, N. A. 1996. The human osteoclast precursor circulates in the monocyte fraction. *Endocrinology*, 137, 4058-60.
- FUJINO, S., ANDOH, A., BAMBA, S., OGAWA, A., HATA, K., ARAKI, Y., BAMBA, T. & FUJIYAMA, Y. 2003. Increased expression of interleukin 17 in inflammatory bowel disease. *Gut*, 52, 65-70.
- FUNK, J. O., WALCZAK, H., VOIGTLANDER, C., BERCHTOLD, S., BAUMEISTER, T., RAUCH, P., ROSSNER, S., STEINKASSERER, A., SCHULER, G. & LUTZ, M. B. 2000. Cutting edge: resistance to apoptosis and continuous proliferation of dendritic cells deficient for TNF receptor-1. *J Immunol*, 165, 4792-6.
- GABRILOVICH, D. 2004. Mechanisms and functional significance of tumour-induced dendritic-cell defects. *Nat Rev Immunol*, 4, 941-52.
- GABRILOVICH, D. I. & NAGARAJ, S. 2009. Myeloid-derived suppressor cells as regulators of the immune system. *Nat Rev Immunol*, 9, 162-74.
- GADNER, H., GROIS, N., ARICO, M., BROADBENT, V., CECI, A., JAKOBSON, A., KOMP, D., MICHAELIS, J., NICHOLSON, S., POTSCGER, U., PRITCHARD, J. & LADISCH, S. 2001. A randomized trial of treatment for multisystem Langerhans' cell histiocytosis. *J Pediatr*, 138, 728-34.
- GADNER, H., GROIS, N., POTSCGER, U., MINKOV, M., ARICO, M., BRAIER, J., BROADBENT, V., DONADIEU, J., HENTER, J. I., MCCARTER, R. & LADISCH, S. 2008. Improved outcome in multisystem Langerhans cell histiocytosis is associated with therapy intensification. *Blood*, 111, 2556-62.
- GADNER, H., HEITGER, A., GROIS, N., GATTERER-MENZ, I. & LADISCH, S. 1994. Treatment strategy for disseminated Langerhans cell histiocytosis. DAL HX-83 Study Group. *Med Pediatr Oncol*, 23, 72-80.
- GADNER, H., MINKOV, M., GROIS, N., POTSCGER, U., THIEM, E., ARICO, M., ASTIGARRAGA, I., BRAIER, J., DONADIEU, J., HENTER, J. I., JANKA-SCHAUB, G., MCCLAIN, K. L., WEITZMAN, S., WINDEBANK, K. & LADISCH, S. 2013. Therapy prolongation improves outcome in multisystem Langerhans cell histiocytosis. *Blood*, 121, 5006-14.
- GALLO, R. L. & HOOPER, L. V. 2012. Epithelial antimicrobial defence of the skin and intestine. *Nat Rev Immunol*, 12, 503-16.
- GARABEDIAN, L., STRUYF, S., OPDENAKKER, G., SOZZANI, S., VAN DAMME, J. & LAUREYS, G. 2011. Langerhans cell histiocytosis: a cytokine/chemokine-mediated disorder? *Eur Cytokine Netw*, 22, 148-53.
- GAVHED, D., LAURENCIKAS, E., AKEFELDT, S. O. & HENTER, J. I. 2011. Fifteen years of treatment with intravenous immunoglobulin in central nervous system Langerhans cell histiocytosis. *Acta Paediatr*, 100, e36-9.

- GEISSMANN, F., EMILE, J. F., ANDRY, P., THOMAS, C., FRAITAG, S., DE PROST, Y. & BROUSSE, N. 1997. Lack of expression of E-cadherin is associated with dissemination of Langerhans' cell histiocytosis and poor outcome. *J Pathol*, 181, 301-4.
- GEISSMANN, F., LEPELLETIER, Y., FRAITAG, S., VALLADEAU, J., BODEMER, C., DEBRE, M., LEBORGNE, M., SAELAND, S. & BROUSSE, N. 2001. Differentiation of Langerhans cells in Langerhans cell histiocytosis. *Blood*, 97, 1241-8.
- GEISSMANN, F., MANZ, M. G., JUNG, S., SIEWEKE, M. H., MERAD, M. & LEY, K. 2010. Development of monocytes, macrophages, and dendritic cells. *Science*, 327, 656-61.
- GEISSMANN, F., PROST, C., MONNET, J. P., DY, M., BROUSSE, N. & HERMINE, O. 1998. Transforming growth factor beta1, in the presence of granulocyte/macrophage colony-stimulating factor and interleukin 4, induces differentiation of human peripheral blood monocytes into dendritic Langerhans cells. *J Exp Med*, 187, 961-6.
- GHIRINGHELLI, F., PUIG, P. E., ROUX, S., PARCELLIER, A., SCHMITT, E., SOLARY, E., KROEMER, G., MARTIN, F., CHAUFFERT, B. & ZITVOGEL, L. 2005. Tumor cells convert immature myeloid dendritic cells into TGF-beta-secreting cells inducing CD4+CD25+ regulatory T cell proliferation. *J Exp Med*, 202, 919-29.
- GHOSAL, N., KAPILA, K., KAKKAR, S. & VERMA, K. 2001. Langerhans cell histiocytosis infiltration in cerebrospinal fluid: a case report. *Diagn Cytopathol*, 24, 123-5.
- GINHOUX, F., COLLIN, M. P., BOGUNOVIC, M., ABEL, M., LEBOEUF, M., HELFT, J., OCHANDO, J., KISSENPFENNIG, A., MALISSEN, B., GRISOTTO, M., SNOECK, H., RANDOLPH, G. & MERAD, M. 2007. Blood-derived dermal langerin+ dendritic cells survey the skin in the steady state. *J Exp Med*, 204, 3133-46.
- GINHOUX, F., TACKE, F., ANGELI, V., BOGUNOVIC, M., LOUBEAU, M., DAI, X. M., STANLEY, E. R., RANDOLPH, G. J. & MERAD, M. 2006. Langerhans cells arise from monocytes in vivo. *Nat Immunol*, 7, 265-73.
- GIORDANO, P., CECINATI, V., GRASSI, M., GIORDANI, L., DE MATTIA, D. & SANTORO, N. 2011. Langerhans cell histiocytosis in a pediatric patient with thrombocytopenia-absent radius syndrome and 1q21.1 deletion: case report and proposal of a rapid molecular diagnosis of 1q21.1 deletion. *Immunopharmacol Immunotoxicol*, 33, 754-8.
- GIRSCHIKOVSKY, M., ARICO, M., CASTILLO, D., CHU, A., DOBERAUER, C., FICHTER, J., HAROCHE, J., KALTSAS, G. A., MAKRAS, P., MARZANO, A. V., DE MENTHON, M., MICKE, O., PASSONI, E., SEEGENSCHMIEDT, H. M., TAZI, A. & MCCLAIN, K. L. 2013. Management of adult patients with Langerhans cell histiocytosis: recommendations from an expert panel on behalf of Euro-Histio-Net. *Orphanet J Rare Dis*, 8, 72.
- GOBERT, M., TREILLEUX, I., BENDRISS-VERMARE, N., BACHELOT, T., GODDARD-LEON, S., ARFI, V., BIOTA, C., DOFFIN, A. C., DURAND, I., OLIVE, D., PEREZ, S., PASQUAL, N., FAURE, C., RAY-COQUARD, I., PUISIEUX, A., CAUX, C., BLAY, J. Y. & MENETRIER-CAUX, C. 2009. Regulatory T cells recruited through CCL22/CCR4 are selectively activated in lymphoid infiltrates surrounding primary breast tumors and lead to an adverse clinical outcome. *Cancer Res*, 69, 2000-9.

- GRAUS, F. & DALMAU, J. 2007. Paraneoplastic neurological syndromes: diagnosis and treatment. *Curr Opin Neurol*, 20, 732-7.
- GROIS, N., FAHRNER, B., ARCECI, R. J., HENTER, J. I., MCCLAIN, K., LASSMANN, H., NANDURI, V., PROSCH, H. & PRAYER, D. 2010. Central nervous system disease in Langerhans cell histiocytosis. *J Pediatr*, 156, 873-81, 881 e1.
- GROIS, N., FLUCHER-WOLFRAM, B., HEITGER, A., MOSTBECK, G. H., HOFMANN, J. & GADNER, H. 1995. Diabetes insipidus in Langerhans cell histiocytosis: results from the DAL-HX 83 study. *Med Pediatr Oncol*, 24, 248-56.
- GROIS, N., POTSCHEGER, U., PROSCH, H., MINKOV, M., ARICO, M., BRAIER, J., HENTER, J. I., JANKA-SCHAUB, G., LADISCH, S., RITTER, J., STEINER, M., UNGER, E. & GADNER, H. 2006. Risk factors for diabetes insipidus in langerhans cell histiocytosis. *Pediatr Blood Cancer*, 46, 228-33.
- GROIS, N., PRAYER, D., PROSCH, H. & LASSMANN, H. 2005. Neuropathology of CNS disease in Langerhans cell histiocytosis. *Brain*, 128, 829-38.
- GROIS, N., PROSCH, H., WALDHAUSER, F., MINKOV, M., STRASSER, G., STEINER, M., UNGER, E. & PRAYER, D. 2004. Pineal gland abnormalities in Langerhans cell histiocytosis. *Pediatr Blood Cancer*, 43, 261-6.
- GROIS, N., TSUNEMATSU, Y., BARKOVICH, A. J. & FAVARA, B. E. 1994. Central nervous system disease in Langerhans cell histiocytosis. *Br J Cancer Suppl*, 23, S24-8.
- GROIS, N. G., FAVARA, B. E., MOSTBECK, G. H. & PRAYER, D. 1998. Central nervous system disease in Langerhans cell histiocytosis. *Hematol Oncol Clin North Am*, 12, 287-305.
- GROUP, T. F. L. C. H. S. 1996. A multicentre retrospective survey of Langerhans' cell histiocytosis: 348 cases observed between 1983 and 1993. *Arch Dis Child*, 75, 17-24.
- GUYOT-GOUBIN, A., DONADIEU, J., BARKAOUI, M., BELLEC, S., THOMAS, C. & CLAVEL, J. 2008. Descriptive epidemiology of childhood Langerhans cell histiocytosis in France, 2000-2004. *Pediatr Blood Cancer*, 51, 71-5.
- HAGE, C., WILLMAN, C. L., FAVARA, B. E. & ISAACSON, P. G. 1993. Langerhans' cell histiocytosis (histiocytosis X): immunophenotype and growth fraction. *Hum Pathol*, 24, 840-5.
- HAMILTON, S. R., GUPTA, P. K., MARSHALL, M. E., DONOVAN, P. A., WINGARD, J. R. & ZAATARI, G. S. 1982. Cerebrospinal fluid cytology in histiocytic proliferative disorders. *Acta Cytol*, 26, 22-8.
- HAMOUDI, A. B., NEWTON, W. A., JR., MANCER, K. & PENN, G. M. 1982. Thymic changes in histiocytosis. *Am J Clin Pathol*, 77, 169-73.
- HAMRE, M., HEDBERG, J., BUCKLEY, J., BHATIA, S., FINLAY, J., MEADOWS, A., NESBIT, M., SMITHSON, A. & ROBISON, L. 1997. Langerhans cell histiocytosis: an exploratory epidemiologic study of 177 cases. *Med Pediatr Oncol*, 28, 92-7.
- HANAIAH, F., YAACOB, H., GHANI, K. S. & HUSSIN, A. S. 1993. Histiocytosis X: evidence for a genetic etiology. *J Nihon Univ Sch Dent*, 35, 171-4.
- HAND, A. 1893. Polyuria and tuberculosis. *Arch Pediatr*, 10, 673-675.
- HAND, A. 1921. Defects of membranous bones, exophthalmos and polyuria in childhood: is it dyspituitarism? *Am J Med Science*, 162, 509-515.
- HAROCHE, J., CHARLOTTE, F., ARNAUD, L., VON DEIMLING, A., HELIAS-RODZEWICZ, Z., HERVIER, B., COHEN-AUBART, F., LAUNAY, D., LESOT, A., MOKHTARI, K., CANIONI, D., GALMICHE, L., ROSE, C.,

- SCHMALZING, M., CROOCKEWIT, S., KAMBOUCHNER, M., COPIN, M. C., FRAITAG, S., SAHM, F., BROUSSE, N., AMOURA, Z., DONADIEU, J. & EMILE, J. F. 2012. High prevalence of BRAF V600E mutations in Erdheim-Chester disease but not in other non-Langerhans cell histiocytoses. *Blood*, 120, 2700-3.
- HAROCHE, J., COHEN-AUBART, F., EMILE, J. F., ARNAUD, L., MAKSUD, P., CHARLOTTE, F., CLUZEL, P., DRIER, A., HERVIER, B., BENAMEUR, N., BESNARD, S., DONADIEU, J. & AMOURA, Z. 2013. Dramatic efficacy of vemurafenib in both multisystemic and refractory Erdheim-Chester disease and Langerhans cell histiocytosis harboring the BRAF V600E mutation. *Blood*, 121, 1495-500.
- HARRINGTON, L. E., HATTON, R. D., MANGAN, P. R., TURNER, H., MURPHY, T. L., MURPHY, K. M. & WEAVER, C. T. 2005. Interleukin 17-producing CD4+ effector T cells develop via a lineage distinct from the T helper type 1 and 2 lineages. *Nat Immunol*, 6, 1123-32.
- HART, D. N. 1997. Dendritic cells: unique leukocyte populations which control the primary immune response. *Blood*, 90, 3245-87.
- HARTUPEE, J., LIU, C., NOVOTNY, M., LI, X. & HAMILTON, T. 2007. IL-17 enhances chemokine gene expression through mRNA stabilization. *J Immunol*, 179, 4135-41.
- HASHIMOTO, K. & PRITZKER, M. S. 1973. Electron microscopic study of reticulohistiocytoma. An unusual case of congenital, self-healing reticulohistiocytosis. *Arch Dermatol*, 107, 263-70.
- HAUDENSCHILD, D., MOSELEY, T., ROSE, L. & REDDI, A. H. 2002. Soluble and transmembrane isoforms of novel interleukin-17 receptor-like protein by RNA splicing and expression in prostate cancer. *J Biol Chem*, 277, 4309-16.
- HAUPT, R., FEARS, T. R., HEISE, A., GADNER, H., LOIACONO, G., DE TERLIZZI, M. & TUCKER, M. A. 1997. Risk of secondary leukemia after treatment with etoposide (VP-16) for Langerhans' cell histiocytosis in Italian and Austrian-German populations. *Int J Cancer*, 71, 9-13.
- HAUPT, R., NANDURI, V., CALEVO, M. G., BERNSTRAND, C., BRAIER, J. L., BROADBENT, V., REY, G., MCCLAIN, K. L., JANKA-SCHAUB, G. & EGELER, R. M. 2004. Permanent consequences in Langerhans cell histiocytosis patients: a pilot study from the Histiocyte Society-Late Effects Study Group. *Pediatr Blood Cancer*, 42, 438-44.
- HE, D., LI, H., YUSUF, N., ELMETS, C. A., LI, J., MOUNTZ, J. D. & XU, H. 2010. IL-17 promotes tumor development through the induction of tumor promoting microenvironments at tumor sites and myeloid-derived suppressor cells. *J Immunol*, 184, 2281-8.
- HEINE, H. & LIEN, E. 2003. Toll-like receptors and their function in innate and adaptive immunity. *Int Arch Allergy Immunol*, 130, 180-92.
- HENTER, J. I., KARLEN, J., CALMING, U., BERNSTRAND, C., ANDERSSON, U. & FADEEL, B. 2001. Successful treatment of Langerhans'-cell histiocytosis with etanercept. *N Engl J Med*, 345, 1577-8.
- HENTER, J. I., TONDINI, C. & PRITCHARD, J. 2004. Histiocyte disorders. *Crit Rev Oncol Hematol*, 50, 157-74.
- HETTINGER, J., RICHARDS, D. M., HANSSON, J., BARRA, M. M., JOSCHKO, A. C., KRIJGSVELD, J. & FEUERER, M. 2013. Origin of monocytes and macrophages in a committed progenitor. *Nat Immunol*, 14, 821-30.
- HIROTA, K., YOSHITOMI, H., HASHIMOTO, M., MAEDA, S., TERADAIRA, S., SUGIMOTO, N., YAMAGUCHI, T., NOMURA, T., ITO, H., NAKAMURA,

- T., SAKAGUCHI, N. & SAKAGUCHI, S. 2007. Preferential recruitment of CCR6-expressing Th17 cells to inflamed joints via CCL20 in rheumatoid arthritis and its animal model. *J Exp Med*, 204, 2803-12.
- HOU, W., KANG, H. S. & KIM, B. S. 2009. Th17 cells enhance viral persistence and inhibit T cell cytotoxicity in a model of chronic virus infection. *J Exp Med*, 206, 313-28.
- HOWARTH, D. M., GILCHRIST, G. S., MULLAN, B. P., WISEMAN, G. A., EDMONSON, J. H. & SCHOMBERG, P. J. 1999. Langerhans cell histiocytosis: diagnosis, natural history, management, and outcome. *Cancer*, 85, 2278-90.
- HUANG, F. & ARCECI, R. 1999. The histiocytoses of infancy. *Semin Perinatol*, 23, 319-31.
- HUANG, W., NA, L., FIDEL, P. L. & SCHWARZENBERGER, P. 2004. Requirement of interleukin-17A for systemic anti-Candida albicans host defense in mice. *J Infect Dis*, 190, 624-31.
- HUIRNE, J. A., LAMBALK, C. B., VAN LOENEN, A. C., SCHATS, R., HOMPES, P. G., FAUSER, B. C. & MACKLON, N. S. 2004. Contemporary pharmacological manipulation in assisted reproduction. *Drugs*, 64, 297-322.
- HUTTER, C., KAUER, M., SIMONITSCH-KLUPP, I., JUG, G., SCHWENTNER, R., LEITNER, J., BOCK, P., STEINBERGER, P., BAUER, W., CARLESSO, N., MINKOV, M., GADNER, H., STINGL, G., KOVAR, H. & KRIEHLBER, E. 2012. Notch is active in Langerhans cell histiocytosis and confers pathognomonic features on dendritic cells. *Blood*, 120, 5199-208.
- IDOYAGA, J., SUDA, N., SUDA, K., PARK, C. G. & STEINMAN, R. M. 2009. Antibody to Langerin/CD207 localizes large numbers of CD8alpha+ dendritic cells to the marginal zone of mouse spleen. *Proc Natl Acad Sci U S A*, 106, 1524-9.
- IMASHUKU, S., ISHIDA, S., KOIKE, K., ICHIKAWA, M., MINATO, T., SUZUKI, Y., KOBAYASHI, R. & MORIMOTO, A. 2004. Cerebellar ataxia in pediatric patients with Langerhans cell histiocytosis. *J Pediatr Hematol Oncol*, 26, 735-9.
- IMASHUKU, S., OKAZAKI, N., NAKAYAMA, M., FUJITA, N., FUKUYAMA, T., KOIKE, K., MINATO, T., KOBAYASHI, R. & MORIMOTO, A. 2008. Treatment of neurodegenerative CNS disease in Langerhans cell histiocytosis with a combination of intravenous immunoglobulin and chemotherapy. *Pediatr Blood Cancer*, 50, 308-11.
- IRVING, R. M., BROADBENT, V. & JONES, N. S. 1994. Langerhans' cell histiocytosis in childhood: management of head and neck manifestations. *Laryngoscope*, 104, 64-70.
- ISHII, K., KURITA-TANIGUCHI, M., AOKI, M., KIMURA, T., KASHIWAZAKI, Y., MATSUMOTO, M. & SEYA, T. 2005. Gene-inducing program of human dendritic cells in response to BCG cell-wall skeleton (CWS), which reflects adjuvancy required for tumor immunotherapy. *Immunol Lett*, 98, 280-90.
- ISHII, R., MORIMOTO, A., IKUSHIMA, S., SUGIMOTO, T., ASAMI, K., BESSHO, F., KUDO, K., TSUNEMATU, Y., FUJIMOTO, J. & IMASHUKU, S. 2006. High serum values of soluble CD154, IL-2 receptor, RANKL and osteoprotegerin in Langerhans cell histiocytosis. *Pediatr Blood Cancer*, 47, 194-9.
- IWAKURA, Y., ISHIGAME, H., SAIJO, S. & NAKAE, S. 2011. Functional specialization of interleukin-17 family members. *Immunity*, 34, 149-62.

- JACKSON, R. A., GIBSON, K. A., WU, Y. W. & CROUGHAN, M. S. 2004. Perinatal outcomes in singletons following in vitro fertilization: a meta-analysis. *Obstet Gynecol*, 103, 551-63.
- JAFFE, R. 2004. Liver involvement in the histiocytic disorders of childhood. *Pediatr Dev Pathol*, 7, 214-25.
- JAFFE, R., WEISS, L. M. & F., F. 2008. Tumors derived from Langerhans cells *In*: SWERDLOW SH, C. E., HARRIS NL, JAFFE ES, PILERI SA, STEIN H (ed.) *WHO Classification of Tumors of Hematopoietic and Lymphoid Tissues*. Lyon: World Health Organization.
- JAKOBSON, A. M., KREUGER, A., HAGBERG, H. & SUNDSTROM, C. 1987. Treatment of Langerhans cell histiocytosis with alpha-interferon. *Lancet*, 2, 1520-1.
- JAKSITS, S., KRIEHLER, E., CHARBONNIER, A. S., RAPPERSBERGER, K., STINGL, G. & MAURER, D. 1999. CD34+ cell-derived CD14+ precursor cells develop into Langerhans cells in a TGF-beta 1-dependent manner. *J Immunol*, 163, 4869-77.
- JANEWAY, C. A., JR. & MEDZHITOV, R. 2002. Innate immune recognition. *Annu Rev Immunol*, 20, 197-216.
- JANKA, G. E. 2012. Familial and acquired hemophagocytic lymphohistiocytosis. *Annu Rev Med*, 63, 233-46.
- JENSON, H. B., MCCLAIN, K. L., LEACH, C. T., DENG, J. H. & GAO, S. J. 2000. Evaluation of human herpesvirus type 8 infection in childhood langerhans cell histiocytosis. *Am J Hematol*, 64, 237-41.
- JEZIORSKI, E., SENECHAL, B., MOLINA, T. J., DEVEZ, F., LERUEZ-VILLE, M., MORAND, P., GLORION, C., MANSUY, L., GAUDELUS, J., DEBRE, M., JAUBERT, F., SEIGNEURIN, J. M., THOMAS, C., JOAB, I., DONADIEU, J. & GEISSMANN, F. 2008. Herpes-virus infection in patients with Langerhans cell histiocytosis: a case-controlled sero-epidemiological study, and in situ analysis. *PLoS One*, 3, e3262.
- KAGER, L., HEISE, A., MINKOV, M., MOBIUS, D., KOTTE, W., SCHULTE-OVERBERG, U., HENZE, G. & GADNER, H. 1999. Occurrence of acute nonlymphoblastic leukemia in two girls after treatment of recurrent, disseminated Langerhans cell histiocytosis. *Pediatr Hematol Oncol*, 16, 251-6.
- KAMATH, A. T., HENRI, S., BATTYE, F., TOUGH, D. F. & SHORTMAN, K. 2002. Developmental kinetics and lifespan of dendritic cells in mouse lymphoid organs. *Blood*, 100, 1734-41.
- KEBIR, H., KREYMBORG, K., IFERGAN, I., DODELET-DEVILLERS, A., CAYROL, R., BERNARD, M., GIULIANI, F., ARBOUR, N., BECHER, B. & PRAT, A. 2007. Human TH17 lymphocytes promote blood-brain barrier disruption and central nervous system inflammation. *Nat Med*, 13, 1173-5.
- KELLNER, H. 2013. Targeting interleukin-17 in patients with active rheumatoid arthritis: rationale and clinical potential. *Ther Adv Musculoskelet Dis*, 5, 141-52.
- KELLY, G. L. & STRASSER, A. 2011. The essential role of evasion from cell death in cancer. *Adv Cancer Res*, 111, 39-96.
- KELLY, M. N., KOLLS, J. K., HAPPEL, K., SCHWARTZMAN, J. D., SCHWARZENBERGER, P., COMBE, C., MORETTO, M. & KHAN, I. A. 2005. Interleukin-17/interleukin-17 receptor-mediated signaling is important for generation of an optimal polymorphonuclear response against *Toxoplasma gondii* infection. *Infect Immun*, 73, 617-21.
- KHADEMI, M., DRING, A. M., GILTHORPE, J. D., WUOLIKAINEN, A., AL NIMER, F., HARRIS, R. A., ANDERSSON, M., BRUNDIN, L., PIEHL, F.,

- OLSSON, T. & SVENNINGSSON, A. 2013. Intense inflammation and nerve damage in early multiple sclerosis subsides at older age: a reflection by cerebrospinal fluid biomarkers. *PLoS One*, 8, e63172.
- KHADER, S. A., BELL, G. K., PEARL, J. E., FOUNTAIN, J. J., RANGEL-MORENO, J., CILLEY, G. E., SHEN, F., EATON, S. M., GAFFEN, S. L., SWAIN, S. L., LOCKSLEY, R. M., HAYNES, L., RANDALL, T. D. & COOPER, A. M. 2007. IL-23 and IL-17 in the establishment of protective pulmonary CD4⁺ T cell responses after vaccination and during *Mycobacterium tuberculosis* challenge. *Nat Immunol*, 8, 369-77.
- KHADER, S. A. & GOPAL, R. 2010. IL-17 in protective immunity to intracellular pathogens. *Virulence*, 1, 423-7.
- KHOSLA, S., DEAN, W., BROWN, D., REIK, W. & FEIL, R. 2001. Culture of preimplantation mouse embryos affects fetal development and the expression of imprinted genes. *Biol Reprod*, 64, 918-26.
- KINGSTON, D., SCHMID, M. A., ONAI, N., OBATA-ONAI, A., BAUMJOHANN, D. & MANZ, M. G. 2009. The concerted action of GM-CSF and Flt3-ligand on in vivo dendritic cell homeostasis. *Blood*, 114, 835-43.
- KISCHKEL, F. C., HELLBARDT, S., BEHRMANN, I., GERMER, M., PAWLITA, M., KRAMMER, P. H. & PETER, M. E. 1995. Cytotoxicity-dependent APO-1 (Fas/CD95)-associated proteins form a death-inducing signaling complex (DISC) with the receptor. *EMBO J*, 14, 5579-88.
- KLIP, H., BURGER, C. W., DE KRAKER, J. & VAN LEEUWEN, F. E. 2001. Risk of cancer in the offspring of women who underwent ovarian stimulation for IVF. *Hum Reprod*, 16, 2451-8.
- KOLLS, J. K. & LINDEN, A. 2004. Interleukin-17 family members and inflammation. *Immunity*, 21, 467-76.
- KOMP, D. M., VIETTI, T. J., BERRY, D. H., STARLING, K. A., HAGGARD, M. E. & GEORGE, S. L. 1977. Combination chemotherapy in histiocytosis X. *Med Pediatr Oncol*, 3, 267-73.
- KOTAKE, S., UDAGAWA, N., TAKAHASHI, N., MATSUZAKI, K., ITOH, K., ISHIYAMA, S., SAITO, S., INOUE, K., KAMATANI, N., GILLESPIE, M. T., MARTIN, T. J. & SUDA, T. 1999. IL-17 in synovial fluids from patients with rheumatoid arthritis is a potent stimulator of osteoclastogenesis. *J Clin Invest*, 103, 1345-52.
- KOZOPAS, K. M., YANG, T., BUCHAN, H. L., ZHOU, P. & CRAIG, R. W. 1993. MCL1, a gene expressed in programmed myeloid cell differentiation, has sequence similarity to BCL2. *Proc Natl Acad Sci U S A*, 90, 3516-20.
- KRAMER, J. M., YI, L., SHEN, F., MAITRA, A., JIAO, X., JIN, T. & GAFFEN, S. L. 2006. Evidence for ligand-independent multimerization of the IL-17 receptor. *J Immunol*, 176, 711-5.
- KRIEHLER, E., BAUER, W., CHARBONNIER, A. S., WINTER, D., AMATSCHEK, S., TAMANDL, D., SCHWEIFER, N., STINGL, G. & MAURER, D. 2005. Balance between NF-kappaB and JNK/AP-1 activity controls dendritic cell life and death. *Blood*, 106, 175-83.
- KRYCZEK, I., WEI, S., SZELIGA, W., VATAN, L. & ZOU, W. 2009. Endogenous IL-17 contributes to reduced tumor growth and metastasis. *Blood*, 114, 357-9.
- KUESTNER, R. E., TAFT, D. W., HARAN, A., BRANDT, C. S., BRENDER, T., LUM, K., HARDER, B., OKADA, S., OSTRANDER, C. D., KREINDLER, J. L., AUJLA, S. J., REARDON, B., MOORE, M., SHEA, P., SCHRECKHISE, R., BUKOWSKI, T. R., PRESNELL, S., GUERRA-LEWIS, P., PARRISH-NOVAK, J., ELLSWORTH, J. L., JASPERS, S., LEWIS, K. E., APPLEBY,

- M., KOLLS, J. K., RIXON, M., WEST, J. W., GAO, Z. & LEVIN, S. D. 2007. Identification of the IL-17 receptor related molecule IL-17RC as the receptor for IL-17F. *J Immunol*, 179, 5462-73.
- KÄLLÉN, B., FINNSTRÖM, O., LINDAM, A., NILSSON, E., NYGREN, K. G. & OLAUSSON, P. O. 2010. Cancer risk in children and young adults conceived by in vitro fertilization. *Pediatrics*, 126, 270-6.
- KÄLLÉN, B., FINNSTRÖM, O., NYGREN, K. G. & OLAUSSON, P. O. 2005. In vitro fertilization in Sweden: child morbidity including cancer risk. *Fertil Steril*, 84, 605-10.
- LAHEY, E. 1975a. Histiocytosis x--an analysis of prognostic factors. *J Pediatr*, 87, 184-9.
- LAHEY, M. E. 1975b. Histiocytosis X--comparison of three treatment regimens. *J Pediatr*, 87, 179-83.
- LAHEY, M. E., HEYN, R., LADISCH, S., LEIKIN, S., NEERHOUT, R., NEWTON, W., SHORE, N., SMITH, B., WARA, W. & HAMMOND, D. 1985. Hypergammaglobulinemia in histiocytosis X. *J Pediatr*, 107, 572-4.
- AMAN, J. D., LEENEN, P. J., ANNELS, N. E., HOGENDOORN, P. C. & EGELER, R. M. 2003. Langerhans-cell histiocytosis 'insight into DC biology'. *Trends Immunol*, 24, 190-6.
- LANGHERHANS, P. 1868. Über die Nerven der menschlichen Haut. . *Arch Pathol Anat*, 44, 325-337.
- LAU, S. K., CHU, P. G. & WEISS, L. M. 2008. Immunohistochemical expression of Langerin in Langerhans cell histiocytosis and non-Langerhans cell histiocytic disorders. *Am J Surg Pathol*, 32, 615-9.
- LAURENCIKAS, E., GAVHED, D., STALEMARK, H., HOOFT, I. V., PRAYER, D., GROIS, N. & HENTER, J. I. 2011. Incidence and pattern of radiological central nervous system Langerhans cell histiocytosis in children: A population based study. *Pediatr Blood Cancer*, 56, 250-7.
- LEAHY, M. A., KREJCI, S. M., FRIEDNASH, M., STOCKERT, S. S., WILSON, H., HUFF, J. C., WESTON, W. L. & BRICE, S. L. 1993. Human herpesvirus 6 is present in lesions of Langerhans cell histiocytosis. *J Invest Dermatol*, 101, 642-5.
- LEE-ELLIOTT, C., ALEXANDER, J., GOULD, A., TALBOT, R. & SNOOK, J. A. 1996. Langerhan's cell histiocytosis complicating small bowel Crohn's disease. *Gut*, 38, 296-8.
- LEE, I., FINGER, P. T., GRIFO, J. A., RAUSEN, A. R., REBARBER, A. & BARAD, D. H. 2004. Retinoblastoma in a child conceived by in vitro fertilisation. *Br J Ophthalmol*, 88, 1098-9.
- LEE, S. Y., KWOK, S. K., SON, H. J., RYU, J. G., KIM, E. K., OH, H. J., CHO, M. L., JU, J. H., PARK, S. H. & KIM, H. Y. 2013. IL-17-mediated Bcl-2 expression regulates survival of fibroblast-like synoviocytes in rheumatoid arthritis through STAT3 activation. *Arthritis Res Ther*, 15, R31.
- LETTERER, E. 1924. Aleukämische retikulose (Ein Beitrag zu den proliferativen Erkrankungen des Retikuloendothelialapparates). *Frankfurter Zeitschrift Pathol*, 30, 377-394.
- LEVENDOGLU-TUGAL, O., NOTO, R., JUSTER, F., BRUDNICKI, A., SLIM, M., BENECK, D. & JAYABOSE, S. 1996. Langerhans cell histiocytosis associated with partial DiGeorge syndrome in a newborn. *J Pediatr Hematol Oncol*, 18, 401-4.
- LI, J., LAU, G. K., CHEN, L., DONG, S. S., LAN, H. Y., HUANG, X. R., LI, Y., LUK, J. M., YUAN, Y. F. & GUAN, X. Y. 2011. Interleukin 17A promotes

- hepatocellular carcinoma metastasis via NF-kB induced matrix metalloproteinases 2 and 9 expression. *PLoS One*, 6, e21816.
- LIAO, Y. H., XIA, N., ZHOU, S. F., TANG, T. T., YAN, X. X., LV, B. J., NIE, S. F., WANG, J., IWAKURA, Y., XIAO, H., YUAN, J., JEVALLEE, H., WEI, F., SHI, G. P. & CHENG, X. 2012. Interleukin-17A contributes to myocardial ischemia/reperfusion injury by regulating cardiomyocyte apoptosis and neutrophil infiltration. *J Am Coll Cardiol*, 59, 420-9.
- LICHTENSTEIN, L. 1953. Histiocytosis X; integration of eosinophilic granuloma of bone, Letterer-Siwe disease, and Schuller-Christian disease as related manifestations of a single nosologic entity. *AMA Arch Pathol*, 56, 84-102.
- LICHTENSTEIN, L. & JAFFE, H. L. 1940. Eosinophilic granuloma of bone: With report of a case. *Am J Pathol*, 16, 595-604 3.
- LIDEGAARD, O., PINBORG, A. & ANDERSEN, A. N. 2005. Imprinting diseases and IVF: Danish National IVF cohort study. *Hum Reprod*, 20, 950-4.
- LIEBERMAN, J., NOSAL, A., SCHLESSNER, A. & SASTRE-FOKEN, A. 1979. Serum angiotensin-converting enzyme for diagnosis and therapeutic evaluation of sarcoidosis. *Am Rev Respir Dis*, 120, 329-35.
- LIN, Y., RITCHEA, S., LOGAR, A., SLIGHT, S., MESSMER, M., RANGEL-MORENO, J., GUGLANI, L., ALCORN, J. F., STRAWBRIDGE, H., PARK, S. M., ONISHI, R., NYUGEN, N., WALTER, M. J., POCIASK, D., RANDALL, T. D., GAFFEN, S. L., IWAKURA, Y., KOLLS, J. K. & KHADER, S. A. 2009. Interleukin-17 is required for T helper 1 cell immunity and host resistance to the intracellular pathogen *Francisella tularensis*. *Immunity*, 31, 799-810.
- LIPTON, S. A. & GENDELMAN, H. E. 1995. Seminars in medicine of the Beth Israel Hospital, Boston. Dementia associated with the acquired immunodeficiency syndrome. *N Engl J Med*, 332, 934-40.
- LIU, J., FENG, Y., YANG, K., LI, Q., YE, L., HAN, L. & WAN, H. 2011. Early production of IL-17 protects against acute pulmonary *Pseudomonas aeruginosa* infection in mice. *FEMS Immunol Med Microbiol*, 61, 179-88.
- LIU, K., VICTORA, G. D., SCHWICKERT, T. A., GUERMONPREZ, P., MEREDITH, M. M., YAO, K., CHU, F. F., RANDOLPH, G. J., RUDENSKY, A. Y. & NUSSENZWEIG, M. 2009. In vivo analysis of dendritic cell development and homeostasis. *Science*, 324, 392-7.
- LIU, L., GE, D., MA, L., MEI, J., LIU, S., ZHANG, Q., REN, F., LIAO, H., PU, Q., WANG, T. & YOU, Z. 2012. Interleukin-17 and prostaglandin E2 are involved in formation of an M2 macrophage-dominant microenvironment in lung cancer. *J Thorac Oncol*, 7, 1091-100.
- LIU, Y. J. 2005. IPC: professional type 1 interferon-producing cells and plasmacytoid dendritic cell precursors. *Annu Rev Immunol*, 23, 275-306.
- LOCK, C., HERMANS, G., PEDOTTI, R., BRENDOLAN, A., SCHADT, E., GARREN, H., LANGER-GOULD, A., STROBER, S., CANNELLA, B., ALLARD, J., KLONOWSKI, P., AUSTIN, A., LAD, N., KAMINSKI, N., GALLI, S. J., OKSENBERG, J. R., RAINE, C. S., HELLER, R. & STEINMAN, L. 2002. Gene-microarray analysis of multiple sclerosis lesions yields new targets validated in autoimmune encephalomyelitis. *Nat Med*, 8, 500-8.
- LOSER, K., MEHLING, A., LOESER, S., APELT, J., KUHN, A., GRABBE, S., SCHWARZ, T., PENNINGER, J. M. & BEISSERT, S. 2006. Epidermal RANKL controls regulatory T-cell numbers via activation of dendritic cells. *Nat Med*, 12, 1372-9.

- LUNDBERG, R., BRYTTING, M., DAHLGREN, L., KANTER-LEWENSOHN, L., SCHLOSS, L., DALIANIS, T. & RAGNARSSON-OLDING, B. 2006. Human herpes virus DNA is rarely detected in non-UV light-associated primary malignant melanomas of mucous membranes. *Anticancer Res*, 26, 3627-31.
- LUZZA, F., PARRELLO, T., MONTELEONE, G., SEBKOVA, L., ROMANO, M., ZARRILLI, R., IMENEO, M. & PALLONE, F. 2000. Up-regulation of IL-17 is associated with bioactive IL-8 expression in *Helicobacter pylori*-infected human gastric mucosa. *J Immunol*, 165, 5332-7.
- LYONS, A. B. 2000. Analysing cell division in vivo and in vitro using flow cytometric measurement of CFSE dye dilution. *J Immunol Methods*, 243, 147-54.
- MAHMOUD, H. H., WANG, W. C. & MURPHY, S. B. 1991. Cyclosporine therapy for advanced Langerhans cell histiocytosis. *Blood*, 77, 721-5.
- MAKRAS, P., POLYZOS, S. A., ANASTASILAKIS, A. D., TERPOS, E., PAPTAEODOROU, A. & KALTSAS, G. A. 2012. Is serum IL-17A a useful systemic biomarker in patients with Langerhans cell histiocytosis? *Mol Ther*, 20, 6-7.
- MANEL, N., UNUTMAZ, D. & LITTMAN, D. R. 2008. The differentiation of human T(H)-17 cells requires transforming growth factor-beta and induction of the nuclear receptor RORgamma. *Nat Immunol*, 9, 641-9.
- MANGAN, P. R., HARRINGTON, L. E., O'QUINN, D. B., HELMS, W. S., BULLARD, D. C., ELSON, C. O., HATTON, R. D., WAHL, S. M., SCHOEB, T. R. & WEAVER, C. T. 2006. Transforming growth factor-beta induces development of the T(H)17 lineage. *Nature*, 441, 231-4.
- MANIPALVIRATN, S., DECHERNEY, A. & SEGARS, J. 2009. Imprinting disorders and assisted reproductive technology. *Fertil Steril*, 91, 305-15.
- MANTOVANI, A., ALLAVENA, P., SICA, A. & BALKWILL, F. 2008. Cancer-related inflammation. *Nature*, 454, 436-44.
- MANTOVANI, A., BISWAS, S. K., GALDIERO, M. R., SICA, A. & LOCATI, M. 2013. Macrophage plasticity and polarization in tissue repair and remodelling. *J Pathol*, 229, 176-85.
- MANTOVANI, A., SOZZANI, S., LOCATI, M., ALLAVENA, P. & SICA, A. 2002. Macrophage polarization: tumor-associated macrophages as a paradigm for polarized M2 mononuclear phagocytes. *Trends Immunol*, 23, 549-55.
- MAREES, T., DOMMERING, C. J., IMHOF, S. M., KORS, W. A., RINGENS, P. J., VAN LEEUWEN, F. E. & MOLL, A. C. 2009. Incidence of retinoblastoma in Dutch children conceived by IVF: an expanded study. *Hum Reprod*, 24, 3220-4.
- MARSDEN, V. S. & STRASSER, A. 2003. Control of apoptosis in the immune system: Bcl-2, BH3-only proteins and more. *Annu Rev Immunol*, 21, 71-105.
- MARTIN-DUVERNEUIL, N., IDBAIH, A., HOANG-XUAN, K., DONADIEU, J., GENEREAU, T., GUILLEVIN, R. & CHIRAS, J. 2006. MRI features of neurodegenerative Langerhans cell histiocytosis. *Eur Radiol*, 16, 2074-82.
- MATUSEVICIUS, D., KIVISAKK, P., HE, B., KOSTULAS, N., OZENCI, V., FREDRIKSON, S. & LINK, H. 1999. Interleukin-17 mRNA expression in blood and CSF mononuclear cells is augmented in multiple sclerosis. *Mult Scler*, 5, 101-4.
- MCCLAIN, K., JIN, H., GRESIK, V. & FAVARA, B. 1994. Langerhans cell histiocytosis: lack of a viral etiology. *Am J Hematol*, 47, 16-20.
- MCCLAIN, K., RAMSAY, N. K., ROBISON, L., SUNDBERG, R. D. & NESBIT, M., JR. 1983. Bone marrow involvement in histiocytosis X. *Med Pediatr Oncol*, 11, 167-71.

- MCCLAIN, K. & WEISS, R. A. 1994. Viruses and Langerhans cell histiocytosis: is there a link? *Br J Cancer Suppl*, 23, S34-6.
- MCCLAIN, K. L., LAUD, P., WU, W. S. & POLLACK, M. S. 2003. Langerhans cell histiocytosis patients have HLA Cw7 and DR4 types associated with specific clinical presentations and no increased frequency in polymorphisms of the tumor necrosis factor alpha promoter. *Med Pediatr Oncol*, 41, 502-7.
- MCDOWELL, H. P., MACFARLANE, P. I. & MARTIN, J. 1988. Isolated pulmonary histiocytosis. *Arch Dis Child*, 63, 423-6.
- MCGEACHY, M. J. & CUA, D. J. 2008. Th17 cell differentiation: the long and winding road. *Immunity*, 28, 445-53.
- MCLEAN, T. W. & PRITCHARD, J. 1996. Langerhans cell histiocytosis and hypercalcemia: clinical response to indomethacin. *J Pediatr Hematol Oncol*, 18, 318-20.
- MERAD, M., GINHOUX, F. & COLLIN, M. 2008. Origin, homeostasis and function of Langerhans cells and other langerin-expressing dendritic cells. *Nat Rev Immunol*, 8, 935-47.
- MERAD, M. & MANZ, M. G. 2009. Dendritic cell homeostasis. *Blood*, 113, 3418-27.
- MERAD, M., MANZ, M. G., KARSUNKY, H., WAGERS, A., PETERS, W., CHARO, I., WEISSMAN, I. L., CYSTER, J. G. & ENGLEMAN, E. G. 2002. Langerhans cells renew in the skin throughout life under steady-state conditions. *Nat Immunol*, 3, 1135-41.
- MICHALOGLOU, C., VREDEVELD, L. C., MOOI, W. J. & PEEPER, D. S. 2008. BRAF(E600) in benign and malignant human tumours. *Oncogene*, 27, 877-95.
- MILNER, J. D., BRENCHELEY, J. M., LAURENCE, A., FREEMAN, A. F., HILL, B. J., ELIAS, K. M., KANNO, Y., SPALDING, C., ELLOUMI, H. Z., PAULSON, M. L., DAVIS, J., HSU, A., ASHER, A. I., O'SHEA, J., HOLLAND, S. M., PAUL, W. E. & DOUEK, D. C. 2008. Impaired T(H)17 cell differentiation in subjects with autosomal dominant hyper-IgE syndrome. *Nature*, 452, 773-6.
- MINKOV, M., GROIS, N., BRAIER, J., ROSSO, D., ARICO, M., BROADBENT, V., GADNER, H. & LADISCH, S. 2003. Immunosuppressive treatment for chemotherapy-resistant multisystem Langerhans cell histiocytosis. *Med Pediatr Oncol*, 40, 253-6.
- MINKOV, M., GROIS, N., BROADBENT, V., CECI, A., JAKOBSON, A. & LADISCH, S. 1999. Cyclosporine A therapy for multisystem langerhans cell histiocytosis. *Med Pediatr Oncol*, 33, 482-5.
- MINKOV, M., GROIS, N., HEITGER, A., POTSCGER, U., WESTERMEIER, T. & GADNER, H. 2000. Treatment of multisystem Langerhans cell histiocytosis. Results of the DAL-HX 83 and DAL-HX 90 studies. DAL-HX Study Group. *Klin Padiatr*, 212, 139-44.
- MINKOV, M., STEINER, M., POTSCGER, U., ARICO, M., BRAIER, J., DONADIEU, J., GROIS, N., HENTER, J. I., JANKA, G., MCCLAIN, K., WEITZMAN, S., WINDEBANK, K., LADISCH, S. & GADNER, H. 2008. Reactivations in multisystem Langerhans cell histiocytosis: data of the international LCH registry. *J Pediatr*, 153, 700-5, 705 e1-2.
- MIOSSEC, P. 2009. IL-17 and Th17 cells in human inflammatory diseases. *Microbes Infect*, 11, 625-30.
- MIOSSEC, P. & KOLLS, J. K. 2012. Targeting IL-17 and TH17 cells in chronic inflammation. *Nat Rev Drug Discov*, 11, 763-76.
- MITTHEISZ, E., SEIDL, R., PRAYER, D., WALDENMAIR, M., NEOPHYTOU, B., POTSCGER, U., MINKOV, M., STEINER, M., PROSCH, H.,

- WNOROWSKI, M., GADNER, H. & GROIS, N. 2007. Central nervous system-related permanent consequences in patients with Langerhans cell histiocytosis. *Pediatr Blood Cancer*, 48, 50-6.
- MONTI, S., SAVAGE, K. J., KUTOK, J. L., FEUERHAKE, F., KURTIN, P., MIHM, M., WU, B., PASQUALUCCI, L., NEUBERG, D., AGUIAR, R. C., DAL CIN, P., LADD, C., PINKUS, G. S., SALLES, G., HARRIS, N. L., DALLA-FAVERA, R., HABERMANN, T. M., ASTER, J. C., GOLUB, T. R. & SHIPP, M. A. 2005. Molecular profiling of diffuse large B-cell lymphoma identifies robust subtypes including one characterized by host inflammatory response. *Blood*, 105, 1851-61.
- MORALES, A. A., OLSSON, A., CELSING, F., OSTERBORG, A., JONDAL, M. & OSORIO, L. M. 2005. High expression of bfl-1 contributes to the apoptosis resistant phenotype in B-cell chronic lymphocytic leukemia. *Int J Cancer*, 113, 730-7.
- MORETTA, L., BIASSONI, R., BOTTINO, C., CANTONI, C., PENDE, D., MINGARI, M. C. & MORETTA, A. 2002. Human NK cells and their receptors. *Microbes Infect*, 4, 1539-44.
- MORIMOTO, A., KOBAYASHI, R., MAEDA, M., ASAMI, K., BESSHO, F. & IMASHUKU, S. 2008. Impact of reactivation on the sequelae of multi-system Langerhans cell histiocytosis patients. *Pediatr Blood Cancer*, 50, 931-2; author reply 932.
- MORIMOTO, A., SHIODA, Y., IMAMURA, T., KANEGANE, H., SATO, T., KUDO, K., NAKAGAWA, S., NAKADATE, H., TAUCHI, H., HAMA, A., YASUI, M., NAGATOSHI, Y., KINOSHITA, A., MIYAJI, R., ANAN, T., YABE, M. & KAMIZONO, J. 2011. Nationwide survey of bisphosphonate therapy for children with reactivated Langerhans cell histiocytosis in Japan. *Pediatr Blood Cancer*, 56, 110-5.
- MUDTER, J. & NEURATH, M. F. 2007. Il-6 signaling in inflammatory bowel disease: pathophysiological role and clinical relevance. *Inflamm Bowel Dis*, 13, 1016-23.
- MULLER, J., GARAMI, M., HAUSER, P., SCHULER, D., CSOKA, M., KOVACS, G., RENYI, I., MAROSI, A., GALANTAI, I., BEKESI, A., KAJTAR, P., KISS, C. S., NAGY, K., BARTYIK, K., MASATH, P. & KRIVAN, G. 2006. Hungarian experience with Langerhans cell histiocytosis in childhood. *Pediatr Hematol Oncol*, 23, 135-42.
- MUNN, S. & CHU, A. C. 1998. Langerhans cell histiocytosis of the skin. *Hematol Oncol Clin North Am*, 12, 269-86.
- MUNN, S. E., OLLIVER, L., BROADBENT, V. & PRITCHARD, J. 1999. Use of indomethacin in Langerhans cell histiocytosis. *Med Pediatr Oncol*, 32, 247-9.
- MURAKAMI, I., GOGUSEV, J., FOURNET, J. C., GLORION, C. & JAUBERT, F. 2002. Detection of molecular cytogenetic aberrations in langerhans cell histiocytosis of bone. *Hum Pathol*, 33, 555-60.
- MURAKAMI, I., MORIMOTO, A., OKA, T., KUWAMOTO, S., KATO, M., HORIE, Y., HAYASHI, K., GOGUSEV, J., JAUBERT, F., IMASHUKU, S., AL-KADAR, L. A., TAKATA, K. & YOSHINO, T. 2012. IL-17A receptor expression differs between subclasses of Langerhans cell histiocytosis, which might settle the IL-17A controversy. *Virchows Arch*.
- MURPHY, K. M. 2011. *Janeway's Immunobiology*, New York, Garland Science.
- NAIR, R. P., DUFFIN, K. C., HELMS, C., DING, J., STUART, P. E., GOLDSGAR, D., GUDJONSSON, J. E., LI, Y., TEJASVI, T., FENG, B. J., RUETHER, A., SCHREIBER, S., WEICHENTHAL, M., GLADMAN, D., RAHMAN, P.,

- SCHRODI, S. J., PRAHALAD, S., GUTHERY, S. L., FISCHER, J., LIAO, W., KWOK, P. Y., MENTER, A., LATHROP, G. M., WISE, C. A., BEGOVICH, A. B., VOORHEES, J. J., ELDER, J. T., KRUEGER, G. G., BOWCOCK, A. M. & ABECASIS, G. R. 2009. Genome-wide scan reveals association of psoriasis with IL-23 and NF-kappaB pathways. *Nat Genet*, 41, 199-204.
- NAKAMURA, T., MORIMOTO, N., GOTO, F., SHIODA, Y., HOSHINO, H., KUBOTA, M. & TAIJI, H. 2012. Langerhans cell histiocytosis with disequilibrium. *Auris Nasus Larynx*, 39, 627-30.
- NAM, J. S., TERABE, M., KANG, M. J., CHAE, H., VOONG, N., YANG, Y. A., LAURENCE, A., MICHALOWSKA, A., MAMURA, M., LONNING, S., BERZOFISKY, J. A. & WAKEFIELD, L. M. 2008. Transforming growth factor beta subverts the immune system into directly promoting tumor growth through interleukin-17. *Cancer Res*, 68, 3915-23.
- NANDURI, V. R., LILLYWHITE, L., CHAPMAN, C., PARRY, L., PRITCHARD, J. & VARGHA-KHADEM, F. 2003. Cognitive outcome of long-term survivors of multisystem langerhans cell histiocytosis: a single-institution, cross-sectional study. *J Clin Oncol*, 21, 2961-7.
- NANDURI, V. R., PRITCHARD, J., LEVITT, G. & GLASER, A. W. 2006. Long term morbidity and health related quality of life after multi-system Langerhans cell histiocytosis. *Eur J Cancer*, 42, 2563-9.
- NEZELOF, C. & BASSET, F. 1998. Langerhans cell histiocytosis research. Past, present, and future. *Hematol Oncol Clin North Am*, 12, 385-406.
- NEZELOF, C. & BASSET, F. 2004. An hypothesis Langerhans cell histiocytosis: the failure of the immune system to switch from an innate to an adaptive mode. *Pediatr Blood Cancer*, 42, 398-400.
- NEZELOF, C., BASSET, F. & ROUSSEAU, M. F. 1973. Histiocytosis X histogenetic arguments for a Langerhans cell origin. *Biomedicine*, 18, 365-71.
- NGUYEN, M., MARCELLUS, R. C., ROULSTON, A., WATSON, M., SERFASS, L., MURTHY MADIRAJU, S. R., GOULET, D., VIALLET, J., BELEC, L., BILLOT, X., ACOCA, S., PURISIMA, E., WIEGMANS, A., CLUSE, L., JOHNSTONE, R. W., BEAUPARLANT, P. & SHORE, G. C. 2007. Small molecule obatoclax (GX15-070) antagonizes MCL-1 and overcomes MCL-1-mediated resistance to apoptosis. *Proc Natl Acad Sci U S A*, 104, 19512-7.
- NICHOLS, K. E. & ARCECI, R. J. 2010. BRAF, a piece of the LCH puzzle. *Blood*, 116, 1825-7.
- NICOLO, C., TOMASSINI, B., RIPPO, M. R. & TESTI, R. 2001. UVB-induced apoptosis of human dendritic cells: contribution by caspase-dependent and caspase-independent pathways. *Blood*, 97, 1803-8.
- NUMASAKI, M., FUKUSHI, J., ONO, M., NARULA, S. K., ZAVODNY, P. J., KUDO, T., ROBBINS, P. D., TAHARA, H. & LOTZE, M. T. 2003. Interleukin-17 promotes angiogenesis and tumor growth. *Blood*, 101, 2620-7.
- ODOM, L. N. & SEGARS, J. 2010. Imprinting disorders and assisted reproductive technology. *Curr Opin Endocrinol Diabetes Obes*, 17, 517-22.
- OKAMOTO YOSHIDA, Y., UMEMURA, M., YAHAGI, A., O'BRIEN, R. L., IKUTA, K., KISHIHARA, K., HARA, H., NAKAE, S., IWAKURA, Y. & MATSUZAKI, G. 2010. Essential role of IL-17A in the formation of a mycobacterial infection-induced granuloma in the lung. *J Immunol*, 184, 4414-22.
- OLSSON, A., NORBERG, M., OKVIST, A., DERKOW, K., CHOUDHURY, A., TOBIN, G., CELSING, F., OSTERBORG, A., ROSENQUIST, R., JONDAL,

- M. & OSORIO, L. M. 2007. Upregulation of bfl-1 is a potential mechanism of chemoresistance in B-cell chronic lymphocytic leukaemia. *Br J Cancer*, 97, 769-77.
- ONISHI, R. M. & GAFFEN, S. L. 2010. Interleukin-17 and its target genes: mechanisms of interleukin-17 function in disease. *Immunology*, 129, 311-21.
- OSBAND, M. E. 1986. Study of thymic hormone therapy for histiocytosis X. *Am J Dis Child*, 140, 191.
- OSBAND, M. E., LIPTON, J. M., LAVIN, P., LEVEY, R., VAWTER, G., GREENBERGER, J. S., MCCAFFREY, R. P. & PARKMAN, R. 1981. Histiocytosis-X. *N Engl J Med*, 304, 146-53.
- OSTERLUNDH, G., KJELLMER, I., LANNERING, B., ROSENGREN, L., NILSSON, U. A. & MARKY, I. 2008. Neurochemical markers of brain damage in cerebrospinal fluid during induction treatment of acute lymphoblastic leukemia in children. *Pediatr Blood Cancer*, 50, 793-8.
- OTANI, S. & EHRLICH, J. C. 1940. Solitary granuloma of bone: Simulating primary neoplasm. *Am J Pathol*, 16, 479-490 7.
- OTTINA, E., TISCHNER, D., HEROLD, M. J. & VILLUNGER, A. 2012. A1/Bfl-1 in leukocyte development and cell death. *Exp Cell Res*, 318, 1291-303.
- OTTO, M., WILTFANG, J., TUMANI, H., ZERR, I., LANTSCH, M., KORNUBER, J., WEBER, T., KRETZSCHMAR, H. A. & POSER, S. 1997. Elevated levels of tau-protein in cerebrospinal fluid of patients with Creutzfeldt-Jakob disease. *Neurosci Lett*, 225, 210-2.
- PAINTLIA, M. K., PAINTLIA, A. S., SINGH, A. K. & SINGH, I. 2011. Synergistic activity of interleukin-17 and tumor necrosis factor-alpha enhances oxidative stress-mediated oligodendrocyte apoptosis. *J Neurochem*, 116, 508-21.
- PARK, H., LI, Z., YANG, X. O., CHANG, S. H., NURIEVA, R., WANG, Y. H., WANG, Y., HOOD, L., ZHU, Z., TIAN, Q. & DONG, C. 2005. A distinct lineage of CD4 T cells regulates tissue inflammation by producing interleukin 17. *Nat Immunol*, 6, 1133-41.
- PARK, Y., LEE, S. W. & SUNG, Y. C. 2002. Cutting Edge: CpG DNA inhibits dendritic cell apoptosis by up-regulating cellular inhibitor of apoptosis proteins through the phosphatidylinositol-3'-OH kinase pathway. *J Immunol*, 168, 5-8.
- PENE, J., CHEVALIER, S., PREISSER, L., VENEREAU, E., GUILLEUX, M. H., GHANNAM, S., MOLES, J. P., DANGER, Y., RAVON, E., LESAUX, S., YSSEL, H. & GASCAN, H. 2008. Chronically inflamed human tissues are infiltrated by highly differentiated Th17 lymphocytes. *J Immunol*, 180, 7423-30.
- PETERS, T. L., MCCLAIN, K. L. & ALLEN, C. E. 2011. Neither IL-17A mRNA nor IL-17A protein are detectable in Langerhans cell histiocytosis lesions. *Mol Ther*, 19, 1433-9.
- PETERSEN, B. L., RENGTVED, P., BANK, M. I. & CARSTENSEN, H. 2003. High expression of markers of apoptosis in Langerhans cell histiocytosis. *Histopathology*, 42, 186-93.
- PHILLIPS, M., ALLEN, C., GERSON, P. & MCCLAIN, K. 2009. Comparison of FDG-PET scans to conventional radiography and bone scans in management of Langerhans cell histiocytosis. *Pediatr Blood Cancer*, 52, 97-101.
- POLLONO, D., REY, G., LATELLA, A., ROSSO, D., CHANTADA, G. & BRAIER, J. 2007. Reactivation and risk of sequelae in Langerhans cell histiocytosis. *Pediatr Blood Cancer*, 48, 696-9.

- PORCELLI, S. A. & MODLIN, R. L. 1999. The CD1 system: antigen-presenting molecules for T cell recognition of lipids and glycolipids. *Annu Rev Immunol*, 17, 297-329.
- PORTELIUS, E., HANSSON, S. F., TRAN, A. J., ZETTERBERG, H., GROGNET, P., VANMECHELEN, E., HOGLUND, K., BRINKMALM, G., WESTMAN-BRINKMALM, A., NORDHOFF, E., BLENNOW, K. & GOBOM, J. 2008. Characterization of tau in cerebrospinal fluid using mass spectrometry. *J Proteome Res*, 7, 2114-20.
- POULIN, L. F., HENRI, S., DE BOVIS, B., DEVILARD, E., KISSENPFENNIG, A. & MALISSEN, B. 2007. The dermis contains langerin+ dendritic cells that develop and function independently of epidermal Langerhans cells. *J Exp Med*, 204, 3119-31.
- PRAYER, D., GROIS, N., PROSCH, H., GADNER, H. & BARKOVICH, A. J. 2004. MR imaging presentation of intracranial disease associated with Langerhans cell histiocytosis. *AJNR Am J Neuroradiol*, 25, 880-91.
- PROSCH, H., GROIS, N., WNOROWSKI, M., STEINER, M. & PRAYER, D. 2007. Long-term MR imaging course of neurodegenerative Langerhans cell histiocytosis. *AJNR Am J Neuroradiol*, 28, 1022-8.
- PUEL, A., CYPOWYJ, S., BUSTAMANTE, J., WRIGHT, J. F., LIU, L., LIM, H. K., MIGAUD, M., ISRAEL, L., CHRABIEH, M., AUDRY, M., GUMBLETON, M., TOULON, A., BODEMER, C., EL-BAGHDADI, J., WHITTERS, M., PARADIS, T., BROOKS, J., COLLINS, M., WOLFMAN, N. M., AL-MUHSSEN, S., GALICCHIO, M., ABEL, L., PICARD, C. & CASANOVA, J. L. 2011. Chronic mucocutaneous candidiasis in humans with inborn errors of interleukin-17 immunity. *Science*, 332, 65-8.
- QIAN, Y., KANG, Z., LIU, C. & LI, X. 2010. IL-17 signaling in host defense and inflammatory diseases. *Cell Mol Immunol*, 7, 328-33.
- QIAN, Y., LIU, C., HARTUPEE, J., ALTUNTAS, C. Z., GULEN, M. F., JANE-WIT, D., XIAO, J., LU, Y., GILTIAIY, N., LIU, J., KORDULA, T., ZHANG, Q. W., VALLANCE, B., SWAIDANI, S., ARONICA, M., TUOHY, V. K., HAMILTON, T. & LI, X. 2007. The adaptor Act1 is required for interleukin 17-dependent signaling associated with autoimmune and inflammatory disease. *Nat Immunol*, 8, 247-56.
- RADTKE, F., FASNACHT, N. & MACDONALD, H. R. 2010. Notch signaling in the immune system. *Immunity*, 32, 14-27.
- RAHMANI, M., DAVIS, E. M., CRABTREE, T. R., HABIBI, J. R., NGUYEN, T. K., DENT, P. & GRANT, S. 2007. The kinase inhibitor sorafenib induces cell death through a process involving induction of endoplasmic reticulum stress. *Mol Cell Biol*, 27, 5499-513.
- RAQIB, R., LJUNGDAHL, A., LINDBERG, A. A., WRETLIND, B., ANDERSSON, U. & ANDERSSON, J. 1996. Dissociation between cytokine mRNA expression and protein production in shigellosis. *Eur J Immunol*, 26, 1130-8.
- RISTEVSKI, S., PURCELL, D. F., MARSHALL, J., CAMPAGNA, D., NOURI, S., FENTON, S. P., MCPHEE, D. A. & KANNOURAKIS, G. 1999. Novel endogenous type D retroviral particles expressed at high levels in a SCID mouse thymic lymphoma. *J Virol*, 73, 4662-9.
- RIVOLLIER, A., MAZZORANA, M., TEBIB, J., PIPERNO, M., AITSISELMI, T., RABOURDIN-COMBE, C., JURDIC, P. & SERVET-DELPRAT, C. 2004. Immature dendritic cell transdifferentiation into osteoclasts: a novel pathway sustained by the rheumatoid arthritis microenvironment. *Blood*, 104, 4029-37.

- RODIG, S. J., PAYNE, E. G., DEGAR, B. A., ROLLINS, B., FELDMAN, A. L., JAFFE, E. S., ANDROKITES, A., SILVERMAN, L. B., LONGTINE, J. A., KUTOK, J. L., FLEMING, M. D. & ASTER, J. C. 2008. Aggressive Langerhans cell histiocytosis following T-ALL: clonally related neoplasms with persistent expression of constitutively active NOTCH1. *Am J Hematol*, 83, 116-21.
- ROLLAND, A., GUYON, L., GILL, M., CAI, Y. H., BANCHEREAU, J., MCCLAIN, K. & PALUCKA, A. K. 2005. Increased blood myeloid dendritic cells and dendritic cell-poietins in Langerhans cell histiocytosis. *J Immunol*, 174, 3067-71.
- ROMANI, N., CLAUSEN, B. E. & STOITZNER, P. 2010. Langerhans cells and more: langerin-expressing dendritic cell subsets in the skin. *Immunol Rev*, 234, 120-41.
- ROSENGREN, L. E., AHLSEN, G., BELFRAGE, M., GILLBERG, C., HAGLID, K. G. & HAMBERGER, A. 1992. A sensitive ELISA for glial fibrillary acidic protein: application in CSF of children. *J Neurosci Methods*, 44, 113-9.
- ROSENGREN, L. E., KARLSSON, J. E., KARLSSON, J. O., PERSSON, L. I. & WIKKELSO, C. 1996. Patients with amyotrophic lateral sclerosis and other neurodegenerative diseases have increased levels of neurofilament protein in CSF. *J Neurochem*, 67, 2013-8.
- ROSENSTEIN, E. D., ESKOW, R. N., LEDERMAN, D. A. & KRAMER, N. 1995. Case report: Langerhans cell histiocytosis associated with elevation of angiotensin-converting enzyme levels. *Am J Med Sci*, 310, 65-7.
- ROSSO, D. A., ROY, A., ZELAZKO, M. & BRAIER, J. L. 2002. Prognostic value of soluble interleukin 2 receptor levels in Langerhans cell histiocytosis. *Br J Haematol*, 117, 54-8.
- ROUVIER, E., LUCIANI, M. F., MATTEI, M. G., DENIZOT, F. & GOLSTEIN, P. 1993. CTLA-8, cloned from an activated T cell, bearing AU-rich messenger RNA instability sequences, and homologous to a herpesvirus saimiri gene. *J Immunol*, 150, 5445-56.
- ROWDEN, G., LEWIS, M. G. & SULLIVAN, A. K. 1977. Ia antigen expression on human epidermal Langerhans cells. *Nature*, 268, 247-8.
- RUEDL, C., KOEBEL, P., BACHMANN, M., HESS, M. & KARJALAINEN, K. 2000. Anatomical origin of dendritic cells determines their life span in peripheral lymph nodes. *J Immunol*, 165, 4910-6.
- RUST, R., KLUIVER, J., VISSER, L., HARMS, G., BLOKZIJL, T., KAMPS, W., POPPEMA, S. & VAN DEN BERG, A. 2006. Gene expression analysis of dendritic/Langerhans cells and Langerhans cell histiocytosis. *J Pathol*, 209, 474-83.
- RUTITZKY, L. I. & STADECKER, M. J. 2011. Exacerbated egg-induced immunopathology in murine *Schistosoma mansoni* infection is primarily mediated by IL-17 and restrained by IFN-gamma. *Eur J Immunol*, 41, 2677-87.
- SAHM, F., CAPPER, D., PREUSSER, M., MEYER, J., STENZINGER, A., LASITSCHKA, F., BERGHOFF, A. S., HABEL, A., SCHNEIDER, M., KULOZIK, A., ANAGNOSTOPOULOS, I., MULLAUER, L., MECHTERSHEIMER, G. & VON DEIMLING, A. 2012. BRAFV600E mutant protein is expressed in cells of variable maturation in Langerhans cell histiocytosis. *Blood*, 120, e28-34.
- SAKATA, N., TOGUCHI, N., KIMURA, M., NAKAYAMA, M., KAWA, K. & TAKEMURA, T. 2008. Development of Langerhans cell histiocytosis

- associated with chronic active Epstein-Barr virus infection. *Pediatr Blood Cancer*, 50, 924-7.
- SALLUSTO, F. & LANZAVECCHIA, A. 1994. Efficient presentation of soluble antigen by cultured human dendritic cells is maintained by granulocyte/macrophage colony-stimulating factor plus interleukin 4 and downregulated by tumor necrosis factor alpha. *J Exp Med*, 179, 1109-18.
- SALOTTI, J. A., NANDURI, V., PEARCE, M. S., PARKER, L., LYNN, R. & WINDEBANK, K. P. 2009. Incidence and clinical features of Langerhans cell histiocytosis in the UK and Ireland. *Arch Dis Child*, 94, 376-80.
- SATOH, T., SMITH, A., SARDE, A., LU, H. C., MIAN, S., TROUILLET, C., MUFTI, G., EMILE, J. F., FRATERNALI, F., DONADIEU, J. & GEISSMANN, F. 2012. B-Raf mutant alleles associated with Langerhans cell histiocytosis, a granulomatous pediatric disease. *PLoS One*, 7, e33891.
- SAVELL, V. H., JR., SHERMAN, T., SCHEUERMANN, R. H., SIDDIQUI, A. M. & MARGRAF, L. R. 1998. Bcl-2 expression in Langerhans' cell histiocytosis. *Pediatr Dev Pathol*, 1, 210-5.
- SAXNE, T., PALLADINO, M. A., JR., HEINEGARD, D., TALAL, N. & WOLLHEIM, F. A. 1988. Detection of tumor necrosis factor alpha but not tumor necrosis factor beta in rheumatoid arthritis synovial fluid and serum. *Arthritis Rheum*, 31, 1041-5.
- SCHINDLER, R., CLARK, B. D. & DINARELLO, C. A. 1990. Dissociation between interleukin-1 beta mRNA and protein synthesis in human peripheral blood mononuclear cells. *J Biol Chem*, 265, 10232-7.
- SCHMITZ, L. & FAVARA, B. E. 1998. Nosology and pathology of Langerhans cell histiocytosis. *Hematol Oncol Clin North Am*, 12, 221-46.
- SCHOUTEN, B., EGELER, R. M., LEENEN, P. J., TAMINIAU, A. H., VAN DEN BROEK, L. J. & HOGENDOORN, P. C. 2002. Expression of cell cycle-related gene products in Langerhans cell histiocytosis. *J Pediatr Hematol Oncol*, 24, 727-32.
- SCHWARZENBERGER, P., LA RUSSA, V., MILLER, A., YE, P., HUANG, W., ZIESKE, A., NELSON, S., BAGBY, G. J., STOLTZ, D., MYNATT, R. L., SPRIGGS, M. & KOLLS, J. K. 1998. IL-17 stimulates granulopoiesis in mice: use of an alternate, novel gene therapy-derived method for in vivo evaluation of cytokines. *J Immunol*, 161, 6383-9.
- SCHÜLLER, A. 1915. Über eigenartige Schädeldefekte im Jugendalter. *Fortschr Röntgenstr*, 23, 12-18.
- SEGURA, E., TOUZOT, M., BOHINEUST, A., CAPPuccio, A., CHIOCCHIA, G., HOSMALIN, A., DALOD, M., SOUMELIS, V. & AMIGORENA, S. 2013. Human inflammatory dendritic cells induce Th17 cell differentiation. *Immunity*, 38, 336-48.
- SENECHAL, B., ELAIN, G., JEZIORSKI, E., GRONDIN, V., PATEY-MARIAUD DE SERRE, N., JAUBERT, F., BELDJORD, K., LELLOUCH, A., GLORION, C., ZERAH, M., MARY, P., BARKAOUI, M., EMILE, J. F., BOCCON-GIBOD, L., JOSSET, P., DEBRE, M., FISCHER, A., DONADIEU, J. & GEISSMANN, F. 2007. Expansion of regulatory T cells in patients with Langerhans cell histiocytosis. *PLoS Med*, 4, e253.
- SERGEJEVA, S., IVANOV, S., LOTVALL, J. & LINDEN, A. 2005. Interleukin-17 as a recruitment and survival factor for airway macrophages in allergic airway inflammation. *Am J Respir Cell Mol Biol*, 33, 248-53.

- SHAHIM, P., MANSSON, J. E., DARIN, N., ZETTERBERG, H. & MATTSSON, N. 2013. Cerebrospinal fluid biomarkers in neurological diseases in children. *Eur J Paediatr Neurol*, 17, 7-13.
- SHAHLA, A., PARVANEH, V. & HOSSEIN, H. D. 2004. Langerhans cells histiocytosis in one family. *Pediatr Hematol Oncol*, 21, 313-20.
- SHAMSTILI, S., GREFKENS, J., DE LEEUW, B., VAN DEN BENT, M., HOOIJKAAS, H., VAN DER HOLT, B., VECHT, C. & SILLEVIS SMITT, P. 2003. Paraneoplastic cerebellar degeneration associated with antineuronal antibodies: analysis of 50 patients. *Brain*, 126, 1409-18.
- SHEILS, C. & DOVER, G. J. 1989. Frequency of congenital anomalies in patients with histiocytosis X. *Am J Hematol*, 31, 91-5.
- SHEN, F., RUDDY, M. J., PLAMONDON, P. & GAFFEN, S. L. 2005. Cytokines link osteoblasts and inflammation: microarray analysis of interleukin-17- and TNF-alpha-induced genes in bone cells. *J Leukoc Biol*, 77, 388-99.
- SHIBATA, K., YAMADA, H., HARA, H., KISHIHARA, K. & YOSHIKAI, Y. 2007. Resident Vdelta1+ gammadelta T cells control early infiltration of neutrophils after Escherichia coli infection via IL-17 production. *J Immunol*, 178, 4466-72.
- SHIMAKAGE, M., SASAGAWA, T., KIMURA, M., SHIMAKAGE, T., SETO, S., KODAMA, K. & SAKAMOTO, H. 2004. Expression of Epstein-Barr virus in Langerhans' cell histiocytosis. *Hum Pathol*, 35, 862-8.
- SICA, A., LARGHI, P., MANCINO, A., RUBINO, L., PORTA, C., TOTARO, M. G., RIMOLDI, M., BISWAS, S. K., ALLAVENA, P. & MANTOVANI, A. 2008. Macrophage polarization in tumour progression. *Semin Cancer Biol*, 18, 349-55.
- SILBERBERG, I. 1971. Ultrastructural studies of Langerhans cells in contact sensitive and primary irritant reactions. *Clin Res*, 19, 715-724.
- SIMPSON, L. A., BURWELL, E. A., THOMPSON, K. A., SHAHNAZ, S., CHEN, A. R. & LOEB, D. M. 2006. The antiapoptotic gene A1/BFL1 is a WT1 target gene that mediates granulocytic differentiation and resistance to chemotherapy. *Blood*, 107, 4695-702.
- SIWE, S. A. 1933. Die retikuloendotheliose- ein neues Krankheitsbild unter den Hepatosplenomegalien. *Z Kinderheilk*, 55, 212-247.
- SIVENDRAN, S., HARVEY, H., LIPTON, A. & DRABICK, J. 2011. Treatment of Langerhans cell histiocytosis bone lesions with zoledronic acid: a case series. *Int J Hematol*, 93, 782-6.
- SJOGREN, M., VANDERSTICHELE, H., AGREN, H., ZACHRISSON, O., EDSBAGGE, M., WIKKELSO, C., SKOOG, I., WALLIN, A., WAHLUND, L. O., MARCUSSON, J., NAGGA, K., ANDREASEN, N., DAVIDSSON, P., VANMECHELEN, E. & BLENNOW, K. 2001. Tau and Abeta42 in cerebrospinal fluid from healthy adults 21-93 years of age: establishment of reference values. *Clin Chem*, 47, 1776-81.
- SLACMEULDER, M., GEISSMANN, F., LEPELLETIER, Y., FOURNET, J. C., BROUSSE, N., THOMAS, C., DONADIEU, J. & GESSAIN, A. 2002. No association between Langerhans cell histiocytosis and human herpes virus 8. *Med Pediatr Oncol*, 39, 187-9.
- SMITH, T. 1865. Skull cap showing congenital deficiency of bone. *Trans Pathol Soc Lond*, 16, 224-225.
- SOTO-CHAVEZ, V., GONZALEZ-RAMELLA, O. & CORONA-RIVERA, A. Langerhans cell histiocytosis. Ten years experience in a single institution (Abstract). 23rd Annual Meeting of the Histiocyte Society 2007 Cambridge, UK.

- STALEMARK, H., LAURENCIKAS, E., KARIS, J., GAVHED, D., FADEEL, B. & HENTER, J. I. 2008. Incidence of Langerhans cell histiocytosis in children: a population-based study. *Pediatr Blood Cancer*, 51, 76-81.
- STARLING, K. A., DONALDSON, M. H., HAGGARD, M. E., VIETTI, T. J. & SUTOW, W. W. 1972. Therapy of histiocytosis X with vincristine, vinblastine, and cyclophosphamide. The Southwest Cancer Chemotherapy Study Group. *Am J Dis Child*, 123, 105-10.
- STEINER, M., PRAYER, D., ASENBAUM, S., PROSCH, H., MINKOV, M., UNGER, E. & GROIS, N. 2005. Modern imaging methods for the assessment of Langerhans' cell histiocytosis-associated neurodegenerative syndrome: case report. *J Child Neurol*, 20, 253-7.
- STEINER, Q. G., OTTEN, L. A., HICKS, M. J., KAYA, G., GROSJEAN, F., SAEUBERLI, E., LAVANCHY, C., BEERMANN, F., MCCLAIN, K. L. & ACHA-ORBEA, H. 2008. In vivo transformation of mouse conventional CD8alpha+ dendritic cells leads to progressive multisystem histiocytosis. *Blood*, 111, 2073-82.
- STEINMAN, R. M. 1991. The dendritic cell system and its role in immunogenicity. *Annu Rev Immunol*, 9, 271-96.
- STEINMAN, R. M. & COHN, Z. A. 1973. Identification of a novel cell type in peripheral lymphoid organs of mice. I. Morphology, quantitation, tissue distribution. *J Exp Med*, 137, 1142-62.
- SURICO, G., MUGGIO, P., RIGILLO, N. & GADNER, H. 2000. Concurrent Langerhans cell histiocytosis and myelodysplasia in children. *Med Pediatr Oncol*, 35, 421-5.
- SUTCLIFFE, A. G., PETERS, C. J., BOWDIN, S., TEMPLE, K., REARDON, W., WILSON, L., CLAYTON-SMITH, J., BRUETON, L. A., BANNISTER, W. & MAHER, E. R. 2006. Assisted reproductive therapies and imprinting disorders--a preliminary British survey. *Hum Reprod*, 21, 1009-11.
- SUTTON, C. E., MIELKE, L. A. & MILLS, K. H. 2012. IL-17-producing gammadelta T cells and innate lymphoid cells. *Eur J Immunol*, 42, 2221-31.
- SWEDEN, S. 2009. The future population of Sweden 2009–2060 In: STATISTICS, S. (ed.) *Demographic reports*. Stockholm: Statistics Sweden.
- TAKAYANAGI, H., OGASAWARA, K., HIDA, S., CHIBA, T., MURATA, S., SATO, K., TAKAOKA, A., YOKOCHI, T., ODA, H., TANAKA, K., NAKAMURA, K. & TANIGUCHI, T. 2000. T-cell-mediated regulation of osteoclastogenesis by signalling cross-talk between RANKL and IFN-gamma. *Nature*, 408, 600-5.
- TANG, A., AMAGAI, M., GRANGER, L. G., STANLEY, J. R. & UDEY, M. C. 1993. Adhesion of epidermal Langerhans cells to keratinocytes mediated by E-cadherin. *Nature*, 361, 82-5.
- TARTOUR, E., FOSSIEZ, F., JOYEUX, I., GALINHA, A., GEY, A., CLARET, E., SASTRE-GARAU, X., COUTURIER, J., MOSSERI, V., VIVES, V., BANCHEREAU, J., FRIDMAN, W. H., WIJDENES, J. G., LEBECQUE, S. & SAUTES-FRIDMAN, C. 1999. Interleukin 17, a T-cell-derived cytokine, promotes tumorigenicity of human cervical tumors in nude mice. *Cancer Res*, 59, 3698-704.
- TATEVOSSIAN, R., NANDURI, V., SALOTTI, J., SARGENT, C., NORTON, A., WELLS, A. & PRITCHARD, J. 2006. Adults with LCH--orphans with an orphan disease. *Clin Med*, 6, 404-8.

- TEUNISSEN, C. E., DIJKSTRA, C. & POLMAN, C. 2005. Biological markers in CSF and blood for axonal degeneration in multiple sclerosis. *Lancet Neurol*, 4, 32-41.
- TEUNISSEN, C. E. & KHALIL, M. 2012. Neurofilaments as biomarkers in multiple sclerosis. *Mult Scler*, 18, 552-6.
- TEUNISSEN, M. B. 1992. Dynamic nature and function of epidermal Langerhans cells in vivo and in vitro: a review, with emphasis on human Langerhans cells. *Histochem J*, 24, 697-716.
- TIEN, R., KUCHARCZYK, J. & KUCHARCZYK, W. 1991. MR imaging of the brain in patients with diabetes insipidus. *AJNR Am J Neuroradiol*, 12, 533-42.
- TITGEMEYER, C., GROIS, N., MINKOV, M., FLUCHER-WOLFRAM, B., GATTERER-MENZ, I. & GADNER, H. 2001. Pattern and course of single-system disease in Langerhans cell histiocytosis data from the DAL-HX 83- and 90-study. *Med Pediatr Oncol*, 37, 108-14.
- TODA, A. & PICCIRILLO, C. A. 2006. Development and function of naturally occurring CD4+CD25+ regulatory T cells. *J Leukoc Biol*, 80, 458-70.
- TOH, M. L., GONZALES, G., KOENDERS, M. I., TOURNADRE, A., BOYLE, D., LUBBERTS, E., ZHOU, Y., FIRESTEIN, G. S., VAN DEN BERG, W. B. & MIOSSEC, P. 2010. Role of interleukin 17 in arthritis chronicity through survival of synoviocytes via regulation of synoviolin expression. *PLoS One*, 5, e13416.
- TOSOLINI, M., KIRILOVSKY, A., MLECNIK, B., FREDRIKSEN, T., MAUGER, S., BINDEA, G., BERGER, A., BRUNEVAL, P., FRIDMAN, W. H., PAGES, F. & GALON, J. 2011. Clinical impact of different classes of infiltrating T cytotoxic and helper cells (Th1, th2, treg, th17) in patients with colorectal cancer. *Cancer Res*, 71, 1263-71.
- TOY, D., KUGLER, D., WOLFSON, M., VANDEN BOS, T., GURGEL, J., DERRY, J., TOCKER, J. & PESCHON, J. 2006. Cutting edge: interleukin 17 signals through a heteromeric receptor complex. *J Immunol*, 177, 36-9.
- TUCCI, M., STUCCI, S., SAVONAROLA, A., CIAVARELLA, S., CAFFORIO, P., DAMMACCO, F. & SILVESTRIS, F. 2013. Immature dendritic cells in multiple myeloma are prone to osteoclast-like differentiation through interleukin-17A stimulation. *Br J Haematol*, 161, 821-31.
- UMEMURA, M., YAHAGI, A., HAMADA, S., BEGUM, M. D., WATANABE, H., KAWAKAMI, K., SUDA, T., SUDO, K., NAKAE, S., IWAKURA, Y. & MATSUZAKI, G. 2007. IL-17-mediated regulation of innate and acquired immune response against pulmonary Mycobacterium bovis bacille Calmette-Guerin infection. *J Immunol*, 178, 3786-96.
- VAKNIN-DEMBINSKY, A., BALASHOV, K. & WEINER, H. L. 2006. IL-23 is increased in dendritic cells in multiple sclerosis and down-regulation of IL-23 by antisense oligos increases dendritic cell IL-10 production. *J Immunol*, 176, 7768-74.
- VALLADEAU, J., DEZUTTER-DAMBUYANT, C. & SAELAND, S. 2003. Langerin/CD207 sheds light on formation of birbeck granules and their possible function in Langerhans cells. *Immunol Res*, 28, 93-107.
- VALLADEAU, J., RAVEL, O., DEZUTTER-DAMBUYANT, C., MOORE, K., KLEIJMEER, M., LIU, Y., DUVERT-FRANCES, V., VINCENT, C., SCHMITT, D., DAVOUST, J., CAUX, C., LEBECQUE, S. & SAELAND, S. 2000. Langerin, a novel C-type lectin specific to Langerhans cells, is an endocytic receptor that induces the formation of Birbeck granules. *Immunity*, 12, 71-81.

- WALLGREN, A. 1940. Systemic reticulo-endothelial granuloma. Nonlipoid reticuloendotheliosis and Schüller-Christian disease. *Am J Dis Child*, 60, 471.
- WALLIN, A., BLENNOW, K. & ROSENGREN, L. E. 1996. Glial fibrillary acidic protein in the cerebrospinal fluid of patients with dementia. *Dementia*, 7, 267-72.
- VAN'T HOOFT, I., GAVHED, D., LAURENCIKAS, E. & HENTER, J. I. 2008. Neuropsychological sequelae in patients with neurodegenerative Langerhans cell histiocytosis. *Pediatr Blood Cancer*, 51, 669-74.
- VAN DEN BERG, W. B. & MIOSEC, P. 2009. IL-17 as a future therapeutic target for rheumatoid arthritis. *Nat Rev Rheumatol*, 5, 549-53.
- VAN GOOL, S. W., DE MEYER, G., VAN DE VOORDE, A., VANMECHELEN, E. & VANDERSTICHELE, H. 2004. Neurotoxicity marker profiles in the CSF are not age-dependent but show variation in children treated for acute lymphoblastic leukemia. *Neurotoxicology*, 25, 471-80.
- VAN GOOL, S. W., VAN KERSCHAUER, E., BROCK, P., POTTEL, H., HULSTAERT, F., VANMECHELEN, E., UYTTEBROECK, A., VAN DE VOORDE, A. & VANDERSTICHELE, H. 2000. Disease- and treatment-related elevation of the neurodegenerative marker tau in children with hematological malignancies. *Leukemia*, 14, 2076-84.
- WANG, C. Y., GUTTRIDGE, D. C., MAYO, M. W. & BALDWIN, A. S., JR. 1999a. NF-kappaB induces expression of the Bcl-2 homologue A1/Bfl-1 to preferentially suppress chemotherapy-induced apoptosis. *Mol Cell Biol*, 19, 5923-9.
- WANG, J., ZHENG, L., LOBITO, A., CHAN, F. K., DALE, J., SNELLER, M., YAO, X., PUCK, J. M., STRAUS, S. E. & LENARDO, M. J. 1999b. Inherited human Caspase 10 mutations underlie defective lymphocyte and dendritic cell apoptosis in autoimmune lymphoproliferative syndrome type II. *Cell*, 98, 47-58.
- WANG, K. X. & DENHARDT, D. T. 2008. Osteopontin: role in immune regulation and stress responses. *Cytokine Growth Factor Rev*, 19, 333-45.
- WANG, L., YI, T., KORTYLEWSKI, M., PARDOLL, D. M., ZENG, D. & YU, H. 2009. IL-17 can promote tumor growth through an IL-6-Stat3 signaling pathway. *J Exp Med*, 206, 1457-64.
- VASSALLO, R., RYU, J. H., COLBY, T. V., HARTMAN, T. & LIMPER, A. H. 2000. Pulmonary Langerhans'-cell histiocytosis. *N Engl J Med*, 342, 1969-78.
- WEI, J., KITADA, S., REGA, M. F., EMDADI, A., YUAN, H., CELLITTI, J., STEBBINS, J. L., ZHAI, D., SUN, J., YANG, L., DAHL, R., ZHANG, Z., WU, B., WANG, S., REED, T. A., WANG, H. G., LAWRENCE, N., SEBTI, S., REED, J. C. & PELLECCIA, M. 2009. Apogossypol derivatives as antagonists of antiapoptotic Bcl-2 family proteins. *Mol Cancer Ther*, 8, 904-13.
- WEINTRAUB, M., BHATIA, K. G., CHANDRA, R. S., MAGRATH, I. T. & LADISCH, S. 1998. p53 expression in Langerhans cell histiocytosis. *J Pediatr Hematol Oncol*, 20, 12-7.
- WEISS, L. M., HU, E., WOOD, G. S., MOULDS, C., CLEARY, M. L., WARNKE, R. & SKLAR, J. 1985. Clonal rearrangements of T-cell receptor genes in mycosis fungoides and dermatopathic lymphadenopathy. *N Engl J Med*, 313, 539-44.
- WEITZMAN, S., BRAIER, J., DONADIEU, J., EGELER, R. M., GROIS, N., LADISCH, S., POTSCGER, U., WEBB, D., WHITLOCK, J. & ARCECI, R. J. 2009. 2'-Chlorodeoxyadenosine (2-CdA) as salvage therapy for Langerhans cell histiocytosis (LCH). results of the LCH-S-98 protocol of the Histiocyte Society. *Pediatr Blood Cancer*, 53, 1271-6.

- VENKATRAMANI, R., ROSENBERG, S., INDRAMOHAN, G., JENG, M. & JUBRAN, R. 2012. An exploratory epidemiological study of Langerhans cell histiocytosis. *Pediatr Blood Cancer*, 59, 1324-6.
- WERTZ, I. E., KUSAM, S., LAM, C., OKAMOTO, T., SANDOVAL, W., ANDERSON, D. J., HELGASON, E., ERNST, J. A., EBY, M., LIU, J., BELMONT, L. D., KAMINKER, J. S., O'ROURKE, K. M., PUJARA, K., KOHLI, P. B., JOHNSON, A. R., CHIU, M. L., LILL, J. R., JACKSON, P. K., FAIRBROTHER, W. J., SESHAGIRI, S., LUDLAM, M. J., LEONG, K. G., DUEBER, E. C., MAECKER, H., HUANG, D. C. & DIXIT, V. M. 2011. Sensitivity to antitubulin chemotherapeutics is regulated by MCL1 and FBW7. *Nature*, 471, 110-4.
- WHITLOCK, J. A., GREER, J. P. & LUKENS, J. N. 1991. Epipodophyllotoxin-related leukemia. Identification of a new subset of secondary leukemia. *Cancer*, 68, 600-4.
- WILLEMS, F., AMRAOUI, Z., VANDERHEYDE, N., VERHASSELT, V., AKSOY, E., SCAFFIDI, C., PETER, M. E., KRAMMER, P. H. & GOLDMAN, M. 2000. Expression of c-FLIP(L) and resistance to CD95-mediated apoptosis of monocyte-derived dendritic cells: inhibition by bisindolylmaleimide. *Blood*, 95, 3478-82.
- WILLIS, B., ABLIN, A., WEINBERG, V., ZOGGER, S., WARA, W. M. & MATTHAY, K. K. 1996. Disease course and late sequelae of Langerhans' cell histiocytosis: 25-year experience at the University of California, San Francisco. *J Clin Oncol*, 14, 2073-82.
- WILLMAN, C. L., BUSQUE, L., GRIFFITH, B. B., FAVARA, B. E., MCCLAIN, K. L., DUNCAN, M. H. & GILLILAND, D. G. 1994. Langerhans'-cell histiocytosis (histiocytosis X)--a clonal proliferative disease. *N Engl J Med*, 331, 154-60.
- VISHWANATH, M., NISHIBU, A., SAELAND, S., WARD, B. R., MIZUMOTO, N., PLOEGH, H. L., BOES, M. & TAKASHIMA, A. 2006. Development of intravital intermittent confocal imaging system for studying Langerhans cell turnover. *J Invest Dermatol*, 126, 2452-7.
- WNOROWSKI, M., PROSCH, H., PRAYER, D., JANSSEN, G., GADNER, H. & GROIS, N. 2008. Pattern and course of neurodegeneration in Langerhans cell histiocytosis. *J Pediatr*, 153, 127-32.
- WRIGHT, J. F., GUO, Y., QUAZI, A., LUXENBERG, D. P., BENNETT, F., ROSS, J. F., QIU, Y., WHITTERS, M. J., TOMKINSON, K. N., DUNUSSI-JOANNOPOULOS, K., CARRENO, B. M., COLLINS, M. & WOLFMAN, N. M. 2007. Identification of an interleukin 17F/17A heterodimer in activated human CD4+ T cells. *J Biol Chem*, 282, 13447-55.
- WU, J., DU, J., LIU, L., LI, Q., RONG, W., WANG, L., WANG, Y., ZANG, M., WU, Z., ZHANG, Y. & QU, C. 2012. Elevated pretherapy serum IL17 in primary hepatocellular carcinoma patients correlate to increased risk of early recurrence after curative hepatectomy. *PLoS One*, 7, e50035.
- XU, S. & CAO, X. 2010. Interleukin-17 and its expanding biological functions. *Cell Mol Immunol*, 7, 164-74.
- YAMASHITA, J., DATTA, N. S., CHUN, Y. H., YANG, D. Y., CAREY, A. A., KREIDER, J. M., GOLDSTEIN, S. A. & MCCAULEY, L. K. 2008. Role of Bcl2 in osteoclastogenesis and PTH anabolic actions in bone. *J Bone Miner Res*, 23, 621-32.
- YANG, M., MA, C., LIU, S., SHAO, Q., GAO, W., SONG, B., SUN, J., XIE, Q., ZHANG, Y., FENG, A., LIU, Y., HU, W. & QU, X. 2010. HIF-dependent

- induction of adenosine receptor A2b skews human dendritic cells to a Th2-stimulating phenotype under hypoxia. *Immunol Cell Biol*, 88, 165-71.
- YANG, X. O., CHANG, S. H., PARK, H., NURIEVA, R., SHAH, B., ACERO, L., WANG, Y. H., SCHLUNS, K. S., BROADDUS, R. R., ZHU, Z. & DONG, C. 2008. Regulation of inflammatory responses by IL-17F. *J Exp Med*, 205, 1063-75.
- YE, P., GARVEY, P. B., ZHANG, P., NELSON, S., BAGBY, G., SUMMER, W. R., SCHWARZENBERGER, P., SHELLITO, J. E. & KOLLS, J. K. 2001. Interleukin-17 and lung host defense against *Klebsiella pneumoniae* infection. *Am J Respir Cell Mol Biol*, 25, 335-40.
- YEN, D., CHEUNG, J., SCHEERENS, H., POULET, F., MCCLANAHAN, T., MCKENZIE, B., KLEINSCHKE, M. A., OWYANG, A., MATTSON, J., BLUMENSCHIN, W., MURPHY, E., SATHE, M., CUA, D. J., KASTELEIN, R. A. & RENNICK, D. 2006. IL-23 is essential for T cell-mediated colitis and promotes inflammation via IL-17 and IL-6. *J Clin Invest*, 116, 1310-6.
- YOON, J. H., PARK, H. J., PARK, S. Y. & PARK, B. K. 2013. Langerhans cell histiocytosis in non-twin siblings. *Pediatr Int*, 55, e73-6.
- YOULE, R. J. & STRASSER, A. 2008. The BCL-2 protein family: opposing activities that mediate cell death. *Nat Rev Mol Cell Biol*, 9, 47-59.
- YOUSEM, S. A., COLBY, T. V., CHEN, Y. Y., CHEN, W. G. & WEISS, L. M. 2001. Pulmonary Langerhans' cell histiocytosis: molecular analysis of clonality. *Am J Surg Pathol*, 25, 630-6.
- YU, R. C., ALAIBAC, M. & CHU, A. C. 1995. Functional defect in cells involved in Langerhans cell histiocytosis. *Arch Dermatol Res*, 287, 627-31.
- YU, R. C., CHU, C., BULUWELA, L. & CHU, A. C. 1994. Clonal proliferation of Langerhans cells in Langerhans cell histiocytosis. *Lancet*, 343, 767-8.
- ZAMZAMI, N., MARCHETTI, P., CASTEDO, M., ZANIN, C., VAYSSIÈRE, J. L., PETIT, P. X. & KROEMER, G. 1995. Reduction in mitochondrial potential constitutes an early irreversible step of programmed lymphocyte death in vivo. *J Exp Med*, 181, 1661-72.
- ZHANG, G. X., GRAN, B., YU, S., LI, J., SIGLIANTI, I., CHEN, X., KAMOUN, M. & ROSTAMI, A. 2003. Induction of experimental autoimmune encephalomyelitis in IL-12 receptor-beta 2-deficient mice: IL-12 responsiveness is not required in the pathogenesis of inflammatory demyelination in the central nervous system. *J Immunol*, 170, 2153-60.
- ZHANG, X., ZHU, D., LAN, H., YU, L., PENG, W., MEI, Y. & FENG, Z. 2011. Langerhans cell histiocytosis, a new clinical phenotype of x-linked lymphoproliferative disease? *Eur J Med Genet*, 54, 165-8.
- ZHANG, Z., ZHENG, M., BINDAS, J., SCHWARZENBERGER, P. & KOLLS, J. K. 2006. Critical role of IL-17 receptor signaling in acute TNBS-induced colitis. *Inflamm Bowel Dis*, 12, 382-8.
- ZHU, F., WANG, Q., GUO, C., WANG, X., CAO, X., SHI, Y., GAO, F., MA, C. & ZHANG, L. 2011. IL-17 induces apoptosis of vascular endothelial cells: a potential mechanism for human acute coronary syndrome. *Clin Immunol*, 141, 152-60.
- ZHU, S. & QIAN, Y. 2012. IL-17/IL-17 receptor system in autoimmune disease: mechanisms and therapeutic potential. *Clin Sci (Lond)*, 122, 487-511.